

The Human Nail

Structure, Growth and Pathological Changes

U. Runne and C.E. Orfanos¹

Department of Dermatology, University of Cologne, Cologne, FRG

Introduction

The nail protects the delicate terminal phalanges of the fingers and toes. It forms a buttress for the digital pulp and aids in picking up small objects. Pathological changes in the nail wall and plate make many everyday activities more difficult. Moreover, changes in the nails have an important cosmetic aspect, so that the hands of these patients are often literally tied. It is interesting from a clinical point of view that nail changes are often signs of dermatological or systemic disease and may even be their leading sign. A correct classification and interpretation of pathological nail symptoms is only possible if the structure, growth and pathology of the nail are fully understood.

1. Structure of the Nail

The essential element of the nail is the translucent *nail plate*, which is closely connected to the reddish shimmering *nail bed*. Proximally and laterally it is surrounded by the epidermal *nail wall* and enclosed by the groove-shaped *nail fold*. Like the matrix, the *nail root*, invisible and 3–5 mm deep, lies in the nail fold. Only the distal end of the matrix appears as the *lunula*; its epithelium, being rich in nuclei, gives the lunula its whitish color, and makes it stand out from the nail bed (fig. 1, 2).

Seen longitudinally, the epidermis of the proximal nail wall bends around the nail root and lies dorsally to it as *eponychium*. Its stratum corneum forms the *cuticle*. The cuticle adheres to the nail plate and protects the nail fold and should therefore not be removed (fig. 3). Immediately below the cuticle and

¹ We should like to thank Mrs. E. Bodeux, Miss R. Kunigk and Mrs. G. Scheffer for their help in preparing the figures and the photographs. We thank Dr. Nicholas M. Walker for checking the translation.

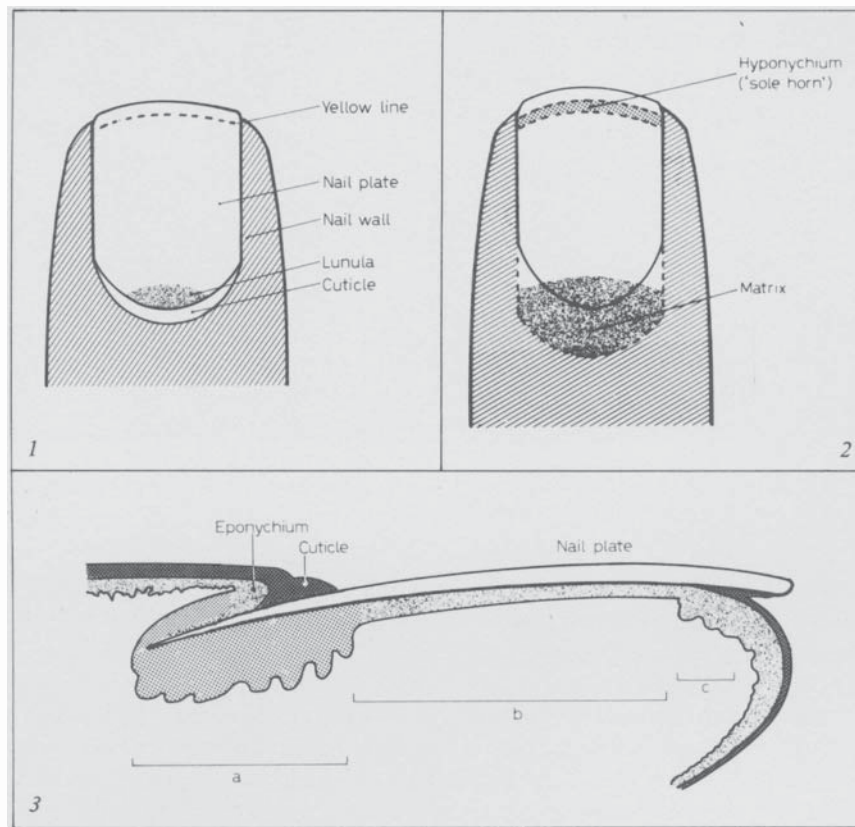


Fig. 1. Clinically visible parts of the nail.

Fig. 2. Localisation of matrix and 'sole horn'.

Fig. 3. Composition of the nail in longitudinal section. a = Matrix (dorsal and ventral parts); b = nail bed; c = hyponychium ('sole horn').

eponychium lies the *matrix* which may be divided into a superficial proximal and a deeper distal part. This topographical relation is clinically important as the superficial part of the matrix may be involved in diseases of the proximal nail wall.

Distal to the matrix lies the *nail bed* with its two sections, the *hyponychium* and the '*sole horn*' (in English nomenclature, 'hyponychium' refers to the 'sole horn' only). The hyponychium is connected to the underlying corium by capillary-rich longitudinal corrugated ridges of epithelium, whereas the narrow terminal '*sole horn*' possesses the normal papillary structure of the dermo-epidermal




Fig. 4. Nail surface, growth direction from up to down. Scanning electron micrograph.

Fig. 5. Free nail border. Scanning electron micrograph.

border. Matrix and connective tissue of the nail bed are without subcutis and are directly attached to the end phalanx. In the region of the 'yellow line' the nail plate becomes detached from its substratum. The resultant cleft is made water-tight by the 'sole horn'.

The *matrix* produces the cells of the nail plate and so does the nail bed, although to a small extent only. Both keratinize in the manner of parakeratosis without the formation of keratohyalin (79b, 80, 96a, 226). Eponychium and 'sole horn', however, show normal epidermal keratinization. As the matrix contains melanocytes in the lower 2–4 cell layers (86), the nail plate may be pigmented to a varying degree depending on race.

The *nail bed* contributes a few cornified cell layers to the underside of the nail. Production and apposition of the nail bed keratin follow synchronously with the extension of the nail plate. Clinically, the nail bed does not possess movement of its own (227), yet autoradiography demonstrated at least the wandering of a few matrix cells into the nail bed (139). As for the rest, the nail bed serves as a slide and holder of the nail plate.

The *nail plate* itself consists of adherent, dead and largely denuded cells, whose cell borders, in contrast with hair, are retained. Ultrastructurally, the nail, like hair and epidermis, contains keratin of the alpha type. In cross section the nail cells form compact horizontal horn cell lamellae. At the nail surface the nail cells slant from proximal-dorsal to distal-volar and cover each other, overlapping like roof tiles (fig. 4). Only at the free border where the intercellular cement is partially removed by detergents or other noxious influences, do the nail cells diverge (fig. 5).

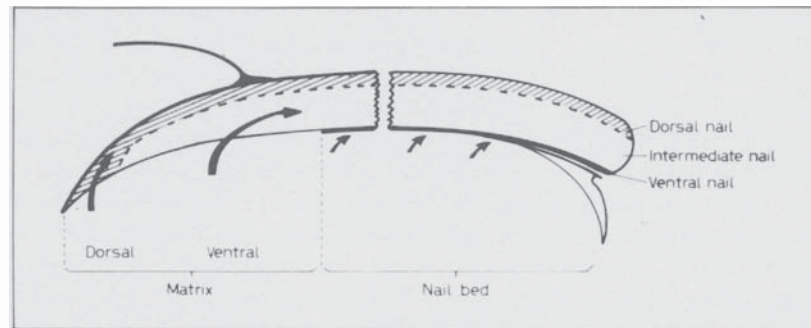


Fig. 6. Origin and arrangement of the three layers of the nail plate.

The nail plate itself, 0.5 mm thick, consists of *three layers*. Two are derived from the matrix and the third from the nail bed. All three differ in structure and histochemical properties (2, 65, 79b, 80, 96a, 112, 115). The dorsal layer (*'dorsal nail'*) arises from the dorsal matrix and consists of hard keratin, only a few cell layers thick. The middle layer (*'intermediate nail'*), three-quarters of the whole nail thickness, is formed by the large ventral matrix and consists of softer keratin. The dorsal and intermediate nails form the greater part of the nail, the so-called hard nail. The nail bed adds a one or two cell-layer thick ventral layer (*'ventral nail'*), consisting of soft hyponychial keratin, to the existing hard nail (115) (fig. 6). The ventral nail also grows on its own, e.g., after nail extraction, covering and protecting the nail bed.

The activity of the nail bed in nail cell formation is very limited – as far as has been observed in autoradiographic investigations in apes (233). However, the ventral nail has a special function in that it connects the nail plate firmly with the substratum. For that reason considerable force is needed to remove the nail and with it the nail bed epidermis. Many pathological changes such as pachyonychia, subungual keratoses and onycholysis occur in the hyponychial keratin.

2. Chemical and Physical Properties

Chemically the nail plate consists mainly of keratin, a scleroprotein containing high amounts of sulfur. The amino acid content corresponds largely to that of hair; on the other hand, it differs from the keratin of the stratum corneum. Glutamic acid, cystine, arginine, serine and leucine are present in higher amounts (72, 109). The lipid content lies below 5%, sulfur at about 4%. Ca, Mg, Zn, Fe and Cu are only present in trace amounts (46, 214) and are presumably of no significance to the hardness of the nails.

In these investigations one should always consider the environmental and endogenous influences which may be taken up by the nail surface. In *muco-viscidosis* ('fibrocystic disease') the sodium content of the nails is increased and nail material may be used for diagnostic purposes (74, 105a).

The nail contains about 18% *water*. As the diffusion-constant of water is about 100 times greater than that of the stratum corneum, the nail plate swells easily and is as porous as hair. If the water content rises to 30%, the nail becomes opaque and soft; if it falls below 16% the nail becomes brittle (174) (see 5.3.2.). A curious fact is that in spite of the absence of sweat glands, the water loss in the form of insensible perspiration per unit surface area of nail is as high as that of the palms and thus more than most other body regions (39, 93).

With the help of standardized determination of the *swelling properties* of the nail in sodium hydroxide solution, *Zaun* (236, 237) and *Zaun and Becker* (238) showed that the tendency for swelling is decreased in psoriatic and dystrophic brittle nails and in the nails in the yellow nail syndrome. Hence, a decrease in swelling capacity seems to point to abnormally produced nail material. In contrast, the rate of swelling of nails loosened by the action of fungi was much increased. The decreased swelling capacity could frequently be restored to normal by therapeutic regimes with gelatin-vitamin A.

It is now generally accepted that the *hardness* of the nails depends on the arrangement, and close attachment of the nail cells to each other. The transverse orientation of the keratin filaments to the direction of growth and the presence of intercellular cement are both factors of considerable importance (26, 63, 65). Curiously, the nails in patients suffering from protein deficiency appear to be harder than those in healthy patients (164b).

The chemical analysis of nail substance has *forensic importance*. Even after several months it is often possible to give a correct estimation of the type of toxin and when it was ingested. The nail of the big toe is the preferred site of investigation because of its size and slowness of growth. While such determinations are, in principle, also possible in hair, the data acquired from the nails are more reliable (75a, 83). Moreover, blood groups may also be demonstrated in the nail substance. This will be important in forensic medicine, if only hands or feet are obtainable or if mummification or putrefaction have set in (75c).

3. Embryology

The development of the nail starts in the 10th embryonic week with a thickening of the epidermis of the dorsal end phalanx (so-called primary nail field). At the level of its proximal transverse groove, an epidermal duplication grows and forms the *primordial matrix* (fig. 7). Before this matrix begins definitive nail production, a thin, rootless *forenail* arises from the subsequent 'sole

Explore Litigation Insights

Docket Alarm provides insights to develop a more informed litigation strategy and the peace of mind of knowing you're on top of things.

Real-Time Litigation Alerts



Keep your litigation team up-to-date with **real-time alerts** and advanced team management tools built for the enterprise, all while greatly reducing PACER spend.

Our comprehensive service means we can handle Federal, State, and Administrative courts across the country.

Advanced Docket Research



With over 230 million records, Docket Alarm's cloud-native docket research platform finds what other services can't. Coverage includes Federal, State, plus PTAB, TTAB, ITC and NLRB decisions, all in one place.

Identify arguments that have been successful in the past with full text, pinpoint searching. Link to case law cited within any court document via Fastcase.

Analytics At Your Fingertips



Learn what happened the last time a particular judge, opposing counsel or company faced cases similar to yours.

Advanced out-of-the-box PTAB and TTAB analytics are always at your fingertips.

API

Docket Alarm offers a powerful API (application programming interface) to developers that want to integrate case filings into their apps.

LAW FIRMS

Build custom dashboards for your attorneys and clients with live data direct from the court.

Automate many repetitive legal tasks like conflict checks, document management, and marketing.

FINANCIAL INSTITUTIONS

Litigation and bankruptcy checks for companies and debtors.

E-DISCOVERY AND LEGAL VENDORS

Sync your system to PACER to automate legal marketing.