

JOURNAL OF CLINICAL PATHOLOGY

The Journal of the Association of Clinical Pathologists

HEALTH SCIENCES LIBRARY
APR 4 1991

- Occasionals**
- 177 **In situ hybridisation in perspective** *A Warford, I Lauder*
- 182 **Opportunistic protozoan infections in human immunodeficiency virus disease: Review highlighting diagnostic and therapeutic aspects** *A Curry, A J Turner, S Lucas*
- Papers**
- 194 **Histopathology and immunohistochemistry of the caecum in children with the Trichuris dysentery syndrome** *T T MacDonald, M-Y Choy, J Spencer, et al*
- 200 **Immunohistological characterisation of amyloid deposits in renal biopsy specimens** *R J Fitzmaurice, C Bartley, J McClure, P Ackrill*
- 205 **Occult papillary microcarcinoma of the thyroid — a potential pitfall of fine needle aspiration cytology?** *H R Harach, E Saravia Day, S B Zusman*
- 208 **Ki-67 staining in histological subtypes of breast carcinoma and fine needle aspiration smears** *V Kuenen-Bloumeester, Th H Van Der Kwast, H A J Van Laarhoven, S C Henzen-Logmans*
- 211 **c-erbB-2 expression in different histological types of invasive breast carcinoma** *S Soomro, S Shousha, P Taylor, H M Shepard, M Feldmann*
- 215 **DNA flow cytometry of follicular non-Hodgkin's lymphoma** *J C Macartney, R S Camplejohn, R Morris, K Hollowood, D Clarke, A Timothy*
- 219 **Histometric studies on cellular infiltrates of tuberculin tests in patients with sarcoidosis** *J G Lowe, J H Gibbs, R C Potts, J L Stanford, J Swanson Beck*
- 224 **Monocyte counting: Discrepancies in results obtained with different automated instruments** *W Goossens, L van Hove, R L Verwilghen*
- 228 **Measurement of acute phase proteins for assessing severity of Plasmodium falciparum malaria** *S H Gillespie, C Dow, J G Raynes, R H Behrens, P L Chiodini, K P W J McAdam*
- 232 **Plasma leucocyte elastase concentrations in smokers** *C R K Hind, H Joyce, G A Tennent, M B Pepys, N B Pride*
- 236 **Measurement of alkaline phosphatase of intestinal origin in plasma by P-bromotetramisole inhibition** *T Kuwana, S B Rosalki*
- 238 **Automated microparticle enzyme immunoassays for IgG and IgM antibodies to Toxoplasma gondii** *J W Safford, G G Abbott, M C Craine, R G MacDonald*
- 243 **Plasma histamine in patients with chronic renal failure and nephrotic syndrome** *D S Gill, V A Fonseca, M A Barradas, R Balliod, J F Moorhead, P Dandona*
- 246 **Lack of specificity for antibodies to double stranded DNA found in four commercial kits** *M Kadlubowski, M Jackson, P L Yap, G Neill*
- Short reports**
- 251 **Immunocytological diagnosis of primary cerebral non-Hodgkin's lymphoma** *A P Lai, A S Wierzbicki, P M Norman*
- 253 **Primary squamous cell carcinoma of the terminal ileum** *C C Platt, N Y Haboubi, P F Schofield*
- 255 **Cells containing factor XIIIa and pulmonary fibrosis induced by bleomycin** *M Toida, Y Okumura, T Takami*
- 257 **Audit of turn-around times in a microbiology laboratory** *S Rogers, M J Bywater, D S Reeves*
- 258 **Comparative yield of Salmonella typhi from blood and bone marrow cultures in patients with fever of unknown origin** *B J Farooqui, M Khurshid, M K Ashfaq, M Ata Khan*
- 259 **Recovery of CD3+ and CD5- lymphocyte subpopulation after autologous bone marrow transplantation and chemotherapy** *P J McKay, A McLaren, L M Andrews, N P Lucie*
- Miscellanea**
- 262 **Correspondence · Book reviews · Notices ·**

BRITISH MEDICAL ASSOCIATION, TAVISTOCK SQUARE, LONDON, WICHUR

JOURNAL OF CLINICAL PATHOLOGY

The Journal of the Association of Clinical Pathologists

Editor: John Lilleyman
Deputy Editor: David Lowe
Technical Editor: Caroline White
Editorial Assistant: Mavis Burrell

EDITORIAL BOARD

AJ Bellingham	DR Davies	E Gowland	DY Mason	JD Sleigh
AJ Bint	PD Dawkins	MR Haeney	J O'D McGee	JP O'Shea
AW Boylston	A Fleck	PG Isaacson	GL Ridgway	DR Turner
D Catovsky	J Gough	FD Lee	G Slavin	DL Williams
and the Editor, <i>British Medical Journal</i>				DA Winfield

Former Editors

AG Signy 1944-72 HEM Kay 1972-80 G Slavin 1978-88

Association of Clinical Pathologists

President: NK Shinton **President-Elect:** G Slavin **Vice-Presidents:** CB Hobbs, FD Lee
Honorary Officers: WR Timperley (Chairman of Council), DM Harris, (Secretary), AC Ames (Treasurer)
General Secretary: Mrs JS Turner
Address: The University of Sussex, School of Biological Sciences, Falmer, Brighton BN1 9QG; Tel (0273) 678435/6

Information for Authors

Papers should be sent in duplicate to the Editors, *Journal of Clinical Pathology*, BMA House, Tavistock Square, London WC1H 9JR. They should be type-written with double spacing on one side of the paper only. The names of the authors with initials or one forename should be followed by the name of the institution where the work was performed. An indication of the position held by each author must be given in an accompanying letter to the Editors, and this should include the signatures of all authors on papers with joint authorship. Guidelines on authorship are detailed in *J Clin Pathol* 1986;39:110. Results should not be shown as both tables and graphs, and histograms should not be used.

ARTICLES Articles should usually be no more than 2000 words long and should report original research of relevance to the understanding and practice of clinical pathology. They should be written in the standard form: a summary (maximum 200 words) saying what was done and why, what was found, and what was concluded; an introduction; material and methods; results; and discussion. Single case reports of outstanding interest or clinical relevance are welcomed, and are usually published as indexed letters. Letters to the Editor should be of not more than 500 words with no more than five references and one figure or table.

ACKNOWLEDGMENT OF RECEIPT A stamped addressed postcard should be enclosed for return to the author as acknowledgment of receipt of the manuscript. Overseas authors should enclose international reply paid coupons.

ETHICS The critical assessment of papers submitted will include ethical considerations.

ILLUSTRATIONS Diagrams should be reproduced photographically. The legends for illustrations should be typed with double spacing on a separate sheet. Photographs and photomicrographs should be of high quality in full tonal scale on glossy paper, and unmounted. Only salient detail should be included, and prints should be no larger than 19 cm without margins.

ABBREVIATIONS Abbreviations must be spelt out on first use or be accompanied by explanation in the text. The use of non-standard abbreviations and acronyms should be avoided.

Symbols and abbreviations should be in the Vancouver style.

UNITS All measurements should be given in SI units.

REFERENCES The references must be given in the Vancouver style.

REPRINTS These may be ordered when the proof is returned. Prices for large numbers of reprints available on request.

NOTICE TO ADVERTISERS Applications for advertisement space and for rates should be addressed to the Advertisement Manager, *Journal of Clinical Pathology*, BMA House, Tavistock Square, London WC1H 9JR.

The *Journal of Clinical Pathology* is published monthly. The annual subscription rates are £137.00 inland and £146.00 overseas; USA \$250.00. Orders should be sent to The Subscription Manager, *Journal of Clinical Pathology*, BMA House, Tavistock Square, London WC1H 9JR. Subscribers may pay for their subscriptions by Access, Visa, or American Express, by quoting on their order the credit or charge card preferred, together with the appropriate personal account number and expiry date of the card. Orders can also be placed with any leading subscription agent or bookseller. (For the convenience of readers in the USA subscription orders, with or without payment, may also be sent to the *British Medical Journal*, Box 560B, Kennebunkport, Maine 04046, USA. All enquiries, however, must be addressed to the publisher in London.) All enquiries regarding air mail rates and single copies already published should be addressed to the publisher in London.

COPYRIGHT © 1991 *Journal of Clinical Pathology*. This publication is copyright under the Berne Convention and the International Copyright Convention. All rights reserved. Apart from any relaxations permitted under national copyright laws, no part of this publication may be reproduced, stored in a retrieval system or transmitted in any form or by any means without the prior permission of the copyright owners. Permission is not, however, required to copy abstracts of papers or of articles on condition that a full reference to the source is shown. Multiple copying of the contents of the publication without permission is always illegal.

Second class postage paid, at Rahway N.J. Postmaster to send address changes to: *Journal of Clinical Pathology* c/o Mercury Airfreight International Ltd. Inc., 2323 Randolph Avenue, Avenel, NJ 07001, USA.
ASTM CODEN:JCPAAK 44(3) 177-264 (1991)
ISSN 0021-9746

Published by British Medical Association, Tavistock Square, London WC1H 9JR and printed in England by Eyre & Spottiswoode Ltd, London and Margate

c-erbB-2 expression in different histological types of invasive breast carcinoma

S Soomro, S Shousha, P Taylor, H M Shepard, M Feldmann

Abstract

Sections of 149 breast carcinomas were examined for the over-expression of *c-erbB-2* oncoprotein using the avidin-biotin immunoperoxidase technique and two different specific antibodies. These included the polyclonal antibody 21N and the monoclonal antibody 4D5. The tumours were divided into two main groups. The first included 75 cases of invasive ductal and classic invasive lobular carcinomas. The second group consisted of 74 cases with histological types known to have a good prognosis, including mucinous, alveolar variant of invasive lobular, medullary, tubular, cribriform and papillary carcinomas. Fifteen (20%) tumours of the first group were positive with the two antibodies. Fourteen of these were of the ductal type and one was a mixed invasive ductal and lobular carcinoma. Ten of the pure ductal cases had areas of comedo carcinoma. The intraductal elements in a further tumour were positively stained with 21N antibody only. None of the second group of tumours, which included histological types known to have good prognosis, stained with 4D5, although one mucinous carcinoma was positively stained with 21N.

These findings suggest that in invasive breast carcinoma immunostaining for *c-erbB-2* is mainly seen in a subgroup of ductal tumours, and that almost all other histological types, especially those associated with good prognosis, lack this expression.

c-erbB-2 (also called *HER2* and *neu*) is a proto-oncogene which encodes a 185-190 kilodalton glycoprotein molecule that is closely related in structure to the epidermal growth factor receptor.¹⁻⁴ It maps to human chromosome 17.⁵ Under experimental conditions, *c-erbB-2* becomes a potent oncogene with transforming activity only when it is overexpressed in the cells.⁶ In 1986 the oncogene was found to be amplified in a small percentage of adenocarcinomas of various organs, including breast, but not in other types of tumours.⁷

The gene product has been localised to the cell membrane with extracellular, transmembrane, and intracellular domains.¹ Various specific antibodies have been raised to the extra- and intracellular domains. Repeated

studies have shown a good correlation between the amplification of the *c-erbB-2* gene and positive immunostaining for its protein product in the cells using these specific antibodies,⁸⁻¹² although overexpression of the protein product can sometimes occur in the absence of gene amplification.^{11,12}

In breast carcinoma between 9-33% of invasive tumours overexpress the gene product,^{8,9,11-20} and there is strong evidence that overexpression is associated with increased tumour aggressiveness.^{11,13,17,19-25} Most of these studies were carried out mainly on breast carcinomas of the ductal type. As there are other less common types of invasive breast carcinoma, some of which are known to have a relatively good prognosis,^{26,27} we investigated the possibility that such tumours may have a lower incidence of *c-erbB-2* protein overexpression. The study was carried out using two specific antibodies, one raised to the intracellular and the other to the extracellular domains of the *c-erbB-2* gene product.

Methods

Routinely processed paraffin wax sections of 149 invasive breast carcinomas were studied. The cases were selected on the basis of their histological type and were divided into two groups. The first included 75 cases of invasive ductal and classic invasive lobular carcinomas. The second group included 74 cases with histological types known to have a good prognosis, including mucinous, medullary, tubular, cribriform, papillary and the alveolar variant of invasive lobular carcinoma (table 1).²⁷

Two specific antibodies were used: a polyclonal antibody, 21N (kindly supplied by Dr W J Gullick, ICRF Oncology Group, Hammersmith Hospital, London), raised to a synthetic peptide of the predicted sequence of the intracellular domain of *c-erbB-2* gene product,²⁸ and a monoclonal antibody, 4D5 (Genentech, San Francisco, California, USA), raised to the extracellular domain of the gene product.²⁹⁻³¹

Four sections, each 5 μ m thick, were cut from a representative paraffin wax embedded tissue block of each case. Two of these sections were intended for staining with the specific antibodies, and two were used as controls. All sections were incubated overnight at 37°C. On the following day they were dewaxed in two changes of xylene for two minutes each and hydrated in graded alcohols. Endogenous peroxidase activity was blocked

Department of
Histopathology,
Charing Cross and
Westminster Medical
School, London,
W6 8RF
S Soomro
S Shousha

Charing Cross Sunley
Research Centre,
London
P Taylor
M Feldmann

Genentech Inc, San
Francisco, California,
USA
H M Shepard

Correspondence to:
Dr S Shousha

Accepted for publication
31 October 1990

Table 1 *c-erbB-2* immunostaining of breast carcinoma according to histological type

Histological type (all invasive)	Total No of cases	Cases positive with 21N (%)	Cases positive with 4D5 (%)
Ductal	63	14 (22%)	14 (22%)
Lobular, classic	11	0	0
Composite, ductal and lobular	1	1	1
Mucinous	23	1 (4%)	0
Lobular, alveolar variant	22	0	0
Medullary	13	0	0
Tubular	6	0	0
Cribriform	6	0	0
Papillary	4	0	0
Total	149	16 (11%)	15 (10%)

by 3% hydrogen peroxide in methanol for 30 minutes at room temperature. This was followed by rinsing three times in 0.1M TRIS-buffered-saline (TBS), pH 7.6.

Sections intended for staining with the polyclonal antibody 21N, and their controls, were incubated with 10% normal swine serum in TBS. Sections intended for staining with the monoclonal antibody 4D5, and their controls, were incubated in 10% normal rabbit serum. After 30 minutes excess serum was removed and sections were incubated overnight at 4°C either with the specific primary antisera, or, for the negative controls, with TBS.

On the following day sections were rinsed in TBS and then covered for 30 minutes with a 1 in 250 solution of the secondary antibodies in TBS (biotinylated swine anti-rabbit immunoglobulin for 21N, and biotinylated rabbit anti-mouse immunoglobulin for 4D5; both from Dakopatts, England). Sections were then rinsed three times with TBS and incubated for 60 minutes in avidin-biotin complex—horseradish peroxidase (Dakopatts, England). After rinsing in TBS sections were incubated with diaminobenzidine (DAB, Sigma, England) for six minutes and then counterstained with Harris's haematoxylin, dehydrated in graded alcohols, and mounted with Permount.

The results were assessed semiquantitatively according to the percentage of cells showing membrane staining so that (–) indicated absence of stained cells, (+) indicated staining of less than 33% of tumour cells, (++) staining of 33–66% of tumour cells, and (+++) staining of more than 66% of the cells. Cells showing cytoplasmic staining only were regarded as negative.^{32,33}

Results

Only 15 tumours stained with both antibodies (table 1). Of these, 14 were invasive ductal (22% of all ductal cases examined), 10 of which had areas of intraductal comedo elements (fig 1). The only other positive case was a composite tumour comprising two distinct zones, one invasive ductal and the other classic lobular; both showed strong positive staining (+++) with the two antibodies.

Positive staining with 21N was seen in two other tumours. These included a moderately stained (++) pure mucinous carcinoma (fig 2) and the intraductal elements of an invasive

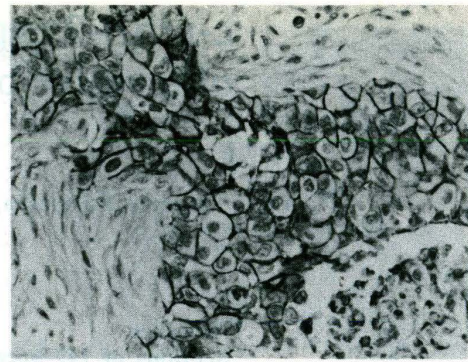
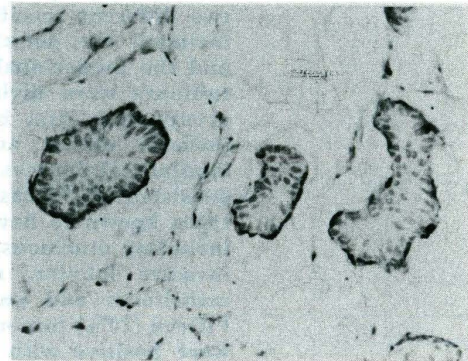
Figure 1 *c-erbB-2* positive invasive ductal carcinoma (avidin-biotin complex).Figure 2 *c-erbB-2* (21N) positive pure mucinous carcinoma (avidin-biotin complex).

Table 2 Comparison of semiquantitatively assessed staining results of 21N and 4D5 antibodies in invasive elements of 63 ductal carcinomas

Antibody	Total	–	+	++	+++
21N	63	49	0	1	13
4D5	63	49	2	6	6

ductal tumour. These two tumours did not stain with 4D5.

All remaining 133 tumours were negative with the two antibodies. These included all pure classic and alveolar lobular carcinomas, 22 of the 23 mucinous carcinomas, and all medullary, tubular, cribriform and papillary tumours examined (table 1).

Thus the two antibodies gave concordant results in 147 (98.7%) out of the 149 cases examined. In a given positive case, however, 21N tended to stain more cells than 4D5 (table 2). On the other hand, cytoplasmic staining, presumably non-specific, was often seen with 21N, but was not encountered in cases stained with 4D5.

Discussion

The main finding of this study is the almost consistent absence of *c-erbB-2* immunostaining in the uncommon histological varieties of invasive breast carcinoma, which are known to be associated with better prognosis than the common invasive ductal variety. This was

especially so when the monoclonal antibody 4D5, which recognises the extracellular domain of the oncogene product, was used. The results obtained with the polyclonal antibody 21N were similar, except for one case of mucinous carcinoma which was positive with this antibody but not with 4D5 (table 1). The findings provide indirect support for the existence of an association between positive *c-erbB-2* immunostaining and increased aggressiveness of invasive tumours. As most of these special types of breast carcinoma, with the exception of the medullary type, are also usually rich in oestrogen receptors,^{27,34} the findings are in line with the presence, in general, of an inverse relation between *c-erbB-2* and oestrogen receptors.^{18,25,35-39}

Almost all cases of invasive lobular carcinoma examined, whether classic or alveolar in type, did not overexpress this oncoprotein. The only positive lobular elements were seen in a composite tumour which consisted of separate, but adjacent, lobular and ductal parts. There are no published references about the *c-erbB-2* expression of the alveolar variant of lobular carcinoma, but investigators who have examined cases of the classic variant found them either all negative,^{12,17,35,40} or to have included only an occasional positive case.^{9,14,39,41} In view of the recently reported absence of the oncoprotein in lobular carcinoma *in situ*^{40,42} the findings suggest that overexpression of *c-erbB-2* may not have an important role in lobular neoplasia. The presence of *c-erbB-2* immunostaining in the composite ductal/lobular tumour examined may indicate that the pathogenesis of the lobular-looking elements in this case is different from that of pure lobular tumours.

The only cases that were positively stained with the two antibodies used in this study were either purely or partly of ductal type, and most of these cases also contained intraductal comedo elements. This is consistent with the findings of most previous studies and strongly supports the suggestion that overexpression of *c-erbB-2* oncoprotein in invasive breast carcinoma is almost totally restricted to a subset of ductal tumours with specific morphological features.^{9,16,40,42} It also seems that there are only two specific types of *in situ* breast tumour which frequently overexpress the oncoprotein—namely, intraductal comedo carcinoma^{9,39,42} and Paget's disease of the nipple.^{40,43,44} It is tempting to suggest that a common thread may connect these three lesions, one invasive and two *in situ*, together. They are all characterised by large cell size, and although they may occasionally occur separately, they are more commonly seen in a combination of two or three; and when they do, they almost all overexpress the *c-erbB-2* oncoprotein.^{43,44} The neoplastic changes are probably the same and involve specific cells at specific anatomical sites, and what determines what type of lesion(s) develop(s) is the primary site of the target cell(s) involved in the neoplastic process and its original directional proliferation potential.

Our study also shows that there is an excellent correlation (98.7%) between the

immunostaining results obtained with the two antibodies used which were raised to different domains of the oncogene product (intra- and extra-cellular). The polyclonal antibody raised to the intracellular domain (21N), however, tended to stain more cells in a given case, exclusively stained two (1.4%) extra cases (table 2), and in some tumours showed cytoplasmic staining which is considered to be non-specific by most authors.

We thank Dr W J Gullick of the ICRF Oncology Group, Hammersmith Hospital for supplying us with the 21N antibody. Photography was carried out by Mr Ron Barnett.

This study was presented in the Summer meeting of the Pathological Society of Great Britain and Ireland which was held in Nottingham, England, between 10-13 July 1990. This work is part of Dr Soomro's PhD thesis.

- 1 Schechter AL, Stern DF, Vaidyanathan L, et al. The neuro-oncogene: an erbB related gene encoding a 185,000 M tumour antigen. *Nature* 1984;312:513-16.
- 2 Coussense L, Yang-Fang TL, Liao Y-C, et al. Tyrosine kinase receptor with extensive homology to EGF receptor shares chromosomal location with neu oncogene. *Science* 1985;230:1132-9.
- 3 Yamamoto T, Ikawa S, Akiyama T, et al. Similarity of protein encoded by the human c-erbB-2 gene to epidermal growth factor receptor. *Nature* 1986;319:230-4.
- 4 Akiyama T, Sudo C, Ogawara H, Toyoshima K, Yamamoto T. The product of the human c-erbB-2 gene: A 185-kilodalton glycoprotein with tyrosine kinase activity. *Science* 1986;232:1644-6.
- 5 Schechter AL, Hung M-C, Vaidyanathan L, et al. The neu gene: An erb B-homologous gene distinct from and unlinked to the gene encoding the EGF receptor. *Science* 1985;229:976-8.
- 6 Di Fiore PP, Pierce JH, Kraus MH, Segatto O, King CR, Aaronson SA. erb B-2 is a potent oncogene when overexpressed in NIH/3T3 cells. *Science* 1987;237:178-82.
- 7 Yokota J, Yamamoto T, Toyoshima K, et al. Amplification of c-erbB-2 in human adenocarcinomas *in vivo*. *Lancet* 1986;i:765-7.
- 8 Venter DJ, Tuzi NL, Kumar S, Gullick WJ. Overexpression of the c-erb B-2 oncoprotein in human breast carcinomas: immunohistological assessment correlates with gene amplification. *Lancet* 1987;ii:69-72.
- 9 Van de Vijver MD, Peterse JL, Mooi WJ, et al. Neu-protein overexpression in breast cancer. Association with comedo-type ductal carcinoma *in situ* and limited prognostic value in stage II breast cancer. *N Engl J Med* 1988;319:1239-45.
- 10 Walker RA, Senior PV, Jones JL, Critchley DR, Varley JM. An immunohistochemical and *in situ* hybridisation study of c-myc and c-erbB-2 expression in primary human breast carcinomas. *J Pathol* 1989;158:97-105.
- 11 Slamon DJ, Godolphin W, Jones LA, et al. Studies of the HER-2/neu proto-oncogene in human breast and ovarian cancer. *Science* 1989;244:707-12.
- 12 Parkes HC, Lillycrop K, Howell A, Craig RK. C-erbB2 mRNA expression in human breast tumours: comparison with c-erbB2 DNA amplification with prognosis. *Br J Cancer* 1990;61:39-45.
- 13 Slamon DJ, Clark GM, Wong SG, Levin WJ, Ullrich A, McGuire WJ. Human breast cancer: correlation of relapse and survival with amplification of the HER-2/neu oncogene. *Science* 1987;235:177-82.
- 14 Barnes DM, Lammie GA, Millis RR, Gullick WL, Allen DS, Altman DG. An immunohistochemical evaluation of c-erbB-2 expression in human breast carcinoma. *Br J Cancer* 1988;58:448-52.
- 15 Gusterson BA, Machin LG, Gullick WJ, et al. C-erbB-2 expression in benign and malignant breast disease. *Br J Cancer* 1988;58:453-7.
- 16 Adnane J, Gaudray P, Simon M-P, Simony-Lafontaine J, Jeanteur P, Theillet C. Proto-oncogene amplification and human breast tumor phenotype. *Oncogene* 1989;4:1389-95.
- 17 Walker RA, Gullick WJ, Varley JM. An evaluation of immunoreactivity for c-erbB-2 protein as a marker of poor short-term prognosis in breast cancer. *Br J Cancer* 1989;60:426-9.
- 18 Zeillinger R, Kury F, Czerwnka K, et al. HER-2 amplification, steroid receptors and epidermal growth factor receptor in primary breast cancer. *Oncogene* 1989;4:109-14.
- 19 Zhou D-J, Ahuja H, Cline MJ. Proto-oncogene abnormalities in human breast cancer: c-ERBB-2 amplification does not correlate with recurrence of disease. *Oncogene* 1989;4:105-8.
- 20 Paik S, Hazan R, Fisher ER, et al. Pathologic findings from

Explore Litigation Insights

Docket Alarm provides insights to develop a more informed litigation strategy and the peace of mind of knowing you're on top of things.

Real-Time Litigation Alerts



Keep your litigation team up-to-date with **real-time alerts** and advanced team management tools built for the enterprise, all while greatly reducing PACER spend.

Our comprehensive service means we can handle Federal, State, and Administrative courts across the country.

Advanced Docket Research



With over 230 million records, Docket Alarm's cloud-native docket research platform finds what other services can't. Coverage includes Federal, State, plus PTAB, TTAB, ITC and NLRB decisions, all in one place.

Identify arguments that have been successful in the past with full text, pinpoint searching. Link to case law cited within any court document via Fastcase.

Analytics At Your Fingertips



Learn what happened the last time a particular judge, opposing counsel or company faced cases similar to yours.

Advanced out-of-the-box PTAB and TTAB analytics are always at your fingertips.

API

Docket Alarm offers a powerful API (application programming interface) to developers that want to integrate case filings into their apps.

LAW FIRMS

Build custom dashboards for your attorneys and clients with live data direct from the court.

Automate many repetitive legal tasks like conflict checks, document management, and marketing.

FINANCIAL INSTITUTIONS

Litigation and bankruptcy checks for companies and debtors.

E-DISCOVERY AND LEGAL VENDORS

Sync your system to PACER to automate legal marketing.