

THE LANCET

No 8625 BOSTON, MASS. AND LONDON · SATURDAY DECEMBER 17 1988 VOL II FOR 1988

ORIGINAL ARTICLES

Ocular Fundus Lesions in Divers P. J. Polkinghorne, FRACP, Kulwant Sehmi, FRPS, M. R. Cross, MB, Darwin Minassian, FRCS, Prof A. C. Bird, FRCS	1381	Italian Epidemic of Waterborne Tularaemia Dr E. Mignani and others	1423
Allele Loss on Short Arm of Chromosome 17 in Breast Cancers J. Mackay, FRCS, C. M. Steel, MRCPE, P. A. Elder, HNC, Sir Patrick Forrest, FRCS, Prof H. J. Evans, PHD	1384	Home Intravenous Immunoglobulin Therapy Dr H. M. Chapel, Sister V. M. Brennan	1423
Support for Adrenaline-hypertension Hypothesis: 18 hour Pressor Effect after 6 hours Adrenaline Infusion P. J. Blankestijn, MD, A. J. Man in't Veld, MD, Joke Tulen, B SC, A. H. van den Meiracker, PH D, Frans Boomsma, PH D, Peter Moleman, PH D, H. J. Ritsema van Eck, MD, F. H. M. Derckx, MD, Paul Mulder, PH D, S. J. Lamberts, MD, M. A. D. H. Schalekamp, MD	1386	Is Inactivated Poliovaccine more Expensive? Dr J. P. Moullia-Pelat and others	1424
Simultaneous Isolation of HIV-1 and HIV-2 from an AIDS Patient L. A. Evans, PH D, Jacques Moreau, MD, Koudou Odehouri, MD, Deborah Seto, BA, Graeme Thomson-Honnebier, MD, Harold Legg, BA, Ashley Barboza, BA, Cecilia Cheng-Mayer, PH D, Prof J. A. Levy, MD	1389	Heat-stable versus Heat-labile Vaccines Dr C. P. Muller, Prof Günther Jung	1424
Improvement of Hepatic Encephalopathy Treated with Flumazenil Georg Grimm, MD, Peter Ferenci, MD, Regina Katzenschlager, Christian Madl, Bruno Schneeweiss, MD, A. N. Laggner, MD, Kurt Lenz, MD, Prof Alfred Gangl, MD	1392	Management of Dysentery by Community Health Workers Dr Martin Kirkpatrick	1425

PRELIMINARY COMMUNICATION

Remission Induction in Non-Hodgkin Lymphoma with Reshaped Human Monoclonal Antibody CAMPATH-1H	1394
G. Hale, PH D, M. J. S. Dyer, MRCPE, M. R. Clark, PH D, J. M. Phillips, PH D, R. Marcus, MRC PATH, L. Riechmann, PH D, G. Winter, PH D, H. Waldmann, PH D	

Xamoterol: Stabilising the Cardiac Beta Receptor?	1403
Shackled, Shameful, and Shoddy	1404
Valproate, Spina Bifida, and Birth Defect Registries	1406
Diurnal Variation in Platelet Aggregation Responses	1407
Recurrent Respiratory Papillomatosis	1408

REVIEWS

Notices of Books	1399
-------------------------	------

GENERAL PRACTICE

Evaluation of a Structured Treatment and Teaching Programme on Non-insulin-dependent Diabetes	1407
Peter Kronsbein, PH D, Viktor Jörgens, MD, Ingrid Mühlhauser, MD, Vera Scholz, PH D, Annette Venhaus, MS, Prof Michael Berger, MD	

THERAPEUTICS

Reversible Ceftriaxone- associated Biliary Pseudolithiasis in Children	1411
U. B. Schaad, MD, Joanna Wedgwood-Krucko, MD, Heinz Tschaeppeler, MD	

HOSPITAL PRACTICE

Nasal Continuous Positive Airway Pressure in Pneumocystis carinii Pneumonia	1414
Steven Kesten, FRCPC, A. S. Rebeck, FRCPC	

ROUND THE WORLD

India	1415
--------------	------

IN ENGLAND NOW

	1416
--	------

LETTERS TO THE EDITOR

Reversed Polarity of Vasculocutaneous Potential and Neonatal Necrotising Enterocolitis	1417
Dr M. R. Millar and others	
Haemodilution in Renal Transplantation in Patients on Erythropoietin	1418
Dr Jan Wahlberg and others	
Treatments for Neurotic Disorders	1418
Prof D. F. Klein	
Licensing Synthetic Intra-cervical Tents	1418
Mr Nicholas Johnson, MRCOG	
Birthweight and Neonatal Mortality	1419
Dr Alfredo Pisacane	
Food Intolerance and Rheumatoid Arthritis	1419
Dr Pekka Kurki and others; Prof L. Corbeel and others	
Changes in Body Weight between Consecutive Pregnancies	1420
Dr J. S. Samra and others	
Salmonella enteritidis Phage Type 4 and Hens' Eggs	1421
Dr John Paul, Dr Barry Batchelor	
Cholinergic Side-effects of Tetrahydroaminoacridine	1421
Prof Raymond Levy	
Peripheral Facial Paralysis Indicating HIV Infection	1421
Dr Laurent Belec and others	
HIV, Glue Ear, and Adenoidal Hypertrophy	1422
Mr J. W. Fairley, FRCS, and others	
Cat Scratch Disease, Bartonellosis, and Kaposi Sarcoma	1422
Dr S. Dealler	
Inhibition of Cholinesterases by Pentamidine	1423
Dr T. A. Alston	

Parvovirus-associated Thrombocytopenic Purpura	1426
Dr N. K. Foreman and others	
Clinical Trial Numbers and Confidence Intervals of Pre-specified Size	1427
Mr S. J. Day, FSS	
Danish Experience of Statutory Right of Patients to Access to Hospital Records	1428
Dr Teis Andersen Dr Georg Jørgensen	
Better Surgeons get Better Results	1428
Mr Richard Novell, FRCS, and others	
Paying for Extended Medicare	1429
Dr Brian Potter	
ICRF Appeals	1429
Dr L. A. Price	
Graves' Disease: the Thyroid not the Pancreas	1429
Prof J. G. Scadding	
Specific Detection of Taenia saginata Eggs by DNA Hybridisation	1429
Dr A. Flisser and others	
Non-surgical Left-atrial Aortic Bypass	1430
Dr U. U. Babic and others	
Screening for Aortic Aneurysm	1431
Mr Jack Collin, FRCS	
Pelvic Irradiation and Tamoxifen as Risk Factors for Carcinoma of Corpus Uteri	1432
Dr Lennart Hardell	
Erythromycin-resistant Streptococcus pneumoniae	1432
Dr J. Verhaegen and others; Dr R. E. Warren and others	
Naevus of Jamaica	1433
Dr Nejat Akar	

MEDICINE AND THE LAW

Cosmetic Surgery: Greater Duty to Warn of Risks	1434
Doctors and Advertising	1434

NOTES AND NEWS

MRC Activities—Official	1435
Spare a Thought for the Victim	1435
Help for Sick Doctors	1435
After the Christmas Party	1435
Cancer Incidence World Wide	1435
Women's Health Concern	1436
Healers, Quacks, and Lady Doctors	1436
Postgraduate Education	1436
Training Courses for HIV/AIDS Counsellors	1436

CORRECTION

Fetal Obstructive Uropathy	1436
-----------------------------------	------

INTERNATIONAL DIARY

	1436
--	------

Editorial Office: 46 Bedford Square, London WC1B 3SL, England. Tel: 01-436 4981. The Lancet, North American Edition ISSN 0099-5355 published weekly by Little, Brown and Company, 34 Beacon St., Boston, Mass. 02108. Annual individual subscription in U.S. \$85.00, in Canada \$95.00; resident and intern rate (U.S. and Canada) \$48.50; Single copy \$7.00. Second class postage paid at Boston, Mass., and at additional mailing offices. © The Lancet Ltd., 17 December 1988. Postmaster: Send address changes to The Lancet, 34 Beacon St, Boston, Mass. 02108 (617) 227-0730, ext 516. THE WHOLE OF THE LITERARY MATTER IN THE LANCET IS COPYRIGHT

0189 1289LI SCRIP 0400530 RFB
SCRIPPS CLINIC-RES FDTN-C.R.F.L
MEDICAL LIBRARY DEC 29 1988
10666N TORREY PINES
LA JOLLA CA 92037

NEWSPAPER

Discussion

This study is the largest experience to date with the benzodiazepine antagonist flumazenil in the treatment of HE. The effects of the drug were assessed clinically and by SEP recordings. The late components of cortical SEPs (peaks N3 and P3) appear to be highly sensitive indicators of cortical dysfunction in HE.¹⁸ The results indicate that flumazenil may improve the HE that complicates both acute and chronic liver failure. Flumazenil treatment was associated with improvement in neurological status in 60% of episodes of HE; with one exception improvement occurred within a few minutes to an hour of drug administration. The speed of these responses contrasts with the interval of several hours that is typically necessary before HE improves after conventional therapies. The response to flumazenil in benzodiazepine intoxication is also very rapid.¹⁹

The 60% improvement rate may even underestimate the potential efficacy of flumazenil in the treatment of HE since most of the patients in this study had been encephalopathic for many days before flumazenil treatment and had not responded to conventional therapy. Furthermore all 5 patients with clinical evidence of increased intracranial pressure due to brain oedema did not respond to flumazenil. 1 of these patients improved after treatment with mannitol. The remaining 4 died within 3 days of flumazenil administration.

In 8 of the 12 episodes reponding to flumazenil there was an exacerbation of HE 0.5–4 h after stopping treatment. This transient effect of the drug is consistent with its pharmacokinetics.^{20,21} To achieve a sustained response continuous administration of the drug over longer periods may be necessary. Although these 12 episodes improved, no patient regained normal brain function at the end of treatment. The possibility that larger doses or a longer duration of treatment would have achieved complete improvement seems unlikely since, in benzodiazepine intoxication, much lower doses are sufficient for recovery.¹⁸ In addition an increased GABA-ergic tone may be only one of many abnormalities of brain function in patients with liver failure and correction of this particular abnormality may therefore induce incomplete improvement.

The mechanism by which flumazenil improves HE is uncertain. One possibility is displacement of an endogenous benzodiazepine-like substance from the GABA_A-benzodiazepine receptor. The presence of such a substance was suggested in the brains of animals with HE and in cerebrospinal fluid of patients dying with HE.²²

This study was supported by the Fonds zur Förderung der wissenschaftlichen Forschung (P 6169 M). Flumazenil was provided by Hoffmann-La Roche, Basel, Switzerland.

Correspondence should be addressed to G. G., 1st Department of Medicine, University of Vienna, A-1090 Vienna, Austria.

REFERENCES

- Schafer DF, Pappas SC, Brady LE, Jacobs R, Jones EA. Visual evoked potentials in a rabbit model of hepatic encephalopathy I: sequential changes and comparisons with drug induced comas. *Gastroenterology* 1984; 86: 540–45.
- Basile AS, Gammal SH, Mullen KD, Jones EA, Skolnick P. Differential responsiveness of cerebellar Purkinje neurons to GABA and benzodiazepine receptor ligands in an animal model of hepatic encephalopathy. *J Neurosci* 1988; 8: 2414–21.
- Schafer DF, Jones EA. Hepatic encephalopathy and the γ -aminobutyric-acid neurotransmitter system. *Lancet* 1982; ii: 18–20.
- Paul SM, Marangos PJ, Skolnick P. The benzodiazepine-GABA-chloride ionophore receptor complex: common site of minor tranquilizer action. *Biol Psych* 1981; 16: 213–29.

References continued at foot of next column

Preliminary Communication

REMISSION INDUCTION IN NON-HODGKIN LYMPHOMA WITH RESHAPED HUMAN MONOCLONAL ANTIBODY CAMPATH-1H

G. HALE¹
M. R. CLARK¹
R. MARCUS²
G. WINTER³

M. J. S. DYER²
J. M. PHILLIPS¹
L. RIECHMANN³
H. WALDMANN¹

Departments of Pathology¹ and Haematology,² University of Cambridge, and Laboratory of Molecular Biology,³ Cambridge

Summary A genetically reshaped human IgG1 monoclonal antibody (CAMPATH-1H) was used to treat two patients with non-Hodgkin lymphoma. Doses of 1–20 mg daily were given intravenously for up to 43 days. In both patients lymphoma cells were cleared from the blood and bone marrow and splenomegaly resolved. One patient had lymphadenopathy which also resolved. These effects were achieved without myelosuppression, and normal haemopoiesis was restored during the course of treatment, partially in one patient and completely in the other. No antiglobulin response was detected in either patient. CAMPATH-1H is a potent lympholytic antibody which might have an important use in the treatment of lymphoproliferative disorders and additionally as an immunosuppressive agent.

G. GRIMM AND OTHERS: REFERENCES—continued

- Baraldi M, Zeneroli ML, Ventura E, et al. Supersensitivity of benzodiazepine receptors in hepatic encephalopathy due to fulminant hepatic failure in the rat: reversal by a benzodiazepine antagonist. *Clin Sci* 1984; 67: 167–75.
- Bassett ML, Mullen KD, Skolnick P, et al. Amelioration of hepatic encephalopathy by pharmacologic antagonism of the GABA_A-benzodiazepine receptor complex in a rabbit model of fulminant hepatic failure. *Gastroenterology* 1987; 93: 1069–77.
- Bansky G, Meier PJ, Ziegler WH, Walser H, Schmid M, Huber M. Reversal of hepatic coma by benzodiazepine antagonist (Ro 15-1788). *Lancet* 1985; i: 1324–25.
- Bansky G, Meier PJ, Riederer E, et al. Effect of a benzodiazepine antagonist in hepatic encephalopathy in man. *Hepatology* 1987; 7: 1103.
- Scollo-Lavizzari G, Steinmann E. Reversal of hepatic coma by benzodiazepine antagonist (Ro 15-1788). *Lancet* 1985; i: 1324.
- Burke DA, Mitchell KW, Al Mardini H, Record CO. Reversal of hepatic coma with flumazenil with improvement in visual evoked potentials. *Lancet* 1988; ii: 505–06.
- Sutherland LR, Minuk GY. Ro 15-1788 and hepatic failure. *Ann Intern Med* 1988; 108: 158.
- Grimm G, Lenz K, Kleinberger G, et al. Ro 15-1788 improves coma in 4 out of 5 patients with fulminant hepatic failure: verification by long latency auditory and somatosensory potentials. *J Hepatol* 1987; 4 (suppl 1): S21.
- Meier R, Gyr K. Treatment of hepatic encephalopathy (HE) with the benzodiazepine antagonist flumazenil: a pilot study. *Eur J Anaesthesiol* 1988; suppl 2: 139–46.
- Teadale G, Jennett B. Assessment of coma and impaired consciousness: a practical scale. *Lancet* 1974; ii: 81–84.
- Conn HO, Lieberthal M. The hepatic coma syndromes and lactulose. Baltimore: Williams & Wilkins, 1979: 6.
- Cracco RQ, Bodis-Wolner I, eds. Frontiers of clinical neuroscience Vol 3: evoked potentials. New York: Alan R. Liss, 1986.
- Jasper HH. The ten/twenty electrode system of the International Federation. *Electroencephalogr Clin Neurophysiol* 1958; 10: 371–75.
- Chu NS, Yang SS. Portal-systemic encephalopathy: alterations in somatosensory and brainstem auditory evoked potentials. *J Neurol Sci* 1988; 84: 41–50.
- Prischi F, Donner A, Grimm G, et al. Value of flumazenil in benzodiazepine self-poisoning. *Med Toxicol* 1988; 3: 334–39.
- Lister R, Greenblatt D, Abernathy D, et al. Pharmacokinetic studies on Ro 15-1788, a benzodiazepine receptor ligand, in the brain of rat. *Brain Res* 1984; 290: 183–86.
- Roncardi G, Ziegler WH, Guentert TW. Pharmacokinetics of the new benzodiazepine antagonist Ro 15-1788 in man following intravenous and oral administration. *Br J Clin Pharmacol* 1986; 22: 421–28.
- Mullen KD, Martin JV, Mendelson WB, et al. Could an endogenous benzodiazepine ligand contribute to hepatic encephalopathy? *Lancet* 1988; i: 457–59.

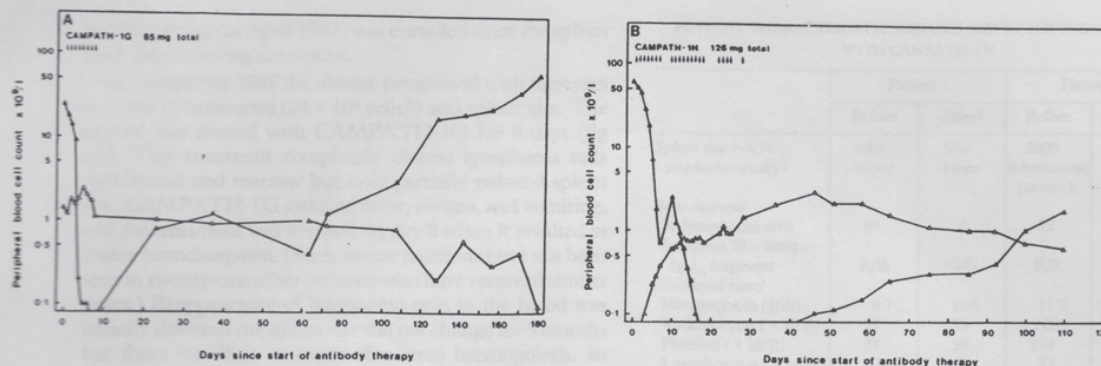


Fig 1—Effect of CAMPATH-1G (A) and CAMPATH-1H (B) on blood counts in patient 1.

▲ = lymphocytes; △ = neutrophils.

INTRODUCTION

TUMOUR treatment by passive serotherapy has had a long and largely unsuccessful history.¹ The advent of monoclonal antibodies gave fresh impetus to this approach, but results with unmodified antibodies are generally unremarkable. Efforts to enhance activity *in vivo* are now largely focused on the conjugation of antibodies to toxins or radionuclides. However, we are convinced that physiological effector mechanisms are still among the most potent and have tried to find the optimum combinations of antibody specificity and isotype to exploit them fully.

One possible specificity is the CAMPATH-1 antigen.² It does not readily undergo modulation and is abundantly expressed on virtually all lymphoid cells and monocytes, but not on other cell types.^{2,3} These properties make it a potential target for treatment of lymphoid malignant disorders and for immunosuppression. Several rat IgM and IgG antibodies to this antigen have been produced.^{4,5} The IgM (CAMPATH-1M) is intensely lytic with human complement and is widely used for depletion of T cells from bone marrow to prevent graft-versus-host disease.^{6,7} The IgG2b (CAMPATH-1G) is the most potent for cell depletion *in vivo*,⁸ probably because it binds to human Fc receptors and can activate the complement system.⁵ Patients with lymphoid malignant disorders treated with CAMPATH-1G (25–50 mg/day for 10 days) showed pronounced reduction in lymphoid infiltration of blood and bone marrow and improvement of splenomegaly.⁸ However, treatment with rat antibody is likely to be limited by an antiglobulin response. This problem should be reduced or eliminated by use of a human antibody. A reshaped human antibody (CAMPATH-1H) has been constructed—the hypervariable regions of the rat antibody were transplanted into normal human immunoglobulin genes.⁹ Human IgG1 was chosen since it had greater activity than other human isotypes both in complement lysis and in cell-mediated killing.^{9–11}

Here we describe the use of CAMPATH-1H to treat two patients with non-Hodgkin lymphoma. Although it was possible to continue treatment for up to 6 weeks without the development of a neutralising antiglobulin response, the main point of this report is to describe the efficacy of the antibody in clearing large masses of tumour cells. This is the first report of treatment with a fully reshaped human monoclonal antibody.

PATIENTS AND METHODS

Approval for the use of monoclonal antibodies was given by the ethical committee of Addenbrooke's Hospital and written consent was obtained from both patients.

Antibodies were obtained from culture supernatant of cells growing in a hollow fibre bioreactor ('Acusyst-Jr', Endotronics). CAMPATH-1G was purified by precipitation with ammonium sulphate; CAMPATH-1H was purified by affinity chromatography on protein-A-'Sepharose'. They were dissolved in phosphate-buffered saline, sterile filtered, and tested for pyrogen and sterility. Patients were prehydrated overnight and antibody, diluted in 500 ml saline, was infused over 2–4 h.

CAMPATH-1 expression on tumour cells was measured by flow cytometry and complement-mediated lysis.^{2,3,8} Serum concentrations of CAMPATH-1H were measured by immunofluorescence with normal lymphocytes.⁸ Southern blot analysis with an immunoglobulin J_H probe was used to detect residual tumour cells in DNA extracted from mononuclear fractions of bone marrow.⁸ Antiglobulin responses were sought by two techniques. The first was a solid-phase enzyme-linked assay using microtitre plates coated with CAMPATH-1H. After incubation with patients' serum samples, the assay was developed with biotin-labelled CAMPATH-1H followed by streptavidin-peroxidase. A mixture of monoclonal mouse antibodies against human IgG was used as a positive control and 500 ng/ml of this mixture could be detected. In the second assay, patients' serum samples were mixed with red cells coupled with CAMPATH-1H.¹² Agglutination by 5 ng/ml of the control mixture could be detected. Immunoglobulin allotypes were determined by means of standard reagents and techniques from the Central Laboratory of the Netherlands Red Cross blood transfusion service.

RESULTS

Patient 1

A 69-year-old woman presented in 1983 with acute appendicitis. Massive splenomegaly was found (table) and the bone marrow was heavily infiltrated with lymphocytes, some of which had clefted nuclei and a single nucleolus. There was weak membrane expression of IgM-kappa. Computed tomography scan showed splenomegaly but no lymphadenopathy. Grade I, stage IVA non-Hodgkin lymphoma in leukaemic phase was diagnosed. Between 1983 and 1987 the patient received oral and intravenous chemotherapy with combinations of cyclophosphamide, vincristine, prednisolone, and chlorambucil, which induced partial responses, the minimum level of marrow infiltration being 40%. Two courses of splenic radiotherapy were given,

but the second (in April 1987) was curtailed since the spleen grew larger during the course.

In September 1987 the disease progressed with increases in blood lymphocytes (24×10^9 cells/l) and spleen size. The patient was treated with CAMPATH-1G for 8 days (fig 1A). This treatment completely cleared lymphoma cells from blood and marrow but only partially reduced spleen size. CAMPATH-1G induced fever, nausea, and vomiting, and the treatment was stopped on day 8 when it resulted in severe bronchospasm. (Such severe reactions have not been seen in twenty-one other patients who have received similar doses.) Reappearance of lymphoma cells in the blood was initially slow and the spleen size did not change for 5 months but there was little recovery of normal haemopoiesis. In March 1988 the patient began to lose weight and experienced drenching night sweats. The spleen enlarged and lymphoma cells reaccumulated in the blood. They had similar phenotype and identical rearranged immunoglobulin J_H fragments to those seen before treatment. Marrow aspirate and trephine showed complete replacement of normal marrow by lymphoma cells (fig 2A); the patient became dependent on red-cell transfusions and was absolutely neutropenic.

The patient's serum did not block binding of CAMPATH-1H or CAMPATH-1G to normal lymphocytes and the tumour cells were still sensitive to these antibodies in vitro, so we decided to treat her with CAMPATH-1H. The starting dose was 1 mg daily and, since it was well tolerated, the dose was increased to a maximum of 20 mg/day, though the usual dose was 4 mg/day owing to the small amount available. In all the patient received 126 mg over 30 days. The response was prompt; in 6 days the night sweats had abated, by day 10 there was pronounced reduction in splenomegaly and recovery of blood neutrophils, and by day 18 lymphoma cells were cleared from the blood (fig 1B). On day 28 a bone marrow aspirate and trephine were hypocellular but showed active myelopoiesis and erythropoiesis and no lymphoid cells (fig 2B). No CAMPATH-1-positive cells could be detected by flow cytometry. DNA from the mononuclear marrow cells was germline when probed with an immunoglobulin J_H probe under conditions where clonal rearrangements could be detected in 0.2% of cells. Thus, we conclude that lymphoma cells were cleared from the marrow. The spleen volume was reduced about eight-fold (fig 3A, B), although it was still slightly larger than normal.

Other than fever occurring about 1 h after the end of antibody infusions there were no adverse effects of antibody treatment until the 5th week, when severe rigors occurred after each infusion. No antiglobulin response could be detected and the rate of clearance of antibody from the serum was unchanged. For the next 3 weeks the patient continued to experience occasional fever and rigors. She was given oral cotrimoxazole because of her lymphopenia, but no infective cause of these symptoms could be found.

In the next 4 months lymphocytes, which appeared morphologically normal, slowly reappeared in the blood (up to 0.2×10^9 /l). They did not show the characteristic rearranged immunoglobulin fragments, and both CD3-positive and CD19-positive cells were present (table). Serum immunoglobulin levels, which had been very low since presentation, have risen towards normal (table). A marrow aspirate and trephine taken 50 days after the end of treatment were again hypocellular but had no lymphomatous infiltration. This marrow sample contained

PATIENT CHARACTERISTICS BEFORE AND AFTER TREATMENT WITH CAMPATH-1H

—	Patient 1		Patient 2	
	Before	After*	Before	After*
Spleen size (ml)†	4460	590	2600	440
Lymphadenopathy†	None	None	Retrocrural; paraortic	None
<i>Bone marrow</i>				
% lymphoma cells	99	0	72	0
Southern blot analysis Ig J_H fragment	R/R	G/G	R/R	G/G
<i>Peripheral blood</i>				
Haemoglobin (g/dl)	8.7	10.6	11.2	12.0
Reticulocytes ($\times 10^9$ /l)	31	135	ND	ND
Platelets ($\times 10^9$ /l)	37	50	110	453
Lymphocytes ($\times 10^9$ /l)	60	0	37	0
Neutrophils ($\times 10^9$ /l)	0	2.0	4.6	7.3
Monocytes ($\times 10^9$ /l)	0	0.04	1.5	0.5
<i>Blood lymphocyte phenotype (%)</i>				
CD19	97	46	93	<5
CD3	0	32	8	80
CAMPATH-1M	96	ND	95	ND
CAMPATH-1H	98	ND	97	ND
<i>Serum immunoglobulins (g/l)</i>				
IgM	<0.3	1.2	<0.3	0.7
IgA	<0.5	<0.5	<0.5	0.5
IgG	5.8	8.2	3.2	4.7
<i>Bence-Jones</i>	None	None	++	None

*Made shortly after end of antibody treatment, except for lymphocyte phenotyping and serum immunoglobulins, which were assessed 6 weeks later.

†By computed tomography.
ND = not done.

4% CAMPATH-1-positive cells and showed some oligoclonal rearrangements of immunoglobulin genes. However, by day 100, lymphoma cells were again detected in the blood and the spleen size had started to increase. A second course of 12 days' therapy with CAMPATH-1H was completed with similar therapeutic benefit to the first and no adverse effects. Since the main reservoir of disease in this patient appeared to be the spleen, splenectomy was carried out at the end of this second course of treatment. At that time no tumour cells could be detected in blood or marrow. The patient is now well 37 days after the splenectomy. The lymphocyte count is low but she has normal neutrophil, platelet, and red-cell counts.

Patient 2

A 67-year-old man presented in April 1988 with splenic pain; there was 12 cm splenomegaly, and computed tomography scan of thorax and abdomen revealed retrocrural and para-aortic lymphadenopathy, the largest node measuring 3 cm in diameter (fig 3C). A blood count revealed 36.6×10^9 lymphocytes/ml, the majority being lymphoplasmacytoid cells which expressed surface IgG-kappa and were characterised by large cytoplasmic periodic-acid-Schiff-positive vacuoles which could be intensely stained by anti-IgG. A marrow aspirate contained 72% lymphomatous cells (fig 2C). DNA from blood mononuclear cells showed biallelic rearrangement of immunoglobulin J_H genes but was germline with various T-cell receptor and oncogene probes. The lymphoma cells expressed the CAMPATH-1 antigen in amounts comparable with normal lymphocytes but were more resistant to complement-mediated lysis. Stage IVA grade I

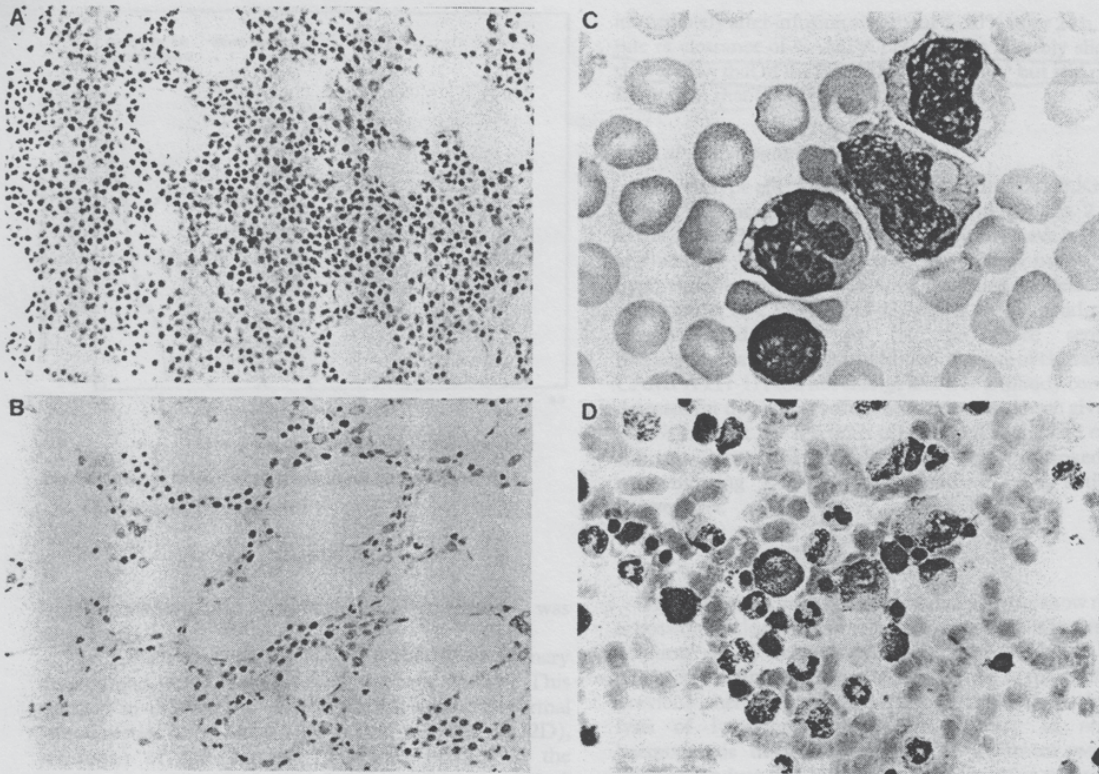


Fig 2—Cytology of bone marrow cells.

A = patient 1 trephine before treatment with CAMPATH-1H; B = patient 1 trephine on day 43 (ie, 16 days after treatment); C = patient 2 aspirate before treatment with CAMPATH-1H; D = patient 2 aspirate on day 78 (ie, 35 days after treatment). Reduced by 58% from $\times 100$ (A,B), $\times 1000$ (C), $\times 400$ (D).

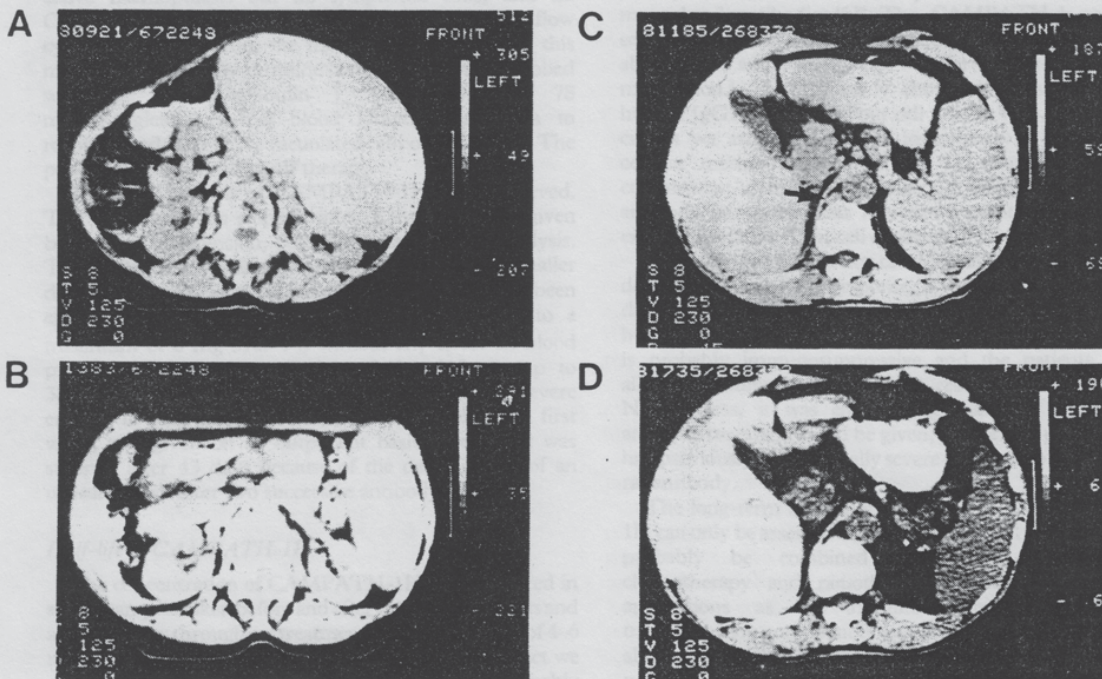


Fig 3—Computed tomography scans showing affected spleens and lymphnode.

A = patient 1 before treatment with CAMPATH-1H; B = patient 1 on day 57; C = patient 2 before treatment with CAMPATH-1H (retrocaval node arrowed); D = patient 2 on day 51.

Explore Litigation Insights

Docket Alarm provides insights to develop a more informed litigation strategy and the peace of mind of knowing you're on top of things.

Real-Time Litigation Alerts



Keep your litigation team up-to-date with **real-time alerts** and advanced team management tools built for the enterprise, all while greatly reducing PACER spend.

Our comprehensive service means we can handle Federal, State, and Administrative courts across the country.

Advanced Docket Research



With over 230 million records, Docket Alarm's cloud-native docket research platform finds what other services can't. Coverage includes Federal, State, plus PTAB, TTAB, ITC and NLRB decisions, all in one place.

Identify arguments that have been successful in the past with full text, pinpoint searching. Link to case law cited within any court document via Fastcase.

Analytics At Your Fingertips



Learn what happened the last time a particular judge, opposing counsel or company faced cases similar to yours.

Advanced out-of-the-box PTAB and TTAB analytics are always at your fingertips.

API

Docket Alarm offers a powerful API (application programming interface) to developers that want to integrate case filings into their apps.

LAW FIRMS

Build custom dashboards for your attorneys and clients with live data direct from the court.

Automate many repetitive legal tasks like conflict checks, document management, and marketing.

FINANCIAL INSTITUTIONS

Litigation and bankruptcy checks for companies and debtors.

E-DISCOVERY AND LEGAL VENDORS

Sync your system to PACER to automate legal marketing.