

PHASE-I CLINICAL TRIAL OF MONOCLONAL ANTIBODY IN TREATMENT OF GASTROINTESTINAL TUMOURS

HENRY F. SEARS
JEFFREY MATTIS
DOROTHEE HERLYN
PEKKA HÄYRY

BARBARA ATKINSON
CAROLYN ERNST
ZENON STEPLEWSKI
HILARY KOPROWSKI

The Fox Chase Cancer Center, Philadelphia, Pennsylvania, U.S.A.; Department of Pathology, Hospital of the University of Pennsylvania, Philadelphia; Centocor Inc., Malvern, Pennsylvania; and The Wistar Institute of Anatomy and Biology, Philadelphia

Summary A phase-I clinical trial of a murine monoclonal antibody that specifically suppresses growth of human gastrointestinal tumours in athymic mice was conducted in four patients, who were given 15–200 mg purified antibody. The monoclonal antibody persisted in the circulation for more than a week when more than 15 mg was given. Antibodies against mouse immunoglobulin developed in three of the four patients. In one patient who received autologous mononuclear cells that had been mixed with monoclonal antibody by way of a hepatic-artery catheter, hepatic metastases became smaller and their echogenic characteristics changed, and there was heavier monocyte infiltration in the histological appearance of a resected metastasis.

Introduction

We have developed a series of monoclonal antibodies that bind selectively to malignant cells of human gastrointestinal tract tumours.^{1,2} One of these antibodies, secreted by hybridoma 1083-17-1A (antibody 17-1A), mediates lysis of colorectal carcinoma cells by human or mouse effector cells³ and specifically inhibits the growth of human colon carcinomas xenografted in athymic (nu/nu) mice.⁴ The antigen detected by antibody 17-1A is not shed during culture by tumour cells.⁵

Monoclonal antibody 17-1A perfused through freshly resected human colons containing adenocarcinomas binds selectively to cells of some of these tumours.⁶ We have used this purified antibody in a phase-I clinical trial to assess its persistence in the systemic circulation, binding to tumour tissue, toxicity, and immunogenicity.

Patients and Methods

Patients

Four patients with metastatic gastrointestinal cancer, scheduled for palliative surgery at Fox Chase Cancer Center, gave informed consent to take part. Two patients had one ureter obstructed by tumour, three had hepatic metastases, and one had only local pelvic

recurrence. One patient, who died 2 months after surgery, had liver metastasis, obstructed ureter and colon, and an enterovaginal fistula after radiation therapy. Patient 4, a 54-year-old man, underwent subtotal gastrectomy for a poorly differentiated adenocarcinoma of the stomach 6 weeks before this trial. Serial computerised tomography (CAT) scans showed enlarging liver metastases.

Preparation of Monoclonal Antibody

Murine monoclonal antibody against human colorectal carcinoma (antibody 17-1A) of γ_2a isotype has been described previously.^{1,2} Ascitic fluid was collected aseptically, was allowed to clot at 37°C, and was then centrifuged and filtered under sterile conditions through 0.22 μm 'Millex' filters (Millipore, Bedford, Massachusetts). The filtrate was diluted with an equal volume of sterile 0.1 mol/l 'tris'-buffer, pH 8.0, and applied to a sterile 'protein-A-Sepharose' (Pharmacia, Piscataway, New Jersey) column (10 ml) for isolation of the IgG_{2a} immunoglobulin. The column was then washed thoroughly with 0.1 mol/l 'tris' buffer, pH 8.0; the adsorbed IgG_{2a} was eluted with 0.1 mol/l citrate, pH 4.5. The pH of the eluate was adjusted to neutral, and the eluate was dialysed against saline. The immunoglobulin was judged to be 95% pure in sodium-dodecyl-sulphate/polyacrylamide-gel electrophoresis and gave negative results in the *Limulus* amoebocyte lysate assay (M.A. Bioproducts, Bethesda, Maryland) at a concentration of 500 $\mu\text{g/ml}$. The immunoglobulin was quantified by absorbance at 280 nm.

Treatment with Monoclonal Antibody

Patients were tested for hypersensitivity to mouse immunoglobulin; patient 1 received 15 mg purified, pyrogen-free monoclonal antibody 17-1A intravenously, and patients 2 and 3 received 180 mg and 150 mg, respectively. Patient 4 was given a first injection of 200 mg antibody intravenously on day 0. On day 1 mononuclear cells (approximately 7.5×10^8), separated from one unit of his blood by gradient centrifugation, were incubated with 67 mg antibody 17-1A for 30 min at room temperature and returned to patient 4 by way of a hepatic-artery catheter. He was given a further 38 mg antibody 17-1A on day 3 and another 30 mg on day 7; the final injection was attempted on day 10, but the patient received only half the 30 mg dose.

Detection of Immunoglobulins

Radioimmunoassay was carried out as described before.^{1,2,5} To detect mouse immunoglobulin, rabbit anti-mouse-IG antibody was exposed to patients' serum or urine samples, and the binding was determined by ¹²⁵I-labelled rabbit anti-mouse F(ab') immunoglobulin. Circulating specific anti-colorectal-carcinoma activity of mouse immunoglobulin in patients' serum was detected with live SW 1116 colon carcinoma cells as the target cells.⁷ To detect human antibodies against mouse immunoglobulin in patients' serum, mouse monoclonal anti-colon-carcinoma antibody was allowed to react with patients' serum samples, and ¹²⁵I-labelled rabbit antibodies against human F(ab')₂ immunoglobulin were used to detect the binding.

Immunoperoxidase Assay with Monoclonal Antibodies

The immunoperoxidase assay was carried out by the method of Kolcher et al.⁸ Fixed, deparaffinised tissue samples were assayed for binding with monoclonal antibodies (see table): 17-1A, 19-

DR VAN DER WERF AND OTHERS: REFERENCES—continued

28. Linos DA, Beard CM, O'Fallon WM, Brockert MB, Beart RW, Kurland LT. Cholecystectomy and carcinoma of the colon. *Lancet* 1981; ii: 379–81.
29. Vernick LJ, Kuller LH. Cholecystectomy and rightsided colon cancer: an epidemiological study. *Lancet* 1981; ii: 381–83.
30. Liu K, Stampler J, Moss D, Garside D, Perskey V, Soltero I. Dietary cholesterol, fat, fibre and colon cancer mortality. An analysis of international data. *Lancet* 1979; ii: 782–85.
31. Cruse P, Lewin M, Clark CG. Dietary cholesterol is co-carcinogenic for human colon cancer. *Lancet* 1979; i: 752–55.
32. Hepner GW. Effect of decreased gallbladder stimulation on enterohepatic cycling and kinetics of bile acids. *Gastroenterology* 1975; 68: 1574–81.
33. Northfield TC, Hofmann AF. Biliary lipid secretion in gallstone patients. *Lancet* 1973; i: 747–48.

BINDING OF MONOCLONAL ANTIBODIES AS DETECTED BY IMMUNOPEROXIDASE ASSAY ON TISSUE SPECIMENS FROM PATIENT 4

Antibody	Primary stomach lesion	Liver metastasis after infusion	Bone metastasis after infusion
17-1A	±	±	±
19-9	++	++	–
10-17	++	++	++*
29-1	++	++	++
P3 x 63Ag8	–	–	–

*Focal.

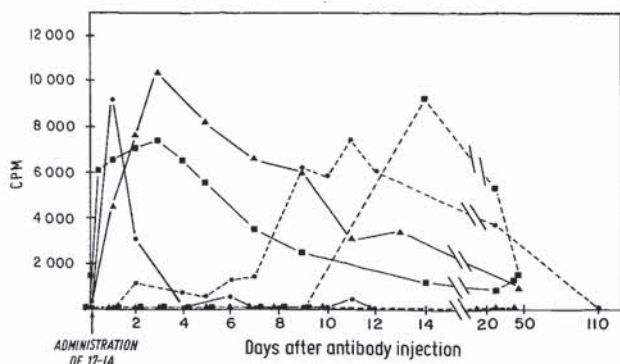


Fig. 1—Presence of mouse immunoglobulin (—●—) and of antibody against mouse immunoglobulin (---■---) in serum of patients 1 (●), 2 (▲) and 3 (■).

(directed against a monosialoganglioside present in serum of patients with gastrointestinal tumours)^{9,10} antibody 10-17 with Le^b specificity,¹¹ and 29-1 (raised against freshly isolated gastric carcinoma cells and directed against [α -1,3] fucosyl-*p*-globoside present in gastrointestinal tumour cells). Immunoglobulin of P3 \times 63Ag8 mouse myeloma was used as a control.

Results

Mouse immunoglobulin was found in the circulation of patient 1 for only 48 h after he received 15 mg monoclonal antibody (fig. 1). Mouse immunoglobulin was detectable for considerably longer in the blood of patients 2 and 3, who received 180 mg and 150 mg antibody, respectively (fig. 1). Antibodies against mouse immunoglobulin were first detected 6 to 8 days after treatment in patients 1 and 3 and reached peak levels 11–14 days after treatment; they dropped to zero 110 and 50 days after treatment, respectively, in patients 1 and 3 (fig. 1). Antibodies against mouse immunoglobulin did not develop in patient 2 during the 40 days after treatment. Patient 4, who received repeated injections of antibody 17-1A (fig. 2), had the highest serum levels of mouse immunoglobulin 24 h after administration of monoclonal antibody. The injections 3 and 10 days after treatment were followed by rises in circulating mouse immunoglobulin: the levels then fell in a linear fashion from the 11th until the 14th day after treatment. Antibodies against mouse immunoglobulin were first detected 9 days after treatment and increased steadily throughout 21 days after treatment (fig. 2).

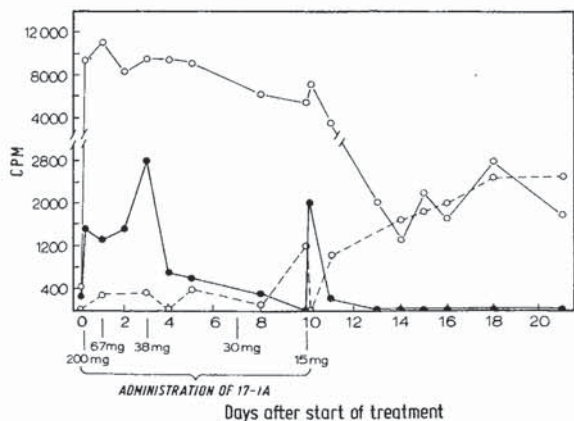


Fig. 2—Presence of mouse immunoglobulin (○—○) and of antibody against mouse immunoglobulin (○---○) and binding activity to SW 1116 target cells (●—●) in serum of patient 4.

The serum of patient 4 also showed a strong binding capacity of circulating mouse monoclonal antibody 17-1A to cultured colon carcinoma SW 1116 cells (fig. 2). The binding increased greatly immediately after each administration of the monoclonal antibody (except on day 7 when no blood sample could be obtained). The highest values for binding of circulating monoclonal antibody to cultured SW 1116 cells by sera of patients 2 and 3 were observed 1–3 days after administration of monoclonal antibodies.

In patients 1, 2, and 3 there were no immediate or delayed side-effects after administration of murine monoclonal antibody 17-1A. It was not possible to measure the effect of a single injection of monoclonal antibodies on the tumour because of the need for surgical intervention. Since we were seeking data to indicate the lack of adverse effects of murine immunoglobulins, we will not give a detailed description. In patient 4, however, the study was extended to include an evaluation of the therapeutic effect after repeated administration of monoclonal antibody, given either alone or together with the patient's peripheral-blood mononuclear cells.

Levels of carcinoembryonic antigen were normal, and levels of a circulating tumour antigen detected with antibody 19-9 against monosialoganglioside^{9,10} were high and remained high during the course of immunotherapy in patient 4.

Patient 4 was given a first injection of 200 mg purified antibody 17-1A intravenously over 30 min. The next day (day 1) the mixture of mononuclear cells and antibody was infused through a hepatic-artery catheter over 15 min. Small aggregates in the preparation were noted towards the end of the injection. The flow in the hepatic artery, which was sluggish at the start of the infusion, temporarily stopped at the end of the infusion. The next day (day 2) the patient's temperature was 38.5°C and he complained of right epigastric discomfort and hiccups. Abdominal examination was unremarkable; however, the patient's serum aspartate aminotransferase (AAT) level, which had been 86 IU on admission, rose to 259 IU then fell rapidly to 195 IU by that afternoon and continued to decrease throughout the remainder of the treatment. Lactic dehydrogenase levels also increased (to 429 IU) on day 2 but were almost normal by day 7.

On day 3, 38 mg 17-1A antibody was given intravenously. At laparotomy on day 4 three hepatic metastases with surrounding normal hepatic parenchyma were resected, and the nodal metastases in the retrocaval area were biopsied. On day 7 another 30 mg antibody was given. On day 10 the patient received less than half of the 30 mg dose, since he became flushed and complained of mild bronchospasm. Symptoms were relieved when administration of antibody was discontinued, and 0.3 ml adrenaline (1:10 000) was given intravenously. 4 days later the clavicular metastasis was biopsied. The patient showed no signs of serum sickness when examined for the next 2 weeks as an outpatient. He had no proteinuria, and renal function was normal. Liver ultrasound examination 3 weeks after administration of monoclonal antibodies showed that the metastases were much smaller, and their echogenic characteristics had changed. No change was noted in the bone metastasis during the same period.

The material from the original gastric resection of patient 4 showed a poorly differentiated adenocarcinoma that widely infiltrated the mucosa, muscularis, and serosa. The linitis plastica invasion of the tumour extensively involved nerves

and vascular spaces. The liver metastasis resected 4 days after the first infusion of antibody was a well-defined nodule with total necrosis in the centre. At the periphery of the nodule there was a rim of viable tumour cells interspersed among an inflammatory infiltrate composed mainly of mononuclear cells. Sections from the bone metastasis resected 14 days after the first infusion of antibody showed bone marrow with several foci of metastatic poorly differentiated adenocarcinoma similar to the primary tumour but without tumour necrosis and only focal mononuclear inflammatory infiltrate.

Sections from the stomach tumour and liver and bone metastases were studied by immunoperoxidase assay for binding of four monoclonal antibodies with a variety of specificities. Antigen detected by monoclonal antibody 17-1A was present on the tumour cells of the primary gastric carcinoma and in the liver and bone (clavicle) metastases (see table); the staining of the specimens, however, was very weak. Antigens detected by antibody 10-17 (which defines an Le^b specificity¹¹) and antibody 29-1 (against $[\alpha-1,3]$ fucosyl- p -globoside) were present in all three specimens, and the immunoperoxidase reaction was very strong. The monosialoganglioside antigen detected by monoclonal antibody 19-9^{9,10} was expressed by the tumour cells of the primary stomach lesion (fig. 3) and its liver metastasis (fig. 4), but not by tumour cells of the bone metastasis (see table).

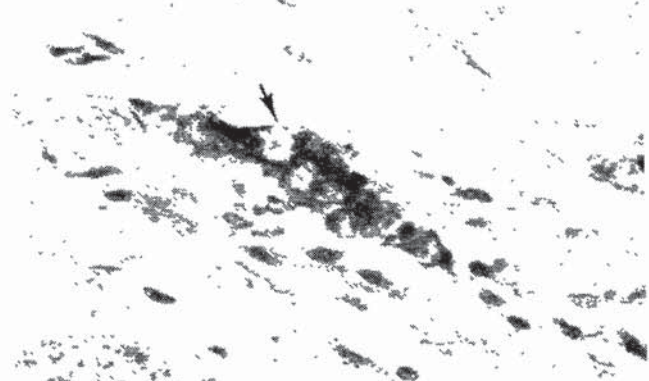


Fig. 3—Original biopsy of gastric adenocarcinoma.

Immunoperoxidase counterstained with haematoxylin only. Poorly differentiated tumour nests infiltrating the gastric muscularis demonstrate strong staining (arrow) with 19-9 monoclonal antibody. Original magnification $\times 640$, reduced by one third.

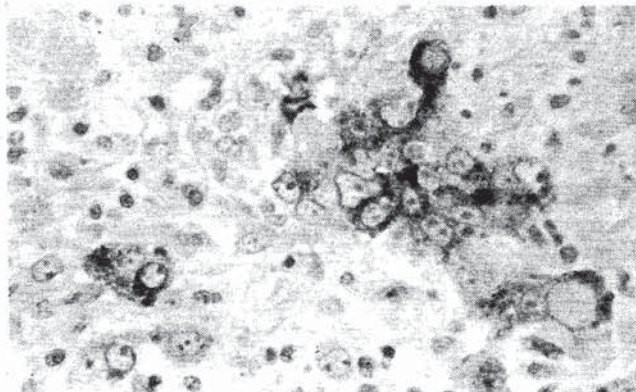


Fig. 4—Liver metastasis.

Immunoperoxidase counterstained with haematoxylin only. Cytoplasmic localisation of monosialoganglioside detected by 19-9 monoclonal antibody in malignant cells. Original magnification $\times 640$, reduced by one third.

Discussion

Our aim was to identify potential hazards of further immunotherapy or immunodiagnostic efforts by means of a monoclonal antibody that specifically destroys human gastrointestinal tumours implanted in animals.⁴ We were particularly concerned with binding of the antibody to tumour and to normal tissues, sensitisation of the host to mouse immunoglobulin, and potential antigenic modulation secondary to exposure to antibody. Though the patients showed no evidence of serum sickness, the data suggest that whole mouse immunoglobulins will induce an anti-mouse-immunoglobulin response.

In other attempts at immunotherapy against human tumours¹²⁻¹⁴ antibody against a normal lymphocyte antigen was used in smaller amounts; it may therefore have been bound rapidly by antigen on circulating cells.¹³ By contrast, antibody 17-1A does not react with antigens shed by the tumour cells.⁵ This may explain why functional antibody could be detected for a considerable time after administration. Administration of 15 mg antibody 17-1A results in the transient appearance of mouse immunoglobulin in the patient's circulation immediately after injection. When larger amounts (150 mg) of antibody 17-1A were injected, the intact mouse immunoglobulin was present in the circulation for longer periods of time and was also found transiently in the urine of one patient.

The fraction of the circulating mouse immunoglobulin that binds *in vitro* to colorectal carcinoma target cells and represents the active 17-1A antibody persisted in the serum of patients 2 and 3 for as long as the mouse immunoglobulin did. In patient 4 the specific binding decayed by day 10 after treatment, whereas mouse immunoglobulin persisted for a longer time. As with mouse immunoglobulin, binding activity to colorectal carcinoma cells was highest 2 to 4 days after treatment started.

In three of our four patients an antibody response to the mouse immunoglobulin developed within 6 to 10 days. The lack of antibody response in patient 2 might be attributed to her debilitated condition and to radiation and chemotherapy before the antibody therapy. Development of antibody against mouse immunoglobulin in patient 4 led to a large fall in circulating mouse immunoglobulin; this change accompanied the patient's adverse clinical reaction to the last injection of antibody 17-1A.

Miller et al.^{12,14} have described a T-cell leukaemic patient in whom antibody against mouse immunoglobulin was detected transiently 5 days after administration of monoclonal antibody, but who showed no clinical signs after a second dose of antibody 7 days after the first. The lack of clinical signs may be due to the smaller dosage of monoclonal antibody used (1-5 mg) or to the reduced ability of a patient with advanced leukaemia to mount an adequate immune response.

Purified peripheral-blood mononuclear cells exposed to 17-1A monoclonal antibody effectively destroy colorectal carcinoma cells.⁴ Destruction of colorectal carcinoma cells in athymic nude mice injected with antibody 17-1A is attributed to effector cells exposed to circulating antibody.¹⁵ As an adjunct to our immunotherapeutic trial we therefore isolated peripheral-blood lymphocytes of patient 4, exposed them to antibody 17-1A, and returned them to the patient. Liver metastases of patient 4 were affected by the treatment, as

shown by histology of the resected metastases and by ultrasound scanning of the two metastases remaining in situ. During the administration of mononuclear cells and antibody 17-1A, small aggregates formed which interfered with arterial blood supply to liver; lysis of tumour cells may therefore have been due to ischaemia. The transient elevation of AAT levels immediately after infusion of the mixture of peripheral-blood mononuclear cells and antibody may also have indicated hepatic dysfunction resulting from ischaemia. However, hepatic-artery flow observed 2 days later at surgery appeared normal, and the liver tissue appeared to be well vascularised. Furthermore, histology showed heavy infiltration of the necrotic area by mononuclear cells, implying that the peripheral-blood mononuclear cells played an active part in the destruction of tumour metastases.

Although the bone metastasis apparently became smaller during the treatment, there was no histological evidence of tumour destruction. The lack of evidence of tumour destruction might be attributed to antigenic modulation of the metastatic cells, as indicated by the absence of 19-9 antigen in this lesion.

We have demonstrated that a mouse monoclonal antibody against a human tumour antigen can be safely administered directly to the affected organ and that the antibody persists in the circulation for long periods of time. An anti-mouse-immunoglobulin response develops; this may limit repeated administration of whole molecules of mouse immunoglobulins. The efficacy of this immunotherapeutic approach may be enhanced by exposing the patient's own effector cells to monoclonal antibody and administering these cells directly into the metastatic site.

We thank J. Smith and K. O'Neill for technical assistance. The study was supported by grants CA-10815 and CA-21124 from the National Cancer Institute and grant RR-05540 from the Division of Research Resources.

Correspondence should be addressed to H. K., The Wistar Institute, 36th Street at Spruce, Philadelphia, PA 19104, U.S.A.

REFERENCES

- Herlyn M, Steplewski Z, Herlyn D, Koprowski H. Colorectal carcinoma-specific antigen: detection by means of monoclonal antibodies. *Proc Natl Acad Sci USA* 1979; **76**: 1438-42.
- Koprowski H, Steplewski Z, Mitchell K, Herlyn M, Herlyn D, Fuhrer P. Colorectal carcinoma antigens detected by hybridoma antibodies. *Somat Cell Genet* 1979; **5**: 957-72.
- Herlyn D, Herlyn M, Steplewski Z, Koprowski H. Monoclonal antibodies in cell-mediated cytotoxicity against human melanoma and colorectal carcinoma. *Eur J Immunol* 1979; **9**: 657-59.
- Herlyn D, Steplewski Z, Herlyn M, Koprowski H. Inhibition of growth of colorectal carcinoma in nude mice by monoclonal antibody. *Cancer Res* 1980; **40**: 719-21.
- Steplewski Z, Chang TH, Herlyn M, Koprowski H. Release of monoclonal antibody defined antigens by human colorectal carcinoma and melanoma cells. *Cancer Res* 1981; **41**: 2723-27.
- Sears HF, Herlyn D, Herlyn M, et al. *Ex vivo* perfusion of tumor-containing colon with monoclonal antibody. *J Surg Res* 1981; **31**: 145-50.
- Koprowski H, Steplewski Z, Herlyn D, Herlyn M. Study of antibodies against human melanoma produced by somatic cell hybrids. *Proc Natl Acad Sci USA* 1978; **75**: 3405-09.
- Kolcher D, Hovanhand P, Teramoto YA, Wunderlich D, Schlom J. Use of monoclonal antibodies to define a diversity of mammary tumor viral gene products in virions and mammary tumors of the genus MUS. *Cancer Res* 1981; **41**: 1451-59.
- Koprowski H, Herlyn M, Steplewski Z, Sears HF. Specific antigen in serum of patients with colon carcinoma. *Science* 1981; **212**: 53-55.
- Magnani JL, Brockhaus M, Smith DF, et al. A monosialoganglioside is a monoclonal antibody defined antigen of colon carcinoma. *Science* 1981; **212**: 55-56.
- Brockhaus M, Magnani JL, Blaszczyk M, et al. Monoclonal antibodies directed against the human Le^b blood group antigen. *J Biol Chem* 1981; **256**: 13223-25.
- Miller RA, Levy R. Response of cutaneous T cell lymphoma to therapy with hybridoma monoclonal antibody. *Lancet* 1981; **ii**: 226-30.
- Rutz J, Pesando JM, Sallan SE, et al. Serotherapy of acute lymphoblastic leukemia with monoclonal antibody. *Blood* 1981; **58**: 141-52.
- Miller RA, Maloney DG, McKillop Y, Levy R. *In vivo* effects of murine hybridoma monoclonal antibody in a patient with T-cell leukemia. *Blood* 1981; **58**: 78-86.
- Herlyn D, Koprowski H. Monoclonal antibodies against solid human tumors inhibit tumor growth in nude mice. *Hybridoma* 1982; **1**: 206.

MORPHOLOGICAL IDENTIFICATION OF THE AGENT OF KOREAN HAEMORRHAGIC FEVER (HANTAAN VIRUS) AS A MEMBER OF THE BUNYAVIRIDAE

J. B. MCCORMICK
E. L. PALMER

D. R. SASSO
M. P. KILEY

*Viral Disease Division, Center for Infectious Diseases,
Centers for Disease Control, Atlanta, Georgia, U.S.A.*

Summary Korean haemorrhagic fever (KHF) (Hantaan virus), a rodent-borne viral illness, is an important cause of human disease throughout much of Asia and Eastern Europe. The agent responsible for KHF has not yet been conclusively identified. Plaque-purified KHF virus was concentrated and then banded in a potassium tartrate gradient. Material from the 1.17-1.19 g/ml band was examined by electron microscopy and particles with a morphology identical to that of the family Bunyaviridae were found. The particles were aggregated by KHF serum but not by saline solution or non-immune serum. Identification of KHF virus as a member of the family Bunyaviridae implies a potential for spread by arthropod vectors.

Introduction

KOREAN haemorrhagic fever (KHF) was described several decades ago and is known by many names throughout Asia and Europe.¹ It is a severe, not uncommon disease, found in a geographic area from Japan to Europe which is occupied by about one-half of the world's population. The agent was isolated in 1978 by Lee et al.² and was grown in tissue culture by French in 1981.³ The virus has not, however, been satisfactorily purified for morphological identification. We describe the purification and morphological characteristics of Hantaan virus.

The strain of Hantaan virus used for this study, designated 76-118, has been registered in the Working Catalogue of Arthropod-Borne Viruses.⁴ Since it is a direct descendent of the 76-118 isolate described by Lee et al. in the original isolation of the virus,² and by French for growth in A-549 cells,³ it has a well-defined pedigree. It is also 1 of the 3 strains studied by Lee and Cho in their effort to characterise the virus.⁴

Several important characteristics of the 76-118 strain have been identified. (a) It was initially isolated from the rodent *Apodemus agrarius corae*.² (b) Antibody titres to 76-118 strain rise 4-fold or more in persons with typical KHF illness.^{2,3} (c) Antibody titres to strain 76-118 have been found in sera from patients with nephropathia epidemica in Scandinavia and epidemic haemorrhagic fever with renal syndrome in China and Japan.⁵⁻⁸ (d) Strain 76-118 is sensitive to lipid solvents and is acid labile.³

Methods

Virus Cultivation

A fifth A-549 cell passage of strain 76-118 virus was inoculated into 30 mm roller tubes of E-6 cells, a cloned line of Vero cells maintained at the Centers for Disease Control (CDC) and available from the American Type Culture Collection. These infected E-6 cells were maintained in minimal essential medium (MEM) with 10% fetal calf serum (FCS) and virus was harvested after 12 days. Six further passages were made in 75 cm² (surface) flasks by inoculation at a multiplicity of infection of approximately 1 tissue culture infective dose (TCID₅₀) per cell.