

Antiuterotrophic effects of a pure antioestrogen, ICI 182,780: magnetic resonance imaging of the uterus in ovariectomized monkeys

D19

M. Dukes, D. Miller, A. E. Wakeling and J. C. Waterton

Research Department 1, ICI Pharmaceuticals, Alderley Park, Macclesfield, Cheshire SK10 4TG, U.K.

RECEIVED 30 January 1992

ABSTRACT

ICI 182,780 is a potent specific pure antioestrogen which may offer advantages in breast cancer treatment compared with partial agonists like tamoxifen. To characterize further the potency and efficacy of ICI 182,780, its effects on the uterus of ovariectomized, oestrogen-treated monkeys (*Macaca nemestrina*) have been measured using magnetic resonance imaging (MRI). Quantitative MRI allows accurate non-invasive repetitive measurements of endometrial and myometrial volume following hormonal treatments, using each animal as its own control. Single i.m. injections of a long-acting oil-based formulation of ICI 182,780 sustained blockade of oestradiol action on the monkey uterus in a dose-dependent manner

for 3–6 weeks. Repeated injections of 4 mg ICI 182,780/kg at 4-weekly intervals provided increasingly effective blockade of uterine proliferation. In a short-acting formulation, ICI 182,780 also completely blocked the trophic action of oestradiol, administered concurrently, in ovariectomized monkeys. Similarly, ICI 182,780 caused involution of the uterus stimulated by prior treatment with oestradiol. The rate and extent of uterine involution in monkeys treated with ICI 182,780 was similar to that seen following oestrogen withdrawal. These studies demonstrate that ICI 182,780 is a fully effective pure antioestrogen in a primate.

Journal of Endocrinology (1992) 135, 239–247

INTRODUCTION

ICI 182,780 is a recently described potent pure antioestrogen (Wakeling, Dukes & Bowler, 1991). Unlike non-steroidal antioestrogens such as tamoxifen, ICI 182,780 has been shown to be devoid of partial agonist (oestrogenic) activity in rats and mice and may, therefore, offer some advantages for the treatment of human breast cancer (Wakeling *et al.* 1991). A long-lasting antioestrogenic effect of parenterally administered ICI 182,780, formulated as a suspension in arachis oil, was demonstrated in rats and in nude mice bearing xenografts of human breast cancer cells (Wakeling *et al.* 1991). Those studies were extended to examine the delay of oestrogen-induced perineal swelling in ovariectomized monkeys by pretreatment with 10 daily doses of 0.1, 0.5 or 1 mg ICI 182,780/kg, or a single dose of 10 mg/kg, before oestrogen treatment. A sustained, dose-related blockade of perineal swelling was noted (Wakeling *et al.* 1991). Preliminary studies using magnetic resonance imaging (MRI) demonstrated the feasibility of precise measurements of the monkey uterus and its response to

endocrine manipulation (Waterton, Miller, Dukes & Morrell, 1991). MRI is an ideal method for such studies since it is quantitative and non-invasive (Waterton *et al.* 1991) and the consequences of interanimal variability are minimized by using each animal as its own control (Waterton, Larcombe-McDouall & Miller, 1992). It greatly reduces, therefore, the number of animals required to give a meaningful result. This paper describes a series of studies undertaken to examine more fully the pharmacology of ICI 182,780 in the ovariectomized primate (*Macaca nemestrina*).

MATERIALS AND METHODS

Quantitative magnetic resonance imaging (MRI)

We have reported previously (Waterton *et al.* 1991, 1992) that the appearance of the corpus uteri of *Macaca nemestrina* in magnetic resonance (MR) images is very similar to that reported for women, although the convoluted cervix in the monkey has a rather different MR appearance from that in women.

We have previously described methodology for quantitative studies (Waterton *et al.* 1991), and discussed the reproducibility and statistical power of the techniques (Waterton *et al.* 1992); a brief description is provided here.

MR instrumentation

The study employed a 'Biospec 400/2.3' instrument (Oxford Research Systems, Coventry, U.K.) incorporating a 2.35 T magnet and pulsed field gradients up to 10 mT/m (where T is the SI symbol for Tesla, the unit of magnetic flux density). A radiofrequency resonator of 208 mm access diameter was employed as transmitter and receiver.

Oblique imaging

In order to allow comparisons between images acquired on different occasions, it is most desirable to measure volume rather than, say endometrial height or area, since the former avoids artefacts from repositioning errors or shape changes. The endometrial volume in this species can be quite small, below 0.1 cm³ in chronically ovariectomized animals, rising typically to 1 cm³ following oestrogen stimulation. Hence it is important to use MRI methods which allow good spatial resolution together with adequate signal-to-noise ratios. Since the uterus is somewhat ellipsoidal with one long axis, oblique imaging allows the use of the slice-selected two-dimensional Fourier-transform technique, which takes full advantage of the better resolution in plane than in slice thickness. Also, the orientation of the uterus within the pelvis varies from day to day depending both on its size in response to oestrogen, and also on other factors, presumably including the volume and disposition of the contents of the urinary bladder and lower gut. It is advantageous for quantitative studies to employ oblique MRI techniques which force the presentation of the uterus for image analysis to be similar from examination to examination, as shown in the Plate.

In order to achieve this reproducible oblique presentation, the following procedure was used for each MRI examination. A multislice sagittal image set was acquired in order to determine the spatial co-ordinates of the uterine cervix and fundus. From these co-ordinates, MRI parameters were calculated to allow the acquisition of eight contiguous oblique slices, the thickness, position and orientation of which were forced to depend on the vector connecting the fundus and cervix (Text-fig. 1). Thus, the presentation of the uterus in the images is more or less independent of its size, location and orientation in the pelvis. Image matrices were 256 × 256 giving an in-plane resolution of 0.6 mm. The signal from adipose tissue

was suppressed, and good contrast between the uterine tissues was ensured by using pulse sequence parameters T_R (repetition time) of 3000 ms and T_E (echo time) of 50 ms.

Quantification of the images

Endometrium and myometrium volumes were obtained by pixel counting in the oblique images using the irregular region-of-interest facilities within the programs 'uxnmr' or 'DISNMR' (Bruker Analytische Messtechnik GmbH, Karlsruhe, Germany). Only slices more fundal than the internal os were included in the analysis. The junction zone was included with the myometrium. Any contribution to endometrial volume from the lumen was neglected since this is very narrow and insignificant in comparison with the endometrium. Errors arising from interobserver variability were minimized since each of the seven experiments was analysed by a single observer (5/7 by D.M., 1 each by J.B.L.McD. and by S.A.B.; see Acknowledgements) and our conclusions are based on percentage changes, each animal acting as its own control. The intraobserver variability cannot be greater than the week-to-week variability, and this is 5% for the myometrium in ovariectomized females (Waterton *et al.* 1992). Limited correlations between measurements made by MRI and by histology gave satisfactory results, consistent with data previously reported in the human uterus (Lee, Gersell, Balfe *et al.* 1985).

Animal handling

Mature female pigtail monkeys (*Macaca nemestrina*) of 5–10 kg body weight were used. Animals were ovariectomized at least 11 months before their use in these studies. MRI examinations took place before the animals received their morning feed, in order to minimize artefactual noise associated with gut motion. Anaesthesia was induced with 0.7 mg ketamine/kg (Vetalar, Parke Davis, Pontypool, Gwent, U.K.) and maintained with halothane (Fluothane, ICI Pharmaceuticals, Macclesfield, Cheshire, U.K.).

Pharmacological protocols

To assess the effects of treatment with ICI 182,780, each animal was first treated with 5 µg oestradiol benzoate (OB: Sigma Chemical Company, Poole, Dorset, U.K.)/kg in arachis oil, s.c. daily for 7 days (day 0 to day 6 inclusive), unless otherwise noted. Uterine images were recorded on day 0 immediately before the first dose of OB and on day 7. Animals then received 5 mg progesterone (Sigma Chemical

Company) s.c., daily for 5 or 6 days. After progesterone withdrawal-induced menstruation, animals again received OB, together with ICI 182,780. Details of the treatment schedules employed and the timing of MRI in each experiment are given in the legends to Text-figs 2–5. One experiment used a different (cross-over) protocol; see legend to Text-fig. 6.

Analysis of the data

Using our MRI methods to study outbred populations of this species, we have shown previously (Waterton *et al.* 1992) that interanimal variation in the volumes of the uterine tissues greatly exceeds week-to-week variation in a single animal, e.g. by a factor of 8–12 in the myometrium, making it beneficial to use each animal as its own control. However, because of extreme endometrial atrophy at day 0, volumes of this tissue are inaccurate and probably not meaningful. Hence we have elected to normalize to the volumes of endometrial and myometrial tissues after 7 days of treatment with 5 µg OB, taken as 100%. Except where otherwise stated, results are presented as the arithmetic mean \pm S.E.M.

RESULTS

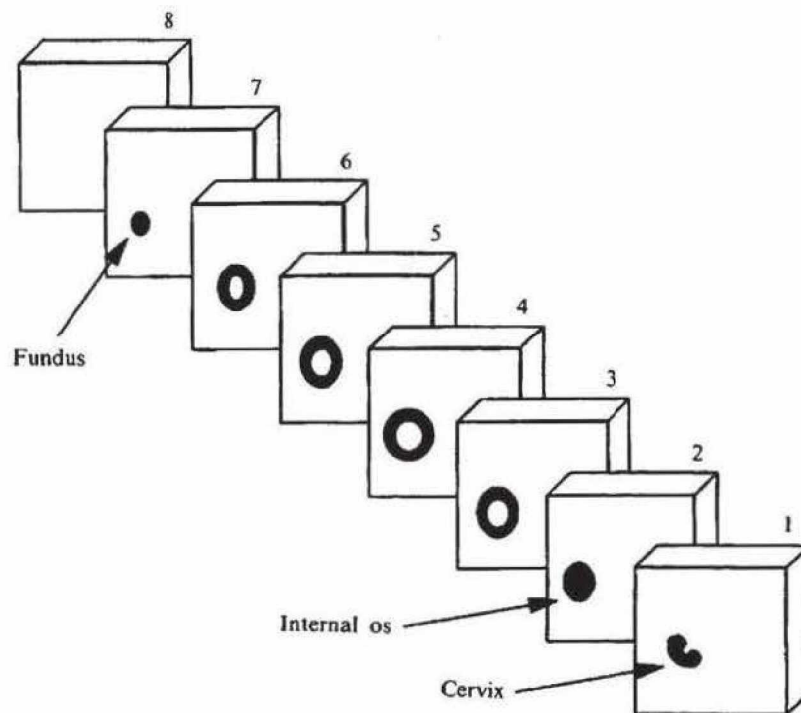
An initial treatment with OB alone established the extent of uterine response in ovariectomized monkeys. Typical MR images comparing the ovariectomized and oestrogen-treated uterus illustrate the large increase in endometrial volume after 7 days of OB treatment (cf. Plate, figs 1 and 2). Text-figure 2 compares the effects of unopposed oestrogen treatment for 7 and 14 days on endometrium and myometrium volume in two individual animals. In this and succeeding studies, treatment effects on tissue volume in individual animals are normalized to those achieved after 7 days of OB treatment. The changes in endometrium volume in response to oestrogen (>tenfold) were proportionately much greater than those of myometrium (approx. twofold). Before a pilot study in these animals, to address the effect of ICI 182,780, uterine involution was initiated by withdrawing OB and treatment for 6 days with progesterone (Text-fig. 2). Menstrual bleeding (not shown) was seen beginning on day 24/25 and continued for 5 or 6 days. The endometrium, and particularly the myometrium, had not regressed completely to basal levels (cf. day 35 and day 0, Text-fig. 2).

The effect of ICI 182,780 on the trophic response of the uterus to OB was first addressed using ICI 182,780 formulated as a suspension in arachis oil. This formulation has been demonstrated previously to provide a sustained antioestrogenic effect on the perineum

(Wakeling *et al.* 1991). Daily treatment for 10 days with 1 mg ICI 182,780/kg s.c. (day 39 to day 48, Text-fig. 2), beginning 3 days before the resumption of daily OB injections (day 42 to day 70, Text-fig. 2), completely blocked the uterotrophic action of oestradiol for 3–4 weeks (Text-fig. 2). After the effect of ICI 182,780 waned (day 70 to day 84, Text-fig. 2) progesterone treatment was again used to promote uterine involution.

The sustained antiuterotrophic action of ICI 182,780 confirmed in the above study was investigated further by the intramuscular administration of single doses of ICI 182,780 formulated, in solution, in a castor oil-based vehicle. The duration of action of differing doses of ICI 182,780 was assessed by MRI measurements of endometrium and myometrium volume immediately before treatment, when ICI 182,780 was administered i.m. and daily treatment with OB commenced, and weekly thereafter until uterine stimulation was apparent. Treatment effects were compared with that of OB alone recorded in each animal measured before antioestrogen treatment, as described above. The results in Text-fig. 3 confirmed that ICI 182,780 blocks the trophic action of OB on the endometrium and myometrium and that the duration of action of a single i.m. injection of ICI 182,780 was dose-related. The appearance of the uterus in MR images recorded before and 2 and 7 weeks after injection of ICI 182,780 is illustrated in the Plate (figs 3–5) and compared with the effect of unopposed OB treatment (Plate, fig. 2). Uterotrophic response was completely blocked initially (cf. Plate, figs 3 and 4 with Plate, fig. 2) but eventually resumed (Plate, fig. 5). Estimated by reference to the time from the onset of treatment required to reach 50% of the unopposed oestrogen control volume, endometrium response to OB was blocked for approximately 3, 4 and 6 weeks, and myometrium for 3, >4 and >7 weeks after 2.5, 4 or 5 mg ICI 182,780/kg respectively.

To investigate the effect of repeated treatments with the long-acting formulation of ICI 182,780, animals treated continuously with OB were given three i.m. injections of 4 mg ICI 182,780/kg at 28-day intervals. Uterine volumes were measured on the first day of treatment, 14 days later, and at weekly intervals thereafter (Text-fig. 4a). Endometrial growth was suppressed completely for 2 weeks after the first injection but recovered fully to oestrogen control levels by 4 weeks. A second injection of ICI 182,780 led to a rapid involution of the endometrium for 14 days followed by a slow recovery from antioestrogen blockade which was incomplete, reaching only 50% of oestrogen control immediately preceding the third injection of ICI 182,780. After the third injection, ICI 182,780 again caused endometrial involution and antiuterotrophic activity was sustained for between 4



TEXT-FIGURE 1. Prescribed presentation of the uterus in the oblique image set. The slice width is automatically adjusted to accommodate variations in the length of the uterus.

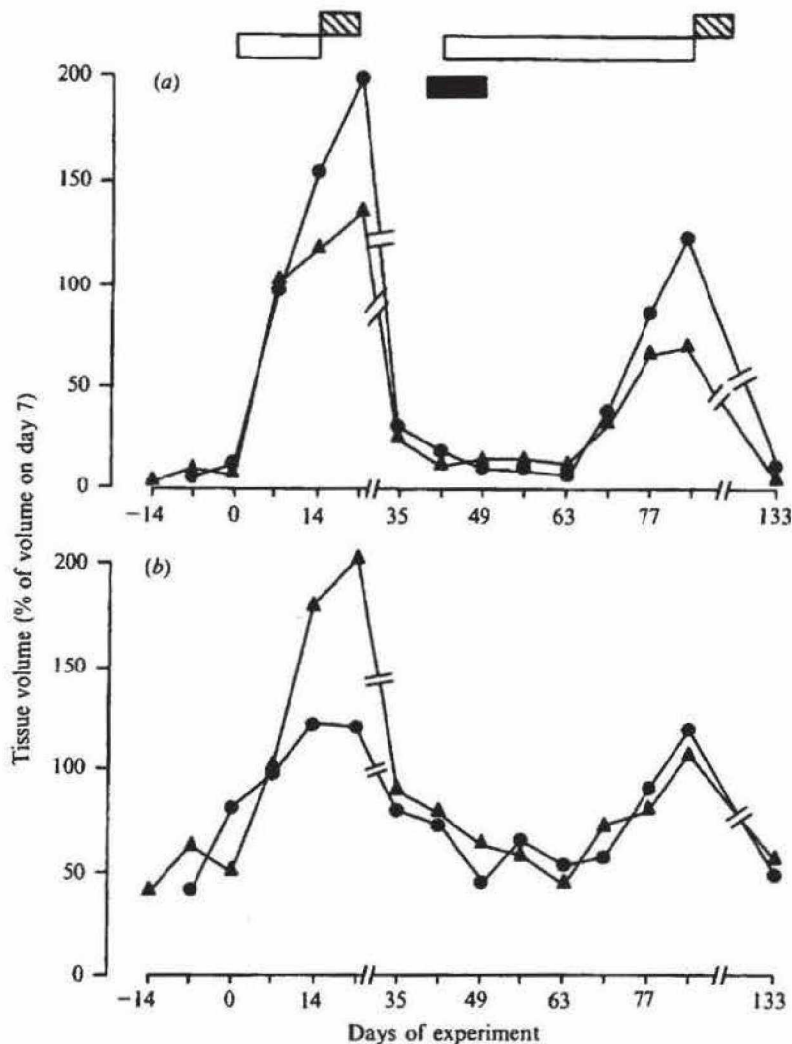
and 5 weeks. The volume of the myometrium varied significantly less than that of the endometrium during the course of this experiment (cf. Text-fig. 4a and b) and myometrial growth was blocked completely from the first dose of ICI 182,780 to the end of the experiment.

The gradual recovery of uterine response to oestrogen after treatment with long-acting oil-depot formulations of ICI 182,780, was characteristic of a competitive reversible antioestrogenic action of ICI 182,780. This was investigated further using a propylene glycol formulation of ICI 182,780 which provides rapid release of ICI 182,780 *in vivo*. Ovariectomized monkeys were first treated for 14 days with OB alone to establish control oestrogen response by MRI of the uterus at 0, 7 and 14 days (Text-fig. 5). After hormone withdrawal, this treatment was repeated, but with the addition of daily i.m. injections of 0.1 or 1.0 mg ICI 182,780/kg for the first 7 days of the experimental period. Both doses were equally effective and the data presented in Text-fig. 5 demonstrate that blockade of oestrogen stimulation occurred only during the 7-day antioestrogen treatment period since, during the second week of (unopposed) oestrogen treatment, the growth of both endometrium and myometrium resumed at a rate similar to that in the control experiment.

Each of the studies described above employed concurrent treatment with OB and ICI 182,780 to block the onset of uterine growth. The capacity of ICI 182,780 to produce involution of the uterus in the oestrogen-treated monkey noted in the repeat dose study with the long-acting formulation was investigated further. Using a cross-over design, each of two animals was first treated with OB alone for 7 days and then received either continued treatment for a further 2 weeks with OB together with daily i.m. injections of 0.2 mg ICI 182,780/kg in propylene glycol solution or propylene glycol vehicle alone. Three weeks later the experiment was repeated but each animal was crossed-over to the alternative treatment protocol. The rate and extent of involution of both endometrium and myometrium during the period when animals received ICI 182,780 and OB were the same as those following oestrogen withdrawal (Text-fig. 6), as was the time of onset and duration of oestrogen-withdrawal bleeding.

DISCUSSION

An initial study (Text-fig. 2) employing a dosing regime similar to that described previously for the perineal swelling studies (Wakeling *et al.* 1991) served



TEXT-FIGURE 2. (a) Endometrium and (b) myometrium volumes in two ovariectomized monkeys treated once daily with oestradiol benzoate (OB) or OB together with ICI 182,780. Percentage values were calculated by reference to the volume of the endometrium and myometrium in each animal after the initial treatment with 5 μ g OB/kg s.c. alone for 7 days. Open bars (days 0-14 and days 42-83) represent once daily s.c. injection of 5 μ g OB/kg s.c. The closed bar indicates once daily treatment for 10 days with 1 mg ICI 182,780/kg s.c. in arachis oil suspension (days 39-48). Involution of the uterus was induced by withdrawal of OB and once daily treatment with 5 mg progesterone for 5 days (hatched bars, days 14-18 and days 83-87). Experiment days designated by reference to the first injection of OB (day 0).

to illustrate the utility of MRI to provide accurate sequential data on the changes in the primate uterus following hormone treatment. Repeated measurements of endometrium and myometrium volume in individual animals allowed each animal to act as its own control. The extensive series of studies reported

here was completed with only 15 animals using a non-invasive technique entirely analogous to those now available in the clinic.

ICI 182,780 treatment effects were calculated by reference to the volume of endometrium and myometrium recorded in control studies where each animal

Explore Litigation Insights

Docket Alarm provides insights to develop a more informed litigation strategy and the peace of mind of knowing you're on top of things.

Real-Time Litigation Alerts



Keep your litigation team up-to-date with **real-time alerts** and advanced team management tools built for the enterprise, all while greatly reducing PACER spend.

Our comprehensive service means we can handle Federal, State, and Administrative courts across the country.

Advanced Docket Research



With over 230 million records, Docket Alarm's cloud-native docket research platform finds what other services can't. Coverage includes Federal, State, plus PTAB, TTAB, ITC and NLRB decisions, all in one place.

Identify arguments that have been successful in the past with full text, pinpoint searching. Link to case law cited within any court document via Fastcase.

Analytics At Your Fingertips



Learn what happened the last time a particular judge, opposing counsel or company faced cases similar to yours.

Advanced out-of-the-box PTAB and TTAB analytics are always at your fingertips.

API

Docket Alarm offers a powerful API (application programming interface) to developers that want to integrate case filings into their apps.

LAW FIRMS

Build custom dashboards for your attorneys and clients with live data direct from the court.

Automate many repetitive legal tasks like conflict checks, document management, and marketing.

FINANCIAL INSTITUTIONS

Litigation and bankruptcy checks for companies and debtors.

E-DISCOVERY AND LEGAL VENDORS

Sync your system to PACER to automate legal marketing.