

HE. The effects of the drug were assessed clinically and by SEP recordings. The late components of cortical SEPs (peaks N3 and P3) appear to be highly sensitive indicators of cortical dysfunction in HE.¹⁸ The results indicate that flumazenil may improve the HE that complicates both acute and chronic liver failure. Flumazenil treatment was associated with improvement in neurological status in 60% of episodes of HE; with one exception improvement occurred within a few minutes to an hour of drug administration. The speed of these responses contrasts with the interval of several hours that is typically necessary before HE improves after conventional therapies. The response to flumazenil in benzodiazepine intoxication is also very rapid.¹⁹

The 60% improvement rate may even underestimate the potential efficacy of flumazenil in the treatment of HE since most of the patients in this study had been encephalopathic for many days before flumazenil treatment and had not responded to conventional therapy. Furthermore all 5 patients with clinical evidence of increased intracranial pressure due to brain oedema did not respond to flumazenil. 1 of these patients improved after treatment with mannitol. The remaining 4 died within 3 days of flumazenil administration.

In 8 of the 12 episodes reponding to flumazenil there was an exacerbation of HE 0.5–4 h after stopping treatment. This transient effect of the drug is consistent with its pharmacokinetics.^{20,21} To achieve a sustained response continuous administration of the drug over longer periods may be necessary. Although these 12 episodes improved, no patient regained normal brain function at the end of treatment. The possibility that larger doses or a longer duration of treatment would have achieved complete improvement seems unlikely since, in benzodiazepine intoxication, much lower doses are sufficient for recovery.¹⁸ In addition an increased GABA-ergic tone may be only one of many abnormalities of brain function in patients with liver failure and correction of this particular abnormality may therefore induce incomplete improvement.

The mechanism by which flumazenil improves HE is uncertain. One possibility is displacement of an endogenous benzodiazepine-like substance from the GABA_A-benzodiazepine receptor. The presence of such a substance was suggested in the brains of animals with HE and in cerebrospinal fluid of patients dying with HE.²²

This study was supported by the Fonds zur Förderung der wissenschaftlichen Forschung (P 6169 M). Flumazenil was provided by Hoffmann-La Roche, Basel, Switzerland.

Correspondence should be addressed to G. G., 1st Department of Medicine, University of Vienna, A-1090 Vienna, Austria.

REFERENCES

- Schafer DF, Pappas SC, Brady LE, Jacobs R, Jones EA. Visual evoked potentials in a rabbit model of hepatic encephalopathy I: sequential changes and comparisons with drug induced comas. *Gastroenterology* 1984; **86**: 540–45.
- Basile AS, Gammal SH, Mullen KD, Jones EA, Skolnick P. Differential responsiveness of cerebellar Purkinje neurons to GABA and benzodiazepine receptor ligands in an animal model of hepatic encephalopathy. *J Neurosci* 1988; **8**: 2414–21.
- Schafer DF, Jones EA. Hepatic encephalopathy and the γ -aminobutyric-acid neurotransmitter system. *Lancet* 1982; **ii**: 18–20.
- Paul SM, Marangos PJ, Skolnick P. The benzodiazepine-GABA-chloride ionophore receptor complex: common site of minor tranquilizer action. *Biol Psych* 1981; **16**: 213–29.

References continued at foot of next column

REMISSION INDUCTION IN NON-HODGKIN LYMPHOMA WITH RESHAPED HUMAN MONOCLONAL ANTIBODY CAMPATH-1H

G. HALE¹
M. R. CLARK¹
R. MARCUS²
G. WINTER³

M. J. S. DYER²
J. M. PHILLIPS¹
L. RIECHMANN³
H. WALDMANN¹

Departments of Pathology¹ and Haematology,² University of Cambridge, and Laboratory of Molecular Biology,³ Cambridge

Summary A genetically reshaped human IgG1 monoclonal antibody (CAMPATH-1H) was used to treat two patients with non-Hodgkin lymphoma. Doses of 1–20 mg daily were given intravenously for up to 43 days. In both patients lymphoma cells were cleared from the blood and bone marrow and splenomegaly resolved. One patient had lymphadenopathy which also resolved. These effects were achieved without myelosuppression, and normal haemopoiesis was restored during the course of treatment, partially in one patient and completely in the other. No antiglobulin response was detected in either patient. CAMPATH-1H is a potent lympholytic antibody which might have an important use in the treatment of lymphoproliferative disorders and additionally as an immunosuppressive agent.

G. GRIMM AND OTHERS: REFERENCES—continued

- Baraldi M, Zeneroli ML, Ventura E, et al. Supersensitivity of benzodiazepine receptors in hepatic encephalopathy due to fulminant hepatic failure in the rat: reversal by a benzodiazepine antagonist. *Clin Sci* 1984; **67**: 167–75.
- Bassett ML, Mullen KD, Skolnick P, et al. Amelioration of hepatic encephalopathy by pharmacologic antagonism of the GABA_A-benzodiazepine receptor complex in a rabbit model of fulminant hepatic failure. *Gastroenterology* 1987; **93**: 1069–77.
- Bansky G, Meier PJ, Ziegler WH, Walser H, Schmid M, Huber M. Reversal of hepatic coma by benzodiazepine antagonist (Ro 15-1788). *Lancet* 1985; **i**: 1324–25.
- Bansky G, Meier PJ, Riederer E, et al. Effect of a benzodiazepine antagonist in hepatic encephalopathy in man. *Hepatology* 1987; **7**: 1103.
- Scollo-Lavizzari G, Steinmann E. Reversal of hepatic coma by benzodiazepine antagonist (Ro 15-1788). *Lancet* 1985; **i**: 1324.
- Burke DA, Mitchell KW, Al Mardini H, Record CO. Reversal of hepatic coma with flumazenil with improvement in visual evoked potentials. *Lancet* 1988; **ii**: 505–06.
- Sutherland LR, Minuk GY. Ro 15-1788 and hepatic failure. *Ann Intern Med* 1988; **108**: 158.
- Grimm G, Lenz K, Kleinberger G, et al. Ro 15-1788 improves coma in 4 out of 5 patients with fulminant hepatic failure: verification by long latency auditory and somatosensory potentials. *J Hepatol* 1987; **4** (suppl 1): S21.
- Meier R, Gyr K. Treatment of hepatic encephalopathy (HE) with the benzodiazepine antagonist flumazenil: a pilot study. *Eur J Anaesthesiol* 1988; suppl 2: 139–46.
- Teasdale G, Jennett B. Assessment of coma and impaired consciousness: a practical scale. *Lancet* 1974; **ii**: 81–84.
- Conn HO, Lieberthal M. The hepatic coma syndromes and lactulose. Baltimore: Williams & Wilkins, 1979: 6.
- Cracco RQ, Bodis-Wolner I, eds. Frontiers of clinical neuroscience Vol 3: evoked potentials. New York: Alan R. Liss, 1986.
- Jasper HH. The ten/twenty electrode system of the International Federation. *Electroencephalogr Clin Neurophysiol* 1958; **10**: 371–75.
- Chu NS, Yang SS. Portal-systemic encephalopathy: alterations in somatosensory and brainstem auditory evoked potentials. *J Neurol Sci* 1988; **84**: 41–50.
- Prischl F, Donner A, Grimm G, et al. Value of flumazenil in benzodiazepine self-poisoning. *Med Toxicol* 1988; **3**: 334–39.
- Lister R, Greenblatt D, Abernathy D, et al. Pharmacokinetic studies on RO 15-1788, a benzodiazepine receptor ligand, in the brain of rat. *Bran Res* 1984; **290**: 183–86.
- Roncardi G, Ziegler WH, Guentert TW. Pharmacokinetics of the new benzodiazepine antagonist Ro 15-1788 in man following intravenous and oral administration. *Br J Clin Pharmacol* 1986; **22**: 421–28.
- Mullen KD, Martin JV, Mendelson WB, et al. Could an endogenous benzodiazepine ligand contribute to hepatic encephalopathy? *Lancet* 1988; **i**: 457–59.

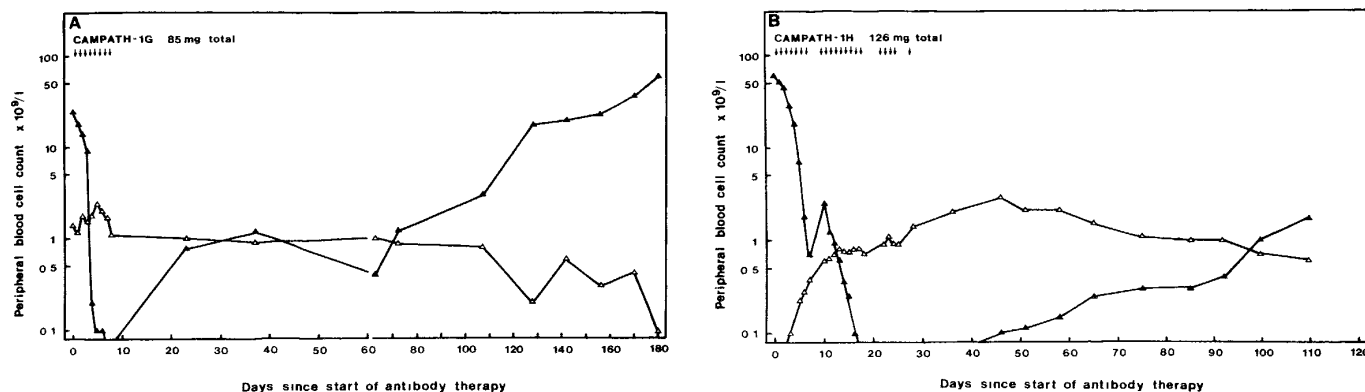


Fig 1—Effect of CAMPATH-1G (A) and CAMPATH-1H (B) on blood counts in patient 1.

▲ = lymphocytes; △ = neutrophils.

INTRODUCTION

TUMOUR treatment by passive serotherapy has had a long and largely unsuccessful history.¹ The advent of monoclonal antibodies gave fresh impetus to this approach, but results with unmodified antibodies are generally unremarkable. Efforts to enhance activity *in vivo* are now largely focused on the conjugation of antibodies to toxins or radionuclides. However, we are convinced that physiological effector mechanisms are still among the most potent and have tried to find the optimum combinations of antibody specificity and isotype to exploit them fully.

One possible specificity is the CAMPATH-1 antigen.² It does not readily undergo modulation and is abundantly expressed on virtually all lymphoid cells and monocytes, but not on other cell types.^{2,3} These properties make it a potential target for treatment of lymphoid malignant disorders and for immunosuppression. Several rat IgM and IgG antibodies to this antigen have been produced.^{4,5} The IgM (CAMPATH-1M) is intensely lytic with human complement and is widely used for depletion of T cells from bone marrow to prevent graft-versus-host disease.^{6,7} The IgG2b (CAMPATH-1G) is the most potent for cell depletion *in vivo*,⁸ probably because it binds to human Fc receptors and can activate the complement system.⁵ Patients with lymphoid malignant disorders treated with CAMPATH-1G (25–50 mg/day for 10 days) showed pronounced reduction in lymphoid infiltration of blood and bone marrow and improvement of splenomegaly.⁸ However, treatment with rat antibody is likely to be limited by an antiglobulin response. This problem should be reduced or eliminated by use of a human antibody. A reshaped human antibody (CAMPATH-1H) has been constructed—the hypervariable regions of the rat antibody were transplanted into normal human immunoglobulin genes.⁹ Human IgG1 was chosen since it had greater activity than other human isotypes both in complement lysis and in cell-mediated killing.^{9–11}

Here we describe the use of CAMPATH-1H to treat two patients with non-Hodgkin lymphoma. Although it was possible to continue treatment for up to 6 weeks without the development of a neutralising antiglobulin response, the main point of this report is to describe the efficacy of the antibody in clearing large masses of tumour cells. This is the first report of treatment with a fully reshaped human monoclonal antibody.

PATIENTS AND METHODS

Approval for the use of monoclonal antibodies was given by the ethical committee of Addenbrooke's Hospital and written consent was obtained from both patients.

Antibodies were obtained from culture supernatant of cells growing in a hollow fibre bioreactor ('Acusyst-Jr', Endotronics). CAMPATH-1G was purified by precipitation with ammonium sulphate; CAMPATH-1H was purified by affinity chromatography on protein-A-'Sepharose'. They were dissolved in phosphate-buffered saline, sterile filtered, and tested for pyrogen and sterility. Patients were prehydrated overnight and antibody, diluted in 500 ml saline, was infused over 2–4 h.

CAMPATH-1 expression on tumour cells was measured by flow cytometry and complement-mediated lysis.^{2,3,8} Serum concentrations of CAMPATH-1H were measured by immunofluorescence with normal lymphocytes.⁸ Southern blot analysis with an immunoglobulin J_H probe was used to detect residual tumour cells in DNA extracted from mononuclear fractions of bone marrow.⁸ Antiglobulin responses were sought by two techniques. The first was a solid-phase enzyme-linked assay using microtitre plates coated with CAMPATH-1H. After incubation with patients' serum samples, the assay was developed with biotin-labelled CAMPATH-1H followed by streptavidin-peroxidase. A mixture of monoclonal mouse antibodies against human IgG was used as a positive control and 500 ng/ml of this mixture could be detected. In the second assay, patients' serum samples were mixed with red cells coupled with CAMPATH-1H.¹² Agglutination by 5 ng/ml of the control mixture could be detected. Immunoglobulin allotypes were determined by means of standard reagents and techniques from the Central Laboratory of the Netherlands Red Cross blood transfusion service.

RESULTS

Patient 1

A 69-year-old woman presented in 1983 with acute appendicitis. Massive splenomegaly was found (table) and the bone marrow was heavily infiltrated with lymphocytes, some of which had clefted nuclei and a single nucleolus. There was weak membrane expression of IgM-kappa. Computed tomography scan showed splenomegaly but no lymphadenopathy. Grade I, stage IVA non-Hodgkin lymphoma in leukaemic phase was diagnosed. Between 1983 and 1987 the patient received oral and intravenous chemotherapy with combinations of cyclophosphamide, vincristine, prednisolone, and chlorambucil, which induced partial responses, the minimum level of marrow infiltration being 40%. Two courses of splenic radiotherapy were given,

in blood lymphocytes (24×10^6 cells/l) and spleen size. The patient was treated with CAMPATH-1G for 8 days (fig 1A). This treatment completely cleared lymphoma cells from blood and marrow but only partially reduced spleen size. CAMPATH-1G induced fever, nausea, and vomiting, and the treatment was stopped on day 8 when it resulted in severe bronchospasm. (Such severe reactions have not been seen in twenty-one other patients who have received similar doses.) Reappearance of lymphoma cells in the blood was initially slow and the spleen size did not change for 5 months but there was little recovery of normal haemopoiesis. In March 1988 the patient began to lose weight and experienced drenching night sweats. The spleen enlarged and lymphoma cells reaccumulated in the blood. They had similar phenotype and identical rearranged immunoglobulin J_H fragments to those seen before treatment. Marrow aspirate and trephine showed complete replacement of normal marrow by lymphoma cells (fig 2A); the patient became dependent on red-cell transfusions and was absolutely neutropenic.

The patient's serum did not block binding of CAMPATH-1H or CAMPATH-1G to normal lymphocytes and the tumour cells were still sensitive to these antibodies in vitro, so we decided to treat her with CAMPATH-1H. The starting dose was 1 mg daily and, since it was well tolerated, the dose was increased to a maximum of 20 mg/day, though the usual dose was 4 mg/day owing to the small amount available. In all the patient received 126 mg over 30 days. The response was prompt; in 6 days the night sweats had abated, by day 10 there was pronounced reduction in splenomegaly and recovery of blood neutrophils, and by day 18 lymphoma cells were cleared from the blood (fig 1B). On day 28 a bone marrow aspirate and trephine were hypocellular but showed active myelopoiesis and erythropoiesis and no lymphoid cells (fig 2B). No CAMPATH-1-positive cells could be detected by flow cytometry. DNA from the mononuclear marrow cells was germline when probed with an immunoglobulin J_H probe under conditions where clonal rearrangements could be detected in 0.2% of cells. Thus, we conclude that lymphoma cells were cleared from the marrow. The spleen volume was reduced about eight-fold (fig 3A, B), although it was still slightly larger than normal.

Other than fever occurring about 1 h after the end of antibody infusions there were no adverse effects of antibody treatment until the 5th week, when severe rigors occurred after each infusion. No antiglobulin response could be detected and the rate of clearance of antibody from the serum was unchanged. For the next 3 weeks the patient continued to experience occasional fever and rigors. She was given oral cotrimoxazole because of her lymphopenia, but no infective cause of these symptoms could be found.

In the next 4 months lymphocytes, which appeared morphologically normal, slowly reappeared in the blood (up to $0.2 \times 10^9/l$). They did not show the characteristic rearranged immunoglobulin fragments, and both CD3-positive and CD19-positive cells were present (table). Serum immunoglobulin levels, which had been very low since presentation, have risen towards normal (table). A marrow aspirate and trephine taken 50 days after the end of treatment were again hypocellular but had no lymphomatous infiltration. This marrow sample contained

	Before	After*	Before	After*
Spleen size (ml)†	4460	590	2600	440
Lymphadenopathy†	None	None	Retrocrural; paraortic	None
Bone marrow				
% lymphoma cells	99	0	72	0
Southern blot analysis				
Ig J_H fragment	R/R	G/G	R/R	G/G
Peripheral blood				
Haemoglobin (g/dl)	8.7	10.6	11.2	12.0
Reticulocytes ($\times 10^9/l$)	31	135	ND	ND
Platelets ($\times 10^9/l$)	37	50	110	453
Lymphocytes ($\times 10^9/l$)	60	0	37	0
Neutrophils ($\times 10^9/l$)	0	2.0	4.6	7.3
Monocytes ($\times 10^9/l$)	0	0.04	1.5	0.5
Blood lymphocyte phenotype (%)				
CD19	97	46	93	<5
CD3	0	32	8	80
CAMPATH-1M	96	ND	95	ND
CAMPATH-1H	98	ND	97	ND
Serum immunoglobulins (g/l)				
IgM	<0.3	1.2	<0.3	0.7
IgA	<0.5	<0.5	<0.5	0.5
IgG	5.8	8.2	3.2	4.7
Bence-Jones	None	None	++	None

*Made shortly after end of antibody treatment, except for lymphocyte phenotyping and serum immunoglobulins, which were assessed 6 weeks later.

†By computed tomography.

ND = not done.

4% CAMPATH-1-positive cells and showed some oligoclonal rearrangements of immunoglobulin genes. However, by day 100, lymphoma cells were again detected in the blood and the spleen size had started to increase. A second course of 12 days' therapy with CAMPATH-1H was completed with similar therapeutic benefit to the first and no adverse effects. Since the main reservoir of disease in this patient appeared to be the spleen, splenectomy was carried out at the end of this second course of treatment. At that time no tumour cells could be detected in blood or marrow. The patient is now well 37 days after the splenectomy. The lymphocyte count is low but she has normal neutrophil, platelet, and red-cell counts.

Patient 2

A 67-year-old man presented in April 1988 with splenic pain; there was 12 cm splenomegaly, and computed tomography scan of thorax and abdomen revealed retrocrural and para-aortic lymphadenopathy, the largest node measuring 3 cm in diameter (fig 3C). A blood count revealed 36.6×10^9 lymphocytes/ml, the majority being lymphoplasmacytoid cells which expressed surface IgG-kappa and were characterised by large cytoplasmic periodic-acid-Schiff-positive vacuoles which could be intensely stained by anti-IgG. A marrow aspirate contained 72% lymphomatous cells (fig 2C). DNA from blood mononuclear cells showed biallelic rearrangement of immunoglobulin J_H genes but was germline with various T-cell receptor and oncogene probes. The lymphoma cells expressed the CAMPATH-1 antigen in amounts comparable with normal lymphocytes but were more resistant to complement-mediated lysis. Stage IVA grade I

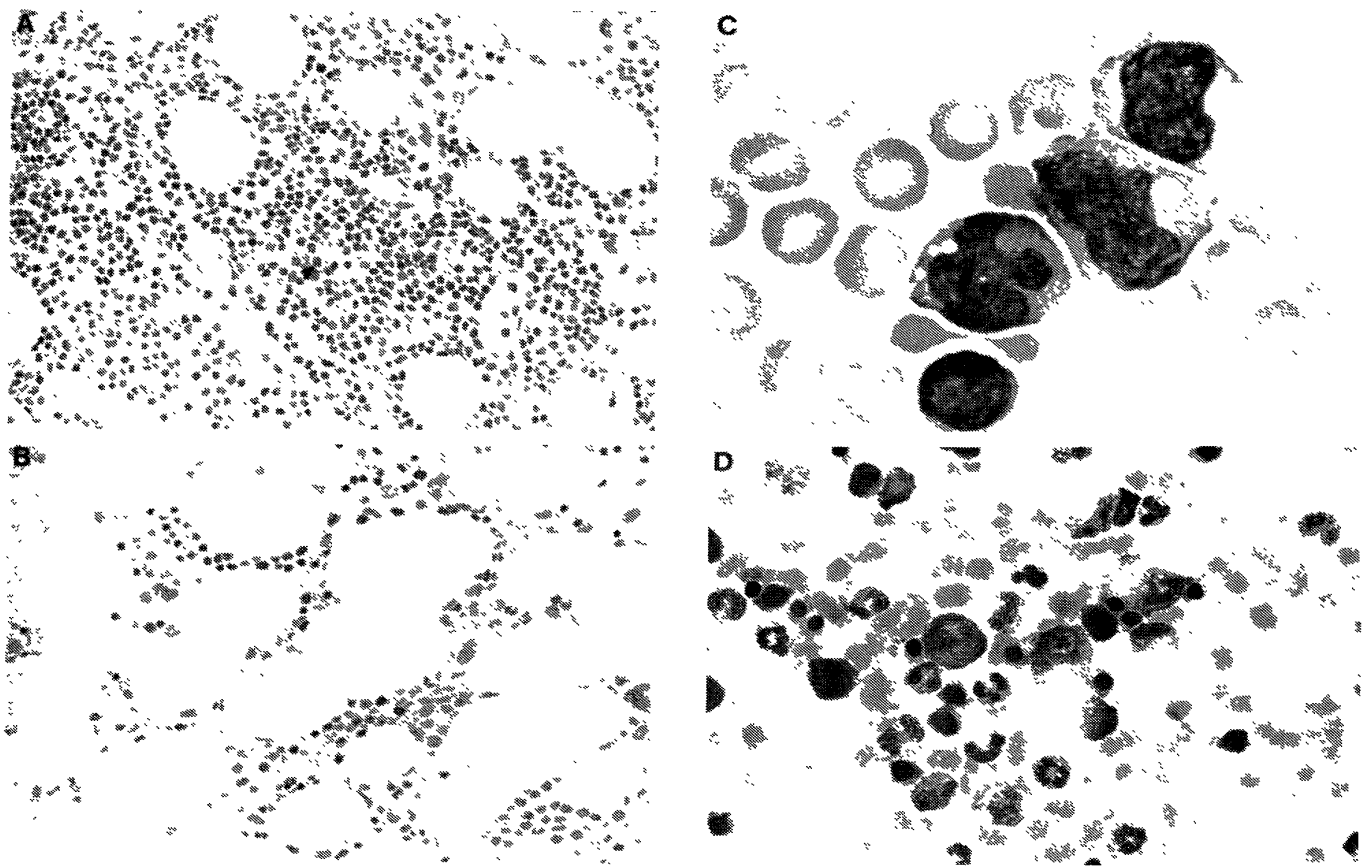


Fig 2—Cytology of bone marrow cells.

A = patient 1 trephine before treatment with CAMPATH-1H; B = patient 1 trephine on day 43 (ie, 16 days after treatment); C = patient 2 aspirate before treatment with CAMPATH-1H; D = patient 2 aspirate on day 78 (ie, 35 days after treatment). Reduced by 58% from $\times 100$ (A,B), $\times 1000$ (C), $\times 400$ (D).

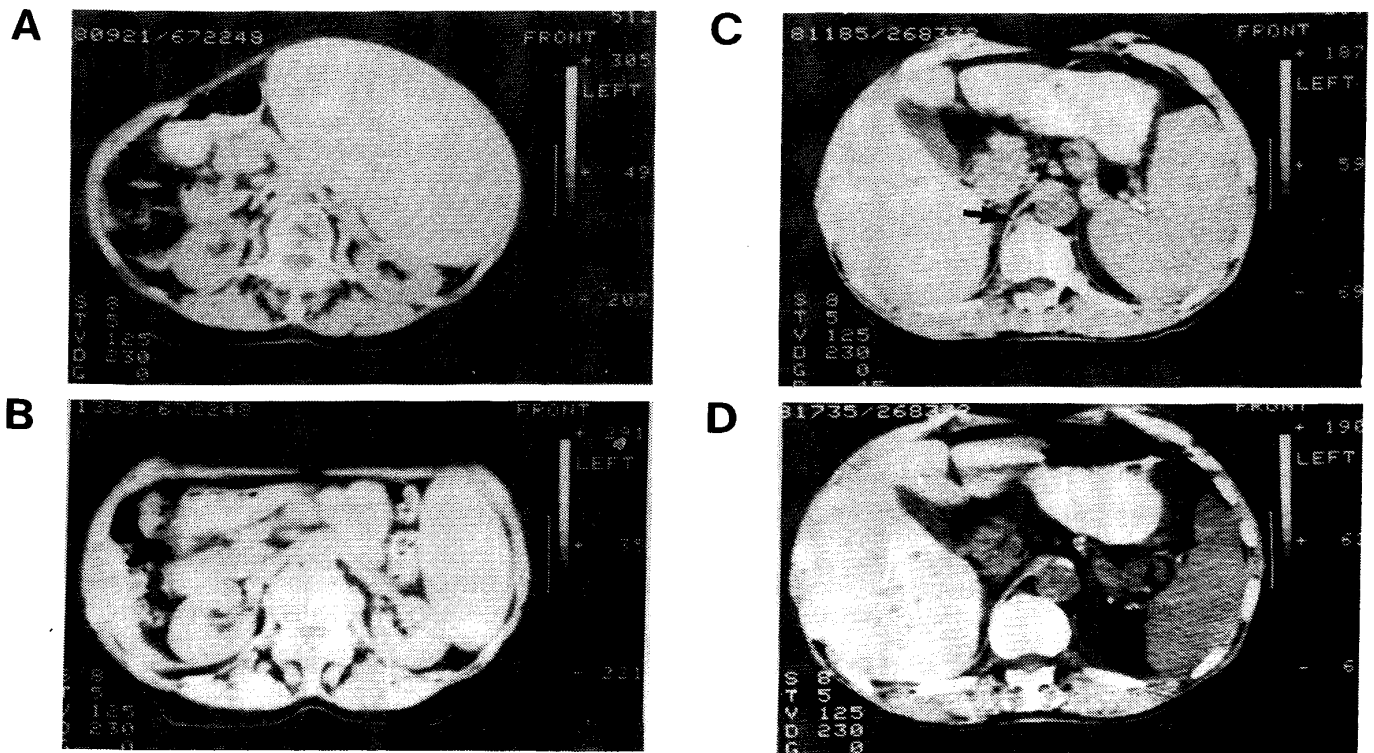


Fig 3—Computed tomography scans showing affected spleens and lymphnode.

A = patient 1 before treatment with CAMPATH-1H; B = patient 1 on day 57; C = patient 2 before treatment with CAMPATH-1H (retrocrural node arrowed); D = patient 2 on day 51.

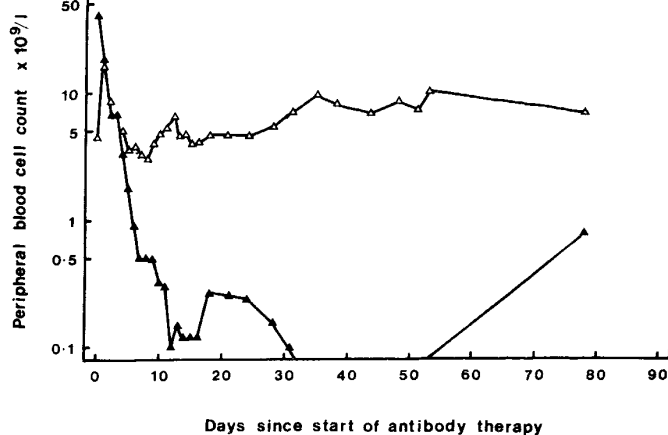


Fig 4—Effect of CAMPATH-1H on blood counts in patient 2.

▲ = lymphocytes; △ = neutrophils.

lymphoplasmacytoid non-Hodgkin lymphoma was diagnosed.

The patient was offered CAMPATH-1H as primary therapy and received a total of 85 mg over 43 days. This resulted in clearance of the lymphoma cells and normal lymphocytes from blood (fig 4) and marrow (fig 2D), resolution of splenomegaly, and improvement in the lymphadenopathy. A computed tomography scan taken 8 days after the end of antibody treatment was normal (fig 3D). A bone marrow aspirate taken at the same time showed active haemopoiesis but no lymphoma cells, and no CAMPATH-1-positive cells could be detected by flow cytometry. DNA from the mononuclear fraction of this marrow showed only germline configuration when probed with the immunoglobulin J_H probe. By day 78 morphologically normal blood lymphocytes began to reappear and none of the vacuolated cells could be seen. The patient remains well and off therapy.

Some toxic effects of CAMPATH-1H were observed. The first dose was stopped after 3 mg had been given because of hypotension, possibly caused by tumour lysis. This problem was subsequently avoided by giving smaller doses at a slower rate and when lymphoma cells had been cleared from the blood, the dose was increased to a maximum of 8 mg over 4 h without any effect on blood pressure. Nevertheless, all doses induced fever (up to 38.5°C), and malaise for up to 36 h, but these were not severe enough to stop antibody treatment which, after the first week, was given on an outpatient basis. Treatment was stopped after 43 days because of the development of an urticarial rash after two successive antibody infusions.

Half-life of CAMPATH-1H

The concentration of CAMPATH-1H was measured in serum samples taken before and after antibody infusions and at other times throughout treatment. In theory, a dose of 4–6 mg corresponds to about 1 µg/ml in the plasma. In fact we could not detect free antibody till day 4–6, presumably because of rapid uptake by the tumour mass. After that, the rate of clearance was roughly constant, with the concentration being about 30–70% of the theoretical level

Lack of Antiglobulin Response

The allotype of CAMPATH-1H is G1m(1,2,17),Km(3). Patient 1 was G1m(1,3,17),Km(3) and patient 2 was G1m(3),Km(3), so both could theoretically have made an anti-allotype response as well as a response to the hypervariable regions. However, we failed to detect any antiglobulin to CAMPATH-1H either by the solid-phase enzyme-linked assay or by the more sensitive haemagglutination assay. In addition, the rate of clearance of CAMPATH-1H did not change and free antibody could be detected for up to 8 days after the last dose had been given. It is possible that the reactions experienced at the end of the course of treatment could have been provoked by contaminating non-human proteins in the antibody preparation.

DISCUSSION

The remissions achieved in these two patients show that it is possible to clear large numbers of tumour cells with small amounts of an unmodified monoclonal antibody. The effects in the first patient were far superior to the results of previous chemotherapy and radiotherapy. The selective lysis of lymphoma cells with recovery of normal haemopoiesis during the course of treatment was an important advantage, which allowed treatment to be given largely on an outpatient basis. We believe the choice of antibody specificity and isotype is important; indeed, it may be why we had more success than previous efforts with other monoclonal antibodies.^{14–16} The CAMPATH-1 antigen seems to be a good target because it is widely distributed and abundant, and does not suffer from antigenic modulation.^{2,3,8,17} This study shows that, as predicted, human IgG1 can bring about cell lysis in vivo, though we cannot yet assess the relative importance of humoral or cellular mechanisms. There was no change in serum complement levels (CH50, C3, or C4 components) during antibody treatment (data not shown), but this does not exclude a role for C3 in cell clearance.

Although the two patients did not make any serologically detectable antiglobulin response, it would be premature to draw general conclusions about the immunogenicity of human monoclonal antibodies, since CAMPATH-1H itself is probably immunosuppressive and the patients were already immunosuppressed as a result of their disease. Nevertheless, it was encouraging that two courses of antibody treatment could be given, even in the patient who had previously had unusually severe reactions to the original rat antibody.

The long-term benefit of treatment with CAMPATH-1H can only be assessed in a much larger trial when it would probably be combined with more conventional chemotherapy and radiotherapy. It may have wider applications as an immunosuppressive agent for transplantation and possibly autoimmune disease, since we already know that the rat antibody CAMPATH-1G is a potent immunosuppressant in the short-term.

We thank the patients and families, nursing staff, medical colleagues, and Prof F. G. J. Hayhoe for their cooperation, encouragement and support; and Dr D. Gilmore, Dr H. S. Kruger-Gray, Prof R. R. A. Coombs, Mark

Explore Litigation Insights

Docket Alarm provides insights to develop a more informed litigation strategy and the peace of mind of knowing you're on top of things.

Real-Time Litigation Alerts



Keep your litigation team up-to-date with **real-time alerts** and advanced team management tools built for the enterprise, all while greatly reducing PACER spend.

Our comprehensive service means we can handle Federal, State, and Administrative courts across the country.

Advanced Docket Research



With over 230 million records, Docket Alarm's cloud-native docket research platform finds what other services can't. Coverage includes Federal, State, plus PTAB, TTAB, ITC and NLRB decisions, all in one place.

Identify arguments that have been successful in the past with full text, pinpoint searching. Link to case law cited within any court document via Fastcase.

Analytics At Your Fingertips



Learn what happened the last time a particular judge, opposing counsel or company faced cases similar to yours.

Advanced out-of-the-box PTAB and TTAB analytics are always at your fingertips.

API

Docket Alarm offers a powerful API (application programming interface) to developers that want to integrate case filings into their apps.

LAW FIRMS

Build custom dashboards for your attorneys and clients with live data direct from the court.

Automate many repetitive legal tasks like conflict checks, document management, and marketing.

FINANCIAL INSTITUTIONS

Litigation and bankruptcy checks for companies and debtors.

E-DISCOVERY AND LEGAL VENDORS

Sync your system to PACER to automate legal marketing.