

BIOLOGICAL SCIENCES LIBRARY

ISSN 0041-1337
TRPLAU

VOLUME 32 • NUMBER 6, DECEMBER 1981

Transplantation®

OFFICIAL JOURNAL OF THE TRANSPLANTATION SOCIETY

LIBRARY
FEB 18 1982
UNIVERSITY OF
WASHINGTON

SEVENTH ANNUAL MEETING OF THE AMERICAN SOCIETY OF
TRANSPLANT SURGEONS
CHICAGO, ILLINOIS
JUNE 5 to 7, 1981

HEALTH SCIENCES

OVERVIEW

Presidential address: role of kidney transplantation and its implementation. J. CERILLI 459

EXPERIMENTAL TRANSPLANTATION

Survival of primates following orthotopic cardiac transplantation treated with total lymphoid irradiation and chemical immune suppression. J. L. PENNOCK, B. A. REITZ, C. P. BIEBER, S. AZIZ, P. E. OYER, S. STROBER, R. HOPPE, H. S. KAPLAN, E. B. STINSON, AND N. E. SHUMWAY 467

Cyclosporin A in experimental lung transplantation. F. J. VEITH, A. J. NORIN, C. M. MONTEFUSCO, K. L. PINSKER, S. L. KAMHOLZ, M. L. GLIEDMAN, AND E. EMESON 474

CLINICAL TRANSPLANTATION

In situ cadaver kidney perfusion. Experimental and clinical studies. R. T. SCHWEIZER, B. A. SUTPHIN, AND S. A. BARTUS 482

Human kidney preservation by intracellular electrolyte flush followed by cold storage for over 24 hours. J. M. BARRY, S. LIEBERMAN, C. WICKRE, C. LIEBERMAN, S. FISCHER, AND D. CRAIG. 485

Cyclosporin A hepatotoxicity in 66 renal allograft recipients. G. B. G. KLINTMALM, S. IWATSUKI, AND T. E. STARZL 488

Method of preservation is not a determinant of graft outcome in kidneys transplanted by Southeastern Organ Procurement Foundation Institutions. W. K. VAUGHN, G. MENDEZ-PICON, A. L. HUMPHRIES, AND E. K. SPEES 490

Clinical significance of antimonocyte antibody in kidney transplant recipients. G. J. CERILLI, L. BRASILE, T. GALOUZIS, AND M. E. DEFRANCIS 495

Continued on cover 3

PUBLISHED BY THE WILLIAMS & WILKINS CO. BALTIMORE 21202, U.S.A.



**DOCKET
ALARM**

Find authenticated court documents without watermarks at docketalarm.com.

Transplantation®

OFFICIAL JOURNAL OF THE TRANSPLANTATION SOCIETY

EDITORS:

J. R. BATCHELOR
London, England

E. J. EICHWALD
Salt Lake City, Utah

ANTHONY P. MONACO
Boston, Massachusetts

PETER J. MORRIS
Oxford, England

DAVID STEINMULLER
Rochester, Minnesota

MARY L. WOOD
Boston, Massachusetts

NORTH AMERICAN EDITORIAL OFFICE:

*New England Deaconess Hospital
185 Pilgrim Road
Boston, Massachusetts 02215*

EUROPEAN EDITORIAL OFFICE:

*Department of Immunology
Royal Postgraduate Medical School
Hammersmith Hospital
Ducane Road
London W12, England*

EDITORIAL BOARD:

Class of 1982

D. B. AMOS, *Durham, North Carolina*
F. O. BELZER, *Madison, Wisconsin*
R. E. BILLINGHAM, *Dallas, Texas*
L. BRENT, *London, England*
J. CROSNIER, *Paris, France*
R. EPSTEIN, *Chicago, Illinois*
J. FABRE, *Oxford, England*
C. G. FATHMAN, *Stanford, California*
B. S. HANDWERGER, *Rochester, Minnesota*
C. S. HENNEY, *Seattle, Washington*
J. HOWARD, *Cambridge, England*

G. JANOSSY, *London, England*
M. JEANNET, *Geneva, Switzerland*
M. L. KRIPKE, *Frederick, Maryland*
J. A. MYBURGH, *Johannesburg, South Africa*
G. SANTOS, *Baltimore, Maryland*
J. W. STREILEIN, *Dallas, Texas*
P. TERASAKI, *Los Angeles, California*
N. L. TILNEY, *Boston, Massachusetts*
K. I. WELSH, *London, England*
G. M. WILLIAMS, *Baltimore, Maryland*
E. YUNIS, *Boston, Massachusetts*

Class of 1983

E. ALBERT, *Munich, Germany*
B. F. ARGYRIS, *Syracuse, New York*
H. BALNER, *Rijswijk, Netherlands*
C. F. BARKER, *Philadelphia, Pennsylvania*
P. R. F. BELL, *Leicester, England*
S. CHO, *Boston, Massachusetts*
R. A. DAYNES, *Salt Lake City, Utah*
B. DUPONT, *New York, New York*
J. FRELINGER, *Los Angeles, California*
T. C. FULLER, *Boston, Massachusetts*
N. GENGOZIAN, *Oak Ridge, Tennessee*
T. GILL, *Pittsburgh, Pennsylvania*

R. D. GUTTMANN, *Montreal, Quebec*
I. MCKENZIE, *Melbourne, Australia*
P. MCMASTER, *Cambridge, England*
G. OPELZ, *Los Angeles, California*
R. A. REISFELD, *La Jolla, California*
R. L. SIMMONS, *Minneapolis, Minnesota*
E. SIMPSON, *Harrow, England*
J. P. SOULILLOU, *Nantes, France*
N. A. STAINES, *London, England*
O. STUTMAN, *New York, New York*
D. SUTHERLAND, *Minneapolis, Minnesota*
J. THOMAS, *Greenville, North Carolina*

Class of 1984

M. BORTIN, *Milwaukee, Wisconsin*
R. CORRY, *Iowa City, Iowa*
A. B. COSIMI, *Boston, Massachusetts*
C. DAVID, *Rochester, Minnesota*
K. DICKE, *Houston, Texas*
W. L. FORD, *Manchester, England*
M. HARDY, *New York, New York*
W. HILDEMAN, *Los Angeles, California*
I. V. HUTCHINSON, *London, England*
C. JANEWAY, *New Haven, Connecticut*

D. W. MASON, *Oxford, England*
J. MILLER, *Miami, Florida*
J. ROSENBERG, *Detroit, Michigan*
D. SACHS, *Bethesda, Maryland*
R. STORB, *Seattle, Washington*
R. TAUB, *New York, New York*
E. THORSBY, *Oslo, Norway*
H. WAGNER, *Mainz, Germany*
T. WEGMANN, *Alberta, Canada*
D. WHITE, *Cambridge, England*

Transplantation (ISSN 0041-1337) is published monthly by Williams & Wilkins, 428 E. Preston Street, Baltimore, MD 21202. Second class postage paid at Baltimore, MD, and at additional mailing offices. Postmaster, send address changes (form 3579) to Williams & Wilkins, 428 E. Preston Street, Baltimore, MD 21202.

TREATMENT OF ACUTE RENAL ALLOGRAFT REJECTION WITH OKT3 MONOCLONAL ANTIBODY¹

A. BENEDICT COSIMI, ROBERT C. BURTON, ROBERT B. COLVIN, GIDEON GOLDSTEIN,
FRANCIS L. DELMONICO, MICHAEL P. LAQUAGLIA, NINA TOLKOFF-RUBIN, ROBERT H. RUBIN,
JOHN T. HERRIN, AND PAUL S. RUSSELL

Transplantation-Immunology Unit of General Surgical Services, Massachusetts General Hospital; Departments of Surgery, Pathology, Medicine, and Pediatrics, Harvard Medical School, Boston, Massachusetts; and Ortho Pharmaceutical Corporation, Raritan, New Jersey

Eight cadaver donor renal allograft recipients, who had received azathioprine and prednisone from the day of transplantation, were treated with OKT3 monoclonal antibody (reactive with all mature peripheral blood T cells) at the time of diagnosis of acute rejection. In all cases, loss of essentially all detectable peripheral blood OKT3-reactive cells was noted within minutes after the initial 1- to 5-mg i.v. infusion. Chills and fever invariably occurred following the first or second infusion of monoclonal antibody, but were not noted during the subsequent 10- to 20-day course of therapy, suggesting rapid cell lysis as the etiology of this toxicity.

The established rejection episode was reversed in all cases within 2 to 7 days without addition of any therapy other than OKT3 antibody and despite continued lowering of the steroid dosages. During the subsequent 3- to 12-month follow-up period, further rejection episodes occurred in five of these patients, two of these were irreversible with conventional therapy so that six of the eight allografts continue with excellent renal function.

These preliminary observations suggest that homogeneity, limited dosage requirements, and ease of *in vitro* monitoring of dosage effects should markedly simplify the use of monoclonal antibody to T cell populations in human allograft recipients. This second generation of antilymphocyte preparations offers the potential for not only increased effectiveness but also the possibility of manipulating specific T cell subsets.

Although some heterologous antisera to human lymphocytes have proved to be effective in delaying or reversing allograft rejection (1, 2), the preparation of these agents has been difficult using conventional immunization techniques. Even the purified IgG fraction from animals immunized with lymphocytes contains not only a heterogeneous group of antibodies to T lymphocytes, but also antibodies reactive with other normal cells as well as extraneous antibodies reflecting the animal's previous immunological activity (3). Therefore, techniques of developing more specific reagents have been sought.

Based upon the recent demonstration by Kohler and Milstein (4) that monoclonal antibody to a specific membrane determinant can be reliably produced using cell hybridization techniques, Kung et al. (5) have produced a panel of monoclonal antibodies specifically reactive with human lymphocyte subpopulations. A phylogenetic screen of these reagents in our

laboratory revealed significant cross-reactivity of some of them with lymphocytes of subhuman primates. In order to evaluate the possible clinical role of monoclonal antibody as an immunosuppressive agent, we previously investigated in cynomolgus renal allograft recipients the effects of OKT4 antibody (6). This antibody is reactive with human T cells having major helper/inducer and T-T collaborative functions (7, 8). By using flow cytometry for monitoring of peripheral blood lymphocytes, we defined the dosage and timing of OKT4 antibody administration required to provide *in vivo* coating of this specific T cell population now in 10 cynomolgus recipients. With a dosage range of 0.5 to 1.0 mg/kg/day, coating of all reactive cells was observed and residual circulating Ab was usually detectable 24 hr after administration. When OKT4 therapy was started before transplantation, allograft survival was extended to as long as 7 weeks after a 1- to 2-week course of therapy (control survival 8 to 11 days).

Encouraged by the effectiveness, ease of administration, and lack of toxicity in this *in vivo* model, we have begun a trial of monoclonal antibody therapy in human renal allograft recipients. Although the ultimate goal is to evaluate only selected T cell subset suppression, in order to expose the patients in this initial study to the least risk of ineffective immunosuppression, we have tested OKT3 antibody which is reactive with all mature human T cells (9, 10).

MATERIALS AND METHODS

Eight cadaver donor renal recipients, who had received azathioprine and prednisone from the time of transplantation, were treated with OKT3 monoclonal antibody at the time of diagnosis of acute rejection. Allograft rejection was suggested in these patients by deterioration in renal function and was confirmed in all patients by histopathological evaluation of tissue obtained by percutaneous needle biopsy.

In the attempt to identify the most effective and least toxic combination of conventional and OKT3 therapy, several dosage schedules were pursued. In the first two patients, azathioprine was administered in a dosage of 10 mg/kg on the day of transplantation and then maintained at 1 to 2 mg/kg/day unless the white blood count fell below 3000/mm³. Prednisone was begun at a daily dosage of 2 mg/kg. Beginning on the 5th postoperative day, the dosage was decreased by 10 mg/day to 0.8 mg/kg/day, after which the dosage was more slowly tapered to the maintenance dosage of 0.25 mg/kg/day. Following confirmation of the diagnosis of rejection, OKT3 antibody was administered by bolus i.v. injection in a total daily dosage of 1

¹ This work was supported by United States Public Health Service Grant HL/AM-18646 and by funds provided by the Ortho Pharmaceutical Corporation. Presented at the Seventh Annual Scientific Meeting

mg/kg/day during OKT3 therapy which was administered i.v. in a total daily dosage of 1 to 3 mg for 14 days. In the last four patients, the azathioprine and prednisone dosages were further reduced to 0.4 mg/kg/day during OKT3 therapy. In these patients OKT3 was administered daily for 14 to 20 days at a dosage of 4 to 5 mg/day (Fig. 1). After discontinuing OKT3 therapy, the azathioprine dosage was again increased to 1 to 2 mg/kg/day in the last six patients.

Prior to transplantation, during azathioprine and prednisone therapy, and at frequent intervals after institution of OKT3 antibody therapy, peripheral blood lymphocytes from buffy coat preparations were analyzed for OKT3-reactive cells using flow cytometry (11). Recipient serum was monitored by incubating sequentially diluted sera with normal human peripheral blood lymphocytes, followed by staining with fluoresceinated goat anti-mouse antibody, in order to detect and maintain a circulating level of OKT3 antibody. Effectiveness of therapy was judged by reversal of rejection defined as the day after which consistent improvement in renal function occurred. Percutaneous renal biopsies were performed on all patients after OKT3 therapy.

Toxicity was studied by daily monitoring of recipient complete blood count, blood urea nitrogen, and creatinine, weekly assays of hepatic function and urine protein excretion, and careful observation for any clinical evidence of serum sickness. Serial urine, salivary, and buffy coat specimens were cultured for viral activity as previously described (12).

RESULTS

The clinical course of a representative patient treated with OKT3 antibody is depicted in Figure 1. Following cadaver donor renal transplantation in this 41-year-old male, the serum creatinine level fell to normal levels by the 4th post-transplant day. Subsequently, the onset of rejection was suggested by the rising serum creatinine level which occurred in conjunction with decreased urinary output, weight gain, hypertension, and low-grade fever. Allograft biopsy confirmed the diagnosis on the 7th post-transplant day and the initial 5-mg dose of OKT3 antibody was infused i.v. after an i.d. skin challenge was observed to produce no reaction. Approximately 45 min later, an episode of shaking chills with fever to 101 C occurred. In addition, the patient complained of shortness of breath and diffuse wheezes were noted over the lung fields. These symptoms rapidly responded to acetaminophen and antihistamine therapy. The patient had no further chills, fever, or other adverse reactions with subsequent OKT3 infusions.

Sequential monitoring of peripheral blood lymphocytes was begun 15 min after the initial injection. As noted in Figure 1, there was essentially complete loss of OKT3-reactive cells from the peripheral circulation, a condition which persisted throughout the 14-day course of therapy. That this was not attributable to masking or modulation of OKT3 antigen was indicated by the failure of fluorescein conjugates of OKT4 and OKT8 monoclonal antibodies, which bind to other T cell antigens (11), to react with the residual cells. In addition, detectable antibody excess was present throughout the course of therapy during which a total dosage of 70 mg of OKT3 antibody was administered.

The serum creatinine level continued to rise for several days after institution of therapy but the patient's clinical condition rapidly improved with diuresis, weight loss, and improved con-

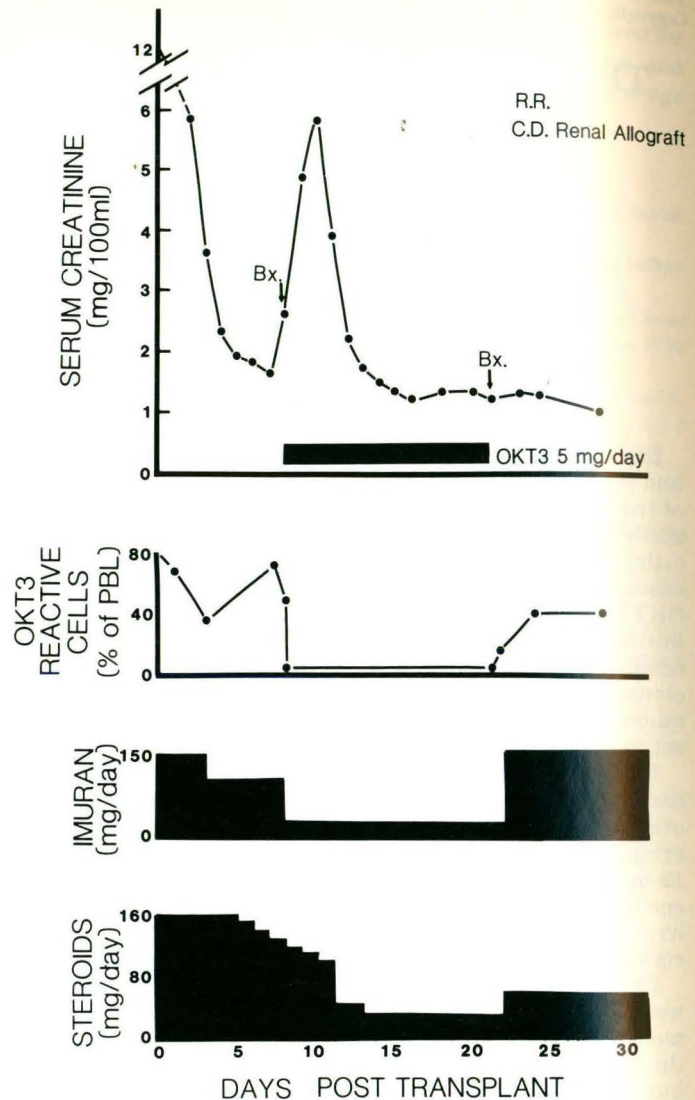


FIGURE 1. Clinical course of renal allograft recipient treated for acute rejection with OKT3 monoclonal antibody. A dramatic and sustained depletion of peripheral blood OKT3-reactive cells and return of normal renal function occurred despite rapid tapering of azathioprine and steroid dosages.

treatment. Continuous improvement in renal function began 72 hr after OKT3 treatment was initiated with the serum creatinine eventually stabilizing at 1.3 mg/100 ml. As depicted in Figure 1, the azathioprine and steroid dosages were rapidly tapered during this period. A second allograft biopsy performed on the last day of therapy showed essentially complete resolution of the histopathological findings of rejection (Fig. 2).

The initial results of treatment of the eight patients studied are summarized in Tables 1 and 2. In every instance, the rejection episode for which OKT3 therapy was instituted was reversed with steady improvement in allograft function beginning after 2 to 7 days of therapy. In the first three patients and the last patient treated, a subsequent rejection episode occurred beginning 2 to 6 weeks after cessation of OKT3 therapy while the patients were being maintained on azathioprine and prednisone. These episodes were easily reversed in three of these patients with increased steroids. The second rejection episode in patient 3, however, could not be reversed despite increased

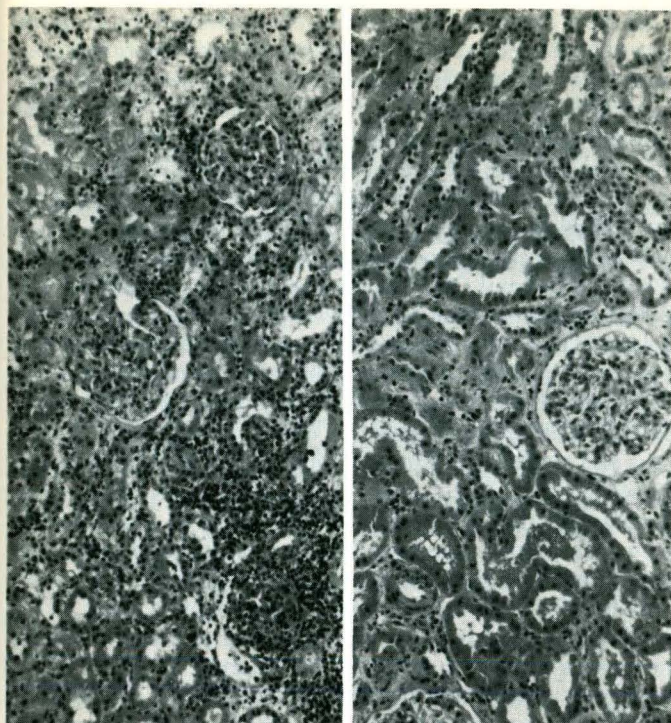


FIGURE 2. Histopathological picture of renal allograft biopsies before (left) and after (right) OKT3 monoclonal antibody therapy. Almost complete disappearance of the interstitial mononuclear infiltrate and reversal of endothelial damage is noted after treatment.

returned to dialysis 2 months after transplantation. She subsequently developed severe cytomegalovirus infection and expired 3 months after transplantation.

Patient 4 is of particular interest because of the development during therapy of an antibody response to the OKT3 reagent. During the initial 10 days of therapy, peripheral blood T cell monitoring of this patient revealed essentially complete loss of cells reactive with OKT3 antibody, and allograft function steadily improved from a peak serum creatinine of 8.1 to 2.9 mg/100 ml. During the final 4 days of OKT3 therapy, however, large numbers of OKT3-reactive cells were repeatedly demonstrable in the patient's peripheral blood and no serum excess of OKT3 could be achieved even after the dosage of monoclonal antibody had been increased from 2 to 5 mg/day. At the time, the steadily falling serum creatinine again began to rise and allograft biopsy revealed extensive evidence of acute rejection. The immunosuppressive protocol was immediately changed to conventional therapy with high-dose steroids, local irradiation, and actinomycin D; but the rejection process continued, necessitating allograft nephrectomy 31 days after transplantation. Evaluation of serial serum samples from this patient by flow cytometry documented the appearance of anti-OKT3 antibody initially on day 10 of therapy with the titer peaking 5 days after therapy was discontinued. Characterization of these antibodies will be reported in detail elsewhere. No evidence of serum sickness or anaphylaxis was noted at any time in this patient.

Therefore, six of the eight allografts continue with excellent renal function 3 to 12 months after OKT3 treatment. All of the patients treated with OKT3 antibody developed chills and fever

TABLE 1. Cadaver donor renal allograft recipients treated for acute rejection with OKT3 monoclonal antibody

Patient	Age	Sex	Weight (kg)	Etiology of renal disease	HLA antigens matched	Follow-up (months)
1	16	Female	55	IgA nephropathy	0	12
2	52	Male	76	Nephrosclerosis	1	12
3	59	Female	50	Interstitial nephritis	1	3 ^a
4	41	Male	70	Chronic glomerulonephritis	1	8 ^b
5	41	Male	78	Chronic glomerulonephritis	2	6
6	39	Female	55	Dysplasia + focal sclerosing glomerulonephritis	2	6
7	52	Male	56	Chronic glomerulonephritis + diabetes	0	4
8	40	Female	51	Polycystic renal disease	1	3

^a Expired with cytomegalovirus infection after second rejection episode.

^b Maintained on dialysis after loss of allograft during second rejection episode.

TABLE 2. Results of treatment of acute rejection with OKT3 monoclonal antibody

Patient	Post-transplant day of rejection	Prerejection creatinine (mg/100 ml)	Peak creatinine	Days to reversal	Post-therapy creatinine	Total OKT3		Subsequent rejection episode
						Mg	Days	
1	6	1.6	5.4	4	1.3	13	10	Yes ^a
2	16	1.9	4.8	2	1.6	20	10	Yes ^a
3	8	1.6	4.3	2	0.9	18	15	Yes ^b
4	9	5.0	8.1 ^c	2	2.9	34	14	Yes ^b
5	7	1.6	5.8	2	1.3	70	14	No
6	6	2.9	8.5	5	0.9	57	14	No
7	6	3.0	8.1 ^c	4	1.2	90	17	No
8	9	10.4 ^c	11.3 ^c	7	1.1	100	20	Yes ^a

^a Reversed with conventional immunosuppression.

^b Irreversible using conventional immunosuppression.

^c On hemodialysis.

Explore Litigation Insights

Docket Alarm provides insights to develop a more informed litigation strategy and the peace of mind of knowing you're on top of things.

Real-Time Litigation Alerts



Keep your litigation team up-to-date with **real-time alerts** and advanced team management tools built for the enterprise, all while greatly reducing PACER spend.

Our comprehensive service means we can handle Federal, State, and Administrative courts across the country.

Advanced Docket Research



With over 230 million records, Docket Alarm's cloud-native docket research platform finds what other services can't. Coverage includes Federal, State, plus PTAB, TTAB, ITC and NLRB decisions, all in one place.

Identify arguments that have been successful in the past with full text, pinpoint searching. Link to case law cited within any court document via Fastcase.

Analytics At Your Fingertips



Learn what happened the last time a particular judge, opposing counsel or company faced cases similar to yours.

Advanced out-of-the-box PTAB and TTAB analytics are always at your fingertips.

API

Docket Alarm offers a powerful API (application programming interface) to developers that want to integrate case filings into their apps.

LAW FIRMS

Build custom dashboards for your attorneys and clients with live data direct from the court.

Automate many repetitive legal tasks like conflict checks, document management, and marketing.

FINANCIAL INSTITUTIONS

Litigation and bankruptcy checks for companies and debtors.

E-DISCOVERY AND LEGAL VENDORS

Sync your system to PACER to automate legal marketing.