

# Management of Onychomycoses

Markus Niewerth and Hans C. Korting

Dermatologische Klinik und Poliklinik, Ludwig-Maximilians-Universität, Munich, Germany

## Contents

Abstract	283
1. Definition and Epidemiology	284
2. Quality of Life	284
3. Clinical Types of Onychomycosis	284
4. Aetiology and Pathogenesis	284
5. Diagnosis	285
6. Treatment	285
6.1 Nail Removal	285
6.2 Drug Treatment	286
6.2.1 General Considerations	286
6.2.2 Former Standard Antimycotics	287
6.2.3 Itraconazole	288
6.2.4 Terbinafine	288
6.2.5 Fluconazole	289
6.2.6 Topical Therapy	289
7. Efficacy	290
8. Adverse Effects and Drug Interactions	291
9. Cost Effectiveness	292
10. Conclusions	292

## Abstract

Onychomycoses, infections of the nail caused by fungi, are amongst the most common illnesses. Because of the high incidence of these infections and problems involved in their therapy, they have received much attention, particularly as concerns a better characterisation of the causative micro-organisms. Onychomycosis caused by dermatophytes (*tinea unguium*) is most common and is found more frequently on the feet than on the hands. The clinical presentation of onychomycosis is at best indicative of fungal infection, and the growth of a credible pathogen is an indispensable prerequisite for definite diagnosis. The clinical appearance is variable. Four major types of manifestation have been characterised, depending on localisation and spread.

New antifungal agents for systemic or topical application based on novel active substances or vehicles are available, and cure is feasible for the majority of cases. Therapy can and should be individualised, depending on the characteristics of the particular case.

Currently, continuous or intermittent oral treatment with itraconazole or terbinafine exhibit a particularly favourable risk : benefit ratio. Fluconazole might become an alternative in the near future. With respect to topical treatment, ciclopirox or amorolfine lacquer and the bifonazole/urea combination deserve particular interest. However, cure cannot be expected for every case.

## 1. Definition and Epidemiology

Onychomycosis is defined as an infection of the nail with fungi, whether dermatophytes, yeasts or moulds.

It seems that the frequency of infections of the nail due to fungi has increased in recent decades. Although there are no comparative world-wide statistics on infections, there is an increasing number of studies examining the frequency and causative organisms of onychomycoses from particular countries and groups of patients. In Europe, there seems to be an average prevalence of about 2 to 5%,<sup>[1,2]</sup> with the prevalence particularly increasing in older people. Important factors that influence the epidemiology comprise climatic conditions, geographical location, degree of urbanisation and social standards, in particular conditions of work and current footwear habits (onychomycosis of the feet is by and large restricted to populations wearing shoes).<sup>[3]</sup>

Moreover, there are some individual risk factors promoting the manifestation of onychomycosis. These include mechanical alteration, for example onycholysis or onychodystrophy, respectively, caused by frequent recurrent trauma in athletes or a single injury of the nail organ resulting in life-long damage.<sup>[4]</sup> Even the application of cosmetic acrylic nail extensions can affect *Candida* nail bed infections and thus promote onychomycosis.<sup>[5]</sup>

## 2. Quality of Life

Onychomycosis is not merely an aesthetic problem, although this aspect must not be underemphasised. For many patients it is a major problem that interferes with their lifestyle. It has been proven repeatedly that this infection leads to psychological stress as well as to physical pain.<sup>[6-9]</sup> Affected patients experience a decrease of self-confidence, reduction of leisure activities and, particularly, a limitation of sports activities. Onychomycosis consequently compromises quality of life to a remarkable extent.

## 3. Clinical Types of Onychomycosis

The clinical spectrum of onychomycosis is generally represented by 4 different types of manifestation. According to localisation and spread, the classification differentiates between:<sup>[10]</sup>

- distal subungual onychomycosis
- white superficial onychomycosis
- proximal subungual onychomycosis
- onychomycosis associated with chronic mucocutaneous candidiasis.

These clinical types can involve either toenails and/or fingernails. Recently, a new classification of onychomycosis has been published, differentiating between distal and lateral subungual onychomycosis, superficial onychomycosis, proximal subungual onychomycosis, endonyx onychomycosis and total dystrophic onychomycosis.<sup>[11]</sup>

## 4. Aetiology and Pathogenesis

Fungal infections of the nail involve toenails more often than fingernails, in a ratio of about 5 : 1. With toenail onychomycosis, tinea pedis, especially of the intertriginous type, is responsible in most instances for the infection of the nail organ.<sup>[12]</sup>

Onychomycoses can be caused by dermatophytes, yeasts or moulds. However, dermatophytes are responsible for about 90 to 95% of infections. Among the dermatophytes, *Trichophyton rubrum* plays a major role as a pathogen.<sup>[13]</sup> In addition, *Trichophyton mentagrophytes* and *Epidermophyton floccosum* are regularly found as causative micro-organisms. Among the yeasts, *Candida albicans* plays the major, if not exclusive, role as a causative organism. Yeast infections of the nail organ are frequently associated with chronic paronychia or chronic mucocutaneous candidiasis, but yeast infection of the nail organ and chronic paronychia must clearly be differentiated. It is a matter of debate whether *C. albicans* is a primary pathogen of nails or whether it can only directly invade nail tissue that is already abnormal.<sup>[14]</sup> Nevertheless, onychomycoses due to *C. albicans* can show the same clinical picture as dermatophyte

onychomycoses. Among the moulds, *Scopulariopsis brevicaulis* is currently considered to be the major pathogen. In some countries, infections due to *Fusarium* and *Scytalidium* spp. are also not infrequent.<sup>[15-17]</sup> In overtly dystrophic nails, the relative proportion of mould infections is clearly increased.<sup>[18]</sup>

This distribution pattern applies to countries in climatically temperate zones. Under other conditions, other distributions of the frequency of pathogens can be found. In tropical zones, for example, there is a higher proportion of yeast infections.

In children, onychomycosis is seen at a lower frequency than in adults. The prevalence according to most studies world-wide is between 0% and 6%. The majority of these infections are due to *T. rubrum*.<sup>[19,20]</sup> The lower frequency may be explained by the faster growth of nails, a smaller surface to attack and structural differences.

In immunosuppressed patients, particularly those with AIDS, onychomycosis is not an overwhelming problem. Although the prevalence in this group of patients seems to be slightly higher, severe manifestations of the disease, as seen for example with oral candidiasis, are uncommon.<sup>[21]</sup> There are indications, however, of a shift of frequency of the clinical types towards proximal subungual onychomycosis.<sup>[22]</sup>

## 5. Diagnosis

In patients with nail disease indicative of onychomycosis, diagnostic proof of infection and identification of the pathogen is required before therapy starts. The first step in diagnosis is normally microscopic examination of native material. The infected part of the nail must first be cleansed with a disinfectant such as 70% isopropanol to remove contaminants such as bacteria.<sup>[23]</sup> The outermost parts of the nail-plate to be examined should be removed as far as possible, and specimens should be taken from deeper layers. For this purpose, high speed abrasion using a special type of frais has proven particularly beneficial.<sup>[24]</sup> The material should be soaked in 15 to 20% potassium hydroxide solution and be examined by micros-

copy after incubation for 1 hour in a wet chamber. In a positive case, mycelial material can be seen. Efforts can be made to differentiate between dermatophytes, yeast and moulds; however, this will not generally be rewarding.<sup>[25]</sup> Potassium hydroxide preparations can be false-negative. If potassium hydroxide preparations are repeatedly negative but onychomycosis is still considered, a nail biopsy can be done. This approach is more sensitive but also more invasive, and for that reason it does not belong in the standard diagnostic procedures.<sup>[26,27]</sup>

In addition to the native preparation, a proof of fungal nail disease by culture should be performed in every case. For this culture, media such as Kimmig's agar or Sabouraud glucose agar can be used. For each specimen at least 2 cultures should be performed: one without any additive and the other with cycloheximide and/or chloramphenicol to prevent overgrowth by airborne bacteria or moulds present in the environment. The culture is time-consuming, taking at least 2 weeks and up to 4 weeks. A clear differentiation of the pathogen at the species level can be made by growth form, surface and colour, and the microscopic appearance of macro- and microconidia, as well as further parameters based on subcultures.<sup>[28]</sup> As yet, molecular approaches to diagnostics have not reached clinical practice.<sup>[29]</sup>

## 6. Treatment

### 6.1 Nail Removal

Previously, nail removal by extraction was employed not infrequently. Because of the high efficacy of the newer antifungal agents, surgical treatment by and large belongs to history. Surgery causes temporary disablement for work, intra- and postoperative complications, and in particular traumatization of the nail matrix with possible permanent deformation. Therefore, its use must be approached very critically. A more recent alternative is represented by atraumatic chemomechanical maceration of the diseased nail with urea ointment under occlusion, an option systematically developed in the context of the characterisation of



**Table I.** Chemistry and route of administration of the most important antimycotics

Drug	Structural class	Administration
Amorolfine	Morpholine	Topical
Bifonazole	Imidazole	Topical
Ciclopirox	Hydroxypyridone	Topical
Clotrimazole	Imidazole	Topical
Econazole	Imidazole	Topical
Fluconazole	Triazole	Oral/intravenous
Griseofulvin	Dimethoxycoumarin derivative	Oral
Itraconazole	Triazole	Oral
Ketoconazole	Imidazole	Oral/topical
Terbinafine	Allylamine	Oral/topical
Tioconazole	Imidazole	Topical

bifonazole/urea ointment which is commercially available in several countries.<sup>[30-33]</sup>

## 6.2 Drug Treatment

### 6.2.1 General Considerations

For drug treatment of onychomycoses, the topical and systemic routes of application of antifungal agents are considered relevant (table I). Topical therapy might seem to be the treatment of choice, since it does not lead to systemic adverse effects or to any interactions with other systemic drugs taken by the patient. Unfortunately, at present topical treatment alone does not provide cure for more than a significant subgroup of patients.

The reasons for the failure of topical treatment may be multiple. Apart from other factors, success depends on the type of infection. Success is considered unlikely in the context of the most common type, pedal distal subungual onychomycosis, if more than 30 to 50% of the nail plate is affected.<sup>[34]</sup> Moreover, cure seems to be particularly difficult if

the lateral part of the nail plate is involved with the lesion reaching from the free margin to the nail matrix.<sup>[35]</sup> Additionally, the probability of cure depends on the number of infected nails. With more than 5 infected nails, cure is unlikely. A shorter period of therapy is commonly required for the treatment of fingernail onychomycosis and cure rates are slightly higher than with toenail onychomycosis. As topical antimycotics must, in most cases, diffuse through the horny material of the nail plate into deeper layers to reach the causative organisms, the chance of cure seems to be particularly low with thickly keratinised, dystrophic, pre-damaged nails. Finally, a significant number of patients have problems with the application of the antifungal agent on toenails because of additional movement disorders.

Topical therapy is particularly justified when less than 30% of the nail plate is affected and with white superficial onychomycosis.<sup>[34]</sup> With more extensive infections, or even in total dystrophic onychomycosis, topical treatment does not generally lead to success and systemic therapy is necessary (table II). However, use of systemic therapy is limited by several factors, including possible severe adverse effects caused by the active compound itself or by its interaction with concomitant medication.

Although there have been some important advances in topical therapy in recent years, the most significant advances have been made in systemic therapy. This is particularly reflected by cure rates. A larger number of effective drugs are available today for drug therapy of onychomycosis than ever before. However, with this relative abundance of options, an informed choice of the correct anti-

**Table II.** Therapeutic procedures for culture-proven onychomycoses<sup>[34]</sup>

Clinical type	Degree of severity <sup>a</sup>	Therapy
White superficial onychomycosis	I-III	Topical, possibly tangential removal
Distal subungual onychomycosis	I-II	Topical, possibly with nail plate removal
Distal subungual onychomycosis	III	Systemic
Proximal subungual onychomycosis	II-III	Systemic
Onychomycosis associated with chronic mucocutaneous candidiasis	I-III	Systemic
Total dystrophic onychomycosis		Systemic

a I = <30% of the nail affected; II = 30 to 60% of the nail affected; III = >60% of the nail affected.



mycotic agent for a given patient is even more important. The different classes of agents have different targets (fig. 1) and thus differ considerably with respect to their therapeutic and adverse effect profiles. Special consideration should be given to the risk : benefit ratio as well as to the cost : benefit ratio.

It has become clear that griseofulvin as a therapeutic agent has ceased to be the gold standard, and today it is rarely used in the therapy of onychomycosis in highly industrialised countries. Occasionally it still is used in studies as a comparative antifungal drug, because its action and effectiveness are well established. Another antifungal agent that has been removed from the therapeutic armamentarium is ketoconazole. Instead, the newer agents itraconazole, terbinafine and fluconazole are considered for first-line systemic treatment; numerous studies of the effectiveness, optimal dosage, adverse effects and cost of these agents have been, and currently still are being, performed.

### 6.2.2 Former Standard Antimycotics

Griseofulvin is a compound synthesised by some species of *Penicillium*. It has been used for systemic treatment of dermal mycoses, including onychomycoses, since 1959. Its efficacy is limited to dermatophytes. The mechanism of action is fungistatic, due to interactions with microtubule-associated proteins and the ensuing inhibition of fungal cell mitosis. The gastrointestinal absorption of griseofulvin shows remarkable interindividual differences, and depends also on the drug formulation. The highest rates of absorption are found with the ultramicrosize preparation.<sup>[37]</sup> The route by which griseofulvin gets to the site of infection has not yet been fully elucidated; it is probably incorporated into newly formed keratinocytes.

Griseofulvin undergoes hepatic metabolism to 6-demethyl-griseofulvin, which is excreted in the urine.<sup>[38]</sup> In onychomycosis of the toenails, the rates of success of griseofulvin treatment are lower than 40% despite treatment periods of a year or more.<sup>[39]</sup>

For some time at the beginning of the 1980s ketoconazole was used as an oral antifungal agent

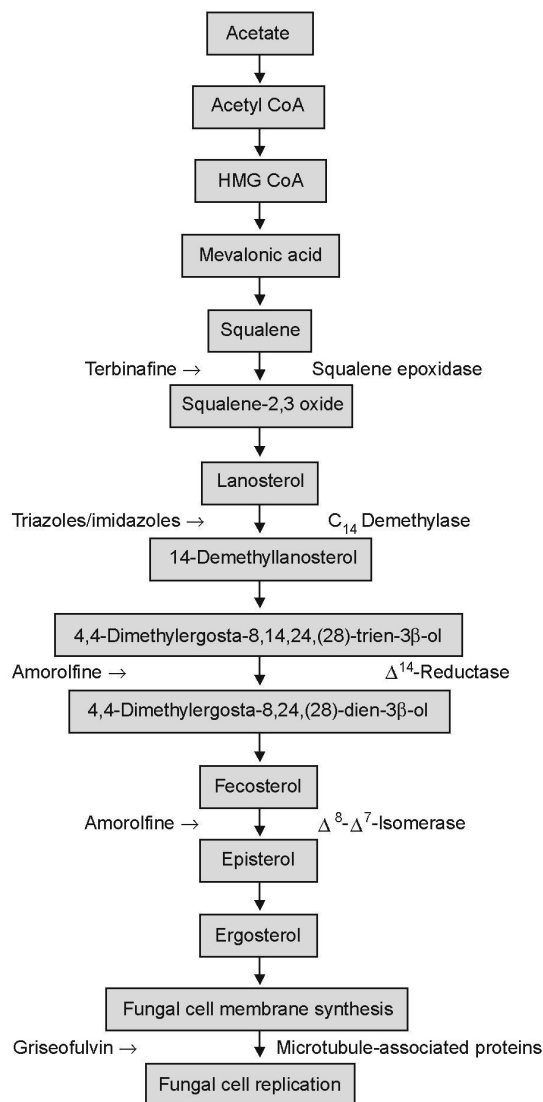


Fig. 1. Molecular targets of relevant antimycotics (modified from Gupta et al.,<sup>[36]</sup> with permission).

for systemic therapy of onychomycoses and severe tinea of glabrous skin, with cure rates similar to those seen with griseofulvin. It was the forerunner of the more modern azoles itraconazole and fluconazole. After some fatal cases of idiosyncratic drug-induced hepatitis, systemic ketoconazole is no longer generally approved for the treatment of onychomycoses. Nevertheless, it may be used with

care for resistant mucocutaneous or fingernail disease if topical treatment is not effective.

### 6.2.3 Itraconazole

Itraconazole is one of the most important drugs among the newer antifungal agents. It belongs to the triazoles, and is currently the only triazole approved for oral administration in onychomycoses. At clinically achievable serum concentrations, itraconazole is fungistatic. Its *in vitro* activity is directed against a variety of different fungi, including dermatophytes, yeasts and some moulds.<sup>[40-42]</sup>

The affinity of itraconazole for fungal cytochrome P450 (CYP) isoenzymes is much higher than for their human congeners. After oral administration it is distributed to a large apparent volume in the body.<sup>[42]</sup> It can be detected within 24 hours in sweat. The drug accumulates in stratum corneum, nail material, sebum and vaginal mucosa. The concentration in sebum is 10-fold higher than the corresponding plasma concentration.<sup>[43]</sup> In plasma, 99.8% of itraconazole is protein-bound. Because of its high affinity for keratin, itraconazole achieves high concentrations in the nail matrix and nail bed.<sup>[44]</sup> In the distal part of the nail plate, effective concentrations can be detected as early as 1 week after starting treatment. After termination of treatment, effective concentrations remain present in the nail for some months; this explains the further improvement of the clinical state observed after discontinuation of the drug. Consequently, pulse therapy is possible with administration of the drug for just 1 week per month. This results in a lower total dose with similar efficacy to continuous treatment.

Itraconazole is processed to numerous metabolites by the liver. Within 1 week, 35% and 54% respectively are excreted in the urine and faeces.<sup>[45]</sup>

For management of onychomycosis, itraconazole can either be given continuously at a dosage of 200 mg/day for 3 months or as a pulse therapy with 400 mg/day in 2 divided doses for 1 week per month for 3 to 4 months.<sup>[46]</sup> In fingernail onychomycosis, administration for 2 months may possibly be sufficient.

### 6.2.4 Terbinafine

Terbinafine, an allylamine, also belongs to the newer antifungal agents.<sup>[47]</sup> It exhibits a primarily fungicidal mode of action. Its activity *in vitro* includes dermatophytes as well as moulds, but it is less active against yeasts.<sup>[48,49]</sup> Its activity against dermatophytes *in vitro* is higher by several orders of magnitude than those of the other antimycotics available (fig. 2). Terbinafine inhibits the biosynthesis of ergosterol by specific and selective inhibition of squalene epoxidase, leading to accumulation of toxic squalene and consequently destruction of the fungal cell. In contrast to the azoles, the affinity of terbinafine for CYP is low, and so it shows less interaction with other drugs as compared with the azoles.

Maximal plasma concentrations of terbinafine are reached within 2 hours. Terbinafine is strongly

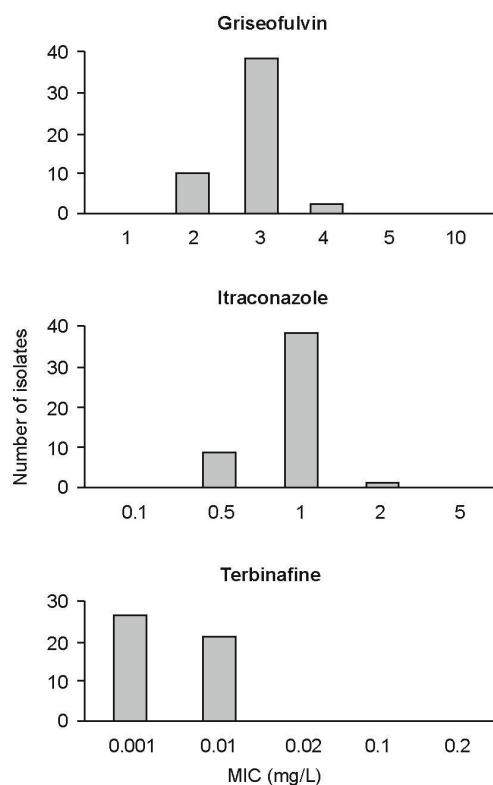


Fig. 2. Distribution of the minimum inhibitory concentrations (MICs) of griseofulvin, itraconazole and terbinafine for dermatophytes (from Niewerth et al.,<sup>[50]</sup> with permission).

and nonspecifically bound to plasma proteins.<sup>[47]</sup> It reaches the nail plate via the nail-bed by passive diffusion. Terbinafine can be detected in the distal part of the nail plate within 1 week.<sup>[51]</sup> Maximum effective concentrations in the nail are reached after 18 weeks with a 6-week treatment. The pharmacokinetics of terbinafine in affected nails do not differ substantially from those in healthy nails.<sup>[52]</sup>

Terbinafine has an average plasma half-life of about 3 weeks. In older patients or patients with hypertension, an increase of plasma concentrations can be found. Smokers show lower plasma concentrations.<sup>[53]</sup>

For the treatment of toenail onychomycosis, terbinafine 250 mg/day should be given for 12 weeks;<sup>[54]</sup> in fingernail onychomycosis a 6-week treatment is generally sufficient.

#### 6.2.5 Fluconazole

The triazole fluconazole has been used for years with great success in oropharyngeal and oesophageal candidiasis and other indications in immunocompromised patients with or without HIV infection. Fluconazole has only recently been evaluated for therapy of onychomycosis.<sup>[55,56]</sup> Consequently the experiences with this kind of therapy are limited.

Because of its strongly hydrophilic character, fluconazole is well absorbed after oral administration. In contrast to itraconazole, the absorption of fluconazole is not influenced by gastric acid, food and antacids or H<sub>2</sub> receptor blocking agents.<sup>[57]</sup> Fluconazole is distributed in the total body water. In plasma, only 11% of fluconazole is protein-bound; the rest can be found as unbound free molecules. Because of its long plasma half-life of 30 hours, fluconazole can be given at 24-hour or even longer intervals (fig. 3). Nearly 80% of fluconazole is excreted unchanged in urine. In toenails, fluconazole can be detected for 4 to 5 months after termination of oral therapy (fig. 4).<sup>[58]</sup> *In vitro*, fluconazole shows sufficient activity against a variety of different fungi, including not only yeasts but also dermatophytes.<sup>[59]</sup>

So far, a consensus about the standard dosage of fluconazole for the treatment of onychomycosis

has not been reached. Most often, 150 mg/day is given either once daily or once weekly for several months. In future, pulse therapy with 150, 300 or 450mg once weekly for up to 12 months will probably be recommended.<sup>[60]</sup>

#### 6.2.6 Topical Therapy

For topical therapy there are a number of alternative approaches that differ in the mechanism of action of the antifungal compound and in the vehicle used. There are still agents for chemical removal of the nail plate alone as well as true antimycotics, and combinations of these approaches. For chemical removal, glutaraldehyde<sup>[61]</sup> and urea ointments,<sup>[62]</sup> among others, have been proposed. The clinical success with these agents, however, is poor. Better cure rates can be found with the combination of antifungal agent and nail removal, in particular with bifonazole 1% and urea ointment 40%, which shows a mycological cure rate of 46% at 24-week follow-up,<sup>[63]</sup> and propylene glycol/urea/lactic acid solution.<sup>[64]</sup> Previously, tioconazole 28% nail solution alone had been suggested, and showed a cure rate of 22%.<sup>[65]</sup>

A better clinical outcome and higher microbiological cure rates can probably be reached with nail lacquer containing either the hydroxypyridone ciclopirox or the morpholine amorolfine. These drugs diffuse from the nail lacquer slowly into the

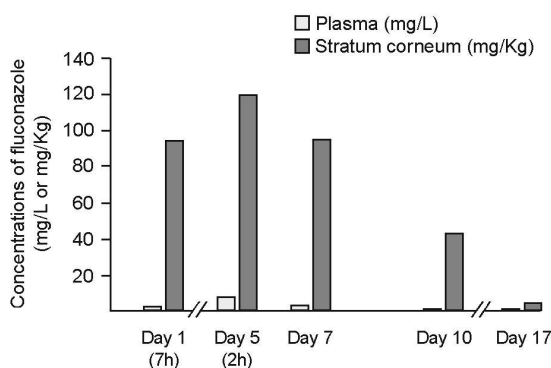


Fig. 3. Fluconazole concentrations in plasma and stratum corneum of 9 healthy individuals after daily administration of one 200mg capsule for 5 days [time elapsed since previous application in brackets] (from Wildfeuer et al.,<sup>[58]</sup> with permission).



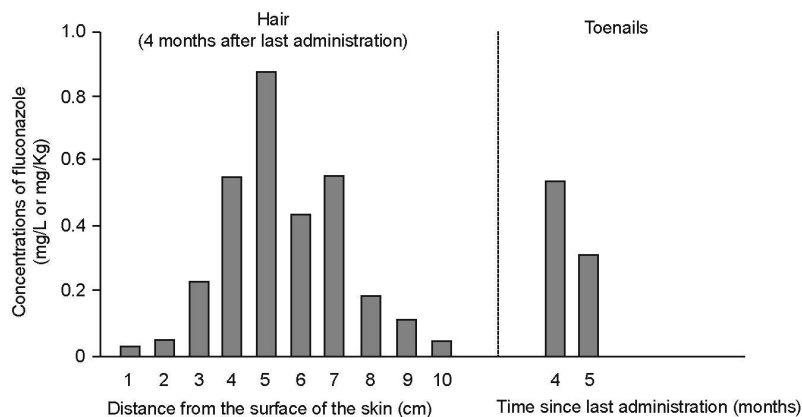


Fig. 4. Fluconazole concentrations in various segments of the scalp hair and toenails of 9 healthy individuals after daily administration of one 200mg capsule for 5 days (from Wildfeuer et al.,<sup>[68]</sup> with permission).

nail plate and are active against dermatophytes, yeasts and moulds.<sup>[66-68]</sup>

Amorolfine should be applied once weekly<sup>[69]</sup> as a 5% lacquer, which provides clinical cure in 46.1% of patients.<sup>[70]</sup> Ciclopirox 8% should be applied every second day in the first month, at least twice weekly in the second month, and once weekly in the third month, possibly for longer.

## 7. Efficacy

Many studies have been performed to test the efficacy of different antifungal agents. In general, it is difficult to compare the cure rates established by the different studies, primarily because the end-points are defined differently, for example as clinical – either complete or partial – cure rates, mycological cure rates or combinations thereof. Another point that should be taken into account is disease relapse rate following successful treatment with different antifungal agents. A knowledge of relapse rates is important for assessment of overall efficacy and cost effectiveness. Relapse rates vary to a large extent between the different studies, generally reflecting cure rates, but in some studies follow-up was not performed. Thus, a final judgement on the relative merits of agents is only possible after direct comparative studies with an adequate follow-up.

If griseofulvin is compared with the newer antifungal agents itraconazole<sup>[71]</sup> and terbinafine,<sup>[72-74]</sup> lower efficacy rates can clearly be seen for the older agent even if the duration of therapy is up to 3 times higher, possibly up to 18 months.

The cure rates with terbinafine range from about 60% to 80% for toenails at the usual daily dosage of 250mg for 3 months.<sup>[75-77]</sup> Extending the duration of application to 12 months does not appear to improve the outcome,<sup>[78]</sup> whereas a shorter duration of 6 weeks is insufficient.<sup>[79]</sup>

The studies with itraconazole also show good efficacy rates, although the results, ranging from about 40% to 80%, differ more widely than with terbinafine.<sup>[80,81]</sup> Itraconazole dosages of between 50 and 100 mg/day have not been proven to be fully adequate,<sup>[82]</sup> and it seems that only dosages of 200 mg/day or greater are sufficient. In addition to continuous treatment with 200 mg/day for 3 months, pulse treatment with 400 mg/day as 2 divided doses for 1 week per month for 3 to 4 months has been proven sufficient.<sup>[83-86]</sup> In a direct comparison of continuous therapy and pulse therapy, almost equal cure rates were found,<sup>[87,88]</sup> pulse therapy excelling because of a lower frequency of adverse effects, lower costs and better compliance.<sup>[89]</sup> Thus, pulse therapy is considered an effective and well tolerated approach.<sup>[90]</sup>

In the majority of trials comparing terbinafine and the 2 alternative dosage regimens for itraconazole, terbinafine tends to be slightly superior to itraconazole; with the latter drug, continuous application tends to be slightly more efficacious than intermittent application after a follow-up of 40 weeks, 6 months and 8 months, respectively.<sup>[91-93]</sup> Some other studies show essentially similar results, with a slight trend towards a higher frequency of adverse effects with terbinafine.<sup>[94]</sup> In contrast with the older results, a recent study<sup>[95]</sup> indicates that terbinafine administered continuously for 12 weeks is more effective for the treatment of toenail onychomycosis than intermittent therapy with itraconazole given for 1 week every 4 weeks for 12 or 16 weeks.<sup>[95]</sup>

With fluconazole, the trials already published do not allow final judgement. Most of the recent data, however, suggest that pulse treatment with fluconazole might become a major alternative to established treatment options. According to recent US trials, cure rates between 77 and 86% have been found with fluconazole 150, 300 and 450mg given once weekly, without a clear-cut dose-dependency.<sup>[96]</sup>

We currently do not know what to do if an established treatment protocol has failed. Recalcitrant onychomycosis can still represent a therapeutic challenge. As such cases are by no means rare, this subpopulation of patients deserves to be the focus of research attention during the years to come. It might well turn out that combined topical and systemic treatment is a good idea in this context. The role of combined treatment still awaits definitive evaluation in placebo-controlled double-blind trials.<sup>[97-99]</sup>

## 8. Adverse Effects and Drug Interactions

Every effective drug applied systemically has adverse effects, and interactions with concomitant medication appear regularly.

Ketoconazole is no longer used in the routine treatment of onychomycosis, because of rare events of life-threatening drug-induced hepatitis. Itraconazole is also an azole derivative, but severe hepatic

toxicity is not a major concern in this treatment setting.<sup>[100]</sup> Single case reports refer to debilitating oedema<sup>[101]</sup> and acute generalised exanthematic pustulosis.<sup>[102]</sup> In contrast to these individual case reports, itraconazole has been characterised in a report on the experience with 13 600 patients treated for various illnesses as virtually free from recognisable adverse effects.<sup>[103]</sup>

Drug interactions associated with itraconazole are generally related to an increase or decrease in the plasma concentrations of drugs. In particular, itraconazole on the one hand increases the plasma concentrations of terfenadine, cyclosporin, digoxin, nifedipine and coumarin.<sup>[104-106]</sup> On the other hand, the plasma concentration of itraconazole is decreased by rifampicin (rifampin), isoniazid, phenytoin, carbamazepine, phenobarbital, antacids, H<sub>2</sub> blockers and didanosine.

Severe adverse effects with terbinafine occur occasionally. A number of reports of erythema multiforme and Stevens-Johnson syndrome, as well as toxic epidermal necrolysis, have been published.<sup>[107,108]</sup> The frequency of erythema multiforme in the UK has been calculated as 15 per 100 000 patients treated with terbinafine.<sup>[109]</sup> Fortunately, these severe skin reactions have so far virtually never been lethal. Taste disturbances (dysgeusia) occur in about 0.6% of patients, women seemingly being affected more often.<sup>[110]</sup> In most cases, taste is no longer compromised 1 month after the end of therapy,<sup>[111]</sup> although a recent publication reports persistent impairment of taste.<sup>[112]</sup>

Terbinafine shows a lower frequency of interactions with other drugs compared with the azoles. The plasma concentration of terbinafine is increased by cimetidine and caffeine, and decreased by rifampicin and phenobarbital.<sup>[113,114]</sup> Reports of interactions with terfenadine are contradictory.<sup>[115]</sup>

With fluconazole, the description of relevant adverse effects is more difficult because data on the use of fluconazole for onychomycosis are limited. With fluconazole therapy for other indications, for example in HIV infection, patients receive a large variety of drugs and consequently it is difficult to differentiate the possible effects of fluconazole

from those of other drugs. So far, no severe adverse effects have been reported that can be unambiguously associated with fluconazole.<sup>[116]</sup>

Fluconazole increases the bioavailability of phenytoin, cyclosporin and sulfonyleureas, and additionally, it increases prothrombin time after administration of warfarin. Fluconazole decreases the bioavailability of ethinylestradiol. Thiazide diuretics increase the plasma concentration of fluconazole, whereas rifampicin increases its metabolism.<sup>[117]</sup>

In general, adverse effects such as nausea and vomiting, gastric pain and headache can occur with the use of the various antifungal agents, including griseofulvin, itraconazole and, in particular, fluconazole.

## 9. Cost Effectiveness

In the selection process of the correct drug for a given indication, cost effectiveness should be considered as well as cure rates, adverse effects and drug-drug interactions. Some authors have compared the costs of therapy using the different antifungal agents. Various aspects should be taken into consideration, including drug acquisition costs, drug administration costs, routine medical care, laboratory tests, and costs for the management of adverse drug reactions. Cost-effectiveness studies should be assessed carefully, as the many publications with conflicting results indicate that the relevant principles for the conduct of the trials have not yet been unequivocally defined.

A multinational study compared the costs of griseofulvin, ketoconazole, itraconazole and terbinafine.<sup>[118,119]</sup> As a result, terbinafine showed the lowest costs per patient per year, although acquisition costs were the highest. Some national studies have also shown terbinafine to be the most cost-effective drug.<sup>[120,121]</sup> In this context, however, itraconazole was studied as continuous rather than intermittent therapy.

In a modelling study of cost effectiveness on the basis of the situation in the US in 1994, itraconazole pulse therapy was calculated to cost only half of the cost of continuous therapy (\$US412.16

vs \$US883.20, respectively).<sup>[122]</sup> On the basis of pulse treatment, itraconazole has been considered as more cost effective than terbinafine given continuously, which is in turn more cost effective than itraconazole given continuously.<sup>[123]</sup> However, in a recently published study, no significant differences in cost effectiveness between itraconazole pulse therapy and continuous terbinafine treatment were observed.<sup>[124]</sup>

In a comparison of systemic and topical therapy, ciclopirox and amorolfine have been compared with terbinafine, griseofulvin and itraconazole. In this meta-analysis, ciclopirox had the lowest total expected cost and cost per symptom-free day, followed closely by amorolfine; terbinafine and itraconazole were intermediate and griseofulvin was the most expensive.<sup>[125,126]</sup> This suggests that topical lacquers are cost effective in the treatment of limited onychomycosis.

## 10. Conclusions

Since the introduction of the antifungal agents itraconazole, terbinafine and fluconazole, it is possible to cure the majority of patients with onychomycoses. Therapy can and should be individualised depending on the characteristics of the particular case.

In cases of minor involvement of less than 30% of the nail plate in the context of distal subungual onychomycosis, topical therapy can be sufficient. With more extensive involvement, oral therapy should in general be preferred. Contraindications to systemic therapy include the systemic use of other drugs that might interact with the antifungal agent. In the selection of the appropriate drug for oral treatment, the risk : benefit ratio<sup>[127]</sup> and the cost : benefit ratio play a central role.

The cure rates for itraconazole and terbinafine, and possibly fluconazole, are encouraging. Systemic azoles or terbinafine are clearly the drugs of choice for more severe cases of onychomycosis. Terbinafine tends to be slightly superior to itraconazole. However, the risk of severe adverse effects with terbinafine seems to be higher than with itraconazole. As onychomycosis is not a life-threaten-



ing illness, the safety of treatment is a prime concern. Nevertheless, the risk : benefit ratio is similar for both drugs. The decision on adequate treatment in a given case should be based on an explanation of advantages and disadvantages to the patient, who should to a large extent make the decision on whether the highest degree of efficacy or safety is the most important.

For onychomycosis, the data for fluconazole are limited, and consequently no such definitive statement on risk : benefit ratio is yet possible. Similarly, as a definite conclusion with respect to cost effectiveness cannot so far be drawn, this factor will not generally influence decision making at present.

## References

- Haneke E. Therapie der Nagelmykosen. *Hautarzt* 1993; 44: 335-46
- Williams HC. The epidemiology of onychomycosis in Britain. *Br J Dermatol* 1993; 129: 101-9
- Aly R. Ecology and epidemiology of dermatophyte infections. *J Am Acad Dermatol* 1994; 31: S21-5
- Baran R, Badillet G. Primary onycholysis of the big toenails: a review of 113 cases. *Br J Dermatol* 1982; 106: 529-34
- Symonds JM, O'Dell CA. *Candida* nail bed infection and cosmetic acrylic extensions – potential source of hospital infection? *J Hospital Infect* 1993; 23: 243-4
- Lubeck DP, Patrick DL, McNulty P, et al. Quality of life of persons with onychomycosis. *Quality Life Res* 1993; 2: 341-8
- Scher RK. Onychomycosis is more than a cosmetic problem. *Br J Dermatol* 1994; 130 Suppl. 43: 15
- Whittam LR, Hay RJ. The impact of onychomycosis on quality of life. *Clin Exp Dermatol* 1997; 22: 87-9
- Elewski BE. The effect of toenail onychomycosis on patient quality of life. *Int J Dermatol* 1997; 36: 754-6
- Zaias N. Clinical manifestations of onychomycoses. *Clin Exp Dermatol* 1992; 17 Suppl. 1: 6-7
- Baran R, Hay RJ, Tosti A, et al. A new classification of onychomycosis. *Br J Dermatol* 1998; 139: 567-71
- Leyden JL. Tinea pedis: pathophysiology and treatment. *J Am Acad Dermatol* 1994; 31: S31-3
- Evans EGV. Nail dermatophytosis: the nature and scale of the problem. *J Dermatol Treatment* 1990; 1 Suppl. 2: 47-8
- Haneke E. Fungal infections of the nail. *Semin Dermatol* 1991; 10: 41-53
- Midgley G, Moore MK, Cook JC, et al. Mycology and nail disorders. *J Am Acad Dermatol* 1994; 31: S68-74
- Elewski BE, Greer DL. *Hendersoniella toruloidea* and *Scytalidium hyalinum*. *Arch Dermatol* 1991; 127: 1041-4
- Baran R, Tosti A, Piraccini BM. Uncommon clinical patterns of *Fusarium* nail infection: report of three cases. *Br J Dermatol* 1997; 136: 424-7
- Ellis DH, Watson AB, Marley J, et al. Non-dermatophytes in onychomycosis of the toenails. *Br J Dermatol* 1997; 136: 490-3
- Gupta AK, Sibbald RG, Lynde CW et al. Onychomycosis in children: prevalence and treatment strategies. *J Am Acad Dermatol* 1997; 36: 395-402
- Zienicke HC, Korting HC, Lukacs A, et al. Dermatophytosis in children and adolescents: epidemiology, clinical, and microbiological aspects changing with age. *J Dermatol (Tokyo)* 1991; 18: 438-46
- Korting HC, Schäfer-Korting M, Zienicke H, et al. Treatment of tinea unguium with medium and high doses of ultramicrosize griseofulvin compared with that with itraconazole. *Antimicrob Agents Chemother* 1993; 37: 2064-8
- Domp Martin D, Domp Martin A, Deluol AM, et al. Onychomycosis and AIDS: clinical and laboratory findings in 63 patients. *Int J Dermatol* 1990; 29: 337-9
- Elewski BE. Onychomycosis: pathogenesis, diagnosis, and management. *Clin Microbiol Rev* 1998; 11: 415-29
- Blecher P, Korting HC. A new combined diagnostic approach to clinically and microscopically suspected onychomycosis unproven by culture. *Mycoses* 1993; 36: 312-4
- Clayton YM. Clinical and mycological diagnostic aspects of onychomycoses and dermatomycoses. *Clin Exp Dermatol* 1992; 17 Suppl. 1: 37-40
- Haneke E. Nail biopsies in onychomycosis. *Mycoses* 1985; 28: 473-80
- Suarez SM, Silvers DN, Scher RK, et al. Histologic evaluation of nail clippings for diagnosing onychomycosis. *Arch Dermatol* 1991; 127: 1517-9
- Meinhof W. Isolierung und Identifizierung von Dermatophyten. *Zbl Bakt* 1990; 273: 229-45
- Bastert J, Korting HC. Diagnostische Methoden zur Spezies-spezifischen Differenzierung unterschiedlicher Dermatophyten. *Dtsch Med Wschr* 1998; 123: 499-503
- Baden HP. Treatment of distal onychomycosis with avulsion and topical antifungal agents under occlusion. *Arch Dermatol* 1994; 130: 558-9
- Cohen PR, Scher RK. Topical and surgical treatment of onychomycosis. *J Am Acad Dermatol* 1994; 31: S74-7
- Baran R, Hay RJ. Partial surgical avulsion of the nail in onychomycosis. *Clin Exp Dermatol* 1985; 10: 413-8
- Stettendorf S. Topical treatment of onychomycoses with bifonazole-urea ointment. In: Nolting S, Korting HC, editors. *Onychomycoses*. Berlin, Heidelberg: Springer, 1990: 102-8
- Abeck D, Gruseck E, Korting HC, et al. Onychomykose: Epidemiologie, Pathogenese, Klinik, Mikrobiologie und Therapie. *Dtsch Ärztebl* 1996; 93: A-2027-32
- Baran R, De Doncker P. Lateral edge nail involvement indicates poor prognosis for treating onychomycosis with the new systemic antifungals. *Acta Derm Venereol (Stockh)* 1996; 76: 82-3
- Gupta AK, Sauder DN, Shear NH. Antifungal agents: an overview. Part II. *J Am Acad Dermatol* 1994; 30: 911-33
- Schäfer-Korting M, Korting HC, Mutschler E. Human plasma and skin blister fluid levels of griseofulvin after its repeated administration. *Eur J Clin Pharmacol* 1985; 29: 351-4
- Warnock DW. New pharmacological concepts in antimycotic treatment. *J Eur Acad Dermatol Venereol* 1993; 2 Suppl. 1: S19-25
- Korting HC, Schäfer-Korting M. Is tinea unguium still widely incurable? *Arch Dermatol* 1992; 128: 243-8
- Haria M, Bryson HM, Goa KL. Itraconazole. A reappraisal of its pharmacological properties and therapeutic use in the management of superficial fungal infections. *Drugs* 1996; 51: 585-620

41. Korting HC, Ollert M, Abeck D. Results of German multicenter study of antimicrobial susceptibilities of *Trichophyton rubrum* and *Trichophyton mentagrophytes* strains causing tinea unguium. *Antimicrob Agents Chemother* 1995; 39: 1206-8
42. Schäfer-Korting M, Korting HC, Lukacs A, et al. Levels of itraconazole in skin blister fluid after a single oral dose and during repetitive administration. *J Am Acad Dermatol* 1990; 22: 211-5
43. Cauwenbergh G, Degreef H, Heykants J, et al. Pharmacokinetic profile of orally administered itraconazole in human skin. *J Am Acad Dermatol* 1988; 18: 263-8
44. Willemsen M, De Doncker P, Willems J. Post-treatment itraconazole levels in nail. New implications for the treatment of onychomycosis. *J Am Acad Dermatol* 1992; 26: 731-5
45. Heykants J, Van Peer A, Van de Velde V. The clinical pharmacokinetics of itraconazole: an overview. *Mycoses* 1989; 32: 67-87
46. Grant SM, Clissold SP. Itraconazole: a review of its pharmacodynamic and pharmacokinetic properties, and therapeutic use in superficial and systemic mycoses. *Drugs* 1989; 37: 310-44
47. Balfour JA, Faulds D. Terbinafine: a review of its pharmacodynamic and pharmacokinetic properties, and therapeutic potential in superficial mycoses. *Drugs* 1992; 43: 259-84
48. Zaias N, Serrano L. The successful treatment of finger *Trichophyton rubrum* onychomycosis with oral terbinafine. *Clin Exp Dermatol* 1989; 14: 120-3
49. Nolting S, Bräutigam M, Weidinger G. Terbinafine in onychomycosis with involvement by non-dermatophytic fungi. *Br J Dermatol* 1994; 130 Suppl. 43: 16-21
50. Niewerth M, Splanemann V, Korting HC, et al. Antimicrobial susceptibility testing of dermatophytes – comparison of the agar macrodilution and broth microdilution tests. *Chemotherapy (Basel)* 1998; 44: 31-5
51. Schatz F, Bräutigam M, Dobrowolowski E, et al. Nail incorporation kinetics of terbinafine in onychomycosis patients. *Clin Exp Dermatol* 1995; 20: 377-83
52. Finlay AY, Lever L, Thomas R, et al. Nail matrix kinetics of oral terbinafine in onychomycosis and normal nails. *J Dermatol Treat* 1990; 1 Suppl. 2: 51-3
53. Nedelman JR, Gibiansky E, Robbins BA, et al. Pharmacokinetics and pharmacodynamics of multi-dose terbinafine. *J Clin Pharmacol* 1996; 36: 452-61
54. Goodfield MJD, Andrew L, Evans EGV. Short term treatment of dermatophyte onychomycosis with terbinafine. *BMJ* 1992; 304: 1151-4
55. Coldiron B. Recalcitrant onychomycosis of the toenails successfully treated with fluconazole. *Arch Dermatol* 1992; 128: 909-10
56. Smith SW, Sealy DP, Schneider E, et al. An evaluation of the safety and efficacy of fluconazole in the treatment of onychomycosis. *South Med J* 1995; 88: 1217-20
57. Grant SM, Clissold SP. Fluconazole. A review of its pharmacodynamic and pharmacokinetic properties, and therapeutic use in superficial and systemic mycoses. *Drugs* 1990; 39: 877-916
58. Wildfeuer A, Faergemann J, Laufen H, et al. Bioavailability of fluconazole in the skin after oral medication. *Mycoses* 1994; 37: 127-30
59. Wildfeuer A, Seidl HP. The *in vitro* activity of fluconazole against fungi involved in dermal infections. *Mycoses* 1994; 37: 447-9
60. Faergemann J, Laufen H. Levels of fluconazole in normal and diseased nails during and after treatment of onychomycoses in toenails with fluconazole 150 mg once weekly. *Acta Derm Venereol (Stockh)* 1996; 76: 219-21
61. Suringa DW. Treatment of superficial onychomycosis with topically applied glutaraldehyde. *Arch Dermatol* 1970; 102: 163-76
62. White MI, Clayton YM. The treatment of fungus and yeast infections of nails by the method of 'chemical removal'. *Clin Exp Dermatol* 1982; 7: 273-6
63. Hay RJ, Roberts DT, Doherty VR, et al. The topical treatment of onychomycosis using a new combined urea/imidazole preparation. *Clin Exp Dermatol* 1988; 13: 164-7
64. Faergemann J, Swanbeck G. Treatment of onychomycosis with a propylene glycol-urea-lactic acid solution. *Mycoses* 1988; 32: 536-40
65. Hay RJ, Clayton YM, Moore MK. A comparison of tioconazole 28% nail solution versus base as an adjunct to oral griseofulvin in patients with onychomycosis. *Clin Exp Dermatol* 1987; 12: 175-7
66. Haria M, Bryson HM. Amorolfine: a review of its pharmacological properties and therapeutic potential in the treatment of onychomycoses and other superficial fungal infections. *Drugs* 1995; 49: 103-20
67. Nolting S, Seebacher C. Ciclopiroxolamin. *Wegweiser topischer Mykose-Therapie*. Frankfurt, Jena: Universitätsverlag Jena, 1993
68. Pharmaceutical Research Associates. Ciclopirox nail lacquer 8%: integrated summary of efficacy. Internal Report 1998
69. Reinel D, Clarke C. Comparative efficacy and safety of amorolfine nail lacquer 5% in onychomycosis, once-weekly versus twice-weekly. *Clin Exp Dermatol* 1992; 17 Suppl. 1: 44-9
70. Lauharanta J. Comparative efficacy and safety of amorolfine nail lacquer 2% versus 5% once weekly. *Clin Exp Dermatol* 1992; 17 Suppl 1: 41-3
71. Korting HC, Blecher P, Stallmann D, et al. Dermatophytes on the feet of HIV-infected patients: frequency, species distribution, localisation and antimicrobial susceptibility. *Mycoses* 1993; 36: 271-4
72. Faergemann J, Anderson C, Hersle K, et al. Double-blind, parallel-group comparison of terbinafine and griseofulvin in the treatment of toenail onychomycosis. *J Am Acad Dermatol* 1995; 32: 750-3
73. Hofmann H, Bräutigam M, Weidinger G. Treatment of toenail onychomycosis: a randomized, double-blind study with terbinafine and griseofulvin. *Arch Dermatol* 1995; 131: 919-22
74. Haneke E, Tausch I, Bräutigam M, et al. Short duration treatment of fingernail dermatophytosis: a randomized, double-blind study with terbinafine and griseofulvin. *J Am Acad Dermatol* 1995; 32: 72-7
75. Goodfield MJD. Short duration therapy with terbinafine for dermatophyte onychomycosis: a multicenter trial. *Br J Dermatol* 1992; 126 Suppl. 39: 33-5
76. Watson A, Marley J, Ellis D, et al. Terbinafine in onychomycosis of the toenail: a novel treatment protocol. *J Am Acad Dermatol* 1995; 33: 775-9
77. Svejgaard EL, Brandrup F, Kragballe K, et al. Oral terbinafine in toenail dermatophytosis. *Acta Derm Venereol (Stockh)* 1997; 77: 66-9
78. Goodfield MJD. Clinical results with terbinafine in onychomycosis. *J Dermatol Treatment* 1990; 1 Suppl. 2: 55-7
79. Tausch I, Bräutigam M, Weidinger G, et al. Evaluations of 6 weeks treatment of terbinafine in tinea unguium in a double-blind trial comparing 6 and 12 weeks therapy. *Br J Dermatol* 1997; 136: 737-42



80. Hay RJ, Clayton YM, Moore MK, et al. An evaluation of itraconazole in the management of onychomycosis. *Br J Dermatol* 1988; 119: 359-66
81. Haneke E, Delescluse J, Plinck EPB, et al. The use of itraconazole in onychomycosis. *Eur J Dermatol* 1996; 6: 7-10
82. Walsoe I, Stangerup M, Svejgaard E. Itraconazole in onychomycosis: open and double-blind studies. *Acta Derm Venereol (Stockh)* 1990; 70: 137-40
83. De Doncker P, Van Lint J, Dockx P, et al. Pulse therapy with one-week itraconazole monthly for three or four months in the treatment of onychomycosis. *Cutis* 1995; 56: 180-3
84. Bonifaz A, Carrasco-Gerard E, Saul A. Itraconazole in onychomycosis: intermittent dose schedule. *Int J Dermatol* 1997; 36: 70-2
85. De Doncker P, Gupta AK, Marynissen G, et al. Itraconazole pulse therapy for onychomycosis and dermatomycoses: an overview. *J Am Acad Dermatol* 1997; 37: 969-74
86. Odom RB, Aly R, Scher RK, et al. A multicenter, placebo-controlled, double-blind study of intermittent therapy with itraconazole for the treatment of onychomycosis of the fingernail. *J Am Acad Dermatol* 1997; 36: 231-5
87. De Doncker P, Decroix J, Pierard GE, et al. Antifungal pulse therapy for onychomycosis. *Arch Dermatol* 1996; 132: 34-41
88. Heikkilä H, Stubb S. Long-term results of patients with onychomycosis treated with itraconazole. *Acta Derm Venereol (Stockh)* 1997; 77: 70-1
89. Havu V, Brandt H, Heikkilä H, et al. A double-blind, randomized study comparing itraconazole pulse therapy with continuous dosing for the treatment of toenail onychomycosis. *Br J Dermatol* 1997; 136: 230-4
90. De Doncker P, Scher RK, Barab RL, et al. Itraconazole therapy is effective for pedal onychomycosis caused by some non-dermatophyte molds and in mixed infection with dermatophytes and molds: a multicenter study with 36 patients. *J Am Acad Dermatol* 1997; 36: 173-7
91. Bräutigam M, Nolting S, Schopf RE, et al. Randomized double blind comparison of terbinafine and itraconazole for treatment of toenail tinea infection. *BMJ* 1995; 311: 919-22
92. Tosti A, Piraccini BC, Stinchi C, et al. Treatment of dermatophyte nail infections: an open randomized study comparing intermittent terbinafine therapy with continuous terbinafine treatment and intermittent itraconazole therapy. *J Am Acad Dermatol* 1996; 34: 595-600
93. Honeyman JF, Talarico FS, Arruda LHF, et al. Itraconazole versus terbinafine (Lamisil): which is better for the treatment of onychomycosis? *J Eur Acad Dermatol Venereol* 1997; 9: 215-21
94. Arenas R, Dominguez-Cherit J. Open randomized comparison of itraconazole versus terbinafine in onychomycosis. *Int J Dermatol* 1995; 34: 138-43
95. Evans EGV, Sigurgeirsson B, Billstein S. Continuous terbinafine versus intermittent itraconazole in the treatment of toenail onychomycosis (L.I.O.N. study). *Focus on Fungal Infection* 8; 1998 Mar 4-6; Orlando (FL)
96. Scher RK. A placebo controlled, randomized, double-blind trial of once-weekly fluconazole (150, 300, or 45 mg) in the treatment of distal subungual onychomycosis of the toenail [abstract]. 37th Interscience Conference on Antimicrobial Agents and Chemotherapy; 1997 Sep 28-Oct 1; Toronto, Canada; 380
97. Kuokkanen K, Alava S. Fluconazole in the treatment of onychomycosis caused by dermatophytes. *J Dermatol Treat* 1992; 3: 115-7
98. Nahass GT, Sisto M. Onychomycosis: successful treatment with once-weekly fluconazole. *Dermatology* 1993; 186: 59-61
99. Feuilhade M, Baran R, Goettmann S, et al. Onychomycoses dermatophytiques avec atteinte de la matrice: intérêt de l'association d'un vernis contenant 5% d'amorolfine a un traitement oral par terbinafine. *Ann Dermatol* 1996; 123 Suppl.: 143
100. Hann SK, Kim JB, Im S, et al. Itraconazole-induced acute hepatitis. *Br J Dermatol* 1993; 129: 500-1
101. Rosen T. Debilitating edema associated with itraconazole therapy. *Arch Dermatol* 1994; 130: 260-1
102. Heymann WR, Manders SM. Itraconazole-induced acute generalized exanthematic pustulosis. *J Am Acad Dermatol* 1995; 32: 131-2
103. Zuckerman JM, Tunkel AR. Itraconazole: a new triazole antifungal agent. *Infect Control Hosp Epidemiol* 1994; 15: 397-410
104. Tailor SAN, Gupta AK, Walker SE, et al. Peripheral edema due to nifedipine-itraconazole interaction: a case report. *Arch Dermatol* 1996; 132: 350-2
105. Neuvonen PJ, Suhonen R. Itraconazole interacts with felodipine. *J Am Acad Dermatol* 1995; 33: 134-5
106. Rzyany B, Mockenhaupt M, Gehring W, et al. Stevens-Johnson syndrome after terbinafine therapy. *J Am Acad Dermatol* 1994; 30: 509
107. Carstens J, Wendelboe P, Sogaard H, et al. Toxic epidermal necrolysis and erythema multiforme following therapy with terbinafine. *Acta Derm Venereol (Stockh)* 1994; 74: 391-2
108. McGregor JM, Rustin MHA. Terbinafine and erythema multiforme. *Br J Dermatol* 1994; 131: 587-8
109. Inman W, Kubota K, Pearce G, et al. PEM Report Number 7. Itraconazole. *Pharmacoepidemiol Drug Saf* 1993; 2: 423-43
110. O'Sullivan DP, Needham CA, Bangs A, et al. Postmarketing surveillance of oral terbinafine in the UK: report of a large cohort study. *Br J Clin Pharmacol* 1996; 42: 559-65
111. Shear NH, Gupta AK. Terbinafine for the treatment of pedal onychomycosis. *Arch Dermatol* 1995; 131: 937-42
112. Bong JL, Lucke TW, Evans CD. Persistent impairment of taste resulting from terbinafine. *Br J Dermatol* 1998; 139: 747-8
113. Gupta AK, Shear NH. Terbinafine: an update. *J Am Acad Dermatol* 1997; 37: 979-88
114. Brodell RT, Elewski BE. Clinical pearl: systemic antifungal drugs and drug interactions. *J Am Acad Dermatol* 1995; 33: 259-60
115. Robbins B, Chang CT, Cramer JA, et al. Safe coadministration of terbinafine and terfenadine: a placebo-controlled crossover study of pharmacokinetic and pharmacodynamic interactions in healthy volunteers. *Clin Pharmacol Therapeutics* 1996; 59: 275-83
116. Hay RJ. Risk/benefit ratio of modern antifungal therapy: focus on hepatic reactions. *J Am Acad Dermatol* 1993; S50-4
117. Bickers DR. Antifungal therapy: potential interactions with other classes of drugs. *J Am Acad Dermatol* 1994; 31: S87-90
118. Arikian SR, Einarson TR, Kobelt-Nguyen G, et al. A multinational pharmaco-economic analysis of oral therapies for onychomycosis. *Br J Dermatol* 1994; 130 Suppl. 43: 35-44
119. Davis R, Balfour JA. Terbinafine. A pharmaco-economic evaluation of its use in superficial fungal infections. *Pharmacoeconomics* 1995; 8: 253-69
120. Einarson TR, Arikian SR, Shear NH. Cost-effectiveness analysis for onychomycosis therapy in Canada from a government perspective. *Br J Dermatol* 1994; 130 Suppl. 43: 32-4
121. Bergman W, Rutten FFH. Orale behandeling van onychomycose van de teenagels; vergelijking van kosteneffectiviteit van



- griseofulvin, itraconazol, ketoconazol en terbinafine. Ned Tijdschr Geneesk 1994; 138: 2346-50
122. Chren MM. Costs of therapy for dermatophyte infections. J Am Acad Dermatol 1994; 31: S103-6
123. Van Doorslaer EKA, Tormans G, Gupta AK, et al. Economic evaluation of antifungal agents in the treatment of toenail onychomycosis in Germany. Dermatology 1996; 193: 239-44
124. Gupta AK. Pharmacoeconomic analysis of oral antifungal therapies used to treat dermatophyte onychomycosis of the toenail. Pharmacoeconomics 1998; 13: 1-15
125. Oh PI, Shear NH, Einarson TR. Cost-effectiveness analysis of antifungal therapy for onychomycosis. 1996 International Summit on Cutaneous Antifungal Therapy; 1996 May 26-28; Vancouver
126. Einarson TR. Pharmacoeconomic applications of meta-analysis for single groups using antifungal onychomycosis lacquers as an example. Clin Ther 1997; 19: 559-69
127. Gupta AK, De Doncker P, Heenen M. An overview of assessment of the use of the antifungal agents itraconazole, terbinafine, and fluconazole in dermatology. In: Korting HC, Schäfer-Korting M, editors. The benefit/risk ratio. A handbook for the use of potentially hazardous drugs. Boca Raton (FL): CRC Press, 1999: 263-85

---

Correspondence and reprints: Dr *Hans C. Korting*, Klinikum Innenstadt, Dermatologische Klinik and Poliklinik, Frauenlobstrasse 9-11, D-80337 Munich, Germany.