



8

Endocrine tumours of the pancreas

Kjell Öberg* MD, PhD

Barbro Eriksson MD, PhD

Department of Medical Sciences, University Hospital, 751 85 Uppsala, Sweden

Endocrine pancreatic tumours (EPTs) are uncommon tumours occurring in approximately 1 in 100 000 of the population, representing 1–2% of all pancreatic neoplasms. Some of the tumours may be part of multiple endocrine neoplasia type one (MEN-1) syndrome or von Hippel–Lindau (vHL) disease. EPTs are classified as functioning or non-functioning tumours on the basis of their clinical manifestation. The biochemical diagnosis of EPT is based on hormones and amines released. Besides specific markers such as insulin, there are also general tumour markers such as chromogranin A, which is the most valuable marker and has been reported to be increased in plasma in 50–80% of patients with EPTs and correlates with tumour burden. The location of endocrine tumours of the pancreas includes different techniques, from endoscopic investigations to scintigraphy (e.g. somatostatin receptor scintigraphy) and positron emission tomography. The medical treatment of endocrine pancreatic tumours consists of chemotherapy, somatostatin analogues and α -interferon. None of these can cure a patient with malignant disease. In future, therapy will be custom-made and based on current knowledge of tumour biology and molecular genetics.

Key words: endocrine pancreatic tumours; histopathology; molecular genetics; biochemistry; localization; medical treatment.

EPIDEMIOLOGY

Endocrine tumours of the pancreas (EPTs) are rare tumours. They occur in approximately 1 in 100 000 or represent 1–2% of all pancreatic neoplasms.^{1–3} The incidence in autopsy studies has been reported as high as 1.5% clinically unrecognized or asymptomatic and usually small (diameter <1 cm).⁴ The tumours show no significant gender predilection and occur at all ages, with a peak incidence between 30 and 60 years.^{5,6} Some of the tumours may be part of the multiple endocrine neoplasia type one syndrome (MEN-1), and these family members might present non-functioning

* Corresponding author. Tel.: +46 18 611 4917; Fax: +46 18 50 7268.
E-mail address: kjell.oberg@medsci.uu.se (K. Öberg).

1521-6918/\$ – see front matter © 2005 Elsevier Ltd. All rights reserved.

endocrine pancreatic tumours when as young as 20–30 years of age.⁷ Less common than MEN-1 is von Hippel–Lindau (vHL) disease where about 15% of the patients present with EPT.⁸

PATHOPHYSIOLOGY, TUMOUR BIOLOGY, SYMPTOMS AND BIOCHEMICAL DIAGNOSIS

Originally EPTs were thought to have evolved from the islets of Langerhans themselves. However, more recent evidence suggests that these tumours arise from pluripotent stem cells in the ductal epithelium.^{9–11} Differentiation from a neuroendocrine lineage is suggested by their cytoplasmic labelling with silver stains.¹² However, it is not clear whether benign insulin-producing tumours develop from islet stem cells.

EPTs are categorized on the basis of their clinical manifestation into functioning and non-functioning tumours. Functioning tumours are associated with a clinical syndrome caused by inappropriate secretion of hormones. Within this group are insulinomas, glucagonomas, somatostatinomas, gastrinomas, VIPomas and other less common tumours. Non-functioning tumours or 'non-syndromic' tumours are not associated with a distinct hormonal syndrome, but may still show elevated hormone levels in the blood or immunoreactivity in tissue sections. Tumours with a majority of cells expressing and secreting pancreatic polypeptide or neurotensin are included in the group of non-functioning tumours. Many somatostatin-producing tumours are also clinically silent, because they do not cause a distinct hormonal syndrome.¹² Quite recently, ghrelin—a novel gastrointestinal hormone produced by rat and human gastric X-like neuroendocrine cells which strongly stimulates growth hormone (GH) secretion—has been detected in endocrine pancreatic tumours. These tumours might express both ghrelin and the ghrelin receptor, but a distinct clinical syndrome related to this overproduction has not been described.¹³ Non-functioning tumours often become clinically apparent due to their large size or invasion of adjacent organs or to the occurrence of metastases. Quite often they are detected incidentally on abdominal imaging procedures for other reasons. About 30–40% of all EPTs constitute the group of non-functioning tumours.

Histopathology

The characteristic histological appearance of EPTs is a uniform cytology with scant mitoses. Cellular patterns can be either solid, acinar or trabecular. However, these different patterns exhibit no difference in biological behaviour.^{11,12} The majority of the tumours are well demarcated and solitary, showing a white–yellow or pink–brown colour. The diameter is usually in the range 1–5 cm. Patients with MEN-1 present multiple endocrine pancreatic tumours, the majority being of non-functioning type, but also some of them produce different hormones in different lesions. Among the functioning tumours insulinomas are usually the smallest, but the size of the tumours is not related to the severity of the hormonally induced symptoms. Non-functioning tumours are generally larger, often 5 cm or more. Tumours with a diameter of more than 2 cm have an increased risk of malignant behaviour, and those over 3 cm are usually malignant.^{11,12}

Coarse-needle aspiration biopsy is a useful method for investigating endocrine

Table 1. Negative prognostic factors of endocrine pancreatic tumours (EPTs).

Metastases
Gross invasion of adjacent organs
Angioinvasion
Perineural invasion
Tumour diameter <2 cm
Mitoses >2 per 10 HPF
Ki-67 (MIB-1) >2%
Necrosis

tomography, transabdominal ultrasonography, and more recently endoscopic ultrasonography. The cytomorphological features of EPTs are the same whether they are functioning or non-functioning. In general the histological pattern of a tumour does not allow a conclusion as to its functioning state or type of hormone production. There are two exceptions to this rule: amyloid deposits are indicative of insulinomas, and glandular structures containing psammoma bodies are commonly observed in somatostatin-producing tumours.^{11,12,14,15} Poorly differentiated endocrine carcinomas are sometimes misdiagnosed as pancreatic cancer. These highly aggressive neoplasms are hardly recognized as endocrine tumours at first sight, and require immunohistochemical examination to reveal their neuroendocrine phenotype (Table 1).

They show rather pleomorphic cells with high mitotic index (> 10/10 HPF). They all usually show also angioinvasion.^{3,11,12} EPTs can clearly be identified by using antibodies to markers common to all or most neuroendocrine cells: i.e. chromogranin A, synaptophysin, neuron-specific enolase (NSE) and protein gene product 9.5 (PGP 9.5). EPTs also contain cytokeratin 8, 18 and 19,⁶ and might also express vesicle monoamine transporter proteins 1 and 2 (VMAT-1 or VMAT-2). VMAT-1 has been exclusively found in the serotonin-containing EPTs.¹⁶ Neuropilin 2 is a novel marker expressed in pancreatic islet cells and DPTs; it seems to be co-localized with glucagon-expressing cells.¹⁷

Molecular genetics

Whereas the molecular basis of familial EPTs (MEN-1) and vHL syndrome has been recently established, little is known about the oncogenesis and the molecular basis of the progression of sporadic tumours. In contrast to other human tumours, the activation of an oncogene is not a common event in EPTs. Mutations in *k-ras*, *P53*, *myc*, *fos*, *jun*, *src* and the *Rb* gene have not been implicated in the pathogenesis of sporadic endocrine pancreatic tumours.^{18–23} Molecular and cytogenetic analyses have identified a number of chromosomal alterations in EPTs. Compared genomic hybridization studies have revealed that chromosomal losses have occurred slightly more frequently than gains, while amplifications are uncommon.^{24,25} Furthermore, the total number of genomic changes per tumour appears to be associated with both tumour volume and disease stage, indicating that genetic alterations accumulate during tumour progression. Thus large tumours with increased malignant potential—and especially metastases—harbour more genetic alterations than small and clinically benign neoplasms. These findings point towards a tumour suppressor pathway and genomic instability as important mechanisms associated with tumour progression. Losses of chromosome 1

Table 2. Genetic alterations in endocrine pancreatic tumours (EPTs).

Locus	LOH	Gene	Mutation	CGH
1p36–	10/29 (34%)			21/102 (21%)
1q32–	8/29 (28%)			16/102 (16%)
3p23–	23/31 (74%)			19/102 (19%)
3p25–26–	31/73 (42%)	VHL	1/75 (1%)	19/102 (19%)
6q22–	43/69 (62%)			29/102 (28%)
9p–	12/37 (32%)	CDKN2A/p16	1/44 (2%)	0/102 (0%)
9q+				29/102 (28%)
10q23–	8/16 (50%)	PTEN	1/31 (3%)	14/102 (14%)
11p14–				28/102 (27%)
11q13	75/111 (67%)	MEN-1	33/155 (21%)	31/102 (30%)
11q22–23	20/37 (54%)	SDHD	0/20 (0%)	31/102 (30%)
12p12+		K-Ras	1/39 (3%)	23/102 (23%)
15q–		SMAD3	0/18 (0%)	6/102 (6%)
17p13–	15/40 (38%)	TP53	1/40 (3%)	2/102 (2%)
17p+				32/102 (31%)
18q21–	23/68 (34%)	DPC4	0/41 (0%)	6/102 (6%)
22q12.1	9/12 (75%)			4/102 (4%)
Xq–	11/23 (48%)			14/46 (30%)
Y–	5/14 (36%)			14/56 (25%)

LOH, loss of heterozygosity; CGH, comparative genetic hybridization.

since they are already present in small tumours. Prevalent chromosomal alterations common in metastases include gains of both chromosome 4 and 7 and losses of 21q, implying that these chromosome imbalances may contribute to tumour dissemination (Table 2).^{26–28}

EPTs belonging to the MEN-1 syndrome present deletions on chromosome 11q13. Data indicate that somatic MEN-1 mutations are present in about 20% of spontaneous neoplasms and that 68% harbour losses of 11q13 and/or more distal parts of the long arm of chromosome 11.^{29–31} These findings indicate that another as yet unknown tumour suppressor gene might be involved. The inherited genetic syndromes most commonly associated with EPT are MEN-1 and vHL disease. The MEN-1 syndrome has been associated with mutations in the menin gene on chromosome 11q13. Menin is a presumed tumour suppressor, a nuclear protein interacting with Jun D and API transcription factor. Up to 80% of MEN-1 patients demonstrate loss of heterozygosity for the menin gene.^{31–33} Less common than MEN-1 syndrome is vHL disease. About 14% of patients with vHL disease present with EPTs. All of these tumours have been of non-functioning type, and more than half of the patients have multiple tumours. The gene associated with vHL is located on chromosome 3p25.2. The gene protein products inhibit the process of transcription elongation. This gene does not appear to be involved in the development of sporadic EPTs.^{8,34}

Biochemical diagnosis

The biochemical diagnosis is based on hormones and amines released from the EPTs (Figure 1). These markers can be divided into specific markers, such as insulin from an

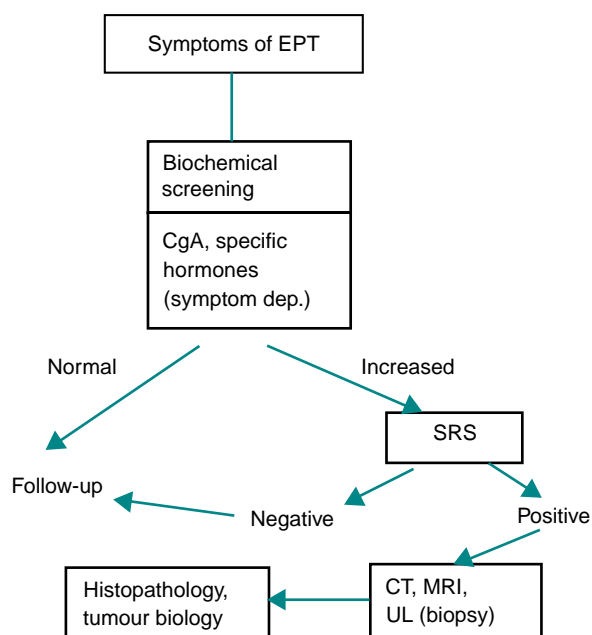


Figure 1. Diagnostic algorithm for endocrine pancreatic tumours (EPTs). CgA, chromogranin A; CT, computed tomography; MRI, magnetic resonance imaging.

and so forth. There are also general tumour markers, the most interesting being chromogranin A, pancreatic polypeptide (PP), and the α -subunits of human chorionic gonadotrophin (hCG). Chromogranin A is a 49 kDa, monomeric, hydrophilic, acidic glycoprotein which is widely expressed in neuroendocrine cells and constitutes one of the most abundant components of secretory granules. Chromogranin A immunohistochemistry is the main step in the diagnosis of neuroendocrine tumours. Chromogranin A is released into the circulation and is a useful marker for neuroendocrine tumours. Increased levels of chromogranin A have been reported in 50–80% of EPTs and sometimes correlate with the tumour burden. The highest chromogranin A levels have been reported in so-called non-functioning tumours.^{35–40} In a recent study, combination of chromogranin A with measurement of PP increased the sensitivity from 84 to 96% in non-functioning tumours and from 74 to 94% in functioning tumours.⁴¹ Serum PP alone shows a rather low sensitivity, somewhere between 40 and 55%. Increased circulating levels of hCG- α subunits have been implicated as a sign of malignancy of EPTs. About 30% of patients with EPTs present high levels of hCG- α . Patients with MEN-1 demonstrate high levels of chromogranin A, which are clearly related to the tumour burden. Specific markers will be discussed in relation to the different tumour types.

INSULINOMAS

Insulinomas are the most frequent of all functioning EPTs. The incidence of insulinoma

Explore Litigation Insights

Docket Alarm provides insights to develop a more informed litigation strategy and the peace of mind of knowing you're on top of things.

Real-Time Litigation Alerts



Keep your litigation team up-to-date with **real-time alerts** and advanced team management tools built for the enterprise, all while greatly reducing PACER spend.

Our comprehensive service means we can handle Federal, State, and Administrative courts across the country.

Advanced Docket Research



With over 230 million records, Docket Alarm's cloud-native docket research platform finds what other services can't. Coverage includes Federal, State, plus PTAB, TTAB, ITC and NLRB decisions, all in one place.

Identify arguments that have been successful in the past with full text, pinpoint searching. Link to case law cited within any court document via Fastcase.

Analytics At Your Fingertips



Learn what happened the last time a particular judge, opposing counsel or company faced cases similar to yours.

Advanced out-of-the-box PTAB and TTAB analytics are always at your fingertips.

API

Docket Alarm offers a powerful API (application programming interface) to developers that want to integrate case filings into their apps.

LAW FIRMS

Build custom dashboards for your attorneys and clients with live data direct from the court.

Automate many repetitive legal tasks like conflict checks, document management, and marketing.

FINANCIAL INSTITUTIONS

Litigation and bankruptcy checks for companies and debtors.

E-DISCOVERY AND LEGAL VENDORS

Sync your system to PACER to automate legal marketing.