

Short Communication

Mutation and Expression Analyses Reveal Differential Subcellular Compartmentalization of PTEN in Endocrine Pancreatic Tumors Compared to Normal Islet Cells

Aurel Perren,^{*†} Paul Komminoth,^{*}
Parvin Saremaslani,^{*} Claudia Matter,^{*}
Seraina Feurer,^{*} Jacqueline A. Lees,[‡]
Philipp U. Heitz,^{*} and Charis Eng^{†§}

From the Department of Pathology,^{*} University of Zürich, Zurich, Switzerland; the Clinical Cancer Genetics and Human Cancer Genetics Programs,[†] Comprehensive Cancer Center, and Division of Human Genetics, Department of Internal Medicine, The Ohio State University, Columbus, Ohio; the Department of Cancer Biology,[‡] Massachusetts Institute of Technology, Cambridge, Massachusetts; and the Cancer Research Campaign Human Cancer Genetics Research Group,[§] University of Cambridge, Cambridge, United Kingdom

The pathogenesis of sporadic endocrine pancreatic tumors (EPTs) is still primarily unknown. Comparative genomic hybridization studies revealed loss of 10q in a significant number (nine of 31) of EPTs. The tumor suppressor gene *PTEN* lies on 10q23, and so, is a candidate to play some role in EPT pathogenesis. Germline *PTEN* mutations are found in Cowden and Bannayan-Riley-Ruvalcaba syndromes, whereas somatic mutations and deletions are found in a variety of sporadic cancers. The mutation and expression status of *PTEN* in EPTs has not yet been examined. Mutation analysis of the entire coding region of *PTEN* including splice sites was performed in 33 tumors, revealing one tumor with somatic L182F (exon 6). Loss of heterozygosity of the 10q23 region was detected in eight of 15 informative malignant (53%) and in none of seven benign EPTs. *PTEN* expression was assessed in 24 available EPTs by immunohistochemistry using a monoclonal anti-*PTEN* antibody. Of these 24, 23 tumors showed strong immunoreactivity for *PTEN*. Only the EPTs with *PTEN* mutation lacked *PTEN* protein expression. Although normal islet cells always exhibited predominantly nuclear *PTEN* immunostaining, 19 of 23 EPTs had a predominantly cytoplasmic *PTEN* expression pattern. Exocrine pancreatic tissue

was *PTEN*-negative throughout. *PTEN* mutation is a rare event in malignant EPTs and *PTEN* protein is expressed in most (23 of 24) EPTs. Thus, intragenic mutation or another means of physical loss of *PTEN* is rarely involved in the pathogenesis of EPTs. Instead, either an impaired transport system of *PTEN* to the nucleus or some other means of differential compartmentalization could account for impaired *PTEN* function. Loss of heterozygosity of the 10q23 region is a frequent event in malignant EPTs and might suggest several hypotheses: a different tumor suppressor gene in the vicinity of *PTEN* might be principally involved in EPT formation; alternatively, 10q loss, including *PTEN*, seems to be associated with malignant transformation, but the first step toward neoplasia might involve altered subcellular localization of *PTEN*. (*Am J Pathol* 2000, 157:1097-1103)

The etiology and pathogenesis of sporadic endocrine pancreatic tumors (EPTs) remain primarily unknown. Mutations of the *MEN1* gene responsible for the autosomal dominantly inherited MEN 1 syndrome are found only in ~15 to 30% of sporadic EPTs.^{1,2} Oncogenes (such as *FOS*, *C-MYC*, *M-MYC*, and *SIS*) or tumor suppressor genes (such as *TP53* or *RB1*) which are frequently activated or mutated in other human tumors seem not to be involved in the neoplastic transformation of EPTs.^{3,4} Comparative genomic hybridization analysis of EPTs revealed losses of Y, 6q, 11q, 3p, 3q, 11p, 6p, 10q, and Xq. The frequency of 10q loss was 25% of all EPTs with a

Supported in part by the American Cancer Society RPG98-211-01CCE (to C. E.) and the National Cancer Institute (P30 CA16058 to The Ohio State University Comprehensive Cancer Center).

Accepted for publication July 1, 2000.

Address reprint requests to Charis Eng, Human Cancer Genetics Program, The Ohio State University Comprehensive Cancer Center, 420 W. 12th Avenue, Room 690C Medical Research Facility, Columbus, OH 43210. E-mail: eng-1@medctr.osu.edu.

frequency as high as seven of nine of nonfunctioning EPTs.⁵ The tumor suppressor gene *PTEN* maps to 10q23.3.⁶⁻⁸

Germline *PTEN* mutations are responsible for the autosomal dominantly inherited Cowden and Bannayan-Riley-Ruvalcaba syndromes as well as a *Proteus*-like syndrome.⁹⁻¹³ Relatively high frequencies of somatic intragenic *PTEN* mutations and deletions are found in noncultured endometrial carcinomas¹⁴⁻¹⁷ and malignant gliomas.^{18,19} Despite the frequency of structural *PTEN* mutations in noncultured endometrial carcinomas, we have shown that epigenetic silencing of *PTEN* not only plays a prominent role in its pathogenesis, but also in the pathogenesis of the earliest endometrial precancers.¹⁷ Further, we have demonstrated that loss of PTEN protein expression in the absence of mutations occurs in breast carcinogenesis.²⁰ To examine whether 10q loss in EPTs points to involvement of the tumor suppressor *PTEN*, we analyzed a series of 33 EPTs for intragenic mutations and deletions of *PTEN* and PTEN protein expression.

Materials and Methods

Tumor Samples

Thirty-three EPTs were drawn from the files of the Department of Pathology, University Hospital Zürich, Switzerland. The tumors were classified according to the most recent World Health Organization classification.²¹ They comprised 19 insulinomas (six malignant, 12 benign, one MEN 1-associated, and one of uncertain clinical behavior), two malignant glucagonomas, three malignant VIPomas, three malignant gastrinomas (one MEN 1-associated), and six nonfunctioning (five malignant, one benign) EPTs. Except for one gastrinoma and one insulinoma as noted, all of the EPTs were sporadic and not associated with MEN 1 or von Hippel-Lindau (VHL) syndrome. Comparative genomic hybridization analysis of these tumors has been performed previously.⁵

Fresh-frozen tissue was snap-frozen in liquid nitrogen and stored at -80°C . Paraffin samples were fixed by immersion in 4% buffered formalin and embedded in paraffin according to standard procedures.

DNA Extraction

Genomic DNA from fresh-frozen tissue was isolated using the D-5000 Purgene DNA Isolation Kit (Gentra Systems, Minneapolis, MN) according to the manufacturer's instructions. DNA from these fresh-frozen tissues was used for mutation analysis. Where no nonneoplastic fresh-frozen tissue was available, DNA was extracted from paraffin blocks for loss of heterozygosity (LOH) analysis. For this purpose, 10- μm sections of formalin-fixed par-

LOH Analysis

To assess LOH of the *PTEN* region at 10q23, we used the centromeric marker D10S579, the intragenic markers AFMa086wg9 and D10S2491, and the telomeric marker D10S1735. Polymerase chain reaction (PCR) was performed according to standard procedures and the products were electrophoresed through polyacrylamide gels containing 7 mol/L urea followed by silver staining as previously described.² LOH was defined as a complete absence or reduced signal of one of the constitutional alleles in the tumor tissue compared to the corresponding nonneoplastic tissue.

Mutation Analysis

PCR amplification was performed in a 50- μl mixture 1 \times PCR buffer (Perkin Elmer Europe, Rotkreuz, Switzerland) containing 400 ng of template DNA, 200 $\mu\text{mol/L}$ of dNTP (Roche Diagnostics, Rotkreuz, Switzerland), 1 $\mu\text{mol/L}$ each of intronic-based primers flanking each exon (Table 1), and 0.2 μl of *Taq* polymerase (AmpliTaq Gold; Perkin Elmer Europe). A touchdown PCR was performed with denaturation at 95°C for 1 minute, annealing at 55 to 48°C (with 1°C decrements per cycle) for 1 minute, and extension at 72°C for 1 minute followed by additional 30 cycles at 48° annealing temperature and a final extension at 72° for 10 minutes. Varying concentrations of MgCl_2 and dimethylsulfoxide were used (Table 1).

For the single-strand conformation polymorphism analysis, 10 μl of denatured PCR products in stop buffer (95% formamide, 20 mmol/L ethylenediaminetetraacetic acid, 0.05% xylene cyanol, 0.05% bromophenol blue) were loaded onto nondenaturing polyacrylamide gels. Electrophoresis was performed at 40 W for 5 hours at room temperature. After electrophoresis, the DNA was visualized by silver staining as described.²³

Immunohistochemistry

The monoclonal anti-human PTEN antibody 6H2.1 raised against the last 100 C-terminal amino acids was used in all immunohistochemical analysis.^{20,24} Specificity and characterization of 6H2.1 has previously been demonstrated by Western blot, immunohistochemistry on cell lines with known PTEN expression status as well as the ability of cold peptide to compete off immunostaining on paraffin-embedded sections.^{17,20,25}

Twenty-four cases where paraffin blocks were available were subjected to immunohistochemistry (Table 2). Four- μm sections were cut and mounted on Superfrost Plus slides (Fischer Scientific, Pittsburgh, PA). Immunostaining was performed as described.²⁰ A semiquantita-

Table 1. Primers and PCR Conditions

Primer	Position AH007803	Sequence	Length (bp)	Condition
PTEN 1	2229-2379	TCTGCCATCTCTCTCTCTCTCT AGAGGAGCAGCCGCAGAAATG	151	2.0 mmol/L MgCl ₂ , 10% DMSO
PTEN 2	10242-10412	TTTCAGATATTTCTTTCCCTTA	171	2.5 mmol/L MgCl ₂
PTEN 3	18382-18528	TAATTTCAAATGTTAGCTCAT AAGATATTTGCAAGCATACAA	147	2.5 mmol/L MgCl ₂
PTEN 4	24099-24248	GTTTGTTAGTATTAGTACTTT ACAACATAGTACAGTACATTCT	150	2.5 mmol/L MgCl ₂
PTEN 5a	26126-26283	TATTCTGAGGTTATCTTTTA CTTCCAGCTTTACAGTGAA	158	2.5 mmol/L MgCl ₂ , 10% DMSO
PTEN 5b	26232-26417	GCTAAGTGAAGATGACAATCA AGGAAAAACATCAAAAAATAA	186	2.5 mmol/L MgCl ₂ , 10% DMSO
PTEN 6	32123-32324	TTGGCTTCTCTTTTTTTCTG ACATGGAAGGATGAGAATTTCT	202	2.5 mmol/L MgCl ₂
PTEN 7	37865-38093	CCTGTGAAATAACTGGTATG CTCCCAATGAAAGTAAAGTACA	229	—
PTEN 8b	40894-41137	TAAATATGTCATTTCTTTTCT CTTTGCTTTATTTGCTTTGT	244	—
PTEN 8b	41084-41200	GTGCAGATAATGACAAGGAATA ACACATCACATACATAAAGTC	117	—
PTEN 9	45308-45549	TTCATTTAAATTTCTTTCT TGGTGTTTTATCCCTCTTGAT	242	2 mmol/L MgCl ₂

DMSO, dimethylsulfoxide.

Table 2. Clinical Data and Results

Clinical data				LOH - Analysis [§]						
No.	Sex	Age	Tumor type	CGH [†]	ICH [‡]	D10S579	AFM86	D10S2491	D10S1735	Mutation analysis
1	M	93	ins							neg
2	M	36	ins		C	*	ni	□	ni	neg
3	M	58	ins			ni	ni	□	ni	neg
4	F	81	ins							neg
5	F	26	ins			ni	ni	□	ni	neg
6	?	?	Ins			ni	ni	□	□	neg
7	M	62	ins			*	ni	*	ni	neg
8	F	22	ins							neg
9	F	59	ins		C					neg
10	F	35	ins		N/C					neg
11	F	42	ins		C	ni	ni	□	ni	neg
12	M	53	ins		C	ni	ni	□	ni	neg
13	F	52	non f	10q-						neg
14	M	61	ins, mal		C/M	*	ni	ni	■	neg
15	M	62	ins, mal		N/C	ni	□	□	□	neg
16	M	52	ins, mal		C	*	ni	ni	ni	neg
17	M	58	ins, mal	10q rg-	C/M	ni	□	■	ni	neg
18	M	56	ins, mal		C	*	ni	■	ni	neg
19	F	64	ins, mal	10q-	N/C	ni	ni	ni	*	neg
20	F	56	gluc, mal	10q-	C	ni	■	■	ni	neg
21	F	48	gluc, mal	10q rg-	C	■	ni	■	ni	neg
22	M	44	non f, mal	10q rg-	C	*	ni	■	■	neg
23	F	33	non f, mal	10q-	neg	ni	*	ni	■	Exon 6 L182F
24	M	51	non f, mal	10q-	N/C	ni	ni	ni	ni	neg
25	F	34	non f, mal	10q-	C/M					neg
26	M	53	non f, mal	10q-	C					neg
27	F	46	vip, mal		C	*	ni	*	ni	neg
28	F	59	vip, mal		C	■	■	■	■	neg
29	F	36	vip, mal		C					neg
30	M	57	vip, mal		C/M	*	ni	ni	ni	neg
31	M	63	gast, mal		C	□	□	□	ni	neg
32	M	20	ins, MEN1							neg
33	M	41	gast, MEN1		C					neg

ins, insulinoma; gluc, glucagonoma; vip, VIPoma; gast, gastrinoma; non F, non-functioning; mal, malignant
[†]10q-rg, partial 10q deletion by CGH (5)

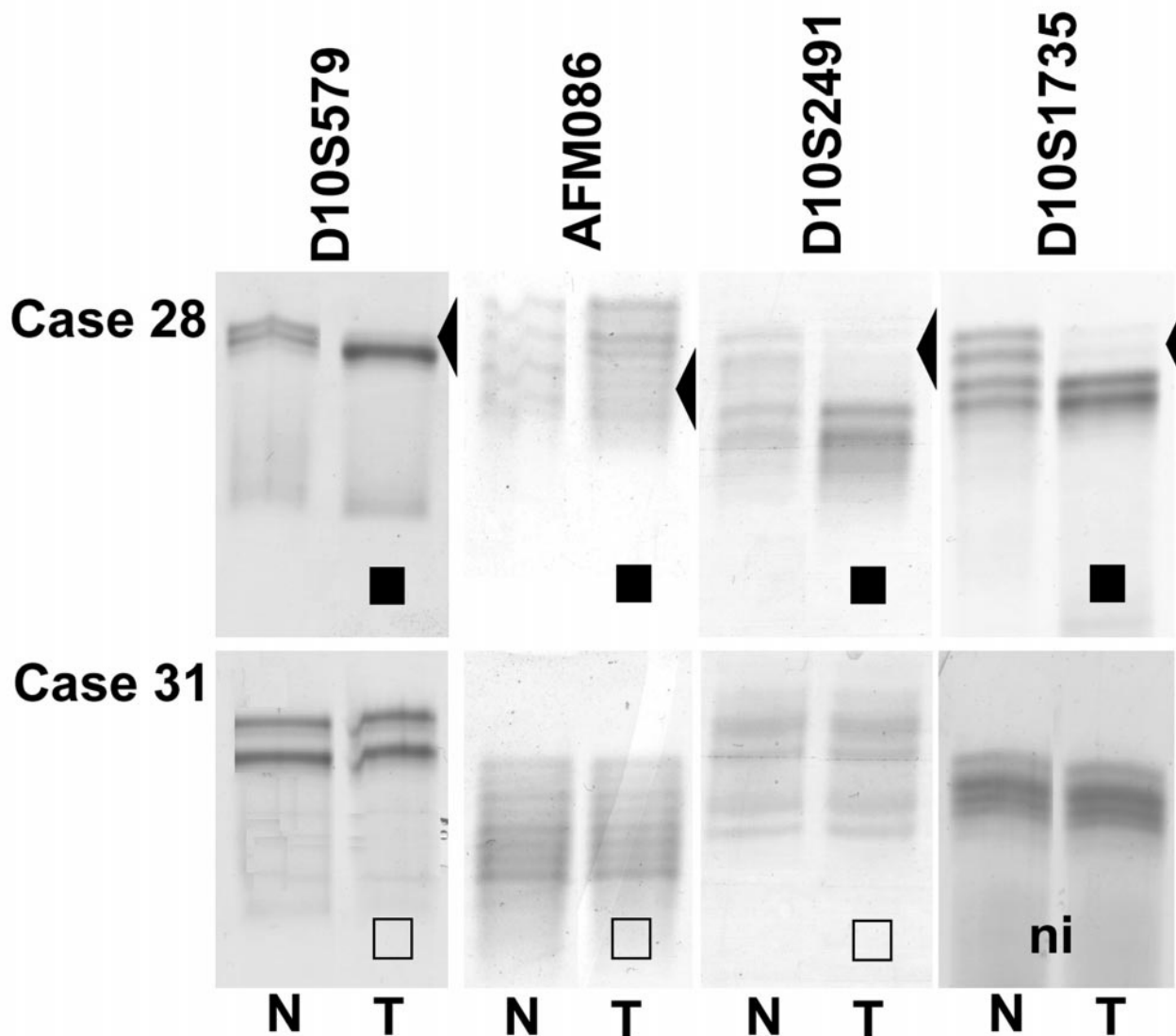


Figure 1. LOH analysis of EPT-nontumor DNA from cases 28 and 31 using microsatellite markers within and flanking *PTEN*. ■, LOH; □, ROH; ni, not informative.

Results

LOH Analysis

For 22 tumor samples, paired normal tissue was available and therefore, could be used for LOH analysis (Table 2). Sixteen of these EPTs were informative for at least one of four markers within and flanking *PTEN*. Among these 16, eight tumors exhibited loss of one allele at the 10q23 region, and eight retained heterozygosity for all of the informative markers (Table 2 and Figure 1). Case 17 showed retention of heterozygosity at AFMa086wg9 and LOH of the adjacent marker D10S2491 indicating partial loss of one *PTEN* allele. LOH at 10q23 seemed to be associated with malignant phenotype: whereas eight of 10 (80%) informative malignant and none of six informa-

tive-benign EPTs retained both 10q23 alleles ($P < 0.05$, Fischer's exact test).

Of the eight informative tumors with LOH, five have been shown by comparative genomic hybridization to have large 10q losses.

Mutation Analysis

Single-strand conformation polymorphism analysis revealed an additional band in exon 6 in one tumor (case 23, Figure 2). Sequencing of exon 6 confirmed that the aberrant single-strand conformation polymorphism band reflected a sequence variant (546A>T) which was absent in the corresponding germline DNA. This 546 A>T tran-

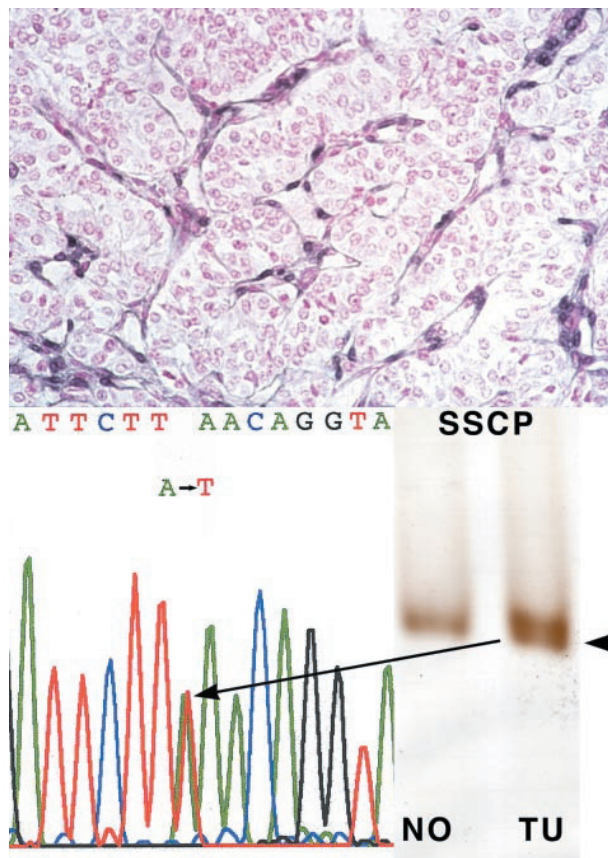


Figure 2. Case 23 EPT with somatic *PTEN* mutation, 546A>T and loss of wild-type allele, resulting in negative PTEN immunoreactivity. **Top:** Negative PTEN immunostaining; note internal positive control of strongly staining neo-vessels. Single-strand conformation polymorphism and sequencing of exon 6 reveals a somatic mutation (546A>T). Note that the chromatogram shows the mutation as an apparent heterozygote although by both immunohistochemical and LOH analysis, this tumor has loss one allele and is mutant in the remaining. This pseudo-heterozygote appearance is because of some admixture with DNA from contaminating normal cells.

also showed LOH at 10q23, at least involving the 3' part of *PTEN* (Table 1).

Immunohistochemistry

Twenty-four paraffin-embedded tumor samples were available for immunohistochemical analysis. Fifteen of these had adjacent normal pancreatic tissue containing the islets of Langerhans, the normal counterpart of EPTs. All of the islets showed strong immunoreactivity (++) to the antibody 6H2.1. With the exception of one case which was fixed in Bouin's solution (case 33), all normal islets exhibited homogenous predominant nuclear PTEN expression (Figure 3a). As internal positive controls, we used predominantly nuclear staining of endothelial cells (especially within neo-vessels) and cytoplasmic staining of Schwann cells in peripheral nerves (graded ++ staining). Exocrine pancreatic acini were PTEN immunostain-negative throughout and were used as internal negative controls.

immunostaining (Figure 2). This malignant, nonfunctioning EPT had a somatic *PTEN* mutation (as described above) and loss of the remaining allele (Table 2, case 23). In the remaining 23 EPTs, all showed strong PTEN expression, graded + to ++. Nineteen of these 23 (83%) tumors exhibited a predominantly cytoplasmic PTEN staining (Figure 3b and Table 2); the staining pattern of four of these 19 tumors was suggestive of PTEN localization at the cell membrane (Figure 3c). In addition, four of these 19 tumors were found to have cytoplasmic staining as well as strong nuclear PTEN staining (case 10, 15, 19, and 24; Figure 3d). We found no association between staining pattern and clinical behavior in this relatively small series.

Discussion

We have detected a novel somatic mutation in exon 6 of *PTEN*. The nucleotide change 546A>T results in an amino acid change at codon 182, L182F. As expected for a tumor suppressor gene, this mutation was accompanied by LOH of the wild-type allele. The structural two-hits in a malignant nonfunctioning EPT (case 23) resulted in loss of immunoreactivity to the monoclonal anti-PTEN antibody recognizing a C-terminal epitope. One would have expected that loss of one allele with a missense mutation in the remaining allele would result in a full-length protein, with subsequent decreased PTEN immunoreactivity. Our observations of complete loss of immunoreactivity may be explained by decreased transcription or translation, increased degradation of the mutant protein, or conformational change in the C-terminal 100 amino acids induced by the missense mutation. Most likely, the missense mutation results in decreased transcript stability. In sum, somatic intragenic *PTEN* mutations do occur in a small percentage, one of 33 (3%), of EPTs. The patient with this widely invasive nonfunctioning EPT underwent a Whipple procedure and remains disease-free 11 years after the surgery.

Although somatic intragenic *PTEN* mutation is infrequent in EPT, we have shown that half of all informative EPTs harbor deletions of the 10q23 region, specifically involving *PTEN*. On the one hand, LOH analysis confirmed the large losses of 10q detected by comparative genomic hybridization analysis; on the other, we detected three additional malignant EPTs (cases 14, 18, and 28) with loss of the 10q23 region solely detected by PCR-based analysis of microsatellite markers. Interestingly, all of the samples that had LOH were malignant EPTs. This finding suggests that allelic loss of this region could be associated with malignant behavior. Apart from the single malignant EPT with two structural hits and no *PTEN* expression, all of the EPTs with LOH remained PTEN-immunopositive. These observations are in contrast to those made in breast cancer, thyroid neoplasia, and endometrial cancer, where loss of one *PTEN* allele is strongly associated with decreased PTEN protein level or complete loss of PTEN expression (XP Zhou and C Eng,

Explore Litigation Insights

Docket Alarm provides insights to develop a more informed litigation strategy and the peace of mind of knowing you're on top of things.

Real-Time Litigation Alerts



Keep your litigation team up-to-date with **real-time alerts** and advanced team management tools built for the enterprise, all while greatly reducing PACER spend.

Our comprehensive service means we can handle Federal, State, and Administrative courts across the country.

Advanced Docket Research



With over 230 million records, Docket Alarm's cloud-native docket research platform finds what other services can't. Coverage includes Federal, State, plus PTAB, TTAB, ITC and NLRB decisions, all in one place.

Identify arguments that have been successful in the past with full text, pinpoint searching. Link to case law cited within any court document via Fastcase.

Analytics At Your Fingertips



Learn what happened the last time a particular judge, opposing counsel or company faced cases similar to yours.

Advanced out-of-the-box PTAB and TTAB analytics are always at your fingertips.

API

Docket Alarm offers a powerful API (application programming interface) to developers that want to integrate case filings into their apps.

LAW FIRMS

Build custom dashboards for your attorneys and clients with live data direct from the court.

Automate many repetitive legal tasks like conflict checks, document management, and marketing.

FINANCIAL INSTITUTIONS

Litigation and bankruptcy checks for companies and debtors.

E-DISCOVERY AND LEGAL VENDORS

Sync your system to PACER to automate legal marketing.