

## Pancreatic neoplasms

Michael J. Levy, MD<sup>a,\*</sup>, Maurits J. Wiersema, MD<sup>b</sup>

<sup>a</sup>*Developmental Endoscopy Unit, Division of Gastroenterology and Hepatology, Mayo Clinic,  
200 First Street Southwest, Rochester, MN 55905, USA*

<sup>b</sup>*GI Consultants, 1900 Carew Street, Suite 1, Fort Wayne, IN 46805, USA*

Endoscopic ultrasound (EUS) is a highly sensitive imaging modality for identifying pancreatic neoplasms, with detection rates over 90% (Table 1) [1–8]. In most studies, EUS has been superior to transabdominal ultrasound (TUS), CT, endoscopic retrograde cholangiopancreatography (ERCP), and angiography in the detection of pancreatic tumors [1,3,9,10]. Rosch et al demonstrated greater sensitivity (99%) and specificity (100%) for detecting pancreatic tumors than TUS (sensitivity 67%, specificity 40%) and CT scan (sensitivity 77%, specificity 53%) [1]. Recent studies comparing EUS to dual-phase helical CT, MRI, and positron emission tomography (PET) have found EUS to have a greater sensitivity for identifying pancreatic neoplasms [2,4,8,11]. In another study of 34 patients with an elevated contrast angiography (CA) 19-9 and normal pancreas according to TUS and CT scan, EUS was 94% accurate in detecting a pancreatic or biliary neoplasm, with a positive and negative predictive value of 92% and 100% respectively [12]. The advantage of EUS is even greater for recognizing tumors less than 2 to 3 cm in diameter [1,4,9,13,14]. Yasuda et al found that EUS had a detection rate of 100%, ERCP 57%, TUS 29%, CT 29%, and angiography 14% for pancreatic tumors less than 2 cm [9]. Similarly, in a study by Rosch et al, the diagnostic sensitivity of EUS for detecting tumors smaller than 3 cm was 100%, compared with 57% for TUS and 68% for CT [15].

### Neuroendocrine pancreatic tumors

Neuroendocrine pancreatic tumors (NPTs) are rare, with an incidence of less than 1 tumor per 100,000 people [16]. Gastrinoma, insulinoma, and non-

---

\* Corresponding author.

E-mail address: [levy.michael@mayo.edu](mailto:levy.michael@mayo.edu) (M.J. Levy).

Table 1  
Endoscopic ultrasound detection rates of pancreatic tumors

Author/Year/Reference	Sensitivity	Specificity	Positive predictive value	Negative predictive value	Accuracy
Rosch, 1991 [1]	99%	100%	100%	97%	76%
Snady, 1992 [3]	85%	80%	89%	73%	83%
Yasuda, 1993 [7]	–	–	–	–	100%
Muller, 1994 [4]	94%	100%	–	–	96%
Baron, 1997 [5]	95%	88%	95%	88%	–
Legmann, 1998 [2]	100%	93%	–	–	–
Akahoshi, 1998 [6]	89%	97%	94%	93%	94%

functioning tumor are most common, with glucagonoma, somatostatinoma, and VIPoma less often reported. Preoperative determination of the location and extent is necessary to enable surgeons to plan the optimal surgical approach. Resection offers the only chance for cure and should be undertaken whenever possible because of the malignant potential of these tumors. Preoperative localization is also important because of the difficulty in identifying these tumors during surgery, which is the case in up to 20% of insulinomas, and as many as 50% of gastrinomas [16]. The approach to tumor localization is similar for all tumor types. Various imaging modalities are available for preoperative identification of NPTs. They include TUS, CT, selective abdominal angiography, selective venous sampling, radiolabeled octreotide (somatostatin-analog) receptor scintigraphy (SRS), intraoperative ultrasound, and most recently EUS.

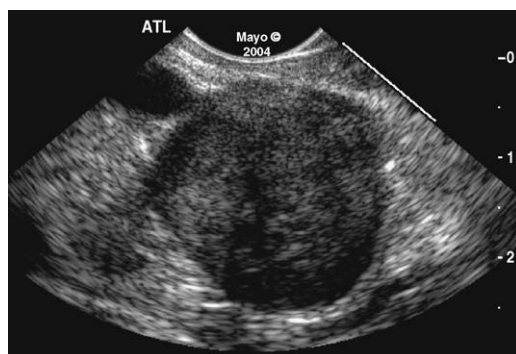Endoscopic ultrasound studies report a localization rate of approximately 77% to 93% for insulinomas [16–23]. In these same studies CT, was able to locate the tumor in only 0% to 20% of patients, and somatostatin receptor scintigraphy (SRS) was able to locate the tumor in only 12% to 14% of patients. Insulinomas have a low density of somatostatin receptors, and as a result they often go undetected by SRS. The high detection rate of EUS for insulinomas likely is explained by the fact that 99% of insulinomas are confined to the pancreas [21,24,25]. Approximately 75% to 100% of pancreatic gastrinomas are identified by EUS [16–18,21,22,26] versus 0% to 67% of duodenal gastrinomas [16,18,22]. EUS is comparable to SRS for detecting pancreatic gastrinomas, and both tests are clearly superior to CT. Even so, both techniques may miss a significant proportion of duodenal gastrinomas [16,18,22,27], which is important, given that 30% to 45% of gastrinomas are located in parapancreatic locations, most commonly the duodenal wall or lymph nodes [24]. Despite focused examination of the duodenal wall by EUS, gastrinomas in this location commonly are missed by EUS unless previously identified endoscopically [21]. Therefore, at the time of EUS, the authors initially perform a careful forward- and side-viewing exam of the duodenal wall.

The addition of fine needle aspiration (FNA) further increases the diagnostic accuracy for NPTs, with overall accuracy of EUS–FNA reported to be 75% to

modalities [28,31]. In a multi-center trial involving 37 patients with a suspected NPT undetected by TUS and CT, the sensitivity and specificity of EUS for tumor localization were 82% and 95%, respectively [1]. These tumors had a mean diameter of 1.4 cm (range 0.5 to 2.5 cm) and consisted of 31 insulinomas, 7 gastrinomas, and 1 glucagonoma. In this same study, only 27% of tumors were identified by angiography. All patients underwent surgical resection, with 36 of 37 considered cured based on clinical and laboratory parameters.

The EUS appearance of NPTs is similar regardless of the type of tumor. They typically appear as round, well-delineated, homogenous, echo-poor lesions, with a surrounding hyper-echoic rim (Fig. 1). Cystic or calcified tumors, echo-rich lesions, an echo-poor border, or echo-texture, however, are similar to surrounding pancreatic parenchyma [1,32,33]. The EUS technique for localizing these tumors is identical to that for ductal adenocarcinoma, except that a more deliberate exam may be needed to find these small lesions. The peripancreatic region also should be examined carefully, not only to search for malignant lymph nodes but also to look for primary tumors [13,34]. Parapancreatic tumors may be attached by a pedicle or completely separate from the pancreas, and they are more difficult to locate than intrapancreatic tumors [21]. As with other tumors, infiltration into adjacent organs and vessels should be evaluated. EUS-FNA helps differentiate benign parapancreatic lymph nodes from a primary NPT, a distinction that can be difficult, especially for insulinomas [17,19–21,28,35–37]. EUS appearance also may predict the malignant potential of NPTs, which can be otherwise difficult to discern in the absence of extensive local invasion or distant metastasis [37,38]. The presence of a hypo-echoic lesion with anechoic regions, an irregular central echogenic area, or pancreatic duct obstruction is indicative of malignant transformation [38]. The echogenic areas correspond with hemorrhage, necrosis, or hyaline degeneration, each of which suggests a malignant tumor [38].

Once identified, it is important to accurately describe the location of tumor(s) to facilitate surgical resection. The authors recommend describing the location relative to pancreatic and peripancreatic structures. In a step further, Gress et al



reported their experience in one patient employing EUS-guided fine needle tattooing [39]. After identifying a  $1.9 \times 0.5$  cm insulinoma, they injected 4 mL of sterile India ink into the lesion and continued to inject as the needle was withdrawn from the pancreas. The ink and tumor were identified readily at surgery performed the same day. This is a method that may facilitate operative localization of NPTs and in particular assist when enucleation or laparoscopic resection is planned for small tumors. For most patients, however, NPT marking is likely to be of no benefit, and the authors discourage doing so outside of a research protocol. In addition to the risks inherent to pancreatic EUS-FNA, injection of India ink may induce peritonitis, phlegmonous gastritis, and luminal and periluminal abscess formation, ulceration, and necrosis [40–43].

The cost-effectiveness of EUS for the preoperative localization of pancreatic endocrine tumors was demonstrated recently. Bansal et al compared the cost of performing tumor localization with and without EUS as part of the protocol, and found that the use of EUS significantly reduced the cost of preoperative staging (\$2620 versus \$4846) [32]. Savings resulted from the reduced need for angiography and venous sampling procedures and because of the reduction in surgical and anesthesia times. The cost per tumor located was \$3144 when EUS was used versus \$5628 when EUS was not employed.

Endoscopic ultrasound is an accurate technique for detecting NPTs. EUS is being used increasingly to search for sporadic NPTs and in patients with multiple endocrine neoplasia (type 1) because of its ability to identify small, previously undetected tumors [44] (Fig. 2). Although some favor its use only when non-invasive studies detect no metastases and no primary tumor is seen, the authors suggest performing EUS in all patients in whom surgery is planned. They favor this approach even when a lesion already has been identified to allow detection of unsuspected multi-focal or metastatic disease and clarify the relationship of the tumor to the main pancreatic duct. The added information obtained by EUS-FNA

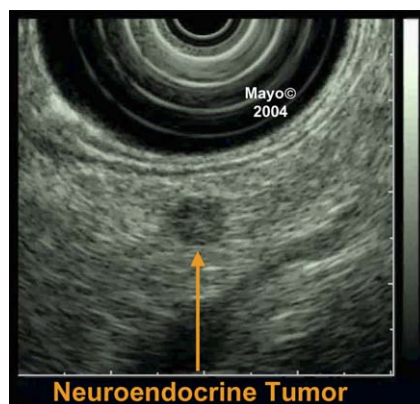


Fig. 2. Neuroendocrine pancreatic tumor. One of many small, nonfunctioning neuroendocrine tumors.

allows cytologic confirmation of the diagnosis with reduced false-positive imaging results and also allows the surgeon to plan the optimal strategy (eg, tumor enucleation versus pancreatic resection). Further study is needed, however, to determine the role, utility, and safety of EUS–FNA when noninvasive studies already have localized a tumor.

### Cystic pancreatic tumors

Widespread use of high-resolution cross-sectional imaging has led to increased detection of cystic lesions of the pancreas, which may be benign, malignant, or result from an inflammatory process. Pseudocysts are most common (80% to 90%), while cystic pancreatic tumors (CPTs) account for 10% to 20% of cystic pancreatic lesions and 1% of primary pancreatic neoplasms [45,46]. The differential also includes congenital cysts, acquired cysts, and extrapancreatic cysts. In addition, solid pancreatic tumors may undergo necrosis and cystic degeneration and be mistaken for a CPT [45]. Although accounting for a minority of lesions, CPTs are an important subgroup to identify given their often distinctive presentation, diverse pathological features, and usually indolent biological behavior. CPTs are classified broadly according to their malignant potential, which impacts prognosis and therapy. Mucinous lesions (mucinous cystic neoplasms and intraductal papillary mucinous tumors) are premalignant or malignant tumors, and surgical resection generally is recommended in operative candidates [47–49]. Nonmucinous lesions include serous cystadenomas that have a very low malignant potential, and pseudocysts, which are always benign, and generally only resected when causing symptoms or complications [47–49]. Management and outcome of patients with CPTs critically depends on early tumor detection, distinction from pseudocysts, and accurate determination of tumor type. The appropriate use of clinical, imaging, laboratory, and pathology information is essential in this regard (Table 2). Detection is important even after malignancy has developed, because certain malignant CPTs have a better prognosis than ductal adenocarcinoma and a relatively high cure rate following resection.

Table 2  
Analysis of aspirated cystic pancreatic tumor fluid — general characteristics

	Viscosity	Amylase	CA 19-9	CA 15-3	CA 72-4	CEA	Cytology
SCA	Low	Variable	Variable	Low	Low	Low	Glycogen
MCA	High	Variable	Variable	High	High	High	Mucinous
MCAC	High	Variable	Variable	High	High	High	Mucinous
IPMN	High	High	Variable	Variable	Variable	Variable	Mucinous
Pseudocyst	Low	High	Variable	Low	Low	Low	Histiocytes

Abbreviations: CA, carbohydrate antigen; CEA, carcinoembryonic antigen; IPMN, intraductal

# Explore Litigation Insights

Docket Alarm provides insights to develop a more informed litigation strategy and the peace of mind of knowing you're on top of things.

## Real-Time Litigation Alerts



Keep your litigation team up-to-date with **real-time alerts** and advanced team management tools built for the enterprise, all while greatly reducing PACER spend.

Our comprehensive service means we can handle Federal, State, and Administrative courts across the country.

## Advanced Docket Research



With over 230 million records, Docket Alarm's cloud-native docket research platform finds what other services can't. Coverage includes Federal, State, plus PTAB, TTAB, ITC and NLRB decisions, all in one place.

Identify arguments that have been successful in the past with full text, pinpoint searching. Link to case law cited within any court document via Fastcase.

## Analytics At Your Fingertips



Learn what happened the last time a particular judge, opposing counsel or company faced cases similar to yours.

Advanced out-of-the-box PTAB and TTAB analytics are always at your fingertips.

## API

Docket Alarm offers a powerful API (application programming interface) to developers that want to integrate case filings into their apps.

## LAW FIRMS

Build custom dashboards for your attorneys and clients with live data direct from the court.

Automate many repetitive legal tasks like conflict checks, document management, and marketing.

## FINANCIAL INSTITUTIONS

Litigation and bankruptcy checks for companies and debtors.

## E-DISCOVERY AND LEGAL VENDORS

Sync your system to PACER to automate legal marketing.