

Colon (Bowel)

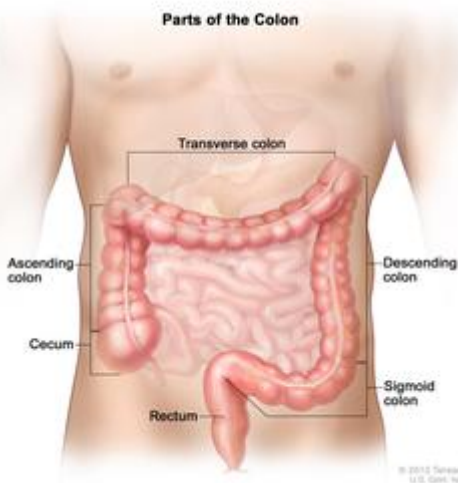


The longest part of the [large intestine](#), which is a tube-like [organ](#) connected to the [small intestine](#) at one end and the [anus](#) at the other. The colon removes water and some [nutrients](#) and [electrolytes](#) from partially digested food. The remaining material, solid waste called [stool](#), moves through the colon to the [rectum](#) and leaves the body through the anus.

PubMed Health Glossary
(Source: NIH - National Cancer Institute)

Related terms: Colonic

Part of: **Gastrointestinal Tract (GI Tract)**



Parts of the colon [National Institutes of Health](#)

Related conditions

- [Diverticulitis](#)
- [Irritable Bowel Syndrome](#)
- [Ulcerative Colitis](#)


Terms to know

[Anus](#)
The opening at the end of the large intestine where bowel contents exit the body.

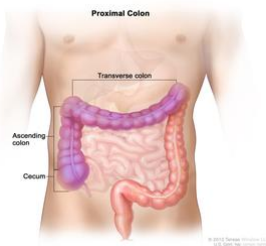[Ascending Colon](#)
The beginning part of the large intestine on the right side of the abdomen.

[Cecum](#)
A pouch that forms the beginning of the large intestine. It connects to the small intestine and the colon, which...

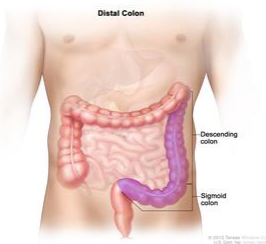
PubMed Health B



methods behind system now made it easier for



The proximal colon *National Institutes of Health*



The distal colon *National Institutes of Health*

Related conditions

- [Diverticulitis](#)
- [Irritable Bowel Syndrome](#)
- [Ulcerative Colitis](#)
- [Colon Cancer](#)
- [Rectal Cancer](#)
- [Colorectal Cancer](#)
- [Microscopic Colitis](#)
- [Hirschsprung Disease](#)
- [Constipation](#)
- [Diverticulosis](#)
- [Colon Diseases](#)
- [Anal Cancer](#)

Terms to know

[Anus](#)

The opening at the end of the digestive tract where bowel contents leave the body.

[Ascending Colon](#)

The beginning part of the colon, usually on the right side of the abdomen.

[Cecum](#)

A pouch that forms the first part of the large intestine. It connects the small intestine to the colon, which is part of the large intestine.

[Colonoscopy](#)

A test to look into the rectum and colon that uses a long, flexible, narrow tube with a light and tiny camera on the end. The tube is called a colonoscope.

[Descending Colon](#)

The part of the colon where stool is stored. It is usually located on the left side of the abdomen.

[Distal Colon](#)

The last part of the colon. The distal colon includes the descending colon (the left side of the colon) and the sigmoid colon (the S-shaped section of the colon that connects to the rectum).

[Proximal Colon](#)

The first and middle parts of the colon. The proximal colon includes the cecum (a pouch that connects the small intestine to the colon), the ascending colon (the right side of the colon), and the transverse colon (the part of the colon that goes across the body between the right and left sides of the colon).

[Rectum](#)

The last several inches of the large intestine closest to the anus.

[Sigmoid Colon](#)

The S-shaped section of the colon that connects to the rectum.

[Transverse Colon](#)

The part of the colon that goes across the abdomen from right to left.