

Low-concentration Homogenized Castor Oil Eye Drops for Noninflamed Obstructive Meibomian Gland Dysfunction

Eiki Goto, MD,^{1,2} Jun Shimazaki, MD,¹ Yu Monden, MD,³ Yoji Takano, MD,^{1,2} Yukiko Yagi,¹ Shigeto Shimmura, MD,^{1,2} Kazuo Tsubota, MD^{1,2}

Objective: We developed low-concentration homogenized castor oil eye drops for the treatment of patients with noninflamed obstructive meibomian gland dysfunction (MGD), a major cause of lipid-deficiency dry eye, and assessed the safety, stability, and efficacy of the eye drops.

Design: Randomized, double-masked, placebo-controlled crossover clinical trial.

Participants: Forty eyes of 20 patients with noninflamed MGD.

Methods: After a preliminary study of eye drops containing castor oil, 2% castor oil and 5% polyoxyethylene castor oil (emulsifier) were mixed to formulate homogenized oil eye drops. The patients were assigned randomly to receive oil eye drops or placebo six times daily for 2 periods of 2 weeks each.

Main Outcome Measures: At the end of each treatment period, we assessed symptoms, tear interference grade, tear evaporation, fluorescein and rose bengal scores, tear break-up time (BUT), and meibomian gland orifice obstruction. Safety and stability tests were also performed.

Results: Symptom scores, tear interference grade, tear evaporation test results, rose bengal scores, tear BUT, and orifice obstruction scores after the oil eye drop period showed significant improvement compared with the results after the placebo period. No complications attributable to the eye drops were observed. The oil eye drops were stable when stored at 4°C.

Conclusions: The results indicate that castor oil eye drops are effective and safe in the treatment of MGD. The possible mechanisms of this treatment are improvement of tear stability as a result of lipid spreading, ease of meibum expression, prevention of tear evaporation, and the lubricating effect of the oil eye drops. *Ophthalmology* 2002;109:2030–2035 © 2002 by the American Academy of Ophthalmology, Inc.

Meibomian glands secrete lipids into tears, and the lipids expand to form the oily precocular tear film layer that is responsible for preventing excessive evaporation of tears while also providing a barrier function at the lid margin, lubrication during blinking, and producing a smooth optical surface.^{1–5} Noninflamed obstructive meibomian gland dysfunction (MGD) is the major cause of lipid tear deficiency or evaporative dry eye and recently has attracted attention as

a cause of ocular discomfort.^{6–8} Meibomian gland dysfunction causes a decreased lipid supply, which in turn leads to increased tear evaporation, decreased tear stability, loss of lubrication, and damage to ocular surface epithelium, resulting in symptoms related to dry eye.^{7–9} The conventional treatment for blepharitis and MGD includes warm compresses, lid hygiene, and topical or systemic medication.^{5,10–12} Nevertheless, long-term compliance with conventional therapy is often insufficient and thus results in only limited relief of symptoms. Another possible approach is direct supplementation with oil as the deficient component. Lipid-containing eye drops designed to simulate natural tears previously have been reported to be an effective treatment for dry eye, but they have not been accepted generally.^{13,14} Because high-concentration oil eye drops and ointments are viscous and cause blurred vision, resulting in decreased patient satisfaction, we conducted a preliminary assessment of the efficacy of a low-concentration castor oil mixture, and in this study assessed the efficacy, safety, and stability of low-concentration and homogenized oil eye drops.

Originally received: October 29, 2001.

Accepted: March 22, 2002.

Manuscript no. 210908.

¹ Department of Ophthalmology, Tokyo Dental College, Chiba, Japan.

² Department of Ophthalmology, Keio University School of Medicine, Tokyo, Japan.

³ Department of Ophthalmology, Kurume University School of Medicine, Kurume, Japan.

Supported by grants from the Japanese Ministry of Education and Science, Tokyo, Japan; Medical School Faculty and Alumni Grants of Keio University Medical Science Fund, Tokyo, Japan; Hightech Research Center at Tokyo Dental College, Chiba, Japan; and Nihon Tenganyaku Kenkyusho Co. Ltd., Nagoya, Japan.

Authors Eiki Goto, MD, Kazuo Tsubota, MD, and Nihon Tenganyaku Kenkyusho Co., Ltd., are in the process of obtaining a Japanese patent on the eye drops described herein and their clinical application.

Correspondence and reprint requests to Kazuo Tsubota, MD, Department of Ophthalmology, Tokyo Dental College, 5-11-13 Sugano, Ichikawa-shi, Chiba, Japan 272-8513. E-mail: eikigoto@nifty.com.

Materials and Methods

Preliminary Study to Choose Oil

We used seven oil ingredients permitted as additives for eye drops and ointments in Japan to formulate a low-concentration mixture

Table 1. Results of Preliminary Study using Castor Oil Mixture for Noninflamed Obstructive Meibomian Gland Dysfunction (Mean \pm Standard Deviation)

Examination	Before*	After [†]	P Value
Face score (1–9)	7.5 \pm 1.6	5.3 \pm 1.4 [‡]	0.01
Tear evaporation rates ($\times 10^{-7}$ g/second)	30 \pm 9.0	22 \pm 11 [‡]	0.02
Fluorescein score (0–9)	1.6 \pm 1.5	0.20 \pm 0.60 [‡]	0.005
Rose bengal score (0–9)	1.2 \pm 1.4	0.50 \pm 0.76	0.2
Tear break-up time (sec)	3.4 \pm 2.4	9.0 \pm 3.6 [‡]	0.002
Schirmer's test value (mm)	18 \pm 14	16 \pm 12	0.6

Data were analyzed by Wilcoxon's signed rank test for nonparametric paired data. A *P* value of <0.05 was accepted as statistically significant.

* Result before use of castor oil mixture.

[†] Result after 2 weeks of application of castor oil mixture.

[‡] Statistically significant.

with preservative-free artificial tears (Soft Santear; Santen Pharmaceutical Co, Ltd., Osaka, Japan) and tested them on normal and dry eye volunteers.¹⁵ Because the subjects reported that the castor oil (Astra Japan, Osaka, Japan) mixture eye drops were the most comfortable, this mixture was formulated for use in a preliminary trial and applied to 8 MGD patients 6 times daily for 2 weeks. The ocular surface and tear function were examined and compared before and after application. The examinations are described in detail in a later section. As shown in Table 1, the face score, fluorescein score, tear break-up time (BUT), and tear evaporation rates improved significantly. The mixture was simple to formulate, but being made from only hydrophobic oil, it may not spread readily over the ocular surface. We therefore decided to formulate homogenized oil eye drops with castor oil.

Formulation, Safety, and Stability of Low-concentration Homogenized Oil Eye Drops

To formulate low-concentration and homogenized oil eye drops (oil eye drops), 2% castor oil lubricant (castor oil; Yoshida Pharmaceutical Co., Tokyo, Japan), 5% polyoxyethylene castor oil (POE castor oil [emulsifier]; Sigma, St. Louis, MO), 0.3% sodium chloride, 0.15% potassium chloride, and 0.5% boric acid were stirred into distilled water under sterile conditions. The concentration of castor oil in the preliminary study was changed to formulate an emulsion. The characteristics of the eye drops were: lucent, odorless, and low viscosity. The pH of the eye drops was 7.0, and their osmolarity was 260 mOsm/kg H₂O. Bacterial and fungal cultures of the remaining unused eye drops were performed at the end of therapy under the usual conditions at room temperature.¹⁶ The stability of the eye drops was assessed by testing for 4 weeks at 60°C and 4°C. Stress testing (testing at 60°C for 4 weeks) was performed instead of accelerated testing (testing at 40°C for 6 months) for the eye drops.¹⁷ In these tests, the pH of the eye drops was measured, and the volunteers were checked for any irritation that might have been caused by administering the eye drops. The samples stored at 4°C remained stable at pH 7.0 for 4 weeks and did not cause irritation, whereas the pH value of the samples stored at 60°C changed to 5.8 and caused irritation.

Subjects

We examined a consecutive series of 20 patients (40 eyes) with MGD whose symptoms had not improved sufficiently despite

conventional treatment, such as by lid hygiene and topical therapy with artificial tears, antibiotics, and corticosteroids or systemic antibiotics. Both eyes of patients were included. The participants consisted of 7 males and 13 females (52.1 \pm 11.0 years) with MGD. Nine patients had a Schirmer's test value of less than 5 mm, indicating aqueous tear deficiency.^{9,18} Four patients of the aqueous tear deficiency group were diagnosed with Sjögren's syndrome according to aqueous tear deficiency.¹⁹ Eyes with anterior blepharitis of more than moderate severity, infectious conjunctivitis, MGD with acute inflammation, and eyes with excessive expression of meibum (seborrhic MGD) were excluded from the study. No patients used contact lenses.

Criteria for Meibomian Gland Dysfunction

Criteria for the diagnosis of MGD were: presence of meibomian gland dropout, poor meibum expression, and lack of active inflammation.^{7–9} Transillumination examination (meibography) with a fiber-optic device (L-3920; Inami Co., Tokyo, Japan) was performed.²⁰ Visible loss of meibomian gland structure (gland dropout) was observed during meibography and was considered evidence of MGD, because this finding was reported to be a good parameter for MGD-associated ocular surface changes.^{7–9} The degree of meibomian gland dropout was scored as described previously^{7–9}: grade 0, no gland dropout; grade 1, gland dropout in less than half of the inferior tarsus; and grade 2, gland dropout in more than half of the inferior tarsus.

To assess meibum expression and meibomian gland orifice obstruction, digital pressure was applied on the upper tarsus, and the degree of ease of expression of meibomian secretions (meibum) was evaluated semiquantitatively as follows: grade 0, clear meibum easily expressed; grade 1, cloudy meibum expressed with mild pressure; grade 2, cloudy meibum expressed with more than moderate pressure; and grade 3, meibum could not be expressed even with strong pressure.^{7,9} Patients with a meibography score of grade 1 or 2 and meibomian gland orifice obstruction score of 2 or 3 were diagnosed as having MGD in this study.

Assessment of Symptoms, Tears, Ocular Surface, and Meibomian Glands

A questionnaire on overall comfort, complaints, and complications was administered by using a face score card that showed nine faces, each with a different expression.¹⁶ For example, the saddest face (scored as 9) described severe symptoms and irritation of the ocular surface, and the happiest face (scored as 1) represented no irritation of the ocular surface. This face score was used to assess patient sensation of lubrication and smoothness during blinking in this study.

Tear interference images were assessed using a DR-1 camera (Kowa, Ltd., Nagoya, Japan) at $\times 12$ magnification based on the grading previously reported: grade 1, somewhat gray color, uniform distribution; grade 2, somewhat gray color, nonuniform distribution; grade 3, a few colors, nonuniform distribution; grade 4, many colors, nonuniform distribution; grade 5, corneal surface partially exposed.^{21,22} Tear evaporation during normal blinking was measured by the method previously reported.²³ The evaporation rate at 40% ambient humidity was used as a representative value.

The ocular surface was examined by the double staining method. A 2- μ l volume of preservative-free solution consisting of 1% fluorescein and 1% rose bengal dye was applied to the conjunctival sac. The intensity of the rose bengal staining of the cornea and conjunctiva was recorded, with a maximum score of 9. Fluorescein staining of the cornea was also rated from 0 to 9. Tear BUT was measured three times, and the measurements were av-

Table 2. Schedule of Examinations in Crossover Study of Castor Oil Eye Drops for Noninflamed Obstructive Meibomian Gland Dysfunction

	Week			
	0	2	4	6
Group 1	Wash-out Period Began	Beginning of Study	Patients Switched Eye Drops	Completion of Study
Group 2	AT	Oil eye drop* usage began	Switched to placebo†	Completed
	AT	Placebo† usage began	Switched to oil eye drops*	Completed

AT = preservative-free artificial tear.

* Low-concentration homogenized castor oil eye drops.

† Placebo eye drops.

Groups 1 and 2 were divided randomly by a controller (YY). Participants used AT for 2 weeks during the washout period, used oil eye drops or placebo for 2 weeks, and then switched eye drops for the next 2 weeks. Examinations were performed at the end of each 2-week period of treatment.

eraged.²⁴ Schirmer's test was performed to measure tear secretion.^{18,25} Assessment of meibum expression and meibomian gland orifice obstruction was recorded as described above in the inclusion criteria section.^{7,9}

Study Design

A randomized, prospective, double-blind, placebo-controlled crossover clinical study was performed after a 2-week wash-out period with preservative-free artificial tears (Soft Santear).²⁶ During the 2 periods of 2 weeks each, the patients were assigned randomly to receive oil eye drops or placebo eye drops six times daily (Table 2). We used normal saline solution as the placebo eye drops. At the end of each treatment period, i.e. the oil eye drop period and the placebo period the following examinations described below were performed.

The examinations were carried out in the following order to avoid the influence of one procedure on another: subjective face scores,¹⁶ tear interference grading (DR-1),²² tear evaporation test,²³ fluorescein and rose bengal vital staining BUT measurement and assessment of meibomian gland orifice obstruction.^{7-9,16,24,25} When the results of the oil eye drop period were better than those of the placebo period, the use of the oil eye drops was judged an improvement. Schirmer's test was not performed during the study period to avoid any influence on the tear evaporation test, which is sensitive to ocular surface damage. Informed consent was obtained from all subjects. Institutional Review Board or Ethics Committee approval was not required for this study.

Statistical Analysis

All data are presented as means \pm standard deviation. Both eyes of each patient were studied separately. Symptoms and findings at the end of each treatment period, the oil eye drop period and the placebo period, were compared and analyzed by Wilcoxon's signed rank test for nonparametric paired data. A *P* value of less than 0.05 was accepted as statistically significant.

Results

Figures 1 and 2 show results from representative case with tear interference images, tear break-up, and rose bengal staining at the end of the placebo period (Fig 1) and at the end of oil eye drop period (Fig 2). Each result shows improvement from the oil eye drop period compared with the placebo period.

The results at the end of placebo period and oil eye drop period are shown in Table 3. Compared with the placebo period, the

subjective face score improved during the oil eye drop period from 6.7 ± 1.6 to 5.5 ± 1.8 ($P = 0.004$), along with the improvement of the other tear examinations. Tear interference grade decreased from 3.1 ± 0.71 to 2.0 ± 0.77 ($P < 0.0001$), tear evaporation rates during normal blinking decreased from 13 ± 6.2 (10^{-7} g/second) to 11 ± 7.5 (10^{-7} g/second; $P = 0.01$), and tear BUT was prolonged from 4.6 ± 2.8 seconds to 12 ± 3.5 seconds ($P < 0.0001$). The improvement of the subjective score also was accompanied by improvements of the rose bengal staining score (from 2.2 ± 0.85 to 1.4 ± 1.3 ; $P = 0.007$) and the meibomian gland orifice obstruction score (from 2.2 ± 0.38 to 1.6 ± 0.63 ; $P = 0.002$), but not accompanied by the improvement of the fluorescein staining score (from 0.4 ± 0.81 to 0.13 ± 0.33 ; $P = 0.06$).

Results of these improvements between the MGD without aqueous tear deficiency group ($n = 11$) and the MGD with aqueous tear deficiency group ($n = 9$) showed no statistically significant difference. Administration of the oil eye drops was well tolerated, and none of the subjects reported irritation or severe blurring. None of the collected samples tested positive for bacteria or fungi. Blinding among participants, persons performing the intervention, outcome assessors, and data analyses were performed entirely by protocol.

Discussion

This study demonstrated a clear benefit of using low-concentration homogenized oil eye drops for the treatment of MGD. Because MGD is a major cause of ocular irritation, symptomatic relief is an essential aspect of treatment. The improvement in symptoms was accompanied by improvement of objective findings, including tear interference image, tear evaporation, tear BUT, rose bengal staining, and meibomian gland orifice obstruction. The improvements were attributed to the effects of the oil eye drops because all patients used eye drops in a double-blind protocol. The eye drops were stable and well tolerated, and they did not cause irritation or blurred vision at room temperature. By using low-concentration oil, we succeeded in avoiding the usual complications of oil administration, such as blurred vision and a viscous sensation.

To supplement the missing tear lipid in MGD, we used POE castor oil to solubilize the castor oil in distilled water in a low concentration.²⁷ It has been reported that a hydrophilic lipid is required to enable oil to spread over the human tear aqueous layer and that polar phospholipids exist as a hydrophilic lipid in tears.^{2-4,27} The POE castor oil is a derivative of castor oil, a polar lipid having a hydrophilic

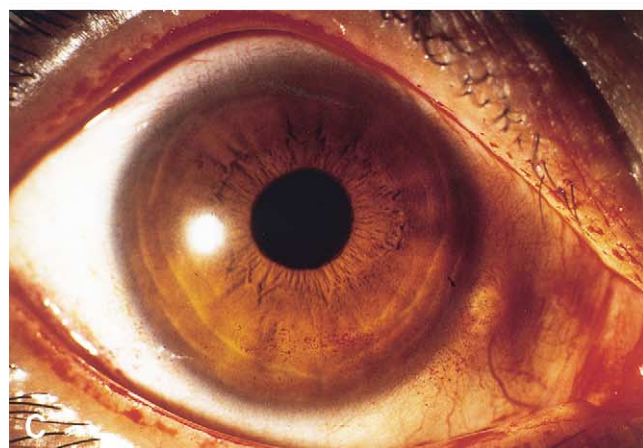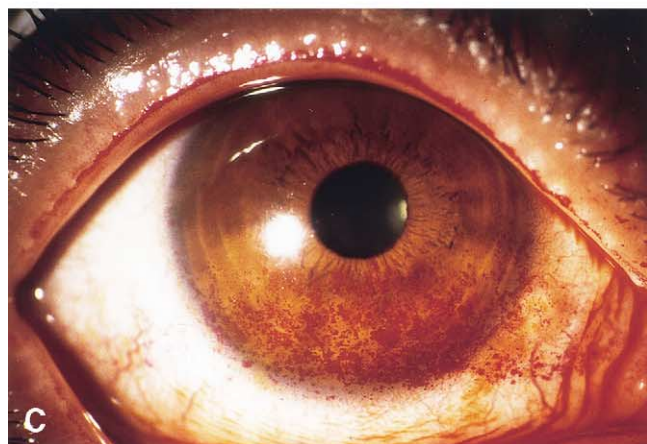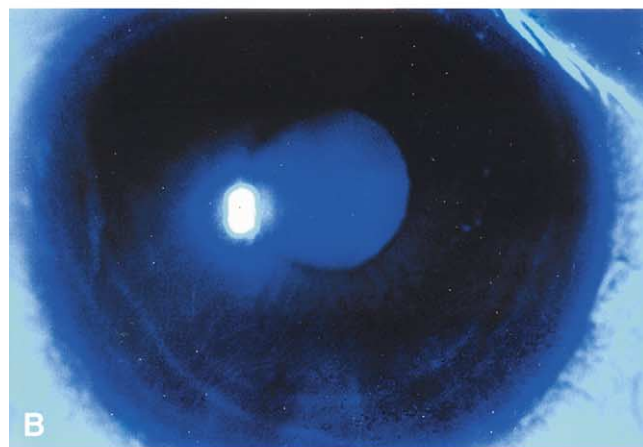
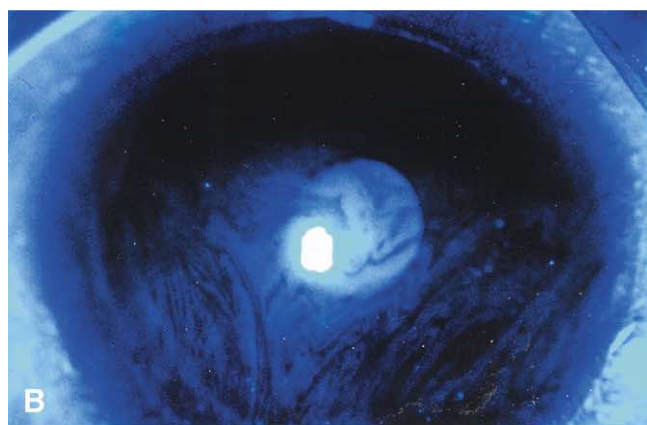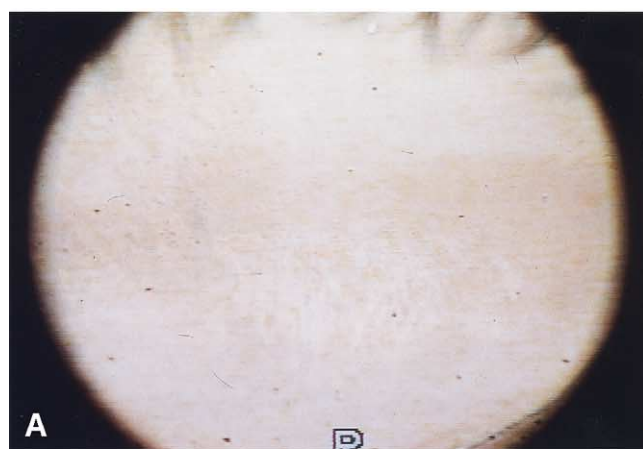
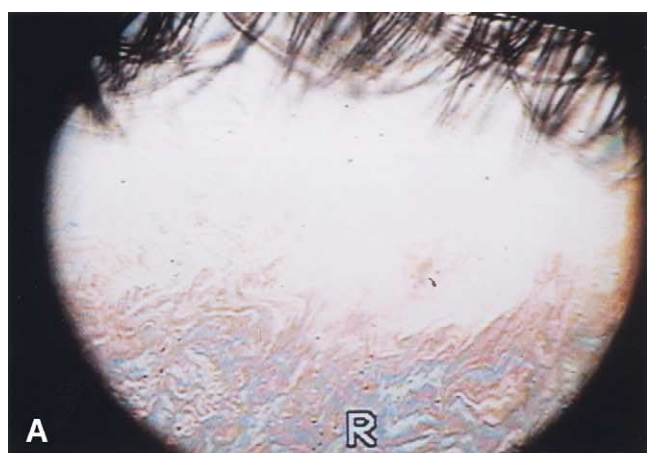


Figure 1. Tear interference image, tear break-up, and rose bengal staining of the representative case at the end of the placebo period. **A**, The tear interference image shows a few colors and a nonuniform pattern. **B**, **C**, Slit-lamp photographs stained by fluorescein and rose bengal were taken immediately after eye opening. Note the remarkable tear break-up (**B**) and rose bengal staining of the ocular surface between the palpebral fissure (**C**).

Figure 2. Tear interference image, tear break-up, and rose bengal staining of the same case as in Figure 1 at the end of oil eyedrop period. **A**, The tear interference shows a somewhat gray color and more uniform distribution. **B**, **C**, Slit-lamp photographs stained by fluorescein and rose bengal were taken immediately after eye opening. Tear break-up cannot be seen, and rose bengal staining was decreased. Figures 1B and 2B were enhanced digitally to show tear break-up using Adobe Photoshop (Adobe Systems Inc., San Jose, CA) from original photographs at brightness -40 and contrast $+70$. The reflex from the central cornea is the result of the digital enhancement.

and a hydrophobic group, which is considered to be an ideal oil for artificial tears. Because the castor oil can spread over the ocular surface, it is expected to make the tear more stable, to decrease tear evaporation, and to decrease friction between the lid and ocular surface.²⁸

Table 3. Results of Crossover Study during Placebo and Oil Eye Drop Periods for the Treatment of Noninflamed Obstructive Meibomian Gland Dysfunction (Mean \pm Standard Deviation)

Examination	Placebo Period*	Oil Eye Drop Period†	P Value‡
Face score (1–9)	6.7 \pm 1.6	5.5 \pm 1.8§	0.004
Tear interference grading (1–5)	3.1 \pm 0.71	2.0 \pm 0.77§	<0.0001
Tear evaporation rates ($\times 10^{-7}$ g/second)	13 \pm 6.2	11 \pm 7.5§	0.01
Fluorescein score (0–9)	0.40 \pm 0.81	0.13 \pm 0.33	0.06
Rose bengal score (0–9)	2.2 \pm 0.85	1.4 \pm 1.3§	0.007
BUT (sec)	4.6 \pm 2.8	12 \pm 3.5§	<0.0001
Orifice obstruction (0–3)	2.2 \pm 0.38	1.6 \pm 0.63§	0.002

BUT tear break-up time.

* Placebo eye drops.

† Low-concentration homogenized castor oil eye drops.

‡ Data were analyzed by Wilcoxon's signed rank test for nonparametric paired data. P value was determined between placebo and oil eye drop period. A P value of <0.05 was statistically significant.

§ Statistically significant.

|| Meibomian gland orifice obstruction score.

Both castor oil and POE castor oil are commercially available, are inexpensive, and have been proven to have minimal topical toxicity for the eye.^{15,28}

It was surprising to us that only a minimal amount of castor oil changed the ocular surface abnormality a great deal. Moreover, there was evidence that tears over the ocular surface were stabilized based on the improved tear interference image and increase of tear BUT. The tear interference pattern significantly showed a more uniform pattern of spreading of the lipid film layer after administration of the castor oil eye drops than with administration of the placebo.^{21,22} Even though the amount of castor oil was minimal, the oil eye drops were well homogenized in the tear lipid layer and later spread to form a more stable tear lipid layer and to improve, the ocular surface condition (Figs 1A and 2A).^{21,22,29}

There is a concern for the clinical application of castor oil eye drops because of their limited shelf life stability.¹⁷ It is expected that oil quality may change during storage room temperature and may be an obstacle for clinical application. When we stored the castor oil at 4°C for 4 weeks, the oil maintained stability and was well preserved. Moreover, it did not cause any irritation to the volunteers. However, after storage of the castor oil eye drops at 60°C for 4 weeks, the pH changed to 5.8 and caused slight irritation to the patients. Castor oil itself is a very effective treatment for ocular surface diseases, but the storage method should be considered before broad clinical application because of the instability of the oil at higher temperatures.

In conclusion, we have documented a beneficial effect of castor oil for the treatment of ocular surface disorders with MGD. Although the concept of administering oily eye drops has not been considered seriously, the application of castor

oil eye drops should be considered more for the ideal artificial tears. Theoretically, patients with aqueous tear deficiency can benefit from the application of these artificial tears because MGD needs to be supplemented by oil or some other ingredient that can stabilize the ocular surface, decrease tear evaporation, and decrease friction between the lid and ocular surface. Based on study, it is necessary to develop a means of maintaining the stability of artificial tears with castor oil in rooms with higher temperatures; however, this randomized double-blind study clearly shows the benefit of the addition of castor oil to artificial tears.

References

- Mishima S, Maurice DM. The oily layer of the tear film and evaporation from the corneal surface. *Exp Eye Res* 1961;1:39–45.
- Holly FJ. Tear film physiology. *Am J Optom Physiol Opt* 1980;57:252–7.
- Tiffany JM. The role of meibomian secretion in the tears. *Trans Ophthalmol Soc U K* 1985;104:396–401.
- Tiffany JM. The lipid secretion of the meibomian glands. *Adv Lipid Res* 1987;22:1–62.
- Driver PJ, Lemp MA. Meibomian gland dysfunction. *Surv Ophthalmol* 1996;40:343–67.
- Lemp MA. Report of the National Eye Institute/Industry Workshop on Clinical Trials in Dry Eyes. *CLAO J* 1995;21:221–32.
- Shimazaki J, Sakata M, Tsubota K. Ocular surface changes and discomfort in patients with meibomian gland dysfunction. *Arch Ophthalmol* 1995;113:1266–70.
- Lee SH, Tseng SCG. Rose bengal staining and cytologic characteristics associated with lipid tear deficiency. *Am J Ophthalmol* 1997;124:736–50.
- Shimazaki J, Goto E, Ono M, et al. Meibomian gland dysfunction in patients with Sjögren syndrome. *Ophthalmology* 1998;105:1485–8.
- Key JE. A comparative study of eyelid cleaning regimens in chronic blepharitis. *CLAO J* 1996;22:209–12.
- Korb DR, Greiner JV. Increase in tear film lipid layer thickness following treatment of meibomian gland dysfunction. In: Sullivan DA, ed. *Lacrimal Gland, Tear Film, and Dry Eye Syndromes*. New York: Plenum Press, 1994;293–8.
- Smith RE, Flowers CW Jr. Chronic blepharitis: a review. *CLAO J* 1995;21:200–7.
- Rieger G. Lipid-containing eye drops: a step closer to natural tears. *Ophthalmologica* 1990;201:206–12.
- Tiffany JM. Lipid-containing eye drops [letter]. *Ophthalmologica* 1991;203:47–9.
- Japanese Pharmaceutical Excipients 1993. Tokyo: Yakuji Nippo, 1994; 109.
- Tsubota K, Goto E, Fujita H, et al. Treatment of dry eye by autologous serum application in Sjögren's syndrome. *Br J Ophthalmol* 1999;83:390–5.
- Awata T. Stability of The Eye Drops. In: Ohashi Y, ed. *The Eye Drops*. Tokyo: Medical View Co, 1996;15–23.
- Xu KP, Yagi Y, Toda I, Tsubota K. Tear function index. A new measure of dry eye. *Arch Ophthalmol* 1995;113:84–8.
- Fox RI, Robinson CA, Curd JG, et al. Sjögren's syndrome. Proposed criteria for classification. *Arthritis Rheum* 1986;29:577–85.
- Robin JB, Jester JV, Nobe J, et al. In vivo transillumination biomicroscopy and photography of meibomian gland dysfunction. A clinical study. *Ophthalmology* 1985;92:1423–6.

Explore Litigation Insights

Docket Alarm provides insights to develop a more informed litigation strategy and the peace of mind of knowing you're on top of things.

Real-Time Litigation Alerts



Keep your litigation team up-to-date with **real-time alerts** and advanced team management tools built for the enterprise, all while greatly reducing PACER spend.

Our comprehensive service means we can handle Federal, State, and Administrative courts across the country.

Advanced Docket Research



With over 230 million records, Docket Alarm's cloud-native docket research platform finds what other services can't. Coverage includes Federal, State, plus PTAB, TTAB, ITC and NLRB decisions, all in one place.

Identify arguments that have been successful in the past with full text, pinpoint searching. Link to case law cited within any court document via Fastcase.

Analytics At Your Fingertips



Learn what happened the last time a particular judge, opposing counsel or company faced cases similar to yours.

Advanced out-of-the-box PTAB and TTAB analytics are always at your fingertips.

API

Docket Alarm offers a powerful API (application programming interface) to developers that want to integrate case filings into their apps.

LAW FIRMS

Build custom dashboards for your attorneys and clients with live data direct from the court.

Automate many repetitive legal tasks like conflict checks, document management, and marketing.

FINANCIAL INSTITUTIONS

Litigation and bankruptcy checks for companies and debtors.

E-DISCOVERY AND LEGAL VENDORS

Sync your system to PACER to automate legal marketing.