

The Diagnosis and Management of Dry Eye

A Twenty-five-Year Review

Stephen C. Pflugfelder, M.D., Abraham Solomon, M.D., and
Michael E. Stern, Ph.D.

Purpose. To review the advances in the diagnosis, pathogenesis, and management of dry eye disease in the past 25 years. **Methods.** Literature review. **Results.** The precorneal tear film is a hydrated mucus gel that contains soluble antimicrobial proteins and growth factors that protect and support the ocular surface. The final common pathway in dry eye is a perturbation of the integrated ocular surface/lacrimal gland reflex unit. Diagnostic tests evaluating tear composition and clearance appear to show stronger correlation with the severity of ocular irritation symptoms and keratoconjunctivitis sicca (KCS) than the conventional Schirmer tests. KCS is a condition of abnormal differentiation and mucus production by the ocular surface epithelium that results in a poorly lubricated, abnormally permeable ocular surface that has increased susceptibility to environmental insults. Chronic subclinical ocular surface inflammation appears to play a key role in the pathogenesis of KCS. New therapeutic strategies are aimed at reducing the ocular surface inflammation of dry eye disease. **Conclusions.** There has been a tremendous increase in knowledge regarding dry eye disease in the past 25 years that has resulted in improved diagnostic classification and new targeted therapies.

Key Words: Dry eye—Tear film—Keratoconjunctivitis sicca—Meibomian gland disease.

Perhaps there is no other area in the field of Cornea and External Disease where more advances have been made in the past 25 years than in the diagnosis, pathogenesis, and treatment of dry eye and tear film disorders. This article will review the major advances in this area.

TEAR FILM STRUCTURE AND COMPOSITION

The precorneal tear film traditionally was reported to consist of three separate layers: mucus, water, and oil. Imaging studies per-

Submitted February 8, 2000. Revision received May 22, 2000. Accepted May 30, 2000.

From the Ocular Surface and Tear Center (S.C.P., A.S.), Bascom Palmer Eye Institute, Department of Ophthalmology, University of Miami School of Medicine, Miami, Florida; and Allergan, Inc. (M.E.S.), Irvine, California, U.S.A.

Supported in part by Public Health Service Research Grant EY11915, Department of Health and Human Services, National Eye Institute, Bethesda Maryland, an unrestricted grant from Research to Prevent Blindness and the Drs. David and Maureen Smith Ocular Surface and Tear Research Fund.

Address correspondence and reprint requests to Dr. Stephen C. Pflugfelder, Bascom Palmer Eye Institute, 900 N.W. 17th Street, Miami, FL 33136, U.S.A. E-mail: spflugfelder@bpei.med.miami.edu

formed in rodents and humans indicate that the mucus, protein, and aqueous components in the precorneal tear film combine to form a hydrated gel (Fig. 1).¹⁻³ The composition of this mucus gel has not been firmly established but appears to consist of a mixture of soluble and gel-forming mucins that are produced by the lacrimal glands, stratified ocular surface epithelium, and conjunctival goblet cells (Table 1). These are anchored by chemical bonds to the underlying membrane-bound mucins (glycocalyx) on the superficial cornea epithelium.⁴ The integrity of the precorneal mucus gel is essential for maintaining high quality vision and ocular comfort. Experimental removal of the mucus gel results in a transient alteration of corneal barrier function to fluorescein dye, a decrease in contrast sensitivity and an increase in corneal surface irregularity. These findings are similar to those observed in eyes with keratoconjunctivitis, the ocular surface pathology of dry eye that is associated with decreased and abnormal production of mucins by the ocular surface epithelium.

We have learned that the tear fluid consists of much more than just water and electrolytes. The tear fluid is a complex biochemical mixture of mucins, immunoglobulins, antimicrobial proteins (lysozyme and lactoferrin), and growth factors such as transforming growth factor- α , epidermal growth factor, and hepatocyte growth factor.⁵⁻⁸ These growth factors regulate cellular processes through their interaction with specific cell surface receptors. The exact biological function of these peptide factors has not been firmly established, but it is likely that some function to maintain ocular surface homeostasis, whereas others regulate wound healing after ocular surface trauma.

There has also been a tremendous increase in knowledge regarding the composition and structure of the Meibomian gland lipid composition. Hydrophilic polar lipids, including phospholipids (phosphatidylcholine, phosphatidylethanolamine), sphingomyelin, ceramides, and cerebrosides, form the lipid layer adjacent to the aqueous-mucin gel.^{9,10} The bulk of the tear lipid layer consists of the overlying nonpolar hydrophobic lipids (wax esters, cholesterol esters, triglycerides, free fatty acids, and hydrocarbons) that are associated with the polar phase by means of hydrophobic bonds.¹¹

LACRIMAL GLAND-OCULAR SURFACE INTERACTION

It is now recognized that the ocular surface (cornea, conjunctiva, accessory lacrimal glands, and Meibomian glands) and the interconnecting neural reflex arcs function as an integrated or "func-

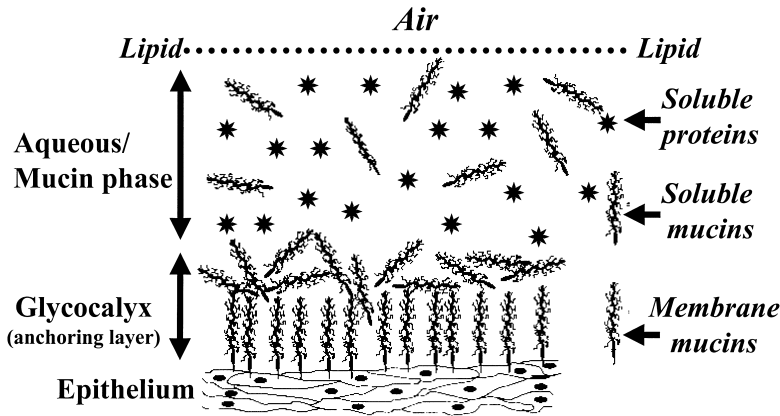


FIG. 1. Proposed structure of precorneal tear film that consists of a superficial lipid layer, a middle aqueous/mucin phase that contains soluble mucins, aqueous fluid, electrolytes, and proteins that are secreted by the lacrimal glands, and ocular surface epithelium. This layer is anchored to the underlying superficial corneal epithelium by chemical attractions to the epithelial membrane mucins (glycocalyx).

tional” unit.¹² Communication between these tissues occurs through their sensory/autonomic neural reflex loop (Fig. 2).

The majority of tear secretion by the lacrimal glands is reflexive. Tear flow is engendered through stimulation (mostly subconscious) of the ocular surface and nasal mucosa.^{13,14} This initiates sensory afferent nerve traffic along the ophthalmic branch of the trigeminal nerve (CN-V) to the central nervous system in the area of the pons. It is here where the nerve signals are integrated with input from emotional (cortical) and various other appropriate central nervous system centers. Efferent nerves consist of parasympathetic fibers that travel in the facial (CN-VII) nerve and sympathetic fibers that emanate from the paraspinal sympathetic chain. The parasympathetic nerves synapse in the pterygopalatine ganglion en route to the main and accessory lacrimal glands. The sympathetic fibers course along with the parasympathetic nerves, without synapsing at the pterygopalatine ganglion. Both types of nerve fibers cause water movement and tear secretion.

DEFINITION OF DRY EYE

For years, there has been considerable confusion regarding the definition of dry eye as well as the diagnostic classification of dry

eye conditions. To address these issues, specialists in the field of dry eye participated in two workshops held at the National Eye Institute (December 13–14, 1993 and December 5–6, 1994) at which time a definition and classification scheme for dry eye disease was proposed.¹⁵ Dry eye was defined as “a disorder of the tear film due to tear deficiency or excessive evaporation that causes damage to the interpalpebral ocular surface and is associated with symptoms of discomfort.”¹⁵ Consistent with this definition is a proposed classification scheme (Fig. 3) that stratifies patients with dry eye from those with decreased aqueous tear production by the lacrimal glands to those with increased evaporative loss.

DIAGNOSIS OF DRY EYE DISEASE

Most clinicians still rely on traditional diagnostic tests, such as fluorescein tear breakup time, the Schirmer test, and ocular surface dye staining, for diagnosis of dry eye disease. It is now recognized that a diagnostic algorithm using many diagnostic tests is better for identifying a patient’s dry eye condition than a single test alone.¹⁶ One such approach that we have found useful for diagnostic classification is presented in Figure 4.¹⁶ Many new diagnostic tests with improved sensitivity and specificity over these conventional

TABLE 1. Mucins detected in the ocular surface epithelium and tear fluid

Mucins	Source sample (detection method)	Normal	KCS	Reference
MUC-1	Corneal and conjunctival specimens (PCR, in situ hybridization, IHC)	Found in conjunctival and corneal epithelium	—	Inatomi et al., 1995 ⁵⁶
	Conjunctival specimens (IHC)	—	Decreased expression of glycosylated form	Jones et al., 1998 ²⁰
SMC/MUC-4 (protein, mRNA)	Conjunctival and corneal epithelium, tear fluid (IHC, immunoprecipitation, western blotting, northern blotting)	Found in the tear fluid and in the corneal and conjunctival epithelium	NA	Pflugfelder et al., 2000 ⁴
MUC-4	Conjunctiva (northern blotting and in situ hybridization)	Found in the stratified conjunctival epithelium	NA	Inatomi et al., 1996 ⁵⁷
MUC-5AC	Conjunctival goblet cells (in situ hybridization)	Found in conjunctival goblet cells	NA	Inatomi et al., 1996 ⁵⁷
	Conjunctiva and tear fluid (RT-PCR, IHC, western blotting)	Found in conjunctival goblet cells, superficial conjunctival epithelium and tear fluid	—	Jumblatt et al., 1999 ⁵⁸
H185	Conjunctival impression cytologies (IHC)	Mosaic staining pattern	Starry sky pattern	Danjo et al., 1998 ²¹
MEM	Conjunctival epithelium (IHC)	—	Sjögren’s syndrome	Pflugfelder et al., 1997 ²²

NA, not evaluated; MEM, mucosal epithelial membrane mucin; SMC, sialomucin complex; RT-PCR, reverse transcription polymerase chain reaction; IHC, immunohistochemistry.

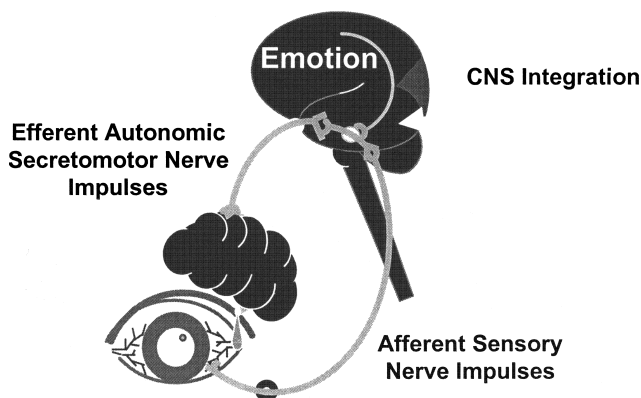


FIG. 2. Integrated ocular surface/lacrimal gland functional unit. Afferent sensory nerve impulses from the ocular surface and nasal mucosa synapse in the brainstem with efferent autonomic secretomotor nerve impulses that innervate the lacrimal gland. Stimulation of this reflex loop results in delivery of tear fluid and proteins on demand to the ocular surface.

tests have been reported over the past 25 years. These techniques include tear film osmolarity, tear fluid protein immunoassays, and fluorescein tear clearance.¹⁷⁻²⁰ Although none of these tests has yet to gain widespread clinical acceptance, the results of studies evaluating these tests indicate that tear composition and clearance appear to show stronger correlation with the severity of ocular surface irritation symptoms and ocular surface disease than the Schirmer test that evaluates tear production alone.

PATHOGENESIS OF DRY EYE DISEASE

There has been a considerable increase in knowledge regarding the pathogenesis of the keratoconjunctivitis sicca (KCS) that occurs in dry eye disease. The pathologic features of this condition include increased epithelial stratification and proliferative index and abnormal differentiation with maintenance of a basal phenotype.²¹ Cells throughout the abnormally thickened conjunctival epithelium express cytokeratin 14, a cytoskeletal protein normally produced by the basal epithelial cells. Furthermore, there is re-

duced expression of secretory and membrane-bound mucins by the superficial ocular surface epithelial cells.^{22,23}

An exact mechanism for the development of these pathologic changes has not been elucidated. The severity of KCS worsens as aqueous tear secretion decreases and as the ability to reflex tear in response to sensory stimulation is lost.¹⁶ Ocular surface epithelial function and differentiation may be adversely affected by the increase in tear film osmolarity that occurs in dry eye.²⁴ Trauma to a poorly lubricated and unprotected ocular surface from environmental factors and blinking may be another contributing factor because KCS is most severe in the exposure zone that is subjected to these stresses.^{15,22} If KCS represents a chronic wound-healing response, then it may be perpetuated, in part, by reduced levels of lacrimal gland-secreted growth factors in the tear fluid.^{25,26}

Inflammation may represent another important causative factor for KCS. Decreased aqueous tear production and tear clearance leads to chronic inflammation of the ocular surface.^{27,28} Evidence exists that the etiology of this disease is facilitated through a loss of the antiinflammatory environment within the lacrimal glands provided through the presence of circulating androgens.^{29,30} At the time of menopause or due to various pathologic conditions, the available level of circulating androgens may drop below a threshold, leaving the tissues vulnerable for the initiation of immune-based inflammation. This is supported by a significantly increased incidence of dry eye in women.³¹ Any condition that results in rapid firing of the “functional unit” can now cause the initiation of neurogenic inflammation within acini of the lacrimal glands resulting in antigen presentation and cytokine secretion by these epithelial cells.^{32,33} This will draw the attention of vigilantly trafficking T cells within the lacrimal glands. In the normal individual, trafficking lymphocytes—finding no inflammation present—would undergo apoptosis (programmed cell death) as they leave the tissue en route to local lymph nodes. In the presence of inflammatory signals, the apoptotic process is aborted (allowing the accumulation of lymphocytes within the glands) and the lymphocytes become activated and secrete proinflammatory cytokines that will result in the “homing” of additional T cells to the tissue and an increase in the level of inflammation.³⁴

It has also been demonstrated that the normally stable, termi-

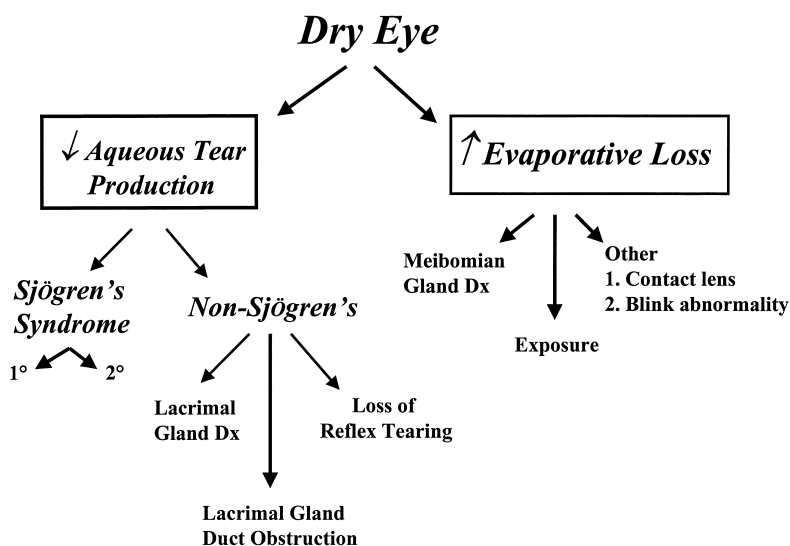


FIG. 3. Diagnostic classification scheme for dry eye disease proposed by the National Eye Institute/Industry Workshop. Adapted from *CLAO J* 1995;21: 222-32.¹⁵

Symptoms of Ocular Irritation

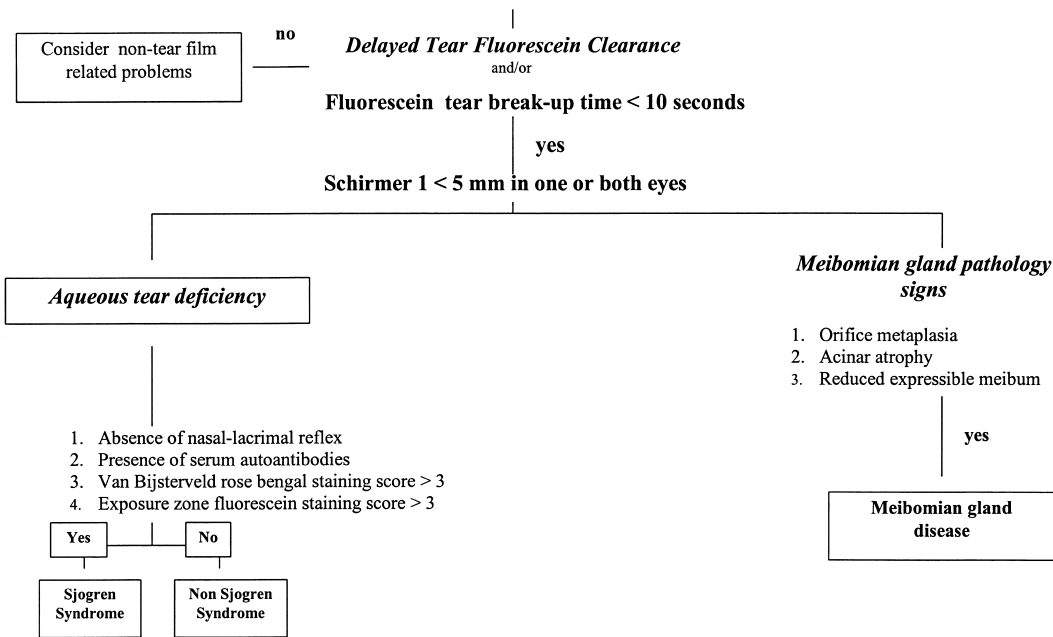


FIG. 4. Algorithm for diagnosis of dry eye disease.

nally differentiated, acinar epithelial cells of the lacrimal gland undergo abnormal (pathologic) apoptosis.³⁴ Tears now secreted to the ocular surface will contain proinflammatory cytokines and will inflame the tissues of the ocular surface. Abnormal apoptosis has also been detected within the epithelial cells and lymphocytes of the ocular surface.³⁴ This ocular surface inflammatory response consists of inflammatory cell infiltration, activation of the ocular surface epithelium with increased expression of adhesion molecules, inflammatory cytokines and pro-apoptotic factors, increased concentrations of inflammatory cytokines in the tear fluid, and increased activity of matrix-degrading enzymes in the tear

fluid (summarized in Table 2).^{26–28,35–39} Significant positive correlation has been observed between the levels of inflammatory cytokines in the conjunctival epithelium and the severity of ocular irritation symptoms, corneal fluorescein staining, and the severity of conjunctival squamous metaplasia in patients with Sjögren’s syndrome KCS.²⁶

THERAPY OF DRY EYE DISEASE

There have been many recent advances in the treatment of dry eye disease. First, there is increasing recognition that the frequent

TABLE 2. Cytokines, growth factors and matrix degrading enzymes detected in the ocular surface tissues and in the tear fluid of patients tear film disorders

Cytokine/growth factor	Source sample (detection method)	Dry eye diseases	Reference
EGF (protein)	Tear fluid (ELISA)	Decreased in ocular surface diseases and Sjögren’s syndrome	Van Setten 1991 ²⁵ Pflugfelder et al., 1999 ²⁶
IL-1 α (mRNA)	Conjunctival epithelium (RT-PCR on conjunctival cytology specimens)	Sjögren’s syndrome increased	Pflugfelder et al., 1999 ²⁶
IL-6 (mRNA)			Jones et al., 1994 ³⁵
IL-8 (mRNA)			
TNF-α (mRNA)			
TGF-β1 (mRNA)			
HGF (protein) ^a	Tear fluid (ELISA)	(Hypothesized to be decreased)	Li et al., 1996 ⁸
IL-1 α (protein)	Tear fluid (ELISA)	Increased in ocular rosacea	Afonso et al., 1999 ²⁷
Pro-MMP-9	Tear fluid (ELISA)		
IL-1 α (protein)	Tear fluid (ELISA)	Increased in ocular rosacea	Barton et al., 1997 ²⁸
IL-6 (protein)	Tear fluid (ELISA)	Increased in Sjögren’s syndrome	Tishler et al., 1998 ³⁸
Plasmin	Fluorometric assay	Increased in Sjögren’s syndrome	Virtanen et al., 1997 ⁵⁹
MMP-3 (protein)	Tear fluid (ELISA)	Increased in ocular rosacea	Sobrin et al., 2000 ³⁹
MMP-9 (protein)			
TIMP-1 (protein)			

^a Normal (after surgery).

EGF, epidermal growth factor; MMP, matrix metalloproteinase; TNF, tumor necrosis factor; TGF, transforming growth factor; HGF, hepatocyte growth factor; TIMP, tissue inhibitor of metalloproteinase; ELISA, enzyme-linked immunosorbent assay; RT-PCR, reverse transcription polymerase chain reaction.

use of artificial tear solutions that are preserved with benzalkonium chloride may be toxic to the ocular surface epithelium.^{40,41} To avoid the risk of preservative toxicity to the abnormal ocular surface epithelium of eyes with KCS, there has been an increase in trend over the past decade to use unit-dose nonpreserved artificial tears in patients who must frequently instill artificial tears to control their irritation symptoms. Laboratory studies have shown that certain electrolyte compositions and the use of a bicarbonate buffering system in artificial tear solutions promotes normal ocular surface differentiation and homeostasis.^{24,42} Currently, there are many commercially available artificial tear preparations with these features. Several different multidose artificial tear preparations with disappearing preservatives have also been released.

Although artificial tears have been reported to improve irritation symptoms and to decrease ocular surface dye staining in eyes with KCS, their use has not been found to improve conjunctival squamous metaplasia.⁴³ For this reason, there is increasing interest in developing therapeutic agents for KCS. Extracellular uridine triphosphate and other nucleotides that stimulate P2Y2 purinergic receptors, which have been reported to increase chloride, fluid, and mucin secretion by the conjunctiva.^{44,45} These agents may prove to have therapeutic benefit for treatment of dry eye disorders.

Consistent with an immunologic mechanism for development of KCS, antiinflammatory therapy has been reported to improve both irritation symptoms and ocular surface disease. Cyclosporin is a potent immunomodulatory agent that inhibits T cell activation and downregulates the production of many inflammatory cytokines. Topically applied cyclosporin has been reported to significantly improve signs of KCS in dogs that develop this condition and it has been approved for treatment of veterinary dry eye disease.⁴⁶ A prospective double-masked randomized placebo-controlled clinical trial evaluating a topical cyclosporin emulsion showed significant improvement in the severity of ocular irritation symptoms and ocular surface disease in the cyclosporin treated group compared to those treated with vehicle.⁴⁷ Furthermore, when compared to the vehicle, cyclosporin was found to decrease many inflammatory markers and the level of the inflammatory cytokine interleukin-6 (IL-6) in the conjunctiva.⁴⁸

Our center has reported that topically applied corticosteroids remarkably improve the irritation symptoms and ocular surface signs of KCS.^{49,50} Furthermore, we have found that steroids decrease levels of the chemotactic cytokine IL-8 in the conjunctival epithelium.²⁶ We currently reserve the use of topical corticosteroids for treatment of those patients who experience intolerable irritation symptoms despite maximal aqueous enhancement therapy (artificial tears and punctual occlusion). The fact that corticosteroids have been found to have excellent efficacy for treatment of KCS provides proof of the principle that inflammation plays a key role in the pathogenesis of dry eye disease.

Female gender has been reported to be a risk factor for developing KCS, particularly that associated with Sjögren's syndrome.⁵¹ Experimental evidence indicates that androgen hormones improve lacrimal gland secretory function.⁵² Furthermore, systemically administered androgenic hormones have been reported to significantly reduce lacrimal gland lymphocytic infiltration and improve lacrimal gland function in murine models of Sjögren's syndrome.^{53,54} At the present time, there have been no controlled clinical trials of androgen hormones for treatment of dry eye disease in humans.

The normal human tear fluid contains many biologically active

growth factors, such as epidermal growth factor, that are secreted by the lacrimal glands. The concentration of these factors have been reported to decrease in patients with lacrimal gland dysfunction. Autologous human serum, which contains many of the growth factors that are present in tear fluid, has been reported to improve KCS and stimulate conjunctival mucus production.⁵⁵ Recent advances in the field of biotechnology provide the opportunity to formulate tear replacements containing recombinant forms of these cytokine growth factors. Future research will hopefully define whether topical application of one or more of these factors alone will duplicate the therapeutic benefits of serum.

REFERENCES

- Nichols BA. Demonstration of the mucous layer of the tear film by electron microscopy. *Invest Ophthalmol Vis Sci* 1985;26:464-73.
- Chen HB. Structure and composition of rat precorneal tear film. A study by an in vivo cryofixation. *Invest Ophthalmol Vis Sci* 1997;38:381-7.
- Prydal JI, Artal P, Woon H, et al. Study of human precorneal tear film thickness and structure using laser interferometry. *Invest Ophthalmol Vis Sci* 1992;33:2006-11.
- Pflugfelder SC, Liu Z, Monroy D, et al. Detection of sialomucin complex (MUC4) in human ocular surface epithelium and tear fluid. *Invest Ophthalmol Vis Sci* 2000;41:1316-26.
- Van Setten GB, Schultz GS. Transforming growth factor alpha is a constant component of tear fluid. *Graefes Arch Clin Exp Ophthalmol* 1994;232:523-6.
- Ohashi Y, Motokura M, Kinoshita Y, et al. Presence of epidermal growth factor in human tears. *Invest Ophthalmol Vis Sci* 1989;30:1879-82.
- Van Setten GB, Viinikka L, Tervo T. Epidermal growth factor is a constant component of normal human tear fluid. *Graefes Arch Clin Exp Ophthalmol* 1989;22:184-7.
- Li Q, Weng J, Mohan RR, et al. Hepatocyte growth factor and hepatocyte growth factor receptor in the lacrimal gland, tears and cornea. *Invest Ophthalmol Vis Sci* 1996;37:727-39.
- Greiner JV, Glonek T, Korb DR, et al. Phospholipids in meibomian gland secretion. *Ophthalmic Res* 1996;28:44-9.
- McCulley J, Shine WE. Meibomian gland secretions in chronic blepharitis. *Adv Exp Med Biol* 1998;430:319-26.
- Shine WE, McCulley J. The role of wax and fatty alcohols in chronic blepharitis. *Invest Ophthalmol Vis Sci* 1993;34:3521-5.
- Stern ME, Beuerman R, Fox RI, et al. The pathology of dry eye: the interaction between the ocular surface and lacrimal glands. *Cornea* 1998;17:584-9.
- Heigle T, Pflugfelder SC. Aqueous tear production in patients with neurotrophic keratitis. *Cornea* 1996;15:135-8.
- Jordan A, Baum J. Basic tear flow? Does it exist? *Ophthalmology* 1980;87:920-30.
- Lemp MA. Report of the National Eye Institute/Industry Workshop on Clinical Trials in Dry Eyes. *CLAO J* 1995;21:222-32.
- Pflugfelder SC, Tseng SCG, Sanabria O, et al. Evaluation of subjective assessments and objective diagnostic tests for diagnosing tear-film disorders known to cause ocular irritation. *Cornea* 1998;17:38-56.
- Gilbard JP, Farris RL, Santamaria IJ. Osmolarity of tear microvolumes in keratoconjunctivitis sicca. *Arch Ophthalmol* 1978;96:677-81.
- McCollum CJ, Foulks GN, Bodner B, et al. Rapid assay of lactoferrin in keratoconjunctivitis sicca. *Cornea* 1994;13:505-8.
- Danjo Y. Ocular surface damage and tear lactoferrin in dry eye syndrome. *Acta Ophthalmol (Copenh)* 1994;72:433-7.
- Afonso A, Monroy D, Stern ME, et al. Correlation of tear clearance and Schirmer test scores with ocular irritation symptoms. *Ophthalmology* 1999;106:803-10.
- Jones DT, Ji A, Monroy D, et al. Evaluation of ocular surface cytokine, mucin, and cytokeratin expression in Sjögren's Syndrome. *Adv Exp Med Biol* 1998;438:533-6.
- Danjo Y, Watanabe H, Tisdale AS, et al. Alteration of mucin in human

Explore Litigation Insights

Docket Alarm provides insights to develop a more informed litigation strategy and the peace of mind of knowing you're on top of things.

Real-Time Litigation Alerts



Keep your litigation team up-to-date with **real-time alerts** and advanced team management tools built for the enterprise, all while greatly reducing PACER spend.

Our comprehensive service means we can handle Federal, State, and Administrative courts across the country.

Advanced Docket Research



With over 230 million records, Docket Alarm's cloud-native docket research platform finds what other services can't. Coverage includes Federal, State, plus PTAB, TTAB, ITC and NLRB decisions, all in one place.

Identify arguments that have been successful in the past with full text, pinpoint searching. Link to case law cited within any court document via Fastcase.

Analytics At Your Fingertips



Learn what happened the last time a particular judge, opposing counsel or company faced cases similar to yours.

Advanced out-of-the-box PTAB and TTAB analytics are always at your fingertips.

API

Docket Alarm offers a powerful API (application programming interface) to developers that want to integrate case filings into their apps.

LAW FIRMS

Build custom dashboards for your attorneys and clients with live data direct from the court.

Automate many repetitive legal tasks like conflict checks, document management, and marketing.

FINANCIAL INSTITUTIONS

Litigation and bankruptcy checks for companies and debtors.

E-DISCOVERY AND LEGAL VENDORS

Sync your system to PACER to automate legal marketing.