

# c-erbB-2 expression in different histological types of invasive breast carcinoma

S Soomro, S Shousha, P Taylor, H M Shepard, M Feldmann

## Abstract

Sections of 149 breast carcinomas were examined for the over-expression of *c-erbB-2* oncoprotein using the avidin-biotin immunoperoxidase technique and two different specific antibodies. These included the polyclonal antibody 21N and the monoclonal antibody 4D5. The tumours were divided into two main groups. The first included 75 cases of invasive ductal and classic invasive lobular carcinomas. The second group consisted of 74 cases with histological types known to have a good prognosis, including mucinous, alveolar variant of invasive lobular, medullary, tubular, cribriform and papillary carcinomas. Fifteen (20%) tumours of the first group were positive with the two antibodies. Fourteen of these were of the ductal type and one was a mixed invasive ductal and lobular carcinoma. Ten of the pure ductal cases had areas of comedo carcinoma. The intraductal elements in a further tumour were positively stained with 21N antibody only. None of the second group of tumours, which included histological types known to have good prognosis, stained with 4D5, although one mucinous carcinoma was positively stained with 21N.

These findings suggest that in invasive breast carcinoma immunostaining for *c-erbB-2* is mainly seen in a subgroup of ductal tumours, and that almost all other histological types, especially those associated with good prognosis, lack this expression.

*c-erbB-2* (also called *HER2* and *neu*) is a proto-oncogene which encodes a 185–190 kilodalton glycoprotein molecule that is closely related in structure to the epidermal growth factor receptor.<sup>1–4</sup> It maps to human chromosome 17.<sup>5</sup> Under experimental conditions, *c-erbB-2* becomes a potent oncogene with transforming activity only when it is overexpressed in the cells.<sup>6</sup> In 1986 the oncogene was found to be amplified in a small percentage of adenocarcinomas of various organs, including breast, but not in other types of tumours.<sup>7</sup>

The gene product has been localised to the cell membrane with extracellular, transmembrane, and intracellular domains.<sup>1</sup> Various specific antibodies have been raised to the extra- and intracellular domains. Repeated

studies have shown a good correlation between the amplification of the *c-erbB-2* gene and positive immunostaining for its protein product in the cells using these specific antibodies,<sup>8–12</sup> although overexpression of the protein product can sometimes occur in the absence of gene amplification.<sup>11,12</sup>

In breast carcinoma between 9–33% of invasive tumours overexpress the gene product,<sup>8,9,11–20</sup> and there is strong evidence that overexpression is associated with increased tumour aggressiveness.<sup>11,13,17,19–25</sup> Most of these studies were carried out mainly on breast carcinomas of the ductal type. As there are other less common types of invasive breast carcinoma, some of which are known to have a relatively good prognosis,<sup>26,27</sup> we investigated the possibility that such tumours may have a lower incidence of *c-erbB-2* protein overexpression. The study was carried out using two specific antibodies, one raised to the intracellular and the other to the extracellular domains of the *c-erbB-2* gene product.

## Methods

Routinely processed paraffin wax sections of 149 invasive breast carcinomas were studied. The cases were selected on the basis of their histological type and were divided into two groups. The first included 75 cases of invasive ductal and classic invasive lobular carcinomas. The second group included 74 cases with histological types known to have a good prognosis, including mucinous, medullary, tubular, cribriform, papillary and the alveolar variant of invasive lobular carcinoma (table 1).<sup>27</sup>

Two specific antibodies were used: a polyclonal antibody, 21N (kindly supplied by Dr W J Gullick, ICRF Oncology Group, Hammersmith Hospital, London), raised to a synthetic peptide of the predicted sequence of the intracellular domain of *c-erbB-2* gene product,<sup>28</sup> and a monoclonal antibody, 4D5 (Genentech, San Francisco, California, USA), raised to the extracellular domain of the gene product.<sup>29–31</sup>

Four sections, each 5 µm thick, were cut from a representative paraffin wax embedded tissue block of each case. Two of these sections were intended for staining with the specific antibodies, and two were used as controls. All sections were incubated overnight at 37°C. On the following day they were dewaxed in two changes of xylene for two minutes each and hydrated in graded alcohols. Endogenous peroxidase activity was blocked

Department of  
Histopathology,  
Charing Cross and  
Westminster Medical  
School, London,  
W6 8RF

S Soomro  
S Shousha

Charing Cross Sunley  
Research Centre,  
London  
P Taylor  
M Feldmann

Genentech Inc, San  
Francisco, California,  
USA  
H M Shepard

Correspondence to:  
Dr S Shousha

Accepted for publication  
31 October 1990

Table 1 *c-erbB-2* immunostaining of breast carcinoma according to histological type

Histological type (all invasive)	Total No of cases	Cases positive with 21N (%)	Cases positive with 4D5 (%)
Ductal	63	14 (22%)	14 (22%)
Lobular, classic	11	0	0
Composite, ductal and lobular	1	1	1
Mucinous	23	1 (4%)	0
Lobular, alveolar variant	22	0	0
Medullary	13	0	0
Tubular	6	0	0
Cribriform	6	0	0
Papillary	4	0	0
Total	149	16 (11%)	15 (10%)

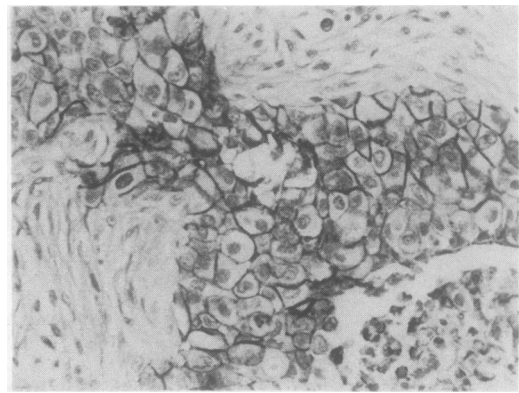


Figure 1 *c-erbB-2* positive invasive ductal carcinoma (avidin-biotin complex).

by 3% hydrogen peroxide in methanol for 30 minutes at room temperature. This was followed by rinsing three times in 0.1M TRIS-buffered-saline (TBS), pH 7.6.

Sections intended for staining with the polyclonal antibody 21N, and their controls, were incubated with 10% normal swine serum in TBS. Sections intended for staining with the monoclonal antibody 4D5, and their controls, were incubated in 10% normal rabbit serum. After 30 minutes excess serum was removed and sections were incubated overnight at 4°C either with the specific primary antisera, or, for the negative controls, with TBS.

On the following day sections were rinsed in TBS and then covered for 30 minutes with a 1 in 250 solution of the secondary antibodies in TBS (biotinylated swine anti-rabbit immunoglobulin for 21N, and biotinylated rabbit anti-mouse immunoglobulin for 4D5; both from Dakopatts, England). Sections were then rinsed three times with TBS and incubated for 60 minutes in avidin-biotin complex—horseradish peroxidase (Dakopatts, England). After rinsing in TBS sections were incubated with diaminobenzidine (DAB, Sigma, England) for six minutes and then counterstained with Harris's haematoxylin, dehydrated in graded alcohols, and mounted with Permount.

The results were assessed semiquantitatively according to the percentage of cells showing membrane staining so that (–) indicated absence of stained cells, (+) indicated staining of less than 33% of tumour cells, (++) staining of 33–66% of tumour cells, and (+++) staining of more than 66% of the cells. Cells showing cytoplasmic staining only were regarded as negative.<sup>32 33</sup>

### Results

Only 15 tumours stained with both antibodies (table 1). Of these, 14 were invasive ductal (22% of all ductal cases examined), 10 of which had areas of intraductal comedo elements (fig 1). The only other positive case was a composite tumour comprising two distinct zones, one invasive ductal and the other classic lobular; both showed strong positive staining (+++) with the two antibodies.

Positive staining with 21N was seen in two other tumours. These included a moderately stained (++) pure mucinous carcinoma (fig 2) and the intraductal elements of an invasive

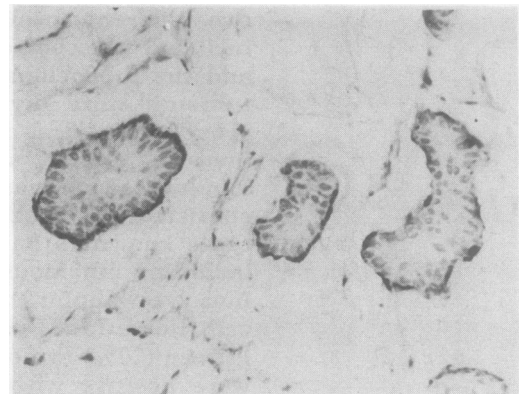


Figure 2 *c-erbB-2* (21N) positive pure mucinous carcinoma (avidin-biotin complex).

Table 2 Comparison of semiquantitatively assessed staining results of 21N and 4D5 antibodies in invasive elements of 63 ductal carcinomas

Antibody	Total	–	+	++	+++
21N	63	49	0	1	13
4D5	63	49	2	6	6

ductal tumour. These two tumours did not stain with 4D5.

All remaining 133 tumours were negative with the two antibodies. These included all pure classic and alveolar lobular carcinomas, 22 of the 23 mucinous carcinomas, and all medullary, tubular, cribriform and papillary tumours examined (table 1).

Thus the two antibodies gave concordant results in 147 (98.7%) out of the 149 cases examined. In a given positive case, however, 21N tended to stain more cells than 4D5 (table 2). On the other hand, cytoplasmic staining, presumably non-specific, was often seen with 21N, but was not encountered in cases stained with 4D5.

### Discussion

The main finding of this study is the almost consistent absence of *c-erbB-2* immunostaining in the uncommon histological varieties of invasive breast carcinoma, which are known to be associated with better prognosis than the common invasive ductal variety. This was

especially so when the monoclonal antibody 4D5, which recognises the extracellular domain of the oncogene product, was used. The results obtained with the polyclonal antibody 21N were similar, except for one case of mucinous carcinoma which was positive with this antibody but not with 4D5 (table 1). The findings provide indirect support for the existence of an association between positive *c-erbB-2* immunostaining and increased aggressiveness of invasive tumours. As most of these special types of breast carcinoma, with the exception of the medullary type, are also usually rich in oestrogen receptors,<sup>27 34</sup> the findings are in line with the presence, in general, of an inverse relation between *c-erbB-2* and oestrogen receptors.<sup>18 25 35-39</sup>

Almost all cases of invasive lobular carcinoma examined, whether classic or alveolar in type, did not overexpress this oncoprotein. The only positive lobular elements were seen in a composite tumour which consisted of separate, but adjacent, lobular and ductal parts. There are no published references about the *c-erbB-2* expression of the alveolar variant of lobular carcinoma, but investigators who have examined cases of the classic variant found them either all negative,<sup>12 17 35 40</sup> or to have included only an occasional positive case.<sup>9 14 39 41</sup> In view of the recently reported absence of the oncoprotein in lobular carcinoma *in situ*<sup>40 42</sup> the findings suggest that overexpression of *c-erbB-2* may not have an important role in lobular neoplasia. The presence of *c-erbB-2* immunostaining in the composite ductal/lobular tumour examined may indicate that the pathogenesis of the lobular-looking elements in this case is different from that of pure lobular tumours.

The only cases that were positively stained with the two antibodies used in this study were either purely or partly of ductal type, and most of these cases also contained intraductal comedo elements. This is consistent with the findings of most previous studies and strongly supports the suggestion that overexpression of *c-erbB-2* oncoprotein in invasive breast carcinoma is almost totally restricted to a subset of ductal tumours with specific morphological features.<sup>9 16 40 42</sup> It also seems that there are only two specific types of *in situ* breast tumour which frequently overexpress the oncoprotein—namely, intraductal comedo carcinoma<sup>9 39 42</sup> and Paget's disease of the nipple.<sup>40 43 44</sup> It is tempting to suggest that a common thread may connect these three lesions, one invasive and two *in situ*, together. They are all characterised by large cell size, and although they may occasionally occur separately, they are more commonly seen in a combination of two or three; and when they do, they almost all overexpress the *c-erbB-2* oncoprotein.<sup>43 44</sup> The neoplastic changes are probably the same and involve specific cells at specific anatomical sites, and what determines what type of lesion(s) develop(s) is the primary site of the target cell(s) involved in the neoplastic process and its original directional proliferation potential.

Our study also shows that there is an excellent correlation (88.7%) between the

immunostaining results obtained with the two antibodies used which were raised to different domains of the oncogene product (intra- and extra-cellular). The polyclonal antibody raised to the intracellular domain (21N), however, tended to stain more cells in a given case, exclusively stained two (1.4%) extra cases (table 2), and in some tumours showed cytoplasmic staining which is considered to be non-specific by most authors.

We thank Dr W J Gullick of the ICRF Oncology Group, Hammersmith Hospital for supplying us with the 21N antibody. Photography was carried out by Mr Ron Barnett.

This study was presented in the Summer meeting of the Pathological Society of Great Britain and Ireland which was held in Nottingham, England, between 10-13 July 1990. This work is part of Dr Soomro's PhD thesis.

- 1 Schechter AL, Stern DF, Vaidyanathan L, *et al*. The neu-oncogene: an erbB related gene encoding a 185,000 M tumour antigen. *Nature* 1984;312:513-16.
- 2 Coussense L, Yang-Fang TL, Liao Y-C, *et al*. Tyrosine kinase receptor with extensive homology to EGF receptor shares chromosomal location with neu oncogene. *Science* 1985;230:1132-9.
- 3 Yamamoto T, Ikawa S, Akiyama T, *et al*. Similarity of protein encoded by the human *c-erbB-2* gene to epidermal growth factor receptor. *Nature* 1986;319:230-4.
- 4 Akiyama T, Sudo C, Ogawara H, Toyoshima K, Yamamoto T. The product of the human *c-erbB-2* gene: A 185-kilodalton glycoprotein with tyrosine kinase activity. *Science* 1986;232:1644-6.
- 5 Schechter AL, Hung M-C, Vaidyanathan L, *et al*. The neu gene: An erb B-homologous gene distinct from and unlinked to the gene encoding the EGF receptor. *Science* 1985;229:976-8.
- 6 Di Fiore PF, Pierce JH, Kraus MH, Segatto O, King CR, Aaronson SA. erb B-2 is a potent oncogene when overexpressed in NIH/3T3 cells. *Science* 1987;237:178-82.
- 7 Yokota J, Yamamoto T, Toyoshima K, *et al*. Amplification of *c-erbB-2* in human adenocarcinomas *in vivo*. *Lancet* 1986;i:765-7.
- 8 Venter DJ, Tuzi NL, Kumar S, Gullick WJ. Overexpression of the *c-erb B-2* oncoprotein in human breast carcinomas: immunohistological assessment correlates with gene amplification. *Lancet* 1987;ii:69-72.
- 9 Van de Vijver MD, Peterse JL, Mooi WJ, *et al*. Neu-protein overexpression in breast cancer. Association with comedo-type ductal carcinoma *in situ* and limited prognostic value in stage II breast cancer. *N Engl J Med* 1988;319:1239-45.
- 10 Walker RA, Senior PV, Jones JL, Critchley DR, Varley JM. An immunohistochemical and *in situ* hybridisation study of *c-myc* and *c-erbB-2* expression in primary human breast carcinomas. *J Pathol* 1989;158:97-105.
- 11 Slamon DJ, Godolphin W, Jones LA, *et al*. Studies of the HER-2/neu proto-oncogene in human breast and ovarian cancer. *Science* 1989;244:707-12.
- 12 Parkes HC, Lillycrop K, Howell A, Craig RK. *C-erbB2* mRNA expression in human breast tumours: comparison with *c-erbB2* DNA amplification with prognosis. *Br J Cancer* 1990;61:39-45.
- 13 Slamon DJ, Clark GM, Wong SG, Levin WJ, Ullrich A, McGuire WJ. Human breast cancer: correlation of relapse and survival with amplification of the HER-2/neu oncogene. *Science* 1987;235:177-82.
- 14 Barnes DM, Lammie GA, Millis RR, Gullick WL, Allen DS, Altman DG. An immunohistochemical evaluation of *c-erbB-2* expression in human breast carcinoma. *Br J Cancer* 1988;58:448-52.
- 15 Gusterson BA, Machin LG, Gullick WJ, *et al*. *C-erbB-2* expression in benign and malignant breast disease. *Br J Cancer* 1988;58:453-7.
- 16 Adnane J, Gaudray P, Simon M-P, Simony-Lafontaine J, Jeanteur P, Theillet C. Proto-oncogene amplification and human breast tumor phenotype. *Oncogene* 1989;4:1389-95.
- 17 Walker RA, Gullick WJ, Varley JM. An evaluation of immunoreactivity for *c-erbB-2* protein as a marker of poor short-term prognosis in breast cancer. *Br J Cancer* 1989;60:426-9.
- 18 Zeillinger R, Kury F, Czerwnka K, *et al*. HER-2 amplification, steroid receptors and epidermal growth factor receptor in primary breast cancer. *Oncogene* 1989;4:109-14.
- 19 Zhou D-J, Ahuja H, Cline MJ. Proto-oncogene abnormalities in human breast cancer: *c-ERBB-2* amplification does not correlate with recurrence of disease. *Oncogene* 1989;4:105-8.

- the National Surgical Adjuvant Breast and Bowel Project: prognostic significance of erb B-2 protein overexpression in primary breast cancer. *J Clin Oncol* 1990;8:103-12.
- 21 Cline MJ, Battifora H, Yokota J. Proto-oncogene abnormalities in human breast cancer: correlations with anatomic features and clinical course of disease. *J Clin Oncol* 1987;5:999-1006.
  - 22 Varley JM, Swallow JE, Brammar WJ, Whittaker JL, Walker RA. Alterations to either c-erbB-2 (neu) or c-myc proto-oncogenes in breast carcinomas correlate with poor short-term prognosis. *Oncogene* 1987;1:423-30.
  - 23 Zhou D, Battifora H, Yokota J, Yamamoto T, Cline MJ. Association of multiple copies of the c-erbB-2 oncogen with spread of breast carcinoma. *Cancer Res* 1987;47:6123-5.
  - 24 Tandon AK, Clark GM, Chamness GC, Ullrich A, McGuire WL. HER-2/neu oncogene protein and prognosis in breast cancer. *J Clin Oncol* 1989;7:1120-8.
  - 25 De Potter C, Beghin C, Makar AP, Vandekerckhove D, Roels HJ. The neu-oncogene protein as a predictive factor for haematogenous metastases in breast cancer patients. *Int J Cancer* 1990;45:55-8.
  - 26 McDivitt RW, Stewart FW, Berg JW. Tumours of the breast. Fascicle 2. In: *Atlas of tumor pathology*. Second series. Washington, DC: Armed Forces Institute of Pathology, 1968:86.
  - 27 Shousha S, Backhous CM, Alagband-Zadeh J, Burn I. Alveolar variant of invasive lobular carcinoma of the breast. A tumor rich in estrogen receptors. *Am J Clin Pathol* 1986;85:1-5.
  - 28 Gullick WJ, Berger MS, Bennett PLP, Rothbard JB, Waterfield MD. Expression of the c-erbB-2 protein in normal and transformed cells. *Int J Cancer* 1987;40:246-54.
  - 29 Hudziak RM, Schlessinger J, Ullrich A. Increased expression of the putative growth factor receptor p185HER2 causes transformation and tumorigenesis of NIH 3T3 cells. *Proc Natl Acad Sci USA* 1987;84:7159-63.
  - 30 Hudziak RM, Lewis GD, Shalaby MR, et al. Amplified expression of the HER2/ERBB2 oncogene induces resistance to tumor necrosis factor alpha in NIH 3T3 cells. *Proc Natl Acad Sci USA* 1988;85:5102-6.
  - 31 Hudziak RM, Lewis GD, Winget M, Fendly BM, Shepard HM, Ullrich A. p185HER2 monoclonal antibody has antiproliferative effects in vitro and sensitizes human breast tumor cells to tumor necrosis factor. *Mol Cell Biol* 1989;9:1165-72.
  - 32 Gusterson BA, Gullick WJ, Venter DJ, et al. Immunohistochemical localization of c-erbB-2 in human breast carcinomas. *Mol Cell Probes* 1988;2:383-91.
  - 33 De Potter CR, Quatacker J, Maertens G. The subcellular localization of the neu protein in human normal and neoplastic cells. *Int J Cancer* 1989;44:969-74.
  - 34 Shousha S, Coady AT, Stamp T, James KR, Alagband-Zadeh J. Oestrogen receptors in mucinous carcinoma of the breast: an immunohistological study using paraffin wax sections. *J Clin Pathol* 1989;42:902-5.
  - 35 Garcia I, Dietrich P-Y, Aapro M, Vauthier G, Vadas L, Engel E. Genetic alterations of c-myc, c-erbB-2, and c-Ha-ras protooncogenes and clinical association in human breast carcinomas. *Cancer Res* 1989;49:6675-9.
  - 36 Roux-Dosseto M, Romain S, Dussault N, Martin PM. Correlation of erbB-2 gene amplification with low levels of estrogen and/or progesterone receptors in primary breast cancer: do erbB-2 products delineate hormone-independent tumors? *Biomed Pharmacother* 1989;43:641-9.
  - 37 Wright C, Angus B, Nicholson S, et al. Expression of c-erbB-2 oncoprotein: a prognostic indicator in human breast cancer. *Cancer Res* 1989;49:2087-90.
  - 38 Heintz NH, Leslie KO, Rogers LA, Howard PL. Amplification of the c-erbB-2 oncogene and prognosis of breast adenocarcinoma. *Arch Pathol Lab Med* 1990;114:160-3.
  - 39 Marx D, Schauer A, Reiche Chr, et al. c-erbB2 expression in correlation to other biological parameters of breast cancer. *J Cancer Res Clin Oncol* 1990;116:15-20.
  - 40 Gusterson BA, Machin LG, Gullick WJ, et al. Immunohistochemical distribution of c-erbB-2 in infiltrating and in situ breast cancer. *Int J Cancer* 1988;42:842-5.
  - 41 Ro J, El-Naggar A, Ro JY, et al. c-erbB-2 amplification in node negative human breast cancer. *Cancer Res* 1989;49:6941-4.
  - 42 Ramachandra S, Machin L, Ashley S, Monaghan P, Gusterson BA. Immunohistochemical distribution of c-erbB-2 in in situ breast carcinoma-A detailed morphological analysis. *J Pathol* 1990;161:7-14.
  - 43 Lammie GA, Barnes DM, Millis RR, Gullick WJ. An immunohistochemical study of the presence of c-erbB-2 protein in Paget's disease of the nipple. *Histopathology* 1989;15:504-14.
  - 44 Keatings L, Sinclair J, Wright C, et al. c-erbB-2 oncoprotein expression in mammary and extramammary Paget's disease: an immunohistochemical study. *Histopathology* 1990;17:243-7.