

A Novel Monoclonal Antibody, SCCL 175, with Specificity for Small Cell Neuroendocrine Carcinoma of the Lung¹

Vincent A. Memoli,² Andrea G. Jordan,³ and Edward D. Ball

Departments of Pathology [V. A. M., A. G. J.] and Medicine and Microbiology [E. D. B.], Dartmouth-Hitchcock Medical Center, Hanover, New Hampshire 03755

ABSTRACT

The murine monoclonal antibody SCCL 175, which is one of several monoclonal antibodies directed against small cell neuroendocrine carcinoma developed by one of us (E. D. B.), was studied for its immunohistochemical reactivity against normal human tissues and a spectrum of bronchopulmonary and metastatic carcinomas using the avidin-biotin complex technique. SCCL 175 reacted with 40 of 44 small cell carcinomas including both primary and metastatic sites and was distributed both on the cell surface and intracytoplasmically. Staining was seen in fresh frozen tissues, cytology preparations, and in a limited number of paraffin-embedded tissue sections after trypsin pretreatment. It was nonreactive with all non-small cell lung carcinomas, neuroendocrine carcinomas from other primary sites, and nonpulmonary carcinomata studied to date. Its distribution in normal adult human tissues was limited to some hypothalamic neurons and the apical membranes of renal proximal tubular epithelium. Cytotrophoblastic and syncytotrophoblastic cells from placental tissue demonstrated variable SCCL 175 immunoreactivity. Of choriocarcinomas studied, one of three demonstrated focal staining. These findings demonstrate the diagnostic utility of SCCL 175 in phenotyping small cell carcinoma of lung, and its specificity suggests a potential role in the therapy of this disease.

INTRODUCTION

Neuroendocrine SCCL⁴ is a distinct clinical and pathological type of bronchopulmonary neoplasm, the recognition of which plays an important role in determining the management and outcome of patients with this diagnosis (1, 2). Modern diagnostic techniques such as aspiration cytology and flexible fiberoptic bronchoscopy have provided the pathologist with a challenge, requiring diagnostic precision from ever smaller tissue and cell samples. Morphological heterogeneity within the various subtypes of bronchopulmonary neoplasms has further complicated the task of the pathologist, requiring new diagnostic methodologies (3-6). Immunohistochemistry has become a powerful tool for diagnosis, allowing classification of a great variety of tumors via the recognition of tumor- and tissue-specific antigens in small biopsy and cytological samples. However, its role in the classification of bronchopulmonary neoplasms has been limited by the unavailability of suitable markers for distinguishing the various subtypes of these carcinomata. Previous work has demonstrated the applicability of immunohistochemical analyses to the classification of pulmonary neuroendocrine neoplasms using antibodies recognizing a variety of neuroendocrine marker substances and different classes of intermediate filament proteins (6, 7). Recent studies with a number of MoAbs having specificity for specific histological subtypes of bronchopulmonary cancers demonstrate the pow-

erful role of this approach in tumor classification (8-18).

The IgM murine MoAb, SCCL 175, prepared in one of our laboratories (E. D. B.) recognizes an antigen associated with SCCL in cells obtained from tissue samples and cultured cell lines (8). SCCL 175 is one of several MoAbs prepared by immunizing with fresh SCCL tumor tissue which we have shown by flow cytometry to be reactive with seven of seven patient-derived SCCL cells and nine of ten SCCL cell lines. It is nonreactive with a number of non-SCCL lung tumor cell lines, common blood group antigens, histocompatibility antigens, the terminal pentasaccharide lacto-*N*-fucopentaose III, and lipid extracts of SCCL tumor cells. SCCL 175 precipitates two polypeptides with molecular masses of 155 and 115 kDa, respectively, under reducing conditions from SCCL cell lines. Further characterization of this antigen is in progress. The purpose of this paper is to report the reactivity of MoAb SCCL 175 with normal human tissues and carcinomata obtained from surgical biopsy, cytology, and autopsy and to demonstrate its clinical utility in the diagnosis of SCCL.

MATERIALS AND METHODS

Normal Tissues. Fresh normal human tissue blocks were obtained from either surgically resected specimens or at autopsy performed within 4 h of death from patients with no history or evidence of carcinoma. All tissues were snap-frozen and stored at -70°C prior to their use in immunohistochemical studies. Normal tissues are listed in Table 1 and include lung, heart, liver, kidney, pancreas, esophagus, stomach, small bowel, colon, thyroid, parathyroid, adrenal, pituitary, bone marrow, spleen, tonsil, lymph node, cerebral cortex, cerebellum, and hypothalamus. Normal fetal lung tissue from 8 autopsy cases and paraffin sections from 12 normal placentae including first, second, and third trimester cases were studied. Cryostat-frozen, 8- to 10- μ m sections were mounted on poly-L-lysine-coated slides (19), fixed for 5 min in cold acetone, and air dried for 10 min prior to immunostaining.

Tumor Specimens. All human tumor tissues were obtained from surgical biopsies, resections, cytological specimens, and at autopsy performed within 4 h of death. Fresh human tumor tissue obtained from ten patients with SCCL and seven with non-SCCL was prepared according to the method outlined above for normal human tissues. Routine, formalin-fixed, paraffin-embedded tissue blocks from nine cases of SCCL were obtained at flexible fiberoptic bronchoscopy, sectioned at 8 to 10 μ m, and mounted on poly-L-lysine-coated glass slides for immunohistochemical studies. Pap-stained cytology smears from 25 cases of SCCL, 65 cases of non-SCCL bronchopulmonary cancers, and 10 pulmonary metastases were decoverslipped and rehydrated in graded alcohols prior to immunohistochemical staining. A series of neuroendocrine and nonneuroendocrine carcinomas from other primary sites was studied and listed in Table 2.

Immunohistochemistry Method. A modification of the ABC technique (20) was used for all tissue sections and cytology smears. Tissues were treated with normal blocking serum at 37°C for 15 min. Sections were incubated with MoAb SCCL 175 at 37°C, for 60 min, washed, and then incubated with biotinylated anti-mouse IgG antibody at 37°C, for 30 min. Endogenous peroxidase activity was blocked with 0.6% H₂O₂ in absolute methanol for 15 min at 25°C. ABC was applied to sections at 37°C, for 30 min. Sections were incubated with 3',3'-diaminobenzidine substrate at 25°C for 5 min, washed, counterstained

Received 1/22/87; revised 10/1/87, 8/29/88; accepted 9/8/88.

The costs of publication of this article were defrayed in part by the payment of page charges. This article must therefore be hereby marked *advertisement* in accordance with 18 U.S.C. Section 1734 solely to indicate this fact.

¹ Supported in part by Grant CA 37868 from the National Cancer Institute.

² To whom requests for reprints should be addressed.

³ Present address: Department of Pathology, Jefferson Medical College, Philadelphia, PA.

⁴ The abbreviations used are: SCCL, small cell carcinoma of the lung; MoAb, monoclonal antibody.

MOAB SCCL 175

Normal tissues	Total	Negative	Positive	Cell type
Adrenal	8	8		
Bone marrow	12	12		
Cerebrum	5	4	1	Hypothalamic neurons
Cerebellum	5	5		
GI tract	18	18		
Heart	5	5		
Liver	5	5		
Lung	20	20		
Lymph node	10	10		
Kidney	12		12	Proximal tubules
Pancreas	8	8		
Pituitary	5	5		
Placenta	12		12	Trophoblasts
Spleen	8	8		
Thyroid	10	10		

Table 2 MoAb SCCL 175 immunoreactivity in tumor tissues

Tumor type	No. of cases (total)	Reactivity ^a			
		Negative	+	++	+++
Primary pulmonary					
Squamous carcinoma	20	20			
Adenocarcinoma	23	23			
Large cell carcinoma	22	22			
Undifferentiated carcinoma	13	13			
Carcinoid	3	3			
SCCL (primary)	34	4	6	13	11
SCCL (metastatic)	10			4	6
Nonneuroendocrine					
Colonic adenocarcinoma	17	17			
Prostatic adenocarcinoma	3	3			
Breast carcinoma	3	3			
Neuroblastoma	3	1	2		
Choriocarcinoma	3	2	1		
Neuroendocrine					
Thyroid medullary carcinoma	15	15			
Adrenal pheochromocytoma	5	5			
Merkel cell carcinoma	5	5			
GI carcinoid	5	5			

^a Semiquantitative analysis of the percentage of positively stained tumor cells per case: negative, no detectable positive cells; +, <20% positive; ++, 20 to 60% positive; +++, >60% positive.

MoAb SCCL 175 used in these studies consisted of both hybridoma supernatant and mouse ascites fluid at a 1:100 dilution. Blocking serum, biotinylated linking antibody, and ABC peroxidase complex were obtained from Vector Labs, Burlingame, CA (Vectastain ABC kit) and prepared according to the manufacturer's instructions.

Paraffin-embedded tissue sections were pretreated with 0.1% trypsin in phosphate-buffered saline, pH 7.6, at 25°C for 5 min prior to immunohistochemical staining.

Positive controls for immunostaining were prepared from cytospin preparations of the DMS SCCL 153 cell line (8). Hybridoma supernatant containing an IgM MoAb to an unknown irrelevant antigen served as a negative antibody control.

RESULTS

Normal Tissues. Table 1 summarizes the immunoreactivity of MoAb SCCL 175 with normal adult human tissues. Noteworthy is the absence of immunostaining of endocrine organs and neuroendocrine cells in the GI tract and lung. All levels of the GI tract were studied including esophagus, stomach, duodenum, jejunum, ileum, and colon. Sections of normal lung from all lobes as well as fetal lung were entirely negative for SCCL 175. In the kidney, renal proximal tubular epithelium showed apical staining with MoAb SCCL 175 (Fig. 1). Scattered hypothalamic neurons also demonstrated cytoplasmic immunoreactivity in one sample (Fig. 2).

Tumor Samples. Cases were judged as positive when at least

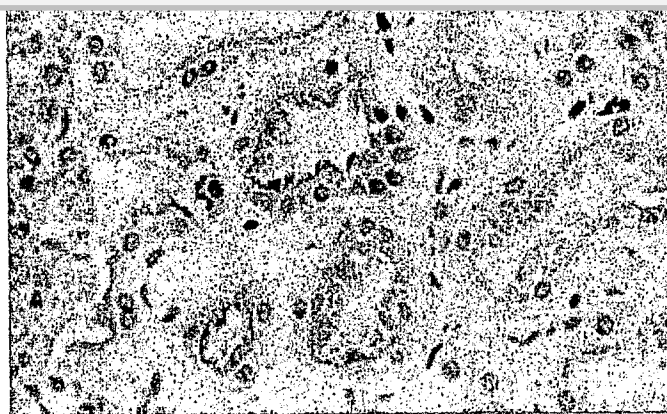


Fig. 1. Section of human kidney showing apical staining of renal proximal tubular epithelial cells with SCCL 175. ABC technique, counterstained with hematoxylin; × 450.

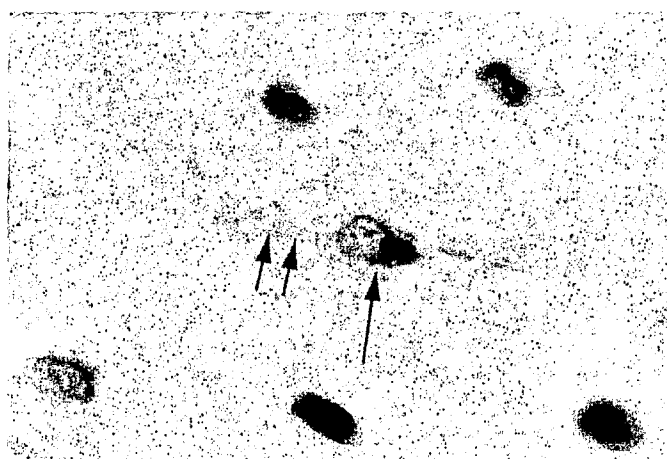


Fig. 2. A neuron with cytoplasmic SCCL 175 immunoreactivity in both cell body (single arrow) and dendritic process (double arrow). ABC technique, counterstained with hematoxylin; × 910.

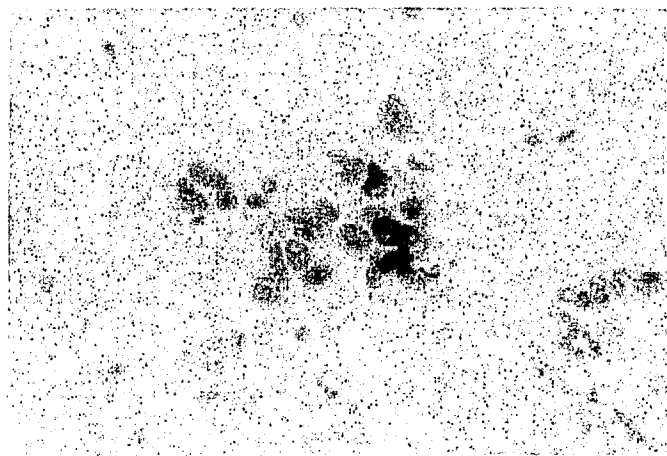


Fig. 3. Adenocarcinoma, cytology preparation, negative for SCCL 175. ABC technique, counterstained with hematoxylin; × 450.

20% of tumor cells demonstrated immunoreactive staining with MoAb SCCL 175. Cases that were judged as negative had no detectable immunostaining with MoAb SCCL 175 (Fig. 3). Table 2 summarizes the results of MoAb SCCL 175 immunoreactivity according to histological tumor type. Positive cases of SCCL demonstrated both surface and cytoplasmic immu-

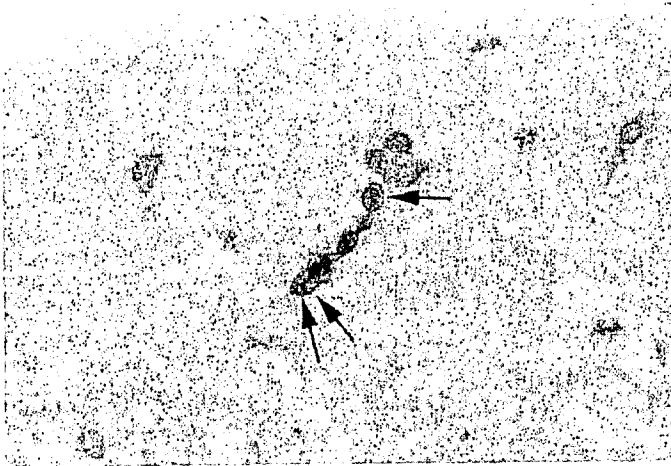


Fig. 4. Cytological preparation of small cell neuroendocrine carcinoma with surface (*single arrow*) and cytoplasmic (*double arrow*) SCCL 175 immunoreactivity. ABC technique, counterstained with hematoxylin; $\times 450$.

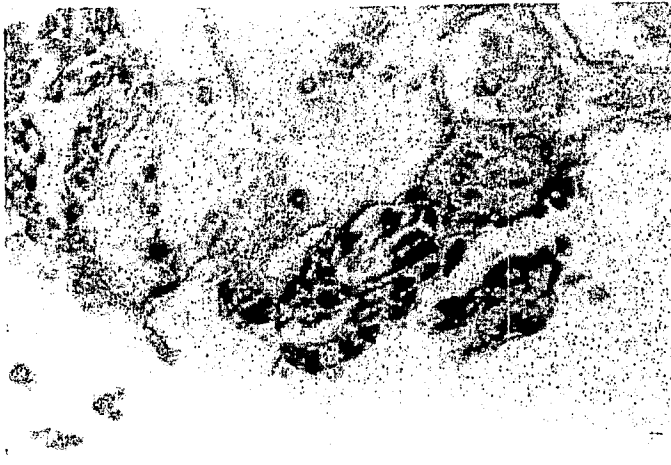

Fig. 5. Paraffin-embedded bronchial biopsy specimen of small cell neuroendocrine carcinoma with intense cytoplasmic SCCL 175 immunoreactivity. The intensity of the staining obscures the nuclear contours in this photomicrograph. ABC technique, counterstained with hematoxylin; $\times 450$.

noreactivity (Figs. 4 and 5). Of the material available for study, cytology preparations provided the best staining results, with tumor cells showing strong membrane immunoreactivity and less intense cytoplasmic immunoreactivity. In several SCCL preparations, scattered normal pulmonary reserve cells showed cytoplasmic immunoreactivity with SCCL 175; however, this staining was not seen in any other tumor samples or in normal lung tissue. Ten metastatic SCCL cases were positive with SCCL 175 including four hepatic, four lymph node, and two pleural fluid metastases. In two positive cases, both primary and metastatic sites were studied, and no difference in staining was observed. Two SCCL cases judged as negative were paraffin-embedded bronchial biopsy specimens, and the remaining two negative SCCL cases were bronchial washings. Prior to trypsin pretreatment, none of the paraffin-embedded SCCL cases demonstrated positive immunoreactivity with MoAb SCCL 175.

DISCUSSION

This study demonstrates the utility of MoAb SCCL 175 as a selective and sensitive probe for SCCL. MoAb SCCL 175 immunoreactivity was identified in over 90% of the SCCL cases

strong and diffusely distributed throughout the tumor. Both surface and cytoplasmic immunoreactivity was detected on both cytology and tissue sections, showing that the antigen recognized by this MoAb is distributed on both the cell surface and intracytoplasmically.

All non-SCCL carcinomas thus far studied have been negative for binding with SCCL 175. Included in this group were carcinomas that were histologically classified as poorly differentiated in which a diagnosis of SCCL was initially considered in the differential diagnosis. The diagnostic dilemma posed by such cases has prompted the use of a variety of additional special techniques to aid in the classification of these tumors, including electron microscopy and immunohistochemistry (4-6). MoAb SCCL 175 provides a unique tool because of its specificity and sensitivity for SCCL and its ready applicability to routinely processed pathology specimens.

Noteworthy is the absence of immunostaining of bronchial carcinoids and other neuroendocrine tumors, suggesting that MoAb SCCL 175 is not a general marker of neuroendocrine differentiation. Additional studies performed in this laboratory have demonstrated that this MoAb can distinguish SCCL from well-differentiated neuroendocrine carcinoma, a subtype of pulmonary neuroendocrine carcinoma having a morphology and clinical course intermediate between typical bronchial carcinoid and the highly aggressive SCCL (21, 22).

Although SCCL 175 was reactive with a colonic carcinoma cell line DLD-1 (8), it does not appear to be reactive with the colonic carcinomas studied to date. Additionally, SCCL 175 demonstrated only weak reactivity with one of three cases of choriocarcinoma despite its reactivity with the BeWo cell line (8). The studies performed on normal tissues indicate that the antigen recognized by MoAb SCCL 175 has a limited distribution in normal human tissues. The antigen does not appear to be expressed in normal or neoplastic adult neuroendocrine cells, suggesting that it is not a general marker of neuroendocrine differentiation. The antigen recognized by MoAb SCCL 175 may be expressed in a limited fashion in the CNS; however, given its limited distribution thus far in the CNS and its absence in normal neuroendocrine cells, it does not appear to recognize a common structural antigen in these systems like synaptophysin (23).

SCCL 175 is variably reactive with cytotrophoblastic and syncytiotrophoblastic cells of normal placenta. SCCL 175 reacted only weakly with one choriocarcinoma; however, further studies are required to determine if this antibody has any utility in the characterization of germ cell tumors. Current work is under way to further assess the reactivity of SCCL 175 in nonpulmonary cancers.

The antigen recognized by MoAb SCCL 175 appears to be preserved, although masked, in formalin-fixed, paraffin-embedded biopsy specimens obtained at fiberoptic bronchoscopy. Mild trypsin pretreatment can unmask immunoreactivity in at least some routinely processed cases of SCCL, although snap-frozen tissue sections and cytological preparations appear to provide more consistent results in this study. Additional studies are being performed on formalin-fixed, paraffin-embedded pulmonary cancers using trypsin pretreatment in order to determine the pattern of immunostaining for routinely prepared biopsy material.

Based on these results, SCCL 175 provides an effective and objective tool in the diagnosis of SCCL and would serve as an excellent reagent in a panel of antibodies capable of phenotyp-

this disease.

REFERENCES

- Gould, V. E., Warren, W. H., and Memoli, V. A. Neuroendocrine neoplasms of the lung. Their light microscopic, ultrastructural, and immunohistochemical spectrum. In: K. L. Becker and A. F. Gazdar (eds.), *The Endocrine Lung in Health and Disease*, pp. 406-445. Philadelphia: W. B. Saunders Company, 1984.
- Minna, J. D., Higgins, G. A., and Gladstein, E. J. Cancer of the lung. In: V. T. DeVita, S. Hellman, and S. A. Rosenberg (eds.), *Principles and Practices of Oncology*, pp. 396-474. Philadelphia: J. B. Lipincott Company, 1982.
- Gould, V. E., and Chejfec, G. Ultrastructural and biochemical analysis of "undifferentiated" pulmonary carcinomas. *Hum. Pathol.*, *9*: 377-384, 1978.
- McDowell, E. M., Wilson, T. S., and Trump, B. F. Atypical endocrine tumors of the lung. *Arch. Pathol. Lab. Med.*, *105*: 20-28, 1981.
- Churg, A., Johnston, W. H., and Stahlberg, M. Small cell squamous and mixed small cell squamous-small anaplastic carcinoma of the lung. *Am. J. Surg. Pathol.*, *4*: 255-263, 1980.
- Gould, V. E., Linnoila, R. I., Memoli, V. A., and Warren, W. H. Neuroendocrine components of the bronchopulmonary tract. Hyperplasia, dysplasias, and neoplasms. *Lab. Invest.*, *49*: 519-537, 1983.
- Blobel, G. A., Gould, V. E., Moll, R., Lee, I., Huszar, M., Geiger, B., and Franke, W. W. Coexpression of neuroendocrine markers and epithelial cytoskeletal proteins in bronchopulmonary neuroendocrine neoplasms. *Lab. Invest.*, *52*: 39-51, 1985.
- Ball, E. D., Graziano, R. F., Pettengill, O. S., Sorenson, G. D., and Fanger, M. W. Monoclonal antibodies reactive with small cell carcinoma of the lung. *J. Natl. Cancer Inst.*, *72*: 593-598, 1984.
- Bernal, S. D., and Speak, J. A. Membrane antigen in small cell carcinoma of the lung defined by monoclonal antibody SM1. *Cancer Res.*, *44*: 265-270, 1984.
- Cuttitta, F., Rosen, S., Gazdar, A. F., and Minna, J. D. Monoclonal antibodies that demonstrate specificity for several types of human lung cancer. *Proc. Natl. Acad. Sci. USA*, *78*: 4591-4595, 1981.
- De Leij, L., Poppema, S., Nulend, J. K., ter Haar, A., Schwander, E., Ebbens, F., Postmus, P. E., and The, T. H. Neuroendocrine differentiation on human lung cancer and Kulchitski cells. *Cancer Res.*, *45*: 2192-2200, 1985.
- Kyoizumi, S., Akiyama, M., Kuono, N., Kobuke, K., Hokoda, M., Jones, S. 45: 3274-3281, 1985.
- Radosevich, J. A., Ma, Y., Lee, I., Salwen, H. R., Gould, V. E., and Rosen, S. T. Monoclonal antibody 44-3A6 as a probe for a novel antigen found on human lung carcinomas with glandular differentiation. *Cancer Res.*, *45*: 5808-5812, 1985.
- Rosen, S. T., Mulshine, J. L., Cuttitta, F., Fedorko, J., Carney, D. N., Gazdar, A. F., and Minna, J. D. Analysis of human small cell lung cancer differentiation antigens using a panel of rat monoclonal antibodies. *Cancer Res.*, *44*: 2052-2061, 1984.
- Sobol, R. E., Peters, R. E., Astarita, R. W., Hofeditz, C., Masui, H., Burton, D., Handley, H. H., Glassy, M. C., Fairshier, R., Carlo, D. J., and Royston, I. A novel monoclonal antibody-defined antigen which distinguishes human non-small cell from small cell lung carcinomas. *Cancer Res.*, *46*: 4746-4750, 1986.
- Tong, A. W., Lee, J., and Stone, M. J. Characterization of two human small cell lung carcinoma-reactive monoclonal antibodies generated by a novel immunization approach. *Cancer Res.*, *44*: 4987-4992, 1984.
- Varki, N. M., Reisfeld, R. A., and Walker, L. E. Antigens associated with a human lung adenocarcinoma defined by monoclonal antibodies. *Cancer Res.*, *44*: 681-687, 1984.
- Watanabe, J., Okabe, T., Fujisawa, M., Takaku, F., Hirohashi, S., and Shimamoto, Y. Monoclonal antibodies that distinguishes small-cell lung cancer from non-small-cell lung cancer. *Cancer Res.*, *47*: 826-829, 1987.
- Husain, O. A. N., Millett, J. A., and Grainger, J. M. Use of polylysine-coated slides in preparation of cell samples for diagnostic cytology. *J. Clin. Pathol.*, *33*: 309-311, 1980.
- Hsu, S. M., Raine, L., and Fanger, H. The use of avidin-biotin-peroxidase complex (ABC) in immunoperoxidase techniques: a comparison between ABC and unlabeled antibody (PAP) procedures. *J. Histochem. Cytochem.*, *29*: 577-581, 1982.
- Warren, W. H., Memoli, V. A., and Gould, V. E. Ultrastructural and immunohistochemical analyses of pulmonary neuroendocrine neoplasms. II. Well-differentiated neuroendocrine carcinomas. *Ultrastruct. Pathol.*, *7*: 185-199, 1984.
- Memoli, V. A., Warren, W. H., Gould, V. E., and Ball, E. D. MOAB SCCL 175 distinguishes small cell carcinoma from well-differentiated neuroendocrine carcinoma. *Lab. Invest.*, *58*: 63A, 1988.
- Gould, V. E., Lee, I., Wiedenmann, B., Moll, R., Chejfec, G., and Franke, W. W. Synaptophysin: a novel marker for neurons, certain neuroendocrine cells, and their neoplasms. *Hum. Pathol.*, *17*: 979-983, 1986.

Cancer Research

The Journal of Cancer Research (1916–1930) | The American Journal of Cancer (1931–1940)

A Novel Monoclonal Antibody, SCCL 175, with Specificity for Small Cell Neuroendocrine Carcinoma of the Lung

Vincent A. Memoli, Andrea G. Jordan and Edward D. Ball

Cancer Res 1988;48:7319-7322.

Updated version Access the most recent version of this article at:
http://cancerres.aacrjournals.org/content/48/24_Part_1/7319

E-mail alerts Sign up to receive free email-alerts related to this article or journal.

Reprints and Subscriptions To order reprints of this article or to subscribe to the journal, contact the AACR Publications Department at pubs@aacr.org.

Permissions To request permission to re-use all or part of this article, contact the AACR Publications Department at permissions@aacr.org.

Explore Litigation Insights

Docket Alarm provides insights to develop a more informed litigation strategy and the peace of mind of knowing you're on top of things.

Real-Time Litigation Alerts



Keep your litigation team up-to-date with **real-time alerts** and advanced team management tools built for the enterprise, all while greatly reducing PACER spend.

Our comprehensive service means we can handle Federal, State, and Administrative courts across the country.

Advanced Docket Research



With over 230 million records, Docket Alarm's cloud-native docket research platform finds what other services can't. Coverage includes Federal, State, plus PTAB, TTAB, ITC and NLRB decisions, all in one place.

Identify arguments that have been successful in the past with full text, pinpoint searching. Link to case law cited within any court document via Fastcase.

Analytics At Your Fingertips



Learn what happened the last time a particular judge, opposing counsel or company faced cases similar to yours.

Advanced out-of-the-box PTAB and TTAB analytics are always at your fingertips.

API

Docket Alarm offers a powerful API (application programming interface) to developers that want to integrate case filings into their apps.

LAW FIRMS

Build custom dashboards for your attorneys and clients with live data direct from the court.

Automate many repetitive legal tasks like conflict checks, document management, and marketing.

FINANCIAL INSTITUTIONS

Litigation and bankruptcy checks for companies and debtors.

E-DISCOVERY AND LEGAL VENDORS

Sync your system to PACER to automate legal marketing.