

VOLUME 84

PAGES 985-1146

CURRENT
JUNE 1988
AWARENESS
TITLE

The American Journal of Medicine®

INDEX ISSUE



A YORKE MEDICAL JOURNAL
CAHNS PUBLISHING COMPANY

DOCKET
A L A R M

Find authenticated court documents without watermarks at docketalarm.com.

Total Suppression of Cortisol Excretion by Ketoconazole in the Therapy of the Ectopic Adrenocorticotrophic Hormone Syndrome

ALAN P. FARWELL, M.D.
JOHN T. DEVLIN, M.D., F.A.C.P.
JAMES A. STEWART, M.D., F.A.C.P.
Burlington, Vermont

Ketoconazole, an antifungal imidazole derivative, has been shown to inhibit adrenal steroidogenesis in vitro and in vivo. This has led to its use clinically as an effective treatment for various forms of Cushing's syndrome. The clinically effective doses have been reported to be between 800 to 1,200 mg per day, usually without glucocorticoid replacement. Herein is reported the first case of Cushing's syndrome due to ectopic adrenocorticotrophic production from a metastatic carcinoid tumor of the thymus that was treated with ketoconazole. Urinary cortisol excretion was totally suppressed at the initial dose and optimal control was achieved with relatively low doses of ketoconazole (200 to 400 mg per day), along with dexamethasone replacement. Use of glucocorticoid replacement is advisable in this setting to avoid symptomatic hypoadrenalism.

Ketoconazole is an imidazole derivative that until recently had been used solely as an antifungal agent. It has been well tolerated overall with very few reported side effects, and it is finding more widespread use due to an increasing incidence of opportunistic fungal infections, as seen in patients with the acquired immunodeficiency syndrome. More recently, it has been found to be a potent inhibitor of androgen [1] and adrenal glucocorticoid production [2], and as such, has been used clinically in the treatment of hormonally responsive tumors (i.e., prostate cancer) and endocrinopathies associated with hypercortisolism (i.e., the Cushing's syndromes) [3]. It has been suggested that a major role of this drug in the future will include the treatment of a variety of endocrine disorders. A cautionary note has been sounded recently with several reported deaths due to septicemia in patients receiving high-dose ketoconazole (1,200 mg per day) for the treatment of prostate cancer [4].

We describe a case of Cushing's syndrome due to ectopic production of adrenocorticotrophic hormone (ACTH) by a metastatic carcinoid tumor of the thymus. Medical control of cortisol excretion was achieved with lower doses of ketoconazole than reported in the literature and this patient was treated prophylactically with dexamethasone to avoid hypoadrenalism. We recommend beginning glucocorticoid replacement when using ketoconazole to treat the ectopic ACTH syndrome.

CASE REPORT

A 50-year-old white woman presented in June 1985 with fatigue, intermittent facial flushing, sweating of the back, neck, and face, anorexia, mild diarrhea, and an unintentional 10-pound weight loss over the previous four to six weeks. Her only pertinent past medical history included hypertension since 1980 treated with propranolol and a diuretic. Due to an elevated left hemidiaphragm noted on a chest radiograph, a computerized tomographic

From the Division of Endocrinology, Department of Medicine, Vermont Regional Cancer Center, Medical Center Hospital of Vermont, Burlington, Vermont. Requests for reprints should be addressed to Dr. Alan P. Farwell, Division of Endocrinology and Metabolism, Department of Medicine, University of Massachusetts Medical Center, 55 Lake Avenue, North, Worcester, Massachusetts 01605. Manuscript submitted November 12, 1987, and accepted February 16, 1988.

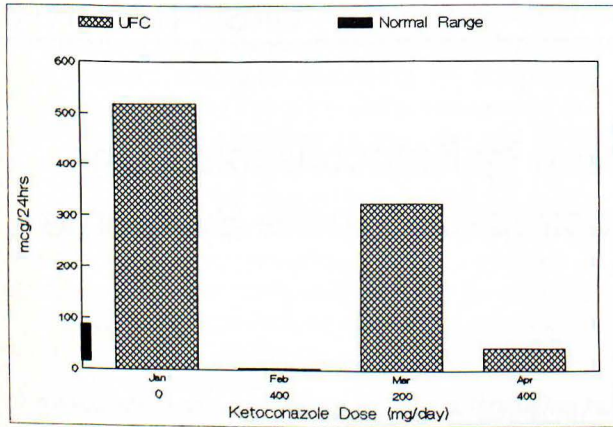


Figure 1. Response of cortisol excretion in the patient described, as measured by urine free cortisol (UFC), to varying doses of ketoconazole.

(CT) scan of the chest was performed that revealed a large anterior mediastinal mass. There was no pleural or parenchymal lung involvement and no abnormality was seen in the liver, spleen, or adrenal glands. Biopsy examination of the mass via mediastinotomy revealed a carcinoid tumor of the thymus. Physical examination revealed a weight of 67.5 kg and blood pressure of 162/100, but results were otherwise unremarkable. A 24-hour urine collection for 5-hydroxyindoleacetic acid (5-HIAA) was negative. The patient was referred to radiation therapy since the tumor was deemed unresectable due to the involvement of the chest wall. Follow-up CT scans after 6,556 rads to the primary tumor mass revealed little, if any, tumor shrinkage but the patient showed symptomatic improvement, with only rare flushing episodes and with a decrease in the fullness of her face. Weight at this time was 62.7 kg. In January 1986, a CT scan revealed an increase in the tumor size and the development of a left-sided pleural effusion. This was followed by serial chest radiographs that showed a slow increase in the size of the effusion, with her only symptom at this time being mild dyspnea on exertion. In December 1986, a biopsy of an enlarging left supraclavicular lymph node was performed, with the histology found to be similar to that of the patient's primary tumor. Physical examination revealed a weight of 70.7 kg, blood pressure of 170/110, facial plethora, moon-shaped facies, hyperpigmentation of the palmar creases and the extensor surfaces, and a generalized increase in body hair. Laboratory examination revealed a 24-hour urine collection negative for 5-HIAA and a urine free cortisol level of 518 μg per 24 hours (normal: 16 to 80 μg per 24 hours). A random plasma cortisol level was 43 $\mu\text{g}/\text{dl}$ (normal: 7 to 25 $\mu\text{g}/\text{dl}$) and an 8-mg overnight dexamethasone suppression test revealed a morning cortisol level of more than 64 $\mu\text{g}/\text{dl}$ (normal: less than 5 $\mu\text{g}/\text{dl}$). Serum ACTH was 187 pg/liter (normal: less than 100 pg/liter). A diagnosis of Cushing's syndrome due to ectopic production of ACTH by a metastatic thymic carcinoid tumor was made, and therapy was begun with ketoconazole 400 mg per day and dexamethasone 1.0 mg per day, both in divided doses. Two weeks later, a 24-hour urine free corti-

sol level was less than 2 μg per 24 hours and the dose of ketoconazole was reduced to 200 mg per day (Figure 1). Four weeks after beginning treatment, her weight was 66.6 kg, blood pressure was 140/84, and the patient was feeling well with less insomnia, resolution of menorrhagia, and improved proximal muscle strength. Serial 24-hour urine free cortisol determinations indicate that the optimal dose of ketoconazole in this patient is 300 to 400 mg per day.

COMMENTS

This case represents an example of a metastatic carcinoid tumor of the thymus producing Cushing's syndrome by ectopic production of ACTH. In retrospect, the patient probably had Cushing's syndrome as the cause of her clinical symptoms upon initial presentation of her tumor. Radiation therapy had little effect on the tumor mass, consistent with the slow-growing nature of thymic carcinoid tumors [5]. However, it most likely did have an effect on decreasing probable hormonal production by the tumor as her clinical symptoms disappeared and she noted a decrease in her facial fullness and her weight. Unfortunately, the only evaluation of hormonal production performed at that time was a 24-hour urine collection for 5-HIAA, which was negative, so possible ectopic steroid production by the tumor remains undocumented. With recurrent disease, she was overtly cushingoid in appearance and the diagnosis was confirmed by an elevated plasma cortisol concentration, an elevated 24-hour urine free cortisol excretion, an elevated ACTH level, and absence of suppression of plasma cortisol concentration with an 8-mg overnight dexamethasone suppression test. She showed quite a remarkable response to the initial 400 mg per day dose of ketoconazole. Due to the precipitous drop in her cortisol excretion to undetectable levels during the first two weeks of therapy, this patient would likely have become symptomatic due to hypoadrenalism had replacement steroids not been initiated along with the ketoconazole. With this therapy, her blood pressure improved, her antihypertensive medications were decreased in dosage, and her clinical symptoms resolved. To our knowledge, this is the first reported case of a thymic carcinoid tumor with ectopic ACTH production treated with ketoconazole.

Ketoconazole was developed in the 1970s as an antifungal agent with oral efficacy. In 1981, DeFelice et al [6] observed that gynecomastia developed in three of 40 patients treated with ketoconazole for fungal infections at doses of 200 to 600 mg per day. They initially postulated a direct effect of the drug on breast tissue. Similar observations in two patients by Pont et al [1] resulted in further investigation and led to the discovery of ketoconazole's role as an inhibitor of testosterone synthesis. Description of ketoconazole's ability to inhibit adrenal glucocorticoid synthesis soon followed [2], as well as delineation of the mechanism of these effects, which include inhibition of P_{450} enzymes such as 11-beta-hydroxylase, as well as

the side-chain cleavage of cholesterol [7], and the competitive inhibition of glucocorticoid activity at the receptor level [8]. The first case of symptomatic hypoadrenalism due to ketoconazole was reported in 1985 in a patient being treated for a fungal infection [9], followed by several descriptions of similar findings in patients being treated with high-dose (1,200 mg per day) ketoconazole for prostatic cancer [10, 11].

Ketoconazole's first published use in Cushing's syndrome was for preoperative stabilization in a patient with an adrenal rest tumor [12]. Subsequent reports have described ketoconazole's use in Cushing's disease as an adjunct to definitive surgery or radiation therapy [13] and as effective primary therapy for short-term [14] and long-term control [15]. Effective control has been achieved without the expected rise in ACTH seen with other inhibitors of steroidogenesis, by some unknown mechanism [14, 15]. Finally, Sheperd et al [16] have described the use of ketoconazole for control of the paraneoplastic Cushing's syndrome resulting from small cell lung cancer, although their patient soon died from the underlying malignancy.

Ectopic hormone production is the cause of approximately 15 percent of cases of Cushing's syndrome [17]. Therapy of this paraneoplastic syndrome is usually aimed at the primary tumor and prolonged survival with excess ACTH is rare due to the highly malignant nature of the primary tumors. An exception to this is carcinoid tumors where the clinical course is often protracted. Carcinoid tumor of the thymus is a rare neoplasm, with less than 100 cases reported in the literature [5]. Cushing's syndrome is a common presentation of thymic carcinoids, occurring in up to 40 percent of cases. Despite the fact that as many as 30 percent of cases will present with local invasion (as in our patient) or extrathoracic metastasis, survival is often protracted with a 10-year survival rate of 35 percent and a median survival of six years [5]. Aggressive surgical extirpation of the primary, and occasionally the metastatic, tumor offers the best hope for either cure or extended survival. Cytotoxic chemotherapy response rates are 10 to 15 percent at best and radiation therapy can be useful in palliating the tumor.

Prior medical therapy of Cushing's syndrome has been limited to essentially two drugs, aminoglutethamide and metyrapone, whose high incidence of side effects limits their use in up to 50 percent of patients [17]. Ketoconazole offers the promise of effectively controlling cortisol secretion with a much lower incidence of side effects. A transient rise in hepatic transaminases, nausea/vomiting, slight gynecomastia, and hypocalcemia are seen most frequently and are rarely severe enough to alter therapy [4]. Ketoconazole's antiadrenal effect is related to serum drug levels in a direct fashion [2] and Pont et al [2] have demonstrated a dramatic decrease in cortisol and testosterone levels for six to eight hours after a 400-mg dose.

Despite this observation, clinical doses for adrenal corticosteroid and androgen inhibition have been 800 to 1,200 mg per day.

The use of replacement glucocorticoids during ketoconazole therapy has generally been avoided in the literature, since the recommendation has been to decrease the ketoconazole dose if symptoms of hypoadrenalism occur [13]. A lower dose (400 mg per day) has been reported as probably safe based on six patients with leukemia treated prophylactically with the drug [18]. Most cases of symptomatic hypoadrenalism have been described with the use of high-dose (800 to 1,200 mg per day) ketoconazole [9–11], while only one of these reports suggests treating simultaneously with steroids, and then only in times of stress [10]. Most recently, Pont [19] utilized prophylactic replacement-dose steroids in a study on the use of high-dose ketoconazole in patients with stage D₂ prostatic cancer and recommends their use in this setting. Few data are available regarding the details of the reported deaths from sepsis in patients receiving high-dose ketoconazole [4], but it is possible that hypoadrenalism was partly responsible.

Our patient demonstrates a greatly increased sensitivity of adrenal glucocorticoid synthesis to inhibition by ketoconazole as compared with that described previously. She would have been at great risk for symptomatic hypoadrenalism had she not been simultaneously treated with dexamethasone, given her near total suppression of cortisol excretion with the initial dose. Because of this, we recommend the use of glucocorticoid replacement therapy at the time of initiation of ketoconazole for the treatment of the ectopic ACTH syndrome in order to eliminate the risk of hypoadrenalism in these patients. By using serial assessments of adrenal function (i.e., 24-hour urine free cortisol excretion), the optimal antiadrenal effect can be determined at the lowest dose of ketoconazole with the least risk to the patient, at which time the steroids can be discontinued if desired. Additional steroids, however, would be required in times of stress.

In summary, ketoconazole's activity as a potent inhibitor of steroidogenesis can be effectively utilized in the management of the ectopic ACTH syndrome. In addition to continuing to be an important antifungal drug, ketoconazole, because of its low incidence of side effects and twice-a-day dosing schedule, should be a very attractive drug in the treatment of several forms of Cushing's syndrome. The increasing use of ketoconazole in a variety of disorders will require closer monitoring for possible drug-induced hypoadrenalism. Future investigations into the long-term efficacy and possible toxicities of this drug are indicated.

ACKNOWLEDGMENT

We wish to thank Dr. John Lantman for referral of this patient.

REFERENCES

1. Pont A, Williams PL, Azhar S, et al: Ketoconazole blocks testosterone synthesis. *Arch Intern Med* 1982; 142: 1237–1240.
2. Pont A, Williams PL, Loose DS, et al: Ketoconazole blocks adrenal steroid synthesis. *Ann Intern Med* 1982; 97: 370–372.
3. Sonino N: The use of ketoconazole as an inhibitor of steroid production. *N Engl J Med* 1987; 317: 812–818.
4. Williams G, Ware H, Kerle DJ, et al: Objective responses to ketoconazole therapy in patients with relapsed progressive prostatic cancer. *Br J Urol* 1986; 58: 45–51.
5. Wick MR, Scott RE, Li CY, Carney JA: Carcinoid tumor of the thymus. *Mayo Clin Proc* 1980; 55: 246–254.
6. DeFelice R, Johnson DG, Galgiani JN: Gynecomastia with ketoconazole. *Antimicrob Agents Chemother* 1981; 19: 1073–1074.
7. Loose DS, Kan MA, Marcus RA, Feldman D: Ketoconazole blocks adrenal steroidogenesis by inhibiting cytochrome P450-dependent enzymes. *J Clin Invest* 1983; 71: 1495–1499.
8. Loose DS, Stover EP, Feldman D: Ketoconazole binds to glucocorticoid receptors and exhibits glucocorticoid antagonist activity in cultured cells. *J Clin Invest* 1983; 72: 404–406.
9. Tucker WS, Snell BB, Island DP, Gregg CR: Reversible adrenal insufficiency induced by ketoconazole. *JAMA* 1985; 253: 2413–2414.
10. White MC, Kendall-Taylor P: Adrenal hypofunction in patients taking ketoconazole (letter). *Lancet* 1985; i: 44–45.
11. Pillans PI, Cowan P, Whitelaw D: Hyponatremia and confusion in a patient taking ketoconazole (letter). *Lancet* 1985; i: 821–822.
12. Contreras P, Altieri E, Lieberman C, et al: Adrenal rest tumor of the liver causing Cushing's syndrome: treatment with ketoconazole preceding an apparent surgical cure. *J Clin Endocrinol Metab* 1985; 60: 21–28.
13. Sonino N, Boscaro M, Merola G, Mantero F: Prolonged treatment of Cushing's disease by ketoconazole. *J Clin Endocrinol Metab* 1985; 61: 718–722.
14. Angeli A, Fraira R: Ketoconazole therapy in Cushing's disease (letter). *Lancet* 1985; i: 821.
15. Loli P, Berselli ME, Tagliaferri M: Use of ketoconazole in the treatment of Cushing's syndrome. *J Clin Endocrinol Metab* 1986; 63: 1365–1371.
16. Sheperd FA, Hoffert B, Evans WK, Emery Y, Trachtenberg J: Ketoconazole: use in the treatment of ectopic adrenocorticotrophic hormone production and Cushing's syndrome in small-cell lung cancer. *Arch Intern Med* 1985; 145: 863–864.
17. Carpenter PC: Cushing's syndrome: update of diagnosis and management. *Mayo Clin Proc* 1986; 61: 49–58.
18. Dandona P, Mohiuddin J, Prentice HG: Ketoconazole and adrenocortical secretion (letter). *Lancet* 1985; i: 227.
19. Pont A: Long-term experience with high-dose ketoconazole therapy in patients with stage D2 prostatic cancer. *J Urol* 1987; 137: 902–904.