

Antiuterotrophic effects of the pure antioestrogen ICI 182,780 in adult female monkeys (*Macaca nemestrina*): quantitative magnetic resonance imaging

520

M. Dukes, J. C. Waterton and A. E. Wakeling

Cancer Research Department, ZENECA Pharmaceuticals, Mereside, Alderley Park, Macclesfield, Cheshire SK10 4TG, U.K.

REVISED MANUSCRIPT RECEIVED 15 February 1993

ABSTRACT

The antiuterotrophic efficacy of the pure antioestrogen ICI 182,780 has been demonstrated previously by magnetic resonance imaging (MRI) in ovariectomized oestrogen-treated monkeys (*Macaca nemestrina*). Further characterization of the effects of ICI 182,780 in intact adult female monkeys with normal menstrual cycles was undertaken to provide an indication of its potential actions in premenopausal women. Changes in the volume of uterine tissues were measured by MRI in early, mid and late cycle. The volume of the uterus varied up to fivefold between individual monkeys but serial observations in individuals provided sufficient precision to allow accurate assessments to be made of changes in the endometrium and myometrium during the course of the menstrual cycle and following ICI 182,780 administration. In comparison with its initial size in untreated monkeys, the endometrium increased in volume by 60% and 125% in the mid and late cycle respectively. In contrast, the

size of the myometrium decreased significantly, by 16% from early to mid cycle and then recovered to near its initial volume in the late cycle. Treatment with ICI 182,780 beginning in the early part of the menstrual cycle prevented the growth of the uterus. The magnitude and duration of the response was dependent on whether or not ovulation occurred during treatment with ICI 182,780. In animals rendered anovulatory, growth of the endometrium was blocked completely by ICI 182,780 and the volume of the tissue declined below that present at the start of the menstrual cycle. Antiuterotrophic efficacy was significantly less in monkeys which ovulated during treatment with ICI 182,780. The volume of myometrium was reduced substantially by antioestrogen treatment, and the difference in response between ovulatory and anovulatory monkeys was less marked than that of the endometrium.

Journal of Endocrinology (1993) **138**, 203–209

INTRODUCTION

ICI 182,780 is a potent specific pure antioestrogen which may prove superior to conventional partial agonist antioestrogens in the treatment of breast cancer (Wakeling *et al.* 1991). Previous studies evaluated the antioestrogenic potency and efficacy of ICI 182,780 in ovariectomized oestrogen-treated monkeys (*Macaca nemestrina*) by magnetic resonance imaging (MRI) of the uterus (Waterton *et al.* 1991; Dukes *et al.* 1992). A daily dose of 0.1 mg ICI 182,780/kg completely blocked the uterotrophic action of exogenous oestradiol-17 β . Single intramuscular injections of a long-acting oil-based formulation of ICI 182,780 in ovariectomized monkeys were also shown to inhibit oestrogen action in a dose-dependent sustained manner (Dukes *et al.*

1992). MRI has been used to observe the uterus during the normal menstrual cycle in women (Demas *et al.* 1986; Haynor *et al.* 1986; McCarthy *et al.* 1986; Wiczak *et al.* 1988; Bartoli *et al.* 1991) and the response to exogenous endocrine agents (Demas *et al.* 1986; McCarthy *et al.* 1986; Andreyko *et al.* 1988; Zawin *et al.* 1990). MRI has also been used quantitatively to measure the changes in volume of the endometrium and myometrium during the normal menstrual cycle in *M. nemestrina* (Waterton *et al.* 1992). The MRI studies reported here were performed to evaluate the antiuterotrophic effects of ICI 182,780 in adult female monkeys with normal menstrual cycles. Such studies are relevant to the potential application of ICI 182,780 in the treatment of both malignant and benign oestrogen-responsive diseases in pre- and perimenopausal women.

MATERIALS AND METHODS

Animal handling and treatment schedules

Mature female pigtail monkeys (*M. nemestrina*) of 5–10 kg body weight with regular menstrual cycles were used. The normal menstrual cycle in this species is 29–32 days in length; menstrual bleeding usually lasts 3–4 days. Daily vaginal swabs were taken to detect the onset of menstrual bleeding and the first day of menstruation was designated day 1 of the cycle. Where required, blood samples (2 ml) for subsequent hormone analyses were collected daily. MRI examinations took place before the animals received their morning feed, in order to minimize artefactual noise associated with gut motion. Anaesthesia was induced with 0.7 mg ketamine/kg (Vetalar; Parke Davis, Pontypool, Gwent, U.K.) and maintained with halothane (Fluothane; ICI Pharmaceuticals, Macclesfield, Cheshire, U.K.).

The timing of MRI, drug treatment and blood sampling was scheduled by reference to the first day of menstruation. To provide a baseline with which to compare the effects of drug treatment, three MRI measurements of the uterus were made during each of two cycles in ten untreated monkeys (Waterton *et al.* 1992). Images were recorded in early (days 2–5), mid (days 12–18) and late (days 21–25) cycle and scheduled by reference to the differences in cycle length in individuals. Images were recorded at similar time-points in monkeys treated with ICI 182,780 beginning early in the menstrual cycle (days 2–5). Two formulations of ICI 182,780 were used: a short-acting propylene glycol-based solution (F1) administered once daily i.m. for 25 days at a dose of 0.1 ($n=5$) or 0.2 mg ($n=5$) ICI 182,780/kg, and a long-acting castor oil-based solution (F2) given as a single i.m. injection of 2.5 ($n=6$) or 4 mg ($n=6$) ICI 182,780/kg.

Quantitative MRI

The method for measurement of endometrium and myometrium volume is described in detail elsewhere (Waterton *et al.* 1991, 1992; Dukes *et al.* 1992). Briefly, the study employed a Biospec 400/2.3 instrument (Oxford Research Systems, Coventry, Warwickshire, U.K.) to record a series of oblique images of the uterus. For each animal on each occasion, sagittal sighting images were used to determine the spatial co-ordinates of the uterine cervix and fundus. From these co-ordinates, MRI parameters were calculated to allow the acquisition of eight contiguous oblique slice images, the thickness, position and orientation of which were forced to depend on the vector connecting the fundus and cervix. This procedure allows reproducible presentation of the

uterus, independent of its size, location and orientation in the pelvis (Dukes *et al.* 1992; Waterton *et al.* 1992). Image matrices were 256×256 giving an in-plane resolution of 0.6 mm. The appearance of the images (see the Plate) results from the choice of MRI parameters, in particular the magnetic field strength of 2.35 tesla, the echo time of 50 ms, the repetition time of 3 s, and suppression of the signal from fat.

To allow comparisons between images acquired on different occasions, tissue volumes were measured rather than endometrium height or area, since the former avoids artefacts from repositioning errors or shape changes. Endometrium and myometrium volumes were obtained by pixel counting in the oblique images using the irregular region-of-interest facilities within the programs *uxnmr* or *DISNMR* (Bruker Analytische Messtechnik GmbH, Karlsruhe, Germany). Only slices more fundal than the internal os were included in the analysis. The junction zone was included with the myometrium. Any contribution to endometrium volume from the lumen was neglected since, except during menstruation, this is very narrow and insignificant in comparison with the endometrium (Dukes *et al.* 1992; Waterton *et al.* 1992).

Although, in principle, the prescription of region-of-interest can be subjective, the method employed minimizes errors, since the presentation of the uterus was the same at each examination (Waterton *et al.* 1991, 1992; Dukes *et al.* 1992). For each animal, the same observer analysed all images. Week-to-week and cycle-to-cycle coefficients of variation were as low as 5% (Waterton *et al.* 1992).

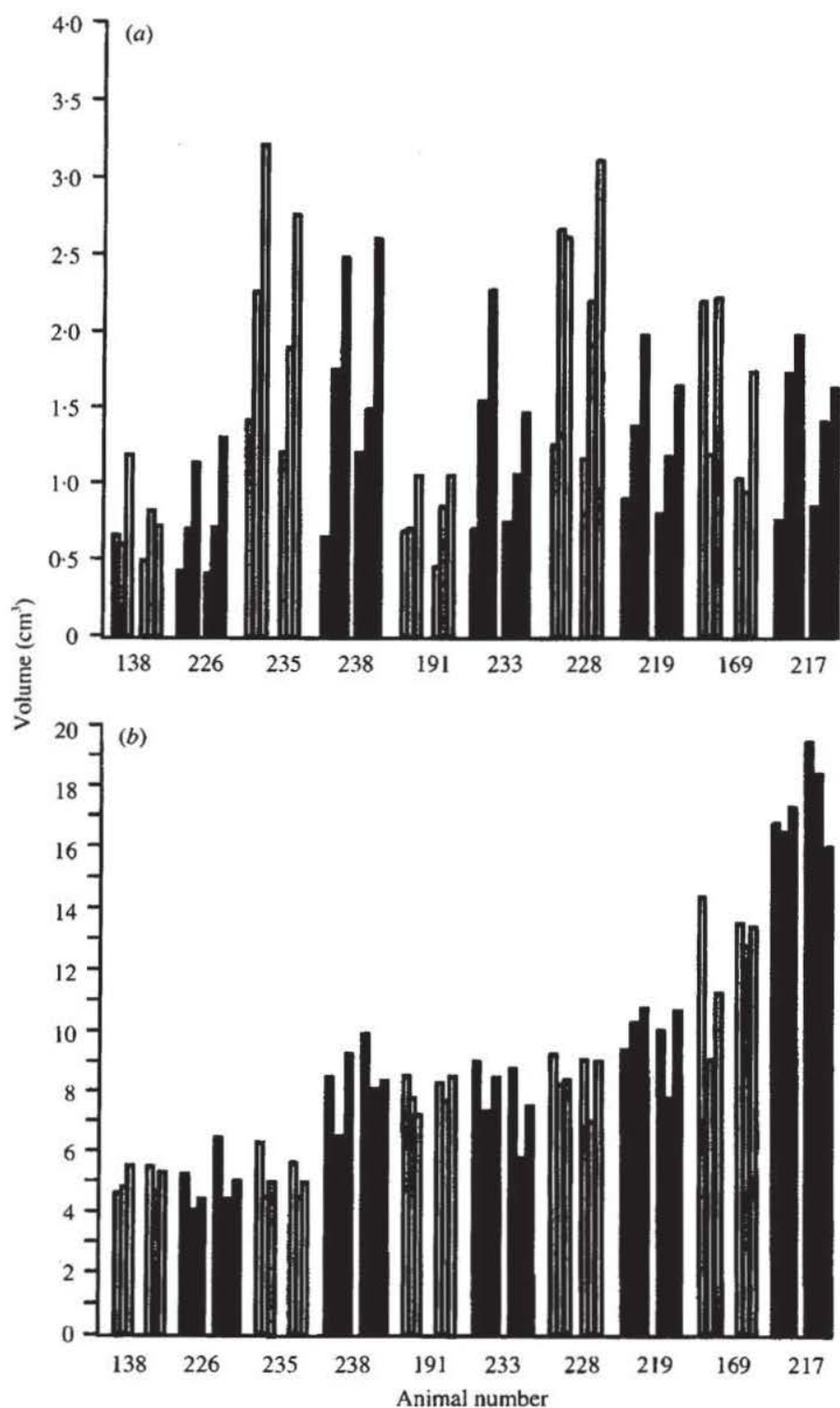
Analysis of results

The volumes of the endometrium and myometrium in treated and untreated groups were calculated as the arithmetic mean (\pm S.E.M.) normalized by reference to tissue volumes in individuals at the first MRI measurement. Differences between group means were tested for significance by the unpaired Student's *t*-test.

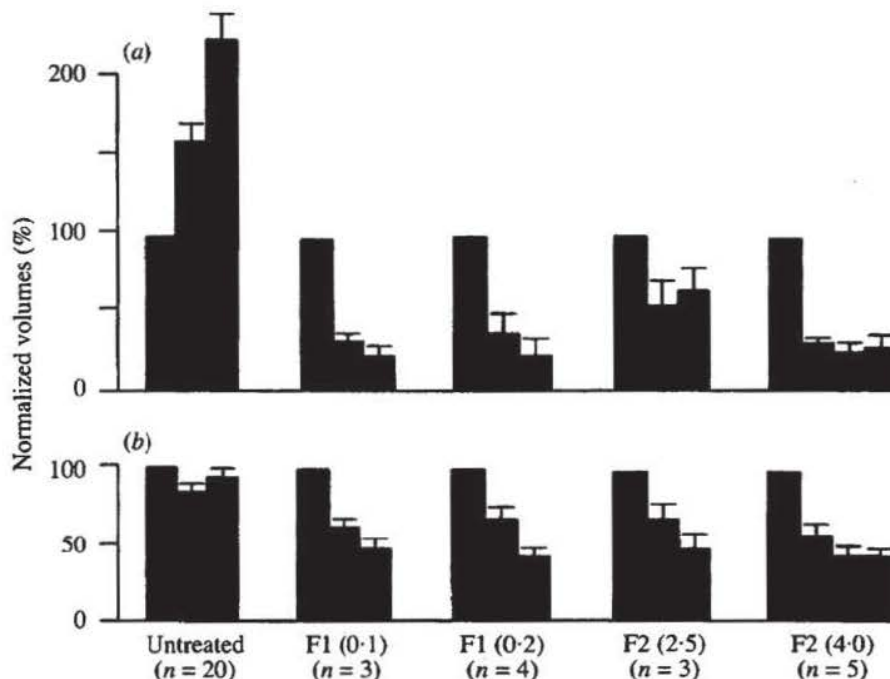
RESULTS

Uterine volume in the normal menstrual cycle

The volumes of the endometrium and myometrium were measured by MRI in early, mid and late cycle in two cycles in each of ten different untreated monkeys (Text-fig. 1). The mean interval between repeat measurements was 4 months (range 1–9 months). Tissue volumes varied widely between individuals but less so in repeat measurements in the same animal. Typical images recorded in one monkey at



TEXT-FIGURE 1. (a) Endometrium and (b) myometrium volumes in untreated monkeys during the menstrual cycle. For each of ten animals the bars represent (from left) tissue volumes measured by magnetic resonance imaging in two separate menstrual cycles, during the early (days 2-5), mid (days 12-18) and late (days 21-25) stages of the cycle.



TEXT-FIGURE 2. (a) Endometrium and (b) myometrium volumes in untreated and ICI 182,780-treated anovulatory monkeys. Tissue volumes at mid and late cycle were normalized to those recorded at the beginning of the cycle in each individual. From the left, values are means \pm S.E.M. for untreated controls; monkeys receiving once daily injections of ICI 182,780 (0.1 or 0.2 mg/kg) (F1) for 25 days, beginning on cycle day 3; monkeys receiving a single injection of ICI 182,780 (2.5 or 4 mg/kg) (F2) on day 3.

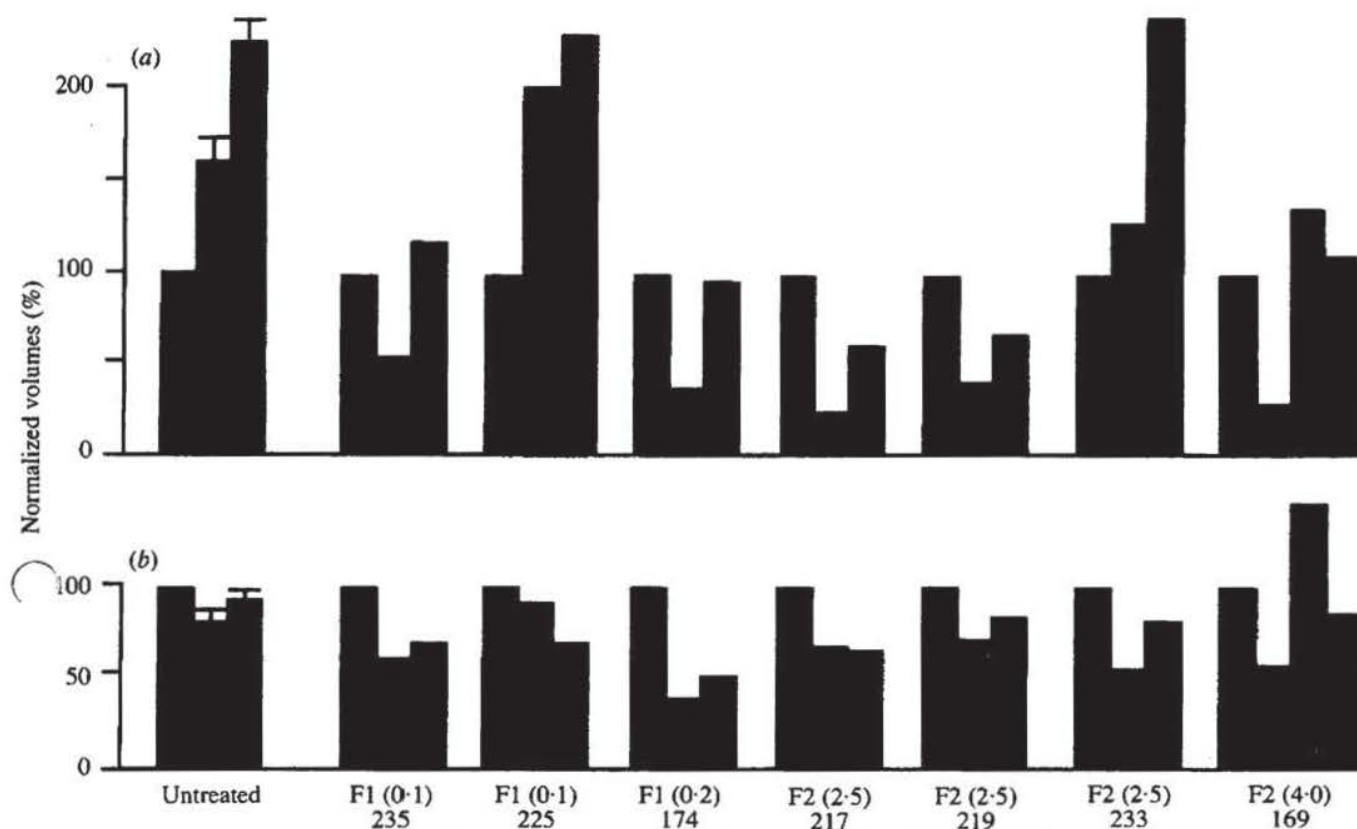
days 3 (early), 16 (mid) and 24 (late) of the cycle are illustrated in the Plate, figs 1–3 and in another case at days 2, 16 and 23 in the Plate, figs 7–9. Analysis of the data showed that >75% of the variance arises from interanimal variability. Average coefficients of variation for volumes measured in different cycles were in the range 14–19% for the endometrium and 6–10% for the myometrium.

The endometrium increased in size in the follicular phase of the menstrual cycle in 17 of 20 cycles (mean increase 60%, $P < 0.001$; early vs mid cycle volume) and this growth continued in the luteal phase in 18 of 20 cycles (mean increase 65%, $P < 0.001$; mid vs late cycle volume). Changes in the volume of the myometrium were smaller but a consistent pattern emerged in which a decrease in size was observed in 18 of 20 cycles in the follicular phase (mean decrease 16%, $P < 0.001$; early vs mid cycle). In the luteal phase the volume of the myometrium increased in 18 of 20 cycles (mean 10%, $P < 0.02$; mid vs late cycle volume). The net effect of the follicular phase shrinkage and luteal phase growth of the myometrium restored mean myometrium volume to near that recorded initially (94%, $P > 0.05$ compared with early cycle).

Effect of ICI 182,780 on the uterus

The effects of ICI 182,780 on the appearance of the uterus in MR images is shown in the Plate. Plate, figs 4–6 and 10–12 illustrate the mid corpus of the uterus at early, mid and late cycle, in individuals treated with the rapid- (F1) or slow- (F2) release formulations of ICI 182,780 respectively, compared with images recorded in control cycles in the same individuals (Plate, figs 1–3 and 7–9). The dramatic shrinkage of the endometrium (central high-signal zone) is immediately apparent; the myometrial changes are less obvious from visual inspection of the images but emerge clearly from quantitative image analysis.

In monkeys treated with ICI 182,780, the magnitude of changes in the volume of the endometrium and myometrium was dependent on whether or not individual monkeys were rendered anovulatory by the treatment. Where serum progesterone concentration (not shown) remained below 2 nmol/l in the second half of the menstrual cycle, animals were judged to be anovulatory; similarly where progesterone exceeded this value and remained elevated for at least 10 days, ovulation was assumed to have occurred. By this criterion, treatment with 0.1 or 0.2 mg ICI 182,780/kg daily (F1) blocked ovulation in three or four of the



TEXT-FIGURE 3. (a) Endometrium and (b) myometrium volumes in untreated and ICI 182,780-treated ovulatory monkeys. Tissue volumes at mid and late cycle, normalized to those recorded at the beginning of the cycle in each individual monkey, are compared with mean values (\pm S.E.M., $n=20$) for untreated controls. From the left, values are means \pm S.E.M. for untreated controls; monkeys receiving once daily injections of ICI 182,780 (0.1 or 0.2 mg/kg) (F1) for 25 days beginning on cycle day 3; monkeys receiving a single injection of ICI 182,780 (2.5 or 4 mg/kg) (F2) on day 3.

five monkeys respectively, in each dose group. Similarly, ovulation was blocked in three or five of the six monkeys receiving a single injection of 2.5 or 4 mg ICI 182,780/kg (F2). There was a tendency for the higher-dose groups to include fewer ovulatory cycles but this was not statistically significant with the small group sizes employed.

The mean changes in the volume of the endometrium and myometrium in ICI 182,780-treated animals are presented in Text-figs 2 and 3. Since absolute tissue volumes vary widely between individuals (Text-fig. 1), the effects of ICI 182,780 were assessed by normalizing the volume of tissue(s) recorded in each animal at the mid and late cycle observations to those recorded at the beginning of the cycle, prior to treatment, and by comparison with similarly normalized observations in the untreated controls. In monkeys rendered anovulatory by ICI 182,780 (Text-fig. 2), the normal follicular and luteal phase growth of the endometrium was blocked completely and tissue volume at mid and late cycle was significantly ($P<0.001$) less than that before treatment began in each of the treatment regimens.

Although shrinkage of the endometrium was most apparent during the first half of the cycle (mean decrease -61% compared with $+60\%$ control, $P<0.001$, at mid cycle), blockade of growth was sustained throughout (mean -67% compared with $+125\%$ control, $P<0.001$, at late cycle). When the occurrence of ovulation was accounted for, no significant differences emerged between the effects of the different formulations and doses of ICI 182,780, with the exception that the 2.5 mg dose (F2) appeared slightly less effective ($P<0.05$) than the 4.0 mg dose in the second half of the cycle. The volume of the myometrium in ICI 182,780-treated anovulatory monkeys (Text-fig. 2) decreased more rapidly than in controls in each treatment group from early to mid cycle (mean -35% compared with -16% control, $P<0.001$, at mid cycle) and this decline continued in the second half of the cycle (mean -54% compared with -6% control, $P<0.001$, at late cycle).

In monkeys in which treatment did not block ovulation (Text-fig. 3), the mean effect of ICI 182,780 on the endometrium in the first half of the cycle (-27% compared with $+60\%$ control, $P<0.01$) was

Explore Litigation Insights

Docket Alarm provides insights to develop a more informed litigation strategy and the peace of mind of knowing you're on top of things.

Real-Time Litigation Alerts



Keep your litigation team up-to-date with **real-time alerts** and advanced team management tools built for the enterprise, all while greatly reducing PACER spend.

Our comprehensive service means we can handle Federal, State, and Administrative courts across the country.

Advanced Docket Research



With over 230 million records, Docket Alarm's cloud-native docket research platform finds what other services can't. Coverage includes Federal, State, plus PTAB, TTAB, ITC and NLRB decisions, all in one place.

Identify arguments that have been successful in the past with full text, pinpoint searching. Link to case law cited within any court document via Fastcase.

Analytics At Your Fingertips



Learn what happened the last time a particular judge, opposing counsel or company faced cases similar to yours.

Advanced out-of-the-box PTAB and TTAB analytics are always at your fingertips.

API

Docket Alarm offers a powerful API (application programming interface) to developers that want to integrate case filings into their apps.

LAW FIRMS

Build custom dashboards for your attorneys and clients with live data direct from the court.

Automate many repetitive legal tasks like conflict checks, document management, and marketing.

FINANCIAL INSTITUTIONS

Litigation and bankruptcy checks for companies and debtors.

E-DISCOVERY AND LEGAL VENDORS

Sync your system to PACER to automate legal marketing.