

ILL# 161499334



Processed: 11/23/15

HSRS

*** Haematologica - RESEND**

Journal Title: Haematologica.

Volume: 84

Issue: 8

Month/Year: August 1999

Pages: 767-8+TOC+cvr w/acq
datestamp

Article Author: Carrasco et al.,

Article Title: Acute megaloblastic anemia: homocysteine levels are useful for diagnosis and follow-up.+TOC+acq date stamp on cover

Imprint: Roma : Il Pensiero Scientifico, [1974]-

ISSN: 0390-6078

Lender String:

*EYM,NUI,UMM,CLU,CUX,EYW,NEH,WAU,MNU,UPM,FHM,UAB,AUT,CUV,PUL

Notes ***RESEND, However we are missing the t


Special Instructions: ***RESEND, However we are missing the t

Note to Scanner: SCAN THIS SHEET!!

Trans. # 2409470



LENDING ARTICLE



Copy To:

UIU (1) - Interlibrary Borrowing
128 Library University of Illinois
1408 West Gregory Drive
Urbana, Illinois 61801
United States
United States

Borrowed From: EYM / MIUG

Interlibrary Loan
University of Michigan
Phone: 734-764-0295
Email: ill-lending@umich.edu

Courier Reply

1st Searched 2nd Searched

<input type="checkbox"/> NOS <input type="checkbox"/> Volume <input type="checkbox"/> Call #		
<input type="checkbox"/> NFC <input type="checkbox"/> Vol/Year don't agree <input type="checkbox"/> Other		
<input type="checkbox"/> Tightly Bound		
<input type="checkbox"/> Missing Pages		
<input type="checkbox"/> Bound w/o issue		
<input type="checkbox"/> Non-circ		
<input type="checkbox"/> Other		

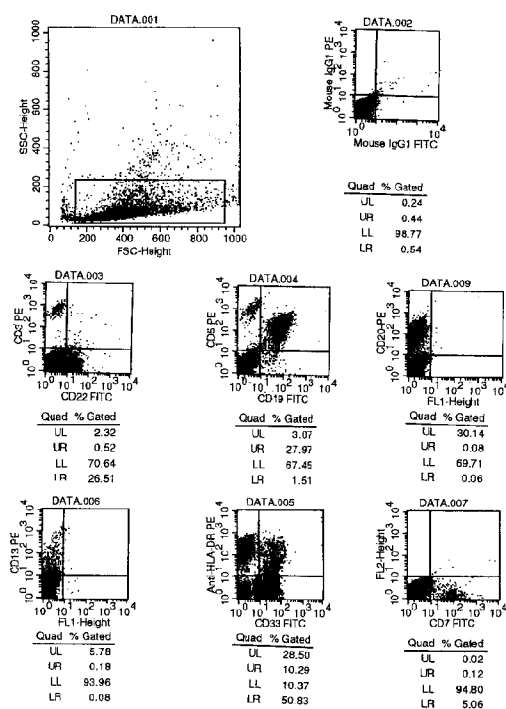


Figure 1. Light scatter properties of analyzed cells (top). The flow cytometric dot plots clearly show that virtually all CD19⁺ cells are positive for CD5 antigen and there are two cell populations with different HLA-DR antigen expression pattern. CD33 antigen is found to be the only antigen that expressed more than 50% of the cells and most of them are negative for HLA-DR antigen.

nosis but we do not have any doubts about the diagnosis because more than $10 \times 10^9/L$ cells expressed CD5, CD19, CD20 and CD22 (Figure 1).

The concomitant presentation of AML and CLL is extremely rare and the use of two-color flow cytometry to differentiate the cell populations demonstrates the utility of this technology in the diagnosis of unusual hematologic malignancies.

Mustafa Nuri Yenerel,* Ibrahim Hatemi,^o Hüseyin Keskin*

*Istanbul University, Istanbul Medical School, Department of Internal Medicine, Division of Hematology, Çapa, Istanbul; ^oHaseki State Hospital, Haseki, Istanbul, Turkey

Key words

CCL, AML, flow cytometry.

Correspondence

Mustafa Nuri Yenerel, MD, Istanbul University, Istanbul Medical School, Department of Internal Medicine, Division of Hematology, Çapa, Istanbul, Turkey. Fax: international +90.212.6311263.

References

- Caballero MD, Gonzalez M, Canizo MC, Orfao A, Nieto MJ, San-Miguel JF. Concomitant chronic lymphocytic leukemia (CLL) and acute myeloid leukemia. Complete remission of CLL achieved with high-dose cytosine arabinoside. *Leukemia* 1992; 6:856-8.
- Conlan MG, Mosher DF. Concomitant chronic lymphocytic leukemia, acute myeloid leukemia, and thrombosis with protein C deficiency. Case report and review of the literature. *Cancer* 1989; 63:1398-401.
- Rai KR, Patel DV. Chronic lymphocytic leukemia. In Hoffman R, Benz EJ, Jr, Shattil SJ, Furie B, Cohen HJ, Silberstein LE (eds): *Hematology: Basic Principles and Clinical Practice*. 2nd ed. Churchill Livingstone, New York, 1995, p 1308.
- Lima M, Porto B, Rodrigues M, et al. Cytogenetic findings in a patient presenting simultaneously with chronic lymphocytic leukemia and acute myeloid leukemia. *Cancer-Genet Cytogenet* 1996; 87:38-40.
- Mateu R, Bellido M, Sureda A, et al. Concomitant chronic lymphocytic leukemia and acute myeloid leukemia with an uncommon immunophenotype. *Am J Hematol* 1997; 56:281.
- Tamul KR, Meyers DC, Bentley SA, Folds JD. Two color flow cytometric analysis of concomitant acute myeloid leukemia and chronic lymphocytic leukemia. *Cytometry* 1994; 18:30-4.

Acute megaloblastic anemia: homocysteine levels are useful for diagnosis and follow-up

Sir,

Vitamin B₁₂ (cobalamin) and folic acid deficiencies lead to megaloblastic anemia (MA), and induce accumulation of methylmalonic acid (MMA) and homocysteine (HCY).¹ The most common presentation of MA is classical macrocytic anemia. Other presentations are acute megaloblastosis (AM) and masked megaloblastosis.^{2,3} In this report, we present a case of AM diagnosed and followed up by evaluation of HCY levels.

A 45-year old male was diagnosed as having Philadelphia-positive chronic myelogenous leukemia. Three years after diagnosis the patient developed a lymphoid blast crisis and was started on a chemotherapy protocol. The first consolidation treatment consisted of 6-mercaptopurine, methotrexate (MTX), VM-26 and cytarabine. MTX rescue with folinic acid was performed following standard guidelines. On day +14 a platelet count of $9 \times 10^9/L$ was found. Hb was 99 g/L, mean corpuscular volume (MCV) 92 fL and leukocyte count was $7.06 \times 10^9/L$ with 84% of neutrophils with hypersegmentation. Reticulocyte count was $0.053 \times 10^{12}/L$ (1.66%). Vitamin B₁₂ levels and red cell folate were 322 pmol/L (normal 150-1200) and 938 nmol/L (normal 441-1285), respectively. A BM aspirate revealed 30% of erythroid precursors with megaloblastic features and a 55% of myeloid precursors with increased size and no blast cells. Serum HCY levels were 38 $\mu\text{mol}/L$ (normal < 16). The

Table 1. Evolution of analytical parameters during folic acid and vitamin B₁₂ treatment.

	Pre-treatment Day -9	Onset Day 0	Post-treatment Day +9
Platelets (x10 ⁹ /L)	134	9	112
Leukocytes (x10 ⁹ /L)	6.76	7.06	5.72
Hemoglobin (g/L)	91	99	95
MCV (fL)	93	92	95.3
Reticulocytes (x10 ¹² /L)	0.037	0.053	0.163
Homocysteine (μmol/L)	-	38	9

AM, acute megaloblastosis; MCV, mean corpuscular volume.

patient was diagnosed as having AM and began treatment with folic acid 12 mg iv in one single dose and folic acid 5 mg/day po for 14 days and parenteral vitamin B₁₂ 2 mg/day for 4 consecutive days. After 10 days of treatment the platelet count increased to 112×10⁹/L and reticulocyte count to 0.163×10¹²/L (5.41%). Vitamin B₁₂ level was 716 pmol/L, red cell folate level 1,506 nmol/L and serum HCY level decreased to normal value (9 μmol/L) (Table 1).

Four different clinical forms of megaloblastosis have been described.^{3,4} The classical form has an insidious onset with frequent neurologic symptoms and macrocytic anemia. Vitamin B₁₂ and/or red cell folate levels are decreased. The second form is the subtle MA anemia with ill-defined clinical symptoms and decreased or borderline vitamin B₁₂ and folic acid levels with other abnormalities (dUST, HCY, MMA).² Masked megaloblastosis coexists with other deficiencies; MCV is normal or decreased.^{5,6} MA of acute onset is the rarest form.³ There are two clinical presentations; the masked undiagnosed classical MA with cytopenias of abrupt onset and the so-called AM.^{3,7} In AM severe thrombocytopenia develops in 1 to 3 weeks, MCV is normal or only moderately increased. This presentation is more frequent in patients with risk factors: parenteral nutrition, infection, dialysis or treatment with some antifolate drugs. Mortality is high.³ The reticulocyte count is low. Vitamin B₁₂ and red cell folate levels are normal. BM aspirate shows megaloblastic changes. Classically, dUST is used as a diagnostic test. Nevertheless, HCY serum assays provide a sensitive test for the diagnosis of AM, especially in its early stages.⁸ In vitamin B₁₂ deficiencies both HCY and MMA levels are high. In

folate deficiencies only HCY concentration is increased.^{9,10} HCY levels are also useful for AM follow-up of AM; levels return to normal after starting treatment with vitamin B₁₂ or folic acid. The evaluation of serum HCY levels is an easy and non-invasive test for the diagnosis and follow-up of AM.

Marina Carrasco, Angel Remacha, Anna Sureda,
Pilar Sardà, Rodrigo Martino, Jorge Sierra

Department of Hematology, Hospital de la Santa Creu i Sant Pau,
Barcelona, Spain

Key words

Acute megaloblastosis, folic acid, cobalamin, homocysteine

Correspondence

Angel Remacha Sevilla, MD, Laboratorio de Hematología,
Hospital de la Santa Creu i Sant Pau, Antoni Maria i Claret,
167, 08025 Barcelona, Spain. Phone: international +34-93-2919290 – Fax: international +34-93-2919192 – E-mail: 2107@hsp.santpau.es

References

- Green R. Metabolite assay in cobalamin and folate deficiency. *Baillière Clin Haematol* 1995; 8:533-66.
- Carmel R. Subtle cobalamin deficiency. *Ann Intern Med* 1996; 124:338-40.
- Remacha A, Gimferrer E. Las megaloblastosis agudas: revisión y reconsideración conceptual de las distintas formas de presentación de las megaloblastosis. *Biol Clin Hematol* 1984; 6:167-82.
- Carmel R. Pernicious anemia. The expected findings of very low serum cobalamin levels, anemia, and macrocytosis are often lacking. *Arch Intern Med* 1988; 148:1712-4.
- Spivak JL. Masked megaloblastic anemia. *Arch Intern Med* 1982; 142:2111-4.
- Bennett M, Koren A, Ludacer E. B12 deficiency in α -thalassemia. *N Engl J Med* 1984; 310:1058-9.
- Martinez E, Remacha A, Roca-Cusachs A. Acute exacerbation of folate-dependent chronic megaloblastosis. *Biol Clin Hematol*. 1992; 14:223-9.
- Vester B, Rasmussen K. High performance liquid chromatography method for rapid and accurate determination of homocysteine in plasma and serum. *Eur J Clin Chem Clin Biochem*. 1991; 29:549-54.
- Allen RH, Stabler SP, Savage DG, Lindenbaum J. Diagnosis of cobalamin deficiency: I: usefulness of serum methylmalonic acid and total homocysteine concentrations. *Am J Hematol* 1990; 34: 90-8
- Lindenbaum J, Savage DG, Stabler SP, Allen RH. Diagnosis of cobalamin deficiency: II: relative sensitivities of serum cobalamin, methylmalonic acid and total homocysteine concentrations. *Am J Hematol* 1990; 34:99-107.

Haematologica 1999; vol. 84, no. 8

Contents

(indexed by Current Contents/Life Sciences and in Faxon Finder and Faxon XPRESS, also available on diskette with abstracts)

editorial, comments and views

How safe is hydroxyurea in the treatment of polycythemia vera? 673-674

Autologous bone marrow transplantation for chronic myeloid leukemia 674

original papers

Short-term, serum-free, static culture of cord blood-derived CD34⁺ cells: effects of FLT3-L and MIP-1 α on *In vitro* expansion of hematopoietic progenitor cells
Gemma Capmany, Sergi Querol, José Antonio Cancelas, Joan García 675-682

Peripheral T lymphocyte cytokine profile (IFN γ , IL-2, IL-4) and CD30 expression/release during measles infection
Fabrizio Vinante, Mauro Krampera, Lorella Morosato, Antonella Rigo, Sergio Romagnani, Giovanni Pizzolo 683-689

3q21 and 3q26 cytogenetic abnormalities in acute myeloblastic leukemia: biological and clinical features
Nicoletta Testoni, Gabriela Borsaru, Giovanni Martinelli, Cristina Carboni, Deborah Ruggeri, Emanuela Ottaviani, Susanna Pelliconi, Paolo Ricci, Rocco Pastano, Giuseppe Visani, Alfonso Zaccaria, Sante Tura 690-694

Cleavage of the ALL1 gene in acute lymphoid leukemia before treatment disappears in relapse
Eduardo Anguita, Ana Villegas, Anna Serra, Fernando Ataulfo González, Paloma Roperio, Trinidad Contra, Giuseppe Saglio 695-698

Outcome of biphenotypic acute leukemia
Sally Killick, Estella Matutes, Ray L. Powles, Mike Hamblin, John Swansbury, Jennifer G. Treleaven, Athanasios Zomas, Ayad Atra, Daniel Catovsky . 699-706

A prospective study of α -interferon and autologous bone marrow transplantation in chronic myeloid leukemia
The Italian Cooperative Study Group on Chronic Myeloid Leukemia. Writing committee: Giovanna Meloni, Domenico Russo, Michele Baccharani, Nicoletta Testoni, Giovanni Martinelli, Renato Fanin, Eliana Zuffa, Gianantonio Rosti, Giuliana Alimena, Giuseppe Saglio, Franco Mandelli, Sante Tura 707-715

Favorable impact of low-dose fludarabine plus epirubicin and cyclophosphamide regimen (FLEC) as treatment for low-grade non-Hodgkin's lymphomas
Monica Bocchia, Catia Bigazzi, Silvia Marconcini, Francesco Forconi, Giuseppe Marotta, Renato Algeri, Francesco Lauria 716-720

Effect of adenosine derivatives on thrombus formation *in vitro* induced by shear stress
Marzia Menegatti, Gloria Cristalli, Luciana Gallo, Pier Mannuccio Mannucci, Francesco I. Pareti . 721-725

Lipoprotein(a) concentration is not associated with venous thromboembolism in a case control study
Giuseppe Lippi, Antonella Bassi, Giorgio Brocco, Franco Manzato, Maddalena Marini, Giancesare Guidi 726-729

decision making and problem solving

Long-term cost-effectiveness of low molecular weight heparin versus unfractionated heparin for the prophylaxis of venous thromboembolism in elective hip replacement
Monia Marchetti, Nicola Lucio Liberato, Nicola Ruperto, Giovanni Barosi 730-737

trends in hematology

Placental/umbilical cord blood transplantation
Girolamo Sirchia, Paolo Rebulla 738-747

the irreplaceable image

Homozygous form of the Pelger-Huët anomaly
Jesús Gastearena Erice, José María Arguiñano Pérez, Francisco Sala Pericás 748

Bilobulated circulating lymphocytes in persistent polyclonal B-cell lymphocytosis
Soledad Woessner, Lourdes Florensa, Blanca Espinet 749

Atypical clinical presentation of visceral leishmaniasis
José-Ángel Hernández, María Alba Bosch, Goretti Sauca 750

scientific correspondence

Immunosuppression due to MACOP-B does not seem to cure the antiphospholipid syndrome

Piero Maria Stefani, Francesco Pietrogrande, Roberto Sartori, Antonio Girolami. 751-752

New technology and changing parameters of leukapheresis for blood cell transplantation

Katharina Granzow, Roberta Schiavo, Inna Timofeeva, Gianalejandro Moroni, Armando Santoro, Salvatore Siena. 752

INR variability in anticoagulation with acenocoumarol: is it useful for identifying patients at risk of bleeding and thrombosis?

Patricia Casais, Analía Sánchez Luceros, Susana Meschengieser, Emilse Bermejo, Maria Angela Lazzari. 753-754

The frequency of allele α^{ULY} , a low expression allele of the gene encoding erythroid spectrin α -chain, in the Greek population

Issidora Papassideri, Marianna Antonelou, Fotini Karababa, Afrodití Loutradi-Anagnostou, Jean Delaunay, Lukas H. Margaritis. 754-755

Acute myeloid leukemia occurring in a patient with polycythemia vera in treatment with hydroxyurea

Emma Cacciola, Rossella Rosaria Cacciola, Patrizia Guglielmo, Fabio Stagno, Rosario Giustolisi. 755-756

Absence of p53 mutation in 15 cases of myeloid malignancies with structural rearrangements of 3q

Luz Muñoz, Camino Estivill, Anna Aventín, Conxa Boqué, Olga López, Josep F. Nomdedéu. 757-758

Invasive cerebral aspergillosis in a patient with aplastic anemia.

Response to liposomal amphotericin and surgery

Dolores López Rodríguez, Carmen Albo López, Esmeralda Benítez Cobos, Aida Jimenez Blanco, Angeles Fernández Fernández, Luiz Francisco Araujo. 758-759

Transient response of myeloma clone to pamidronate therapy

Alessandro Corso, Cesare Astori, Ester Orlandi, Patrizia Zappasodi, Luca Arcaini, Carlo Bernasconi. 759-760

A paradoxical side-effect of antiaggregating treatment with ticlopidine: the Moschowitz syndrome

Fabrizio Fabris, Guido Luzzatto, MariaTeresa Sartori, Iliá Zanella, Antonio Girolami. 760-762

Flow cytometry of cell suspensions from lymph nodes: immunophenotype, DNA content and proliferative rate are strongly correlated with histopathology diagnosis

Joaquín Sánchez, Josefina Serrano, Jose Manuel García, José Román, Javier Casaño, Antonio Torres. 762-763

Previous occurrence of life-threatening abdominal infection is not a contraindication to bone marrow transplantation

Marco Picardi, Carmine Selleri, Gennaro De Rosa, Catello Califano, Andrea Camera, Bruno Rotoli. 764-765

Splenic inflammatory pseudotumor mimicking primary splenic malignancy

Yeouda Edoute, Ariel Roguin, Zahava Gallimidi, Ofer Ben-Izhak, Pradeep Nagachandran, Haim Ben-Ami. 765-766

Concomitant chronic lymphocytic leukemia and acute myeloid leukemia diagnosed by two color flow cytometric analysis

Mustafa Nuri Yenerel, Ibrahim Hatemi, Hüseyin Keskin. 766-767

Acute megaloblastic anemia: homocysteine levels are useful for diagnosis and follow-up

Marina Carrasco, Angel Remacha, Anna Sureda, Pilar Sardà, Rodrigo Martino, Jorge Sierra. 767-768

announcements

advertisements

Haematologica


is a Latin adjective, neuter and plural,

used in this context as a noun:

it means "hematological subjects".

The appropriate English translation is therefore

Journal of Hematology.



On the cover.

Bone marrow aspirate smear. *Leishmania sp* within reticulo-endothelial macrophages. Note the platelet clump to compare with the sharper and stronger staining of *Leishmania sp*. (see p. 750).

Explore Litigation Insights

Docket Alarm provides insights to develop a more informed litigation strategy and the peace of mind of knowing you're on top of things.

Real-Time Litigation Alerts



Keep your litigation team up-to-date with **real-time alerts** and advanced team management tools built for the enterprise, all while greatly reducing PACER spend.

Our comprehensive service means we can handle Federal, State, and Administrative courts across the country.

Advanced Docket Research



With over 230 million records, Docket Alarm's cloud-native docket research platform finds what other services can't. Coverage includes Federal, State, plus PTAB, TTAB, ITC and NLRB decisions, all in one place.

Identify arguments that have been successful in the past with full text, pinpoint searching. Link to case law cited within any court document via Fastcase.

Analytics At Your Fingertips



Learn what happened the last time a particular judge, opposing counsel or company faced cases similar to yours.

Advanced out-of-the-box PTAB and TTAB analytics are always at your fingertips.

API

Docket Alarm offers a powerful API (application programming interface) to developers that want to integrate case filings into their apps.

LAW FIRMS

Build custom dashboards for your attorneys and clients with live data direct from the court.

Automate many repetitive legal tasks like conflict checks, document management, and marketing.

FINANCIAL INSTITUTIONS

Litigation and bankruptcy checks for companies and debtors.

E-DISCOVERY AND LEGAL VENDORS

Sync your system to PACER to automate legal marketing.