

TOPICAL NON-PRESERVED DICLOFENAC THERAPY FOR KERATOCONJUNCTIVITIS SICCA

M. Rolando, S. Barabino, S. Alongi, and G. Calabria

Department of Neurological and Vision Sciences
Ophthalmology R
University of Genoa, Italy

1. INTRODUCTION

Keratoconjunctivitis sicca, regardless of origin, is associated with variable levels of inflammation of the ocular surface.¹ Chronic inflammation induces and maintains the metaplastic changes that typically develop in the conjunctival epithelium of patients with this disease.^{2,3} Although inflammatory phenomena associated with KCS can be immunomediated and/or induced by local prostaglandin secretion, it is unknown which of the two mechanisms has the prevailing role in the genesis of injury. Nevertheless, it is reasonable to assume that inflammatory prostaglandins are liberated as a result of epithelial damage. In support of this hypothesis, a recent study demonstrated the efficacy of a therapy consisting of cycles of topically administered steroids in the treatment of KCS(4). However, the study also reported notable risks to other aspects of ocular structural health from the well known side effects of corticosteroids, e.g., intraocular hypertension and cataracts. A therapy with non-steroidal and non-preserved anti-inflammatory agents in association with tear substitutes could be an effective therapy for the reduction of inflammation of the ocular surface and its associated symptoms.

2. MATERIALS AND METHODS

Twelve patients (1 male, average age 49.6 yrs) suffering from KCS in both eyes were included in this pilot study. The diagnosis of KCS was based on the presence of typical symptoms and objective test results. Each patient exhibited at least two of the following subjective symptoms: burning, foreign body sensation, pain, blurred vision improved by

substitute tear instillation or photophobia. Objective tests include tear production (Schirmer I test <5.5 mm/5 min), break up time (BUT < 7 sec), positive staining of the inferior exposed ocular surface with 1% Lissamine green (Van Bijsterveld score scale).³ In addition, the distinction between patients with Sjogren and non-Sjogren dry eyes was determined by serologic⁶ and clinical⁷ evaluation for the presence of collagen or inflammatory disease. The subjects who suffered from non-dry eye related inflammation of the ocular surface, such as allergic, viral or bacterial conjunctivitis and ocular surgery, were excluded from the study. Specifically, patients with Rosacea, staphylococcal blepharitis and meibomian glands diseases were excluded.

Impression cytology was performed in both eyes of each patient following the Tseng⁹ modification of the technique originally described by Nelson.⁸ The results were classified according to the criteria outline by Tseng.⁹ In lieu of their previous substitute tear therapy, patients were treated with unpreserved Diclofenac 0.1% (Voltaren Ofta monodose, Ciba Vision, Italy) in one eye and unpreserved 0.3% hydroxypropylmethylcellulose with 0.1% dextran substitute tears (Dacriol monodose, Alcon, Italy) in the controlateral eye, 4 times a day for 15 consecutive days. A visual analogue scale (VAS) made up from a 10 cm line on which the patient could mark the level of his symptoms (Fig. 1). It was used to evaluate the changes in the symptoms in each eye from the beginning to the end of the study in each patient. Lissamine green staining and impression cytology tests were repeated at the end of the study. The Mann-Whitney statistical test was used to analyze the results.

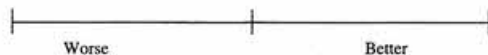


Figure 1. Visual Analogue Scale (100 mm).

3. RESULTS

The results of VAS, Lissamine green staining and impression cytology are summarized in Fig. 2. Analysis of the subjective symptom results indicates that Diclofenac 0.1% significantly improved the symptoms of KCS ($P = 0.03$). The ocular surface condition, evaluated by Lissamine green staining, was also significantly improved after

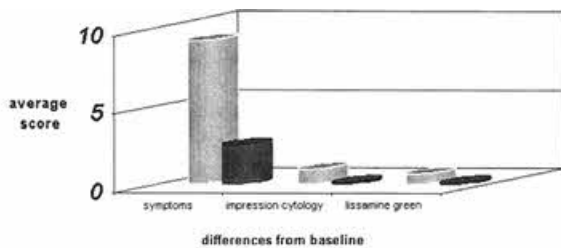


Figure 2. Differences from baseline scores for symptoms, impression cytology and Lissamine green staining of the ocular surface. Unpreserved 0.3% hydroxypropylmethylcellulose with 0.1% dextran (gray bars); Unpreserved 0.1% Diclofenac (black bars).

4. DISCUSSION

In our study the short-term topical use of unpreserved 0.1% Diclofenac was effective in improving symptoms and signs of KCS. This therapy was used in a group of patients where the therapy with substitute tears did not effectively improve the chronic ocular discomfort, and consequently, the quality of life of the patient. After 2 weeks of treatment we noticed an appreciable improvement ($P = 0.03$) in symptoms and therefore, in quality of life of the patients.

Lissamine green staining is an indicator of conjunctival epithelium damage.¹⁰ After 2 weeks of therapy, Lissamine green staining indicated that treatment with Diclofenac improved the condition of the conjunctival epithelium and therefore the ocular surface. Pflugfelder³ previously reported that there is decreased goblet cell density in the temporal bulbar conjunctiva in KCS. At the end of our study we noticed an increase of goblet cell density in this area, even if not statistically significant.

The rationale for the use of Diclofenac in KCS is related to recently published information on the pathogenesis of the disease. Inflammation of the ocular surface is either the origin of injury or can exacerbate an existing injury in eyes with KCS.¹¹ The primary insult that gives rise to inflammation is unclear. However, the inflammatory cascade results in the expression of high levels of pro-inflammatory cytokine mRNA in conjunctival cells of patients with Sjogren syndrome¹² and in general with dry eye.^{1,13} Corticosteroid treatment improves symptoms of these diseases appreciably, probably by interrupting the inflammatory cascade. Chronic treatment with these drugs, however, resulted in important side effects as pointed out in this and other studies.⁴

the ocular surface.¹⁵ Although rare, pathologic ocular surface changes as result of topically administered non-steroidal anti-inflammatory drugs after ocular surgery have been recently described.¹⁶ The number of patients in our study is too small to assess the complete safety of such a treatment in dry eyes. However, dry eye patients treated with topically administered non-steroidal anti-inflammatory drugs should be monitored for the appearance of corneal changes. Although further studies are necessary to establish the safety and the efficacy of long term therapy, the results of this study are encouraging and indicate that Diclofenac in association with tear substitutes can be effective for the treatment of patients with KCS.

REFERENCES

1. Brignole F, Pisella PJ, Goldschild M, De Saint Jean M, Goguel A, Baudoin C. Flow cytometric analysis of inflammatory markers in conjunctival epithelial cells of patients with dry eye. *Invest Ophthalmol Vis Sci*;41,6:1356 (2000).
2. Bron AJ, Mengher LS. The ocular surface in keratoconjunctivitis sicca. *Eye*; 3:428 (1989).
3. Rolando M, Terragna F, Giordano G, Calabria G. Conjunctival surface damage distribution in keratoconjunctivitis sicca. An impression cytology study. *Ophthalmologica* ;200:170 (1990).
4. Marsh P, Pflugfelder SC. Topical nonpreserved methylprednisolone therapy for Keratoconjunctivitis sicca in Sjogren syndrome *Ophthalmology*; 106:811 (1999).
5. Van Bijsterveld OP. Diagnostic tests in the sicca syndrome *Arch Ophthalmol*;82:10 (1969).
6. Ferreri G, Santamaria S. Autoimmunità in oftalmologia. *Apparato lacrimale. Boll. Oculi*; 74 suppl. 1:333 (1995).
7. Prause JU, Manthorpe R, Oxholm P, Schiødt M. Definition and criteria for Sjogren Syndrome used by contributors to the first international seminar on Sjogren Syndrome. *Scand J Rheumatol,suppl.* 61:17 (1986).
8. Nelson JD, Havener VR, Cameron JD. Cellular acetate impressions of the ocular surface. *Arch Ophthalmol*;101:1869 (1983).
9. Tseng SC. Staging of conjunctival squamous metaplasia by impression cytology. *Ophthalmology*;92:728 (1985).
10. Pflugfelder SC. Advances in the diagnosis and management of keratoconjunctivitis sicca. *Current opinion in Ophthalmology*;9:IV 50 (1998).
11. Stern ME, Beuerman RW, Fox RI, et al. The pathology of dry eye: the interaction between the ocular surface and lacrimal glands. *Cornea*;17:584 (1998).
12. Jones DT, Monroy D, Ji Z, Atherton SS, Pflugfelder SC. Sjogren's syndrome: cytokine and Epstein-Barr virus gene expression within the conjunctival epithelium. *Invest Ophthalmol Vis Sci*, 35:3493 (1994).
13. Tsubota K, Fujihara T, Saito K, Takeuchi T. Conjunctival epithelium expression of HLA-DR in dry eye patients. *Ophthalmologica*;213 (1):16 (1999).
14. Ku EC, Lee W, Kothari HV, Scholer DW. Effect of diclofenac Sodium on the arachidonic acid cascade. *Am J Med*;99 (4B):18 (1995).