

Topical Nonpreserved Methylprednisolone Therapy for Keratoconjunctivitis Sicca in Sjögren Syndrome

Peter Marsh, MD, Stephen C. Pflugfelder, MD

Objective: To review the efficacy and side effects of topical nonpreserved corticosteroid therapy for treatment of severe keratoconjunctivitis associated with Sjögren syndrome.

Design: Retrospective, noncomparative case series.

Participants: Twenty-one patients with Sjögren syndrome–associated keratoconjunctivitis sicca and annoying ocular irritation.

Intervention: Treatment with topical nonpreserved methylprednisolone sodium succinate.

Main Outcome Measures: Symptom severity, frequency of instillation of artificial tears, corneal fluorescein staining scores, resolution of filamentary keratitis, steroid-related side effects.

Results: Before starting methylprednisolone therapy, all patients were experiencing moderate-to-severe eye irritation despite prior punctal occlusion in most cases and frequent use of nonpreserved artificial tears by all. After 2 weeks of topical application, three to four times per day, moderate (43%) or complete (57%) relief of irritation symptoms was experienced by all patients and no complications were observed. An average decrease in corneal fluorescein scores of 2.6 ± 0.5 points (on a 12-point scale) was observed, and filamentary keratitis resolved in all ten eyes with this condition. Therapy was stopped after 2 weeks in eight patients, and six of these patients reported that their symptoms remained at a tolerable level for weeks to months. Lower dose steroid therapy was continued in the remaining patients, whose symptoms worsened after attempted weaning. Complications of corticosteroid therapy in patients receiving prolonged therapy included increased intraocular pressure in one patient at 3 months, worsening of pre-existing posterior subcapsular cataracts in one patient at 6 months, and formation of posterior subcapsular cataracts in another patient at 6 months.

Conclusions: These findings indicate that topical nonpreserved methylprednisolone is an effective treatment option for patients suffering from severe keratoconjunctivitis sicca who continue to experience bothersome eye irritation despite maximum aqueous enhancement therapies. They also suggest that inflammation is a key pathogenic factor in this condition. Careful monitoring is essential in dry eye patients treated with corticosteroids for more than 2 weeks because steroid-related complications (increased intraocular pressure and cataract formation) were observed after several months of therapy in this series. Because of the chronic nature of this disease and the likelihood of patients developing steroid-related complications with their long-term use, topical nonpreserved methylprednisolone therapy appears to be most appropriate for short-term “pulse” treatment of exacerbations of keratoconjunctivitis sicca. *Ophthalmology* 1999;106:811–816

Ocular irritation is often associated with deficiencies of one or more of the constituents of the tear film.¹ Among the different types of dry eye, aqueous tear deficiency resulting from lacrimal gland secretory dysfunction is associated with the greatest ocular discomfort and leads to ocular surface disease, termed *keratoconjunctivitis sicca*.^{1,2}

Aqueous enhancement therapies, including artificial tears and punctal occlusion, are currently the mainstay of therapy for patients with irritation due to aqueous tear deficiency.³ These treatments may decrease irritation symptoms and improve ocular surface disease in many patients, particularly those with mild disease. In contrast, patients with severe keratoconjunctivitis sicca, as typically seen in Sjögren syndrome, often complain of annoying irritation, photophobia, and intolerance to sustained visual effort despite maximum use of aqueous-enhancing therapies. These patients may also experience acute exacerbations of this condition, such as filamentary keratitis, that produce disabling symptoms.

The mechanism by which aqueous tear deficiency leads to ocular surface disease has been proposed to be secondary to increased tear osmolarity, desiccation of surface epithelium, and to a poorly lubricated ocular surface.⁴ There is

Originally received: May 5, 1998.

Revision accepted: November 25, 1998.

Manuscript no. 98235.

From the Ocular Surface and Tear Center, Bascom Palmer Eye Institute, Department of Ophthalmology, University of Miami School of Medicine, Miami, Florida.

A coauthor (SCP) and the University of Miami School of Medicine have jointly filed a patent for nonpreserved steroid therapy for dry eye.

Reprint requests to Stephen C. Pflugfelder, MD, Bascom Palmer Eye Institute, 900 NW 17th Street, Miami, FL 33136.

increasing evidence that inflammation may be an important factor in the pathogenesis of keratoconjunctivitis sicca. Squamous metaplasia, a pathogenic condition of reduced mucus production by the conjunctival epithelium, is more severe in the systemic autoimmune disease Sjögren syndrome than other forms of aqueous tear deficiency.² Inflammatory cell infiltration, consisting predominantly of T lymphocytes, has been reported to occur in the conjunctiva of patients with Sjögren syndrome.⁵⁻⁷ Further, abnormally increased expression of inflammatory cytokines such as interleukin-6 (IL-6) and upregulation of the cell surface immune adhesion molecules, human leukocyte antigen-DR (HLA-DR) and intercellular adhesion molecule-1 (ICAM-1), in the conjunctival epithelium have been reported to occur in Sjögren syndrome.^{2,8,9}

Based on these immunopathologic findings, we began treating patients with Sjögren syndrome and keratoconjunctivitis sicca who were experiencing severe and disabling symptoms that were unresponsive to aqueous enhancement therapy with a topical nonpreserved corticosteroid solution. Here we report the results of a retrospective review of the safety and efficacy of this therapy in 21 such patients with Sjögren syndrome. The results indicate that topically applied corticosteroids are a very effective therapy for the symptoms and ocular surface disease seen in these patients. Side effects were rare, but when present were those typically associated with topical steroid therapy (ocular hypertension and cataracts).

Patients and Methods

After approval by the University of Miami Institutional Review Board, the medical records of all patients treated by one physician (SCP) with topical corticosteroid solution for aqueous tear deficiency associated with Sjögren syndrome were reviewed. All patients had the diagnosis of either primary or secondary Sjögren syndrome. Criteria used for the diagnosis of primary Sjögren syndrome were those used previously² and included all of the following: 5-minute Schirmer test without anesthesia less than or equal to 5-mm strip wetting, interpalpebral conjunctival and corneal rose bengal and/or fluorescein staining, presence of one or more serum autoantibodies (rheumatoid factor \geq 1:160, antinuclear antibody \geq 1:160, Sjögren syndrome antibody A [SS-A] or Sjögren syndrome antibody B [SS-B]), xerostomia, and absence of a connective tissue disease. Those diagnosed as having secondary Sjögren syndrome met the above criteria for aqueous tear deficiency, ocular surface changes, and xerostomia but had been diagnosed as having either rheumatoid arthritis, systemic lupus erythematosus, or juvenile rheumatoid arthritis by a rheumatologist.

Records were reviewed to determine the nature and severity of symptoms patients experienced both before and after treatment. Change in symptoms was graded as no change, 1+ (irritation symptoms decreased, but still present), 2+ (irritation symptoms barely noticeable or absent most of the time), and 3+ (complete resolution of irritation symptoms). The type and frequency of topical medications used before methylprednisolone treatment were noted, as well as any change in the frequency of "as needed" medications (e.g., artificial tears) during or after treatment with topical corticosteroid. In cases in which this information was not clearly presented in the chart, patients were contacted by tele-

phone, and their history and symptomatic response were reviewed. Patients were also asked how long their irritation symptoms remained tolerable after stopping corticosteroid therapy.

Corneal fluorescein staining was graded from 0 (none) to 12 (most severe) by one physician (SCP) for each eye before and throughout the use of methylprednisolone according to a previously reported scoring system that has been routinely used for all patients evaluated by the investigator since 1992.¹

Patients were initially treated with the corticosteroid methylprednisolone. A topical solution of this steroid was prepared by the pharmacy of the Bascom Palmer Eye Institute by diluting intravenous methylprednisolone sodium succinate in nonpreserved sterile normal saline solution to final concentrations of 0.1% to 1%. Patients were dispensed bottles containing 5 ml of the steroid solution and were instructed to keep it refrigerated and to discard it after 3 weeks.

Initial therapy consisted of 1% methylprednisolone three to four times a day for 2 weeks. Patients were re-evaluated at that time, and based on their symptoms, the methylprednisolone solution was either stopped or was continued at a lower frequency (usually one drop per day) or dose (0.1%–0.5%). Two patients were changed from methylprednisolone to 1% hydroxymethylprogesterone (HMS; Allergan, Irvine, CA) and one was switched to 0.1% fluorometholone (FML; Allergan, Irvine, CA) to reduce corticosteroid-related side effects. Any change in symptoms or ocular surface disease after this change of medication was noted.

Results

Between December 1994 and June 1996, 21 patients were placed on topical nonpreserved methylprednisolone for treatment of the irritation symptoms or filamentary keratitis associated with primary or secondary Sjögren syndrome keratoconjunctivitis sicca. Diagnosis, demographic data, prior therapy, change in symptoms and corneal fluorescein staining score after 2 weeks of therapy, duration of therapy, and complications are presented in Table 1.

Nineteen of the 21 patients were women. Ages ranged from 31 to 79 years (mean, 59 years). Primary Sjögren syndrome was diagnosed in 17 of the 21 patients. Of the four patients diagnosed with secondary Sjögren syndrome, two had rheumatoid arthritis, one had systemic lupus erythematosus, and one had juvenile rheumatoid arthritis.

All patients were using nonpreserved topical lubricants (tears or ointments) before starting methylprednisolone. One patient was using topical vitamin A ointment, and one patient was using oral cyclosporin A. Two patients (cases 1 and 9 in Table 1) had been previously treated with preservative-containing corticosteroid preparations with some, but not complete relief of symptoms.

All patients reported improvement in irritation symptoms after 2 weeks of methylprednisolone therapy. Moderate improvement in symptoms was noted in 43% of patients (9 of 21), and 57% (12 of 21) of the patients experienced complete relief of their ocular irritation. One patient experienced mild discomfort after instilling the medication. Therapy was stopped after 2 weeks in eight patients who had complete relief of their symptoms. Six of these patients reported that their symptoms remained at a tolerable level with use of artificial tears for periods ranging from 2 weeks to 6 months.

The change in corneal fluorescein staining scores after 2 weeks of therapy is presented in Table 1. A mean decrease in corneal fluorescein scores of 2.6 ± 0.5 points (on a 12-point scale) was observed. Fluorescein staining scores decreased by at least 3 points in 30 (71%) of the 42 eyes, 7 eyes (17%) had a decrease in staining of 2 points, and 5 eyes (12%) had a decrease of 1 point. In addition

Table 1. Clinical Features of Steroid-treated Sjögren Syndrome Patients

Patient No.	Age (yrs)/ Gender	Cause of ATD	Prior Therapy*	Therapeutic Response after 2 Weeks			Treatment Duration§	Complications
				Symptoms†	Ocular Surface Disease‡			
					Right Eye	Left Eye		
1	73 /F	Primary SS	Bion, Inflamase Forte	3+	3+	3+	2 wks	
2	48 /F	Primary SS	Hypotears PF	3+	3+ (*)	3+ (*)	6 wks	
3	50 /F	Secondary SS (RA)	Bion	2+	1+	3+	6 mos	Increased IOP at 3 mos
4	66 /F	Primary SS	Hypotears PF	3+	3+	3+ (*)	2 wks	History of ocular HTN, switched to FML to minimize rise in IOP
5	45 /M	Primary SS	Celluvisc, oral CSA, oral Bromhexine	2+	2+	2+	2 mos, 3 wks	
6	67 /F	Secondary SS (RA)	Hypotears PF, 10% acetylcysteine drops, Refresh plus	2+	2+	2+	3 wks	
7	53 /M	Primary SS	Refresh plus, Refresh PM ointment	2+	1+	3+ (*)	7 mos	Worsening of pre-existing PSC OU at 6 mos
8	69 /F	Primary SS	Hypotears PF	2+	3+	2+	4 wks	
9	36 /F	Secondary SS (JRA)	Pred Forte, Aquasite	3+	3+	3+	52 wks	Early PSC at 6 mos, HMS started
10	65 /F	Primary SS	Bion, Refresh plus	3+	3+ (*)	3+ (*)	2 wks	
11	53 /F	Primary SS	0.01% transretinoic acid ointment, Refresh plus	2+	3+	3+	5 mos	
12	62 /F	Primary SS	Refresh plus	3+	3+	2+	2 wks	
13	68 /F	Primary SS	Refresh plus, Bion	3+	1+	3+	5 wks	Switched to HMS but stopped due to burning
14	79 /F	Primary SS	Refresh plus, Bion	3+	3+	3+	2 wks	
15	70 /F	Primary SS	Bion	3+	3+	3+	3 wks	
16	31 /F	Primary SS	HMS, Bion, Refresh	3+	3+	3+	2 wks	
17	67 /F	Primary SS	Bion	2+	3+	3+	6 wks	
18	62 /F	Secondary SS (SLE)	Refresh Plus	3+	3+	2+	2 wks	
19	49 /F	Primary SS	Refresh plus, Bion	2+	3+ (*)	3+ (*)	5 wks	Burning and discharge with MP
20	55 /F	Primary SS	Bion	2+	1+	1+	9 wks	
21	64 /F	Primary SS	Refresh Plus	3+	3+ (*)	3+ (*)	2 wks	

SS = Sjögren syndrome; PSC = posterior subcapsular cataract; IOP = intraocular pressure; HTN = hypertension; ATD = aqueous tear deficiency.
 * BION Tears (hydroxypropylmethylcellulose, dextran 70; Alcon Laboratories, Ft. Worth, TX), Inflamase Forte (1% prednisolone phosphate, CIBA Vision Corp, Duluth, GA), Hypotears PF (polyvinyl alcohol, PEG-400, dextrose, CIBA Vision Corp), Celluvisc (1% carboxymethylcellulose, Allergan, Inc, Irvine, CA), CSA = 2% cyclosporin emulsion, Refresh Plus (0.5% carboxymethylcellulose, Allergan), Refresh PM (mineral oil, petrolatum and lanolin alcohol, Allergan, Inc), Pred Forte (1% prednisolone acetate, Allergan, Inc), FML (0.1% fluorometholone, Allergan), Aquasite (polycarbophil, PEG-400, dextran 70, CIBA Vision), HMS (1% hydroxymethylprogesterone, Allergan, Inc, Irvine, CA), MP = methylprednisolone.
 † 1+ = slight improvement; 2+ = moderate improvement; 3+ = complete relief.
 ‡ 0 = no change; decrease in corneal fluorescein staining score by one point = 1+; 2 points = 2+; 3 points or resolution of filamentary keratitis = 3+; (*) = resolution of filamentary keratitis.
 § Duration of treatment at the time of the last follow-up examination.
 || Complications at the time of the last follow-up examination.

to a decrease in the intensity of fluorescein staining, a change in the pattern of staining from diffuse punctate staining to localized blotches, as demonstrated in Figure 1, was often observed. Filamentary keratitis resolved in all ten eyes with this condition (Fig 2). All patients reported a decrease in the use of topical lubricants while on methylprednisolone, in many cases from 10 to 15 times per day to once or twice per day.

Treatment duration ranged from 2 weeks to 1 year (mean, 9.1 weeks). In those patients still using the medication, the dose of methylprednisolone at the time of last evaluation ranged from 0.5% once a day to 1% twice a day. No complications were observed after 2 weeks of therapy. Complications that were likely to be related to more prolonged treatment included elevated intraocular pressure and cataracts. Intraocular pressure increased from the high teens to 23 mmHg in the right eye and to 24 mmHg in the left eye of one patient (case 3, Table 1) after 3 months of

therapy. Once the dose of methylprednisolone was tapered to 0.5% twice daily, the intraocular pressure returned to the high teens. Pre-existing posterior subcapsular cataracts in one patient (case 7, Table 1) worsened after 6 months of therapy. Another patient (case 9, Table 1) developed minimal posterior subcapsular cataracts in both eyes that were noted after 6 months of therapy. The patient was using 0.5% methylprednisolone once or twice a day at the time the cataracts were noted. The patient stated that she could not function off of the steroid, and the methylprednisolone was changed to hydroxymethylprogesterone (HMS) once a day. A follow-up examination 6 months after switching to hydroxymethylprogesterone revealed a distance visual acuity was 20/20 in each eye and no change in the cataracts.

Three patients were changed from methylprednisolone to less potent topical corticosteroids. One patient (case 4, Table 1) was switched to fluorometholone 0.1% once or twice daily because of

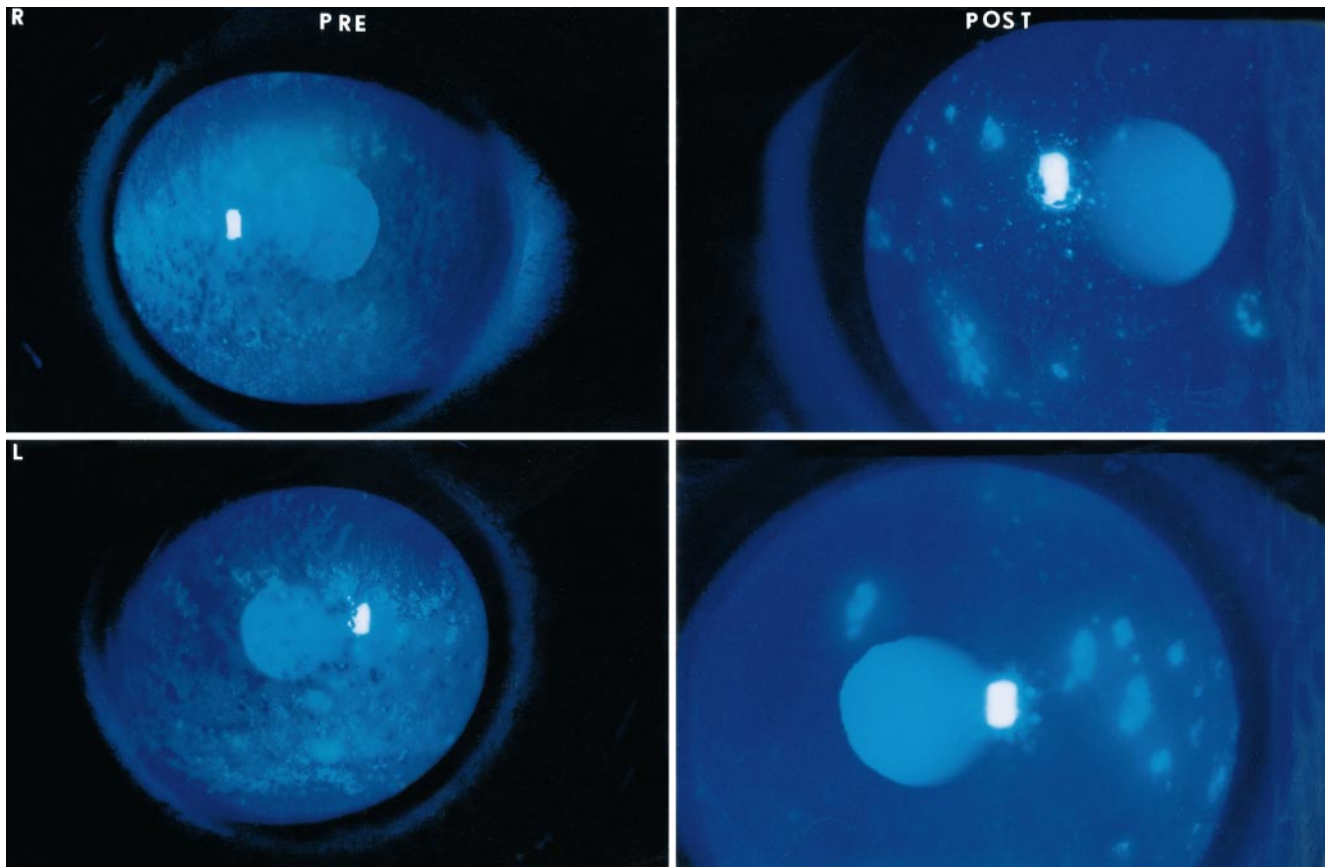
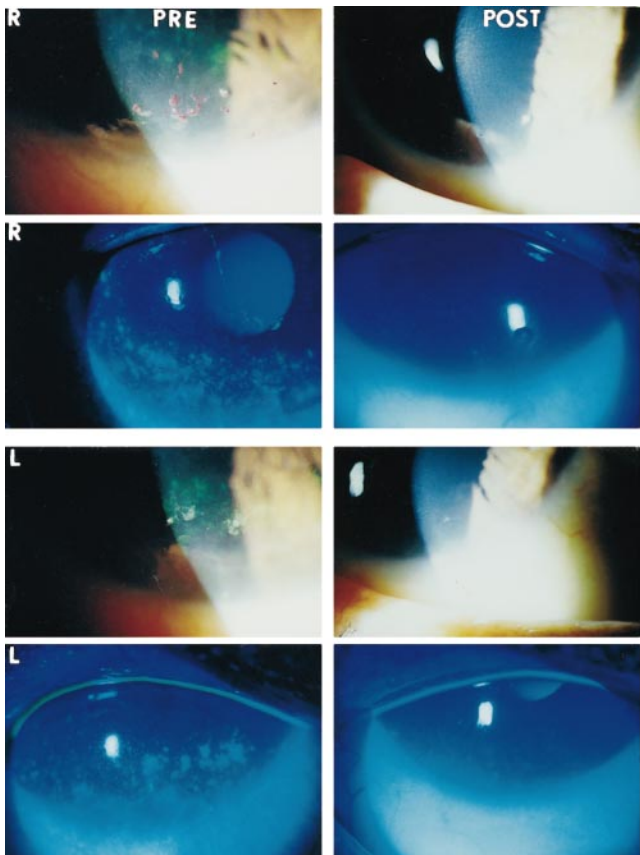


Figure 1. Patient 10. A decrease in area of fluorescein staining and change in staining pattern from a diffuse punctate exposure zone to blotches was observed (Table 1) after 2 weeks of nonpreserved methylprednisolone therapy. This was representative of the therapeutic response in most patients.



a history of steroid-responsive elevated intraocular pressure. One patient (case 9, Table 1) was switched to HMS 1% twice daily at first evidence of cataract formation. This dose controlled the patient's ocular irritation over 6 months of follow-up. Another patient (case 13, Table 1) was changed from methylprednisolone to HMS 1% to reduce the likelihood of steroid-induced complications, although she had no evidence of complications at that time. This patient had marked improvement in symptoms and ocular surface disease after 5 weeks of methylprednisolone treatment. After 1 month of using HMS 1% 1 to 2 times a day, she complained that the drop felt "thick" and clouded her vision. This medication was discontinued and the patient's ocular surface disease and symptoms were stable when they were re-evaluated 5 months later. No cases of infectious keratitis, corneal epithelial defects, or sterile corneal thinning were observed throughout the follow-up period.

Discussion

This retrospective review of our preliminary experience with the use of nonpreserved topical methylprednisolone

Figure 2. Patient 11. Two weeks of methylprednisolone reduced cornea punctate epitheliopathy, adherent mucus, and filaments in both eyes (Table 1).

indicates that topically applied corticosteroid produces rapid and dramatic improvement in ocular irritation symptoms and the keratoconjunctivitis sicca that develops in aqueous tear deficiency occurring in Sjögren syndrome. This therapy was used in a group of patients that had constant annoying and occasionally disabling irritation symptoms despite maximal aqueous enhancement therapy. It was offered to patients to improve the quality of their lives and to allow them to perform their daily activities in a more normal fashion.

All patients reported improvement in irritation symptoms within several days of starting steroid therapy, and improvement in keratoconjunctivitis sicca was clearly evident by the 2-week follow-up visit. One shortcoming of this study is that symptomatic response to therapy was based on a retrospective review of records rather than completion of a formal symptom survey. In most cases in this series, the effect of the steroid therapy on irritation symptoms and daily function was clearly documented at the 2-week follow-up visit, and a numeric value in the four-point symptom grading scheme that was used could be assigned without difficulty. After the 2-week "pulse" of topical methylprednisolone, the steroid was either stopped or patients were switched to a lower concentration of this medication and were instructed to taper their dosing frequency. In some cases, the medication was stopped after several additional weeks while other patients required prolonged low-dose therapy to control their irritation symptoms, under close monitoring for steroid-related complications.

It is interesting that irritation symptoms remained at a tolerable level in many patients for weeks to months after the steroid was stopped. This suggests that steroids may decrease or eliminate the factors that cause irritation in keratoconjunctivitis sicca and that they are efficacious for treatment of acute exacerbations of this condition. No complications were observed at the 2-week follow-up examination that was performed in all patients. Steroid-related complications were observed in three patients receiving prolonged topical steroid therapy. These included ocular hypertension in one patient after 3 months and posterior subcapsular cataracts in two patients after 6 months of treatment.

Keratoconjunctivitis sicca and Sjögren syndrome are established risk factors for microbial keratitis and sterile corneal ulceration.⁴ Neither of these corneal complications was observed in this series. Because of their immunosuppressive effects, corticosteroids could potentially increase the risk for developing microbial keratitis or worsen this condition if it should develop during therapy. Corticosteroids also suppress corneal wound healing, and they could inhibit healing of sterile corneal ulcers.¹⁰ Therefore, they should not be used in patients with keratoconjunctivitis who have corneal epithelial defects, stromal thinning, or stromal infiltrates.

Because of the chronic nature of Sjögren syndrome keratoconjunctivitis and the likelihood of patients developing steroid-related complications with their long-term use, it appears that topical nonpreserved methylprednisolone is most appropriate for short-term pulse therapy of acute disease exacerbations. Longer term corticosteroid therapy should be reserved only for patients with aqueous tear deficiency who have disabling irritation symptoms or ocular

surface disease (such as filamentary keratitis) that decreases their visual acuity and their ability to function. These patients need to be informed of the risks of therapy and to be evaluated at frequent intervals to look for signs of steroid-related complications.

The unparalleled anti-inflammatory efficacy of corticosteroids has prompted the investigation of regimens for treatment of systemic inflammatory diseases that minimize systemic side effects.¹¹⁻¹³ Strategies intended to minimize complications of systemic steroid therapy have included the use of lower doses for rheumatoid arthritis and enteric-coated "site-specific" preparations that facilitate delivery of the medication to the diseased intestinal mucosa, and minimize systemic absorption, in Crohn disease.¹¹⁻¹³ The improved quality of life and reduced end-organ damage reported in these clinical trials were thought to outweigh the minimal corticosteroid-related side effects that were observed.¹¹⁻¹³

Other steroid moieties with less potential to cause ocular toxicity than methylprednisolone sodium succinate may also prove to be useful for therapy of keratoconjunctivitis sicca. Methylprednisolone was used in our dry eye patients because it could be prepared as a nonpreserved aqueous preparation to avoid the well-documented toxicity associated with benzalkonium chloride, the preservative in all commercially available ophthalmic steroids.^{14,15} Furthermore, methylprednisolone has proven efficacy for pulse intravenous therapy of systemic and ocular inflammatory diseases.¹⁶ Several of our patients continued to experience improvement in their irritation symptoms after they were switched to fluorometholone or hydroxymethylprogesterone, two topical corticosteroids that have a lower reported propensity to raise intraocular pressure than prednisolone.^{17,18} Because of their lower potential for complications, these less toxic steroids appear to be viable options if they are formulated without preservatives. Another agent that could be considered is loteprednol etabonate, a corticosteroid that is reported to have greater specificity for ocular surface epithelial cells, reduced intraocular activity, and a lower propensity to raise intraocular pressure.¹⁹

The findings in our study suggest that ocular surface inflammation plays an important pathogenic role in the ocular irritation and ocular surface disease that develop in aqueous tear deficiency. This is further supported by the improvement in irritation symptoms and ocular surface disease that have been observed from topical therapy with the immunosuppressive agent cyclosporin A.²⁰ Indeed, immunopathologic studies show evidence of immune activation of the conjunctival epithelium in Sjögren syndrome. Compared with normal eyes, a significantly greater percentage of conjunctival epithelial cells from patients with Sjögren syndrome express the immune adhesion molecules, HLA class II and ICAM-1 antigens.^{8,9} Furthermore, significantly elevated concentrations of messenger RNAs (mRNAs) encoding the inflammatory cytokines tumor necrosis factor- α , interleukin-1 α , and IL-6 have been found in the conjunctival epithelium of patients with Sjögren syndrome compared to normal control subjects.^{8,21} Corticosteroids decrease both production and release of these inflammatory cytokines,^{22,23} and inhibition of their production and release has been

Explore Litigation Insights

Docket Alarm provides insights to develop a more informed litigation strategy and the peace of mind of knowing you're on top of things.

Real-Time Litigation Alerts



Keep your litigation team up-to-date with **real-time alerts** and advanced team management tools built for the enterprise, all while greatly reducing PACER spend.

Our comprehensive service means we can handle Federal, State, and Administrative courts across the country.

Advanced Docket Research



With over 230 million records, Docket Alarm's cloud-native docket research platform finds what other services can't. Coverage includes Federal, State, plus PTAB, TTAB, ITC and NLRB decisions, all in one place.

Identify arguments that have been successful in the past with full text, pinpoint searching. Link to case law cited within any court document via Fastcase.

Analytics At Your Fingertips



Learn what happened the last time a particular judge, opposing counsel or company faced cases similar to yours.

Advanced out-of-the-box PTAB and TTAB analytics are always at your fingertips.

API

Docket Alarm offers a powerful API (application programming interface) to developers that want to integrate case filings into their apps.

LAW FIRMS

Build custom dashboards for your attorneys and clients with live data direct from the court.

Automate many repetitive legal tasks like conflict checks, document management, and marketing.

FINANCIAL INSTITUTIONS

Litigation and bankruptcy checks for companies and debtors.

E-DISCOVERY AND LEGAL VENDORS

Sync your system to PACER to automate legal marketing.