

The EOG evaluates the retinal pigment epithelium (RPE) and the RPE-photoreceptor outer segment complex; however, it is not necessarily linked to visual field constriction. Taking into account these findings, both peripheral visual field and electrophysiologic tests (ERG and EOG), could be necessary to evaluate visual function impairment in each patient treated by vigabatrin. A larger population sample should be studied over a longer period to determine the prevalence and course of visual impairment associated with vigabatrin therapy and to evaluate the most sensitive and earlier diagnostic tool. The results obtained could be useful in understanding the pathogenesis of this disorder.

GEMA REBOLLEDA, MD
 FRANCISCO J. MUÑOZ-NEGRETE, MD
 CONSUELO GUTIERREZ, MD
 Madrid, Spain

References

1. Daneshvar H, Racette L, Coupland SG, et al. Symptomatic and asymptomatic visual loss in patients taking vigabatrin. *Ophthalmology* 1999;106:1792-8.
2. Arndt CF, Derambure P, Defoort-Dhellemmes S, Hache JC. Outer retinal dysfunction in patients treated with vigabatrin. *Neurology* 1999;52:1201-5.

Author's reply

Dear Editor:

We appreciate the authors' validation of our findings with respect to visual field constriction in patients taking vigabatrin. In all, we found scotopic ERG abnormalities in 43% of all eyes and photopic abnormalities in 29% of all eyes of patients taking vigabatrin. In addition, a subnormal Arden ratio on the EOG was observed in 41% of eyes.

We remain cautious about overinterpreting the significance of electrophysiologic abnormalities in patients taking vigabatrin because it is not yet clear whether these abnormalities are indicative of present or future functional abnormalities or whether they are in fact the normal electrophysiologic correlates of vigabatrin therapy.

DAVID H. ZACKON, MD, FRCSC
 Ottawa, Ontario, Canada

Our Apologies

Dear Editor:

We wish to correct two errors in our manuscript, "Two Multicenter, Randomized Studies of the Efficacy and Safety of Cyclosporine Ophthalmic Emulsion in Moderate to Severe Dry Eye Disease" (*Ophthalmology* 2000;107:631-9).

In Figure 1, the *P* value depicted for "CsA 0.1%," six month time point, did not match the text. In Figure 4, an incorrect data set was plotted. The correct figures appear here. These mistakes probably originated at the time of the revisions and we appreciate the opportunity to correct them.

We apologize for any inconvenience this may have caused.

KENNETH SALL, MD
 Bellflower, California

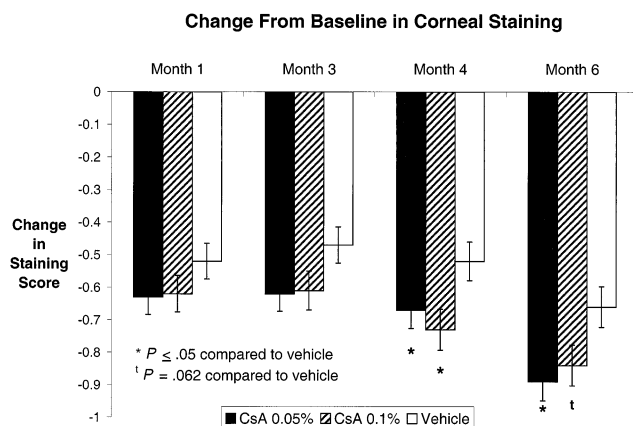


Figure 1. Change from baseline in corneal staining. Mean value ± standard error. Graded on a scale from 0 to 5.

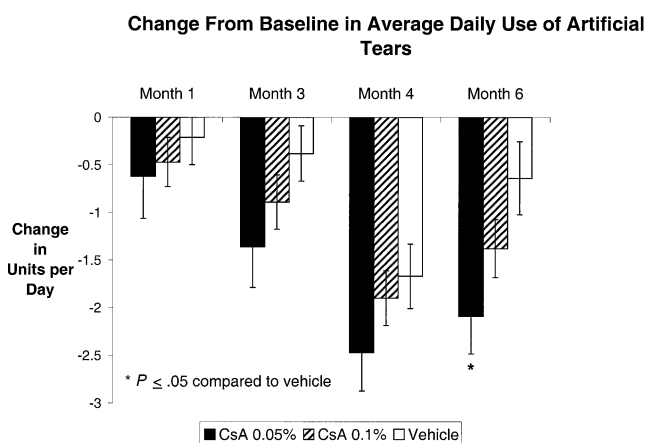


Figure 4. Change from baseline in assigned lubricating eyedrop use. Mean value ± standard error.

Malignant Glaucoma (Aqueous Misdirection) after Pars Plana Vitrectomy

Dear Editor:

The article by Massicotte and Schuman (*Ophthalmology* 1999;106:1375-9) describes two cases of a "malignant glaucoma-like syndrome" after pars plana vitrectomy. Both eyes developed elevated intraocular pressure (IOP) and axial shallowing of the anterior chamber after surgery. One patient was treated with Nd:YAG peripheral iridotomy (PI) with hyaloidotomy and intracameral tissue plasminogen activator. The other patient received a surgical peripheral iridectomy through the pars plana.

A possible confounding factor in both of these cases was the use of intraocular C₃F₈ as part of the original procedure. This probably contributed to the development of aqueous misdirection, the term we prefer, and elevated IOP. The authors removed gas with only a transient drop in IOP and noted persisting shallowing of the anterior chamber. Ultrasound biomicroscopy (UBM) showed no other reason for axial anterior chamber shallowing and elevated IOP, such as annular choroidal detachment. One might argue that case 2 may have had angle closure with pupillary block because a