

MAJOR REVIEW

Topical Ophthalmic Cyclosporine: Pharmacology and Clinical Uses

Eric Donnenfeld, MD,¹ and Stephen C. Pflugfelder, MD²

¹*Ophthalmic Consultants of Long Island and Connecticut, Rockville Centre, New York, USA;*
and ²*Ocular Surface Center, Department of Ophthalmology, Baylor College of Medicine, Houston, Texas, USA*

Abstract. Cyclosporine has been used successfully as a systemic immunomodulator for more than two decades, and numerous studies have investigated its mechanisms of action. In 2003 an ophthalmic formulation, cyclosporine 0.05% ophthalmic emulsion, was approved by the FDA to treat dry eye disease. Topical cyclosporine emulsion has also been investigated for treatment of other ocular surface disorders that may have an immune-based inflammatory component. In these trials, cyclosporine 0.05% ophthalmic emulsion has shown efficacy for management of posterior blepharitis, ocular rosacea, post-LASIK dry eye, contact lens intolerance, atopic keratoconjunctivitis, graft-versus-host disease, and herpetic stromal keratitis. As these disorders are often refractory to other available treatments, ophthalmic cyclosporine is a welcome nontoxic adjunct or replacement to potentially toxic topical or systemic immunosuppressive therapies. (*Surv Ophthalmol* 54:321–338, 2009. © 2009 Elsevier Inc. All rights reserved.)

Key words. atopic keratoconjunctivitis • blepharitis • contact lens intolerance • dry eye disease • graft-versus-host disease • herpetic stromal keratitis • LASIK • meibomian gland disease • ocular rosacea

I. Introduction

Cyclosporine 0.05% ophthalmic emulsion (Restasis; Allergan, Inc., Irvine, CA) has been available as an FDA-approved treatment for dry eye disease since 2003. Given its efficacy for treatment of dry eye, a number of clinicians and researchers have investigated the effectiveness of topical cyclosporine emulsion for treatment of other ocular surface and corneal conditions. Such disorders include those with signs and symptoms that overlap those of dry eye disease and those that appear likely to respond to immunomodulatory therapy.

We begin by reviewing what is known about the mechanism of action for cyclosporine at the molecular level and the use of cyclosporine as a systemic immunosuppressant to minimize rejection of solid

organ transplants and to treat severe ophthalmic inflammatory conditions. We also discuss the challenges in developing an effective ophthalmic formulation of cyclosporine and the effectiveness of its tissue penetration after topical ophthalmic administration. Many of the pharmacological effects of topical ophthalmic cyclosporine administration are readily reconciled with our understanding of its molecular mechanism of action, although there is still much to learn.

We then review in detail recently conducted studies evaluating the effectiveness of topical cyclosporine treatment for ocular disorders such as posterior blepharitis/meibomian gland disease, ocular rosacea, LASIK-associated dry eye, contact lens intolerance, and graft-versus-host disease. We

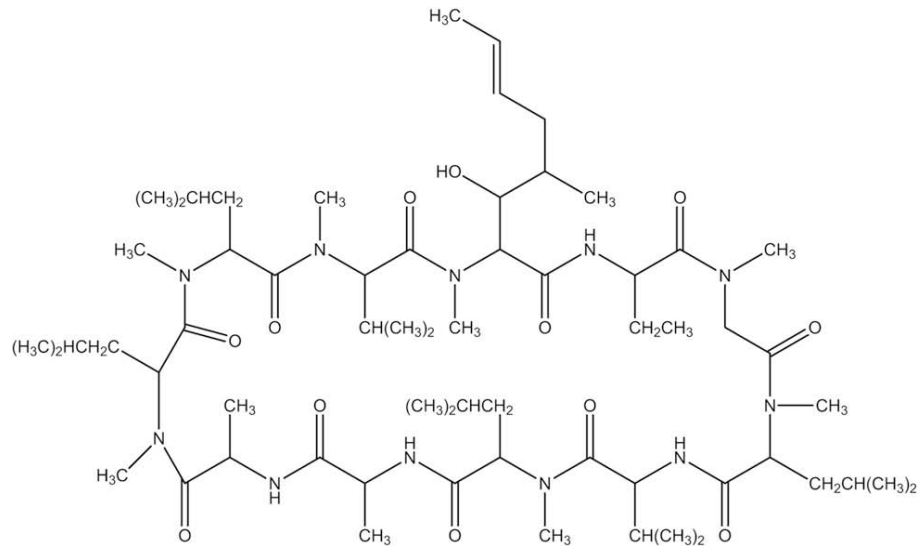


Fig. 1. Structure of cyclosporine (obtained from United States National Library of Medicine, Chemical Information [ChemIDplus Advanced] database. Accessed on March 3, 2008, at http://chem.sis.nlm.nih.gov/chemidplus/ProxyServlet?objectHandle=Search&actionHandle=transferStructure&nextPage=chemidheavy.jsp&responseHandle=JSP&superlistid=079217600&TRANSFER=true&MOLFILE_REFERENCE=&QF10=).

strive to present the best evidence that is currently available regarding the efficacy of cyclosporine 0.05% ophthalmic emulsion in the treatment of these ocular disorders. Our aim is to provide perspectives on how cyclosporine is currently being used clinically in the treatment of ocular disorders, but not to provide a definitive commentary on efficacy or specific recommendations for therapy.

II. Cyclosporine Mechanism of Action

Cyclosporine is a cyclic undecapeptide produced by the fungi *Tolypocladium inflatum* and *Beauveria nevus* (Fig. 1). Its mechanism of action has been very extensively studied because of its widespread use as an immunosuppressant to control rejection of solid organ transplants and to treat autoimmune diseases. Research on its mechanism of action initially focused on the molecule's ability to inhibit activation of T lymphocytes. Later it was appreciated that cyclosporine had other activities in a variety of cell types, such as inhibition of apoptosis. These effects of cyclosporine are mediated by binding to two cytoplasmic proteins called cyclophilin A and cyclophilin D. Cyclophilins are peptidyl-prolyl isomerases, which are proteins that have chaperonin activity able to catalyze refolding of other misfolded proteins.

Cyclosporine binding to cyclophilin A ultimately causes inhibition of T-lymphocyte activation.^{37,45} The cyclosporine-cyclophilin A complex binds to and inhibits the activity of the serine/threonine

phosphatase calcineurin (Fig. 2).^{37,59,70} Calcineurin normally dephosphorylates the nuclear factor for T-cell activation (NF-AT) in the cytoplasm of cells in response to elevated levels of intracellular calcium, an indirect consequence of antigen binding to the T-cell receptor on the cell surface.^{45,125} Dephosphorylated NF-AT is transported to the nucleus where it promotes transcription of a number of genes whose protein products participate in T-cell activation, most notably interleukin 2 (IL-2).^{45,52} It is believed that calcineurin is transported to the nucleus with NF-AT in order to maintain its dephosphorylated state. Secreted IL-2 binds to its receptors on the T-cell surface, stimulating cell division by a self-propagating autocrine and paracrine loop. Cyclosporine-mediated inhibition of calcineurin blocks dephosphorylation of NF-AT in the cytoplasm, thereby preventing its transport to the nucleus and preventing increased transcription of the IL-2 gene and other genes involved in T-cell activation.^{45,52,125}

The calcineurin/NF-AT system has been best studied in T-cells, but is broadly distributed among other cell types. Calcineurin is capable of dephosphorylating at least four different isoforms of NF-AT with varied roles.⁵² Evidence suggests that calcineurin/NF-AT signaling is involved in cytokine and chemokine production by mast cells and eosinophils.²⁷ Calcineurin/NF-AT signaling is important for gene expression in skeletal muscle and for cardiac growth and function.²⁷ Calcineurin and NF-AT are present in epidermal keratinocytes from healthy and psoriasis patients, and cyclosporine-

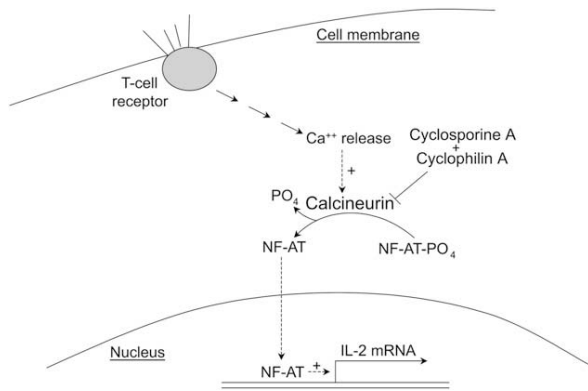


Fig. 2. Role of calcineurin in T-cell activation. When the T-cell receptor on the cell surface is bound by an appropriate ligand, a multistep intracellular signaling process begins, culminating in the release of calcium. Calcium stimulates the phosphatase calcineurin, which dephosphorylates the phosphorylated form of NF-AT. Dephosphorylated NF-AT can now migrate to the nucleus, where it stimulates transcription of the gene for IL-2 (among many others). The cyclosporine–cyclophilin A complex (but not cyclophilin A alone) binds to calcineurin, inhibiting its dephosphorylating activity and preventing translocation of NF-AT to the nucleus. NF-AT = nuclear factor for T-cell activation.

mediated inhibition of calcineurin has been demonstrated in these cells.^{8,92} Calcineurin and NF-AT are present in retinoblastoma cells as well, and cyclosporine treatment of retinoblastoma cell lines reduced proliferation and induced apoptosis.³⁵ Additional substrates of the calcineurin phosphatase activity, other than NF-AT, have been identified.⁵⁹ Clearly there is much to be learned about the roles of these signal transduction pathways in various cell types, and inhibition of calcineurin activity by the cyclosporine–cyclophilin A complex may have effects that have not yet been identified. It should be noted, however, that the sensitivity of T-cell activation to clinically achievable concentrations of cyclosporine depends on the relatively low calcineurin levels in those cells. Calcineurin levels in cardiac tissues, for example, are about 10-fold greater than in cells of the immune system, and this probably accounting for the less dramatic effects of cyclosporine on these cells.²⁷

Cyclosporine binding to cyclophilin D is thought to be primarily responsible for its inhibition of apoptosis, or programmed cell death.¹²² The cyclosporine–cyclophilin D complex binds to and prevents opening of the mitochondrial permeability transition (MPT) pore.⁶⁸ Opening of this pore in response to cellular stress or damage is an early step in the apoptosis cascade. When the MPT pore opens, mitochondrial proteins are released from the intermembrane space. Some of these appear to act directly in apoptosis, such as nucleases that degrade

DNA, and others, such as cytochrome *c*, activate a cascade of latent, apoptosis-specific proteases in the cytosol called caspases.³⁹ Cyclosporine binding of cyclophilin D can inhibit damage-induced cell death in a number of cell types, including neuronal and cardiac tissues.^{72,115,122} Cyclosporine significantly reduced apoptosis of conjunctival epithelial cells, as assessed by DNA fragmentation and levels of activated caspase-3, in an experimental murine model of dry eye.¹¹⁴ Evidence suggests that calcineurin inhibition by the cyclosporine–cyclophilin A complex may also contribute to inhibition of apoptosis by blocking dephosphorylation and consequent activation of BAD, a proapoptotic protein anchored to the outer mitochondrial membrane.¹²³

III. Systemic Use of Cyclosporine as an Immunosuppressant and Immunomodulator

Systemically administered cyclosporine was introduced to prevent rejection of solid organ transplants in 1983 and has been widely used since for kidney, heart, liver, and lung allografts.^{29,108} Successful immunosuppression after organ transplantation appears to require cyclosporine concentrations in the target tissue of 3 to 10 $\mu\text{g/g}$.^{46,98,99} To achieve this, daily doses of 5 to 15 mg/kg (depending in part on the formulation used) are administered orally or intravenously, resulting in trough cyclosporine concentrations in serum ranging from 200 to 400 ng/ml (Neoral [package insert]. East Hanover, NJ: Novartis Pharmaceuticals Corp; 2005). The most severe side effect of cyclosporine dosing in this range is nephrotoxicity.¹⁰⁸ Other side effects include hypertension, gingival hyperplasia, and increased risk of opportunistic infections.

Orally administered cyclosporine is also used for treatment of rheumatoid arthritis, moderate to severe psoriasis, and inflammatory bowel disease, often in combination with other therapeutics.^{40,41,60,87,92,99} Lower daily doses (2.5–5 mg/kg) than for transplant patients are used for these conditions, resulting in lower trough cyclosporine concentrations in serum ranging from 75 to 100 ng/ml.^{40,60,92}

Systemically administered cyclosporine immunosuppressive therapy has been useful to control rejection following limbal allograft surgery as well as for severe ocular inflammatory conditions such as uveitis and Behçet disease.^{17,25,30,53,58,63,71,75,78} Daily doses of 2 to 5 mg/kg are used, and combinations of therapeutics may be employed to reduce the cyclosporine dose over the long term.⁵⁸

Systemic cyclosporine has been used to supplement chemotherapy for retinoblastoma. Cyclosporine is

known to inhibit the P-glycoprotein-mediated multi-drug resistance pump, thereby increasing the residence time and efficacy of chemotherapeutic agents. As noted earlier, cyclosporine inhibition of the calcineurin/NF-AT pathway may also reduce proliferation and increase apoptosis of retinoblastoma cells.³⁵

IV. Ophthalmic Use of Cyclosporine: Pharmacy Formulation

Cyclosporine formulated by a pharmacy has been used for topical treatment of a number of ocular inflammatory diseases. Chief among these is vernal keratoconjunctivitis, a condition that primarily affects young (<10 years) males. Usually it is treated with antihistamines, mast-cell inhibitors, and topical or systemic steroids. In severe cases, 18 of 21 children experienced symptomatic relief within 3 to 4 days with cyclosporine 2%, and 16 of 21 were controlled during the 6-week treatment, but only 5 of 21 patients needed no other therapy 2 months after discontinuation.¹⁶ A trial of 20 patients had similar results: signs and symptoms were controlled while taking cyclosporine 2%, but recurred when treatment ceased.¹⁰² In another trial of 24 children taking cyclosporine 2%, a significant difference was found versus vehicle in subjective ($p < 0.005$) and objective ($p < 0.001$) scores, and at 4 months, serum eosinophil cationic protein levels were lower than before treatment ($p = 0.009$).⁸⁸ Assessment of 52 children with severe vernal keratoconjunctivitis who received cyclosporine 1.25% or 1% for 4 months found that subjective symptoms and objective signs were significantly decreased at 2 weeks and at 4 months ($p < 0.001$).¹⁰⁷ The minimal concentration of cyclosporine in this oil-based pharmacy formulation for controlling shield ulcers associated with vernal keratoconjunctivitis was 1%.²⁴ Analysis of severe vernal keratoconjunctivitis patients taking cyclosporine 2% drops showed that CD4⁺ and CD23⁺ cells in conjunctival impression cytology samples significantly decreased.¹⁰ Topical cyclosporine appears to be an effective alternative for severe vernal keratoconjunctivitis.

Atopic keratoconjunctivitis, unlike vernal keratoconjunctivitis, persists for many years, and patients become dependant on topical steroids with their attendant side effects. In a trial of cyclosporine 2% four times daily (in addition to their usual therapy), 9 of 12 of patients ceased steroid use, compared with 1 of 9 placebo patients.⁴⁹ Final steroid use was less for cyclosporine 2%, 2.6 versus 27.7 doses per week ($p = 0.01$), and steroid use decreased by 85.5 doses per week relative to placebo, to 13.9 doses per week

($p = 0.005$).⁴⁹ Clinical signs and symptom scores were reduced to a greater extent with cyclosporine.⁴⁹ Topical cyclosporine 2% appears to be a safe and effective steroid-sparing agent for atopic keratoconjunctivitis.

Childhood phlyctenular keratoconjunctivitis, also known as childhood ocular rosacea, is characterized by phlyctenules, small inflammatory nodules on the cornea and conjunctiva. Hypersensitivity to staphylococcal antigens such as peptidoglycan and protein A is responsible. Topical cyclosporine 2% instilled 4 times daily ($n = 13$ eyes) controlled corneal inflammation in steroid-dependent disease within 14 days.³¹ Inflammation did not recur during a mean follow-up of 12 ± 8 months, and treatment was stopped in 10 eyes with no recurrences in 10 ± 3 months.³¹ Topical cyclosporine 2% appears safe and effective for long-term therapy of phlyctenular keratoconjunctivitis.

Five patients diagnosed with Theodore superior limbic keratoconjunctivitis were treated with cyclosporine 0.5% four times daily. All exhibited improvement in irritation and foreign-body sensation, injection, and filamentary keratitis over 6 months to 4 years.⁸³ Topical cyclosporine may be useful as primary or adjunctive therapy for superior limbic keratoconjunctivitis or to prevent recurrence.

Herpes simplex virus induces an immunological response that contributes to corneal scarring and neovascularization. In one study, 10 patients received topical cyclosporine 2% four times daily along with acyclovir 3% ointment. Stromal infiltration resolved in all the patients after 2 months, and visual acuity increased by 2 lines or more in 8 of 10 cases.⁴³ In another study, topical cyclosporine 2% was given three times daily with acyclovir 3%, and keratitis resolved in 12 of 18 patients.⁴⁷ Persistent or progressive inflammation was apparent in 6 of 18 patients, who required steroid treatment also, and 4 patients experienced a recurrence of stromal keratitis when the cyclosporine was tapered off.⁴⁷ These results suggest that noninfectious, immunologic herpes simplex virus stromal keratitis can be treated successfully with topical cyclosporine.

Thygeson superficial punctate keratitis is a chronic nummular keratitis of the cornea that may last for a decade and is traditionally treated with topical corticosteroids. Cyclosporine 2% was administered to 42 adult eyes and 10 pediatric eyes with this condition. Complete suppression of epithelial and subepithelial opacities was achieved in 71.5% of adults and 40% of children, and healing occurred in 31% of adults and 20% of children.⁹¹ Cyclosporine may be useful to control Thygeson superficial punctate keratitis and avoid corticosteroid side effects.

Topical cyclosporine has been administered to treat corneal allograft rejection after penetrating keratoplasty. In one trial of 16 eyes, cyclosporine 0.5% cured 9 eyes, improved 6 eyes, and was ineffective for 1 eye.¹²⁷ Rejection occurred after 12 to 24 months in 3 of 9 eyes, but could be resolved by resumption of cyclosporine.¹²⁷ In another study of cyclosporine 2% as an adjunct to steroids, 69.7% (60/86 eyes) were rejection-free versus 45.4% (44/97 eyes) of controls ($p = 0.030$).⁵⁴ Cyclosporine 0.5% was substituted for steroids in 52 eyes with postkeratoplasty glaucoma and steroid-induced hypertension. At first follow-up, 92.3% showed reduced intraocular pressure (IOP), with a mean reduction of 7.9 mm Hg, and at last follow-up, the IOP reduction was 8.2 mm Hg.⁸¹ Graft clarity was maintained in 88% of eyes, and of 6 allograft rejections, 5 were reversed with steroids.⁸¹

A recent preclinical study investigated the pharmacokinetics of an episcleral cyclosporine implant as an alternative treatment option to topical cyclosporine in preventing corneal allograft rejection. The implant led to corneal cyclosporine concentrations of $0.09 \pm 0.05 \mu\text{g}/\text{mg}$ within 3 hours and maintained corneal cyclosporine concentrations in the inhibitory range for T-cell activation and vascular endothelial cell proliferation for at least 1 year.⁶⁴ Clinical examinations showed no signs of ocular toxicity over the 1-year period.⁶⁴ Further studies are needed to determine the clinical efficacy of these devices in penetrating keratoplasty models.

Topical cyclosporine 2% was used to treat Sjögren syndrome in a randomized, double-masked, placebo-controlled trial. After 2 months, there was a significant increase in tear breakup time and decrease in rose bengal staining in the cyclosporine group versus the placebo group ($p < 0.01$).⁴² Schirmer scores were not significantly affected.⁴²

Mooren ulcer is a chronic ulceration of the cornea that may have an autoimmune etiology. Topical cyclosporine 1% plus topical resection and lamellar keratoplasty provided a cure rate on the first procedure of 73.7% (84/114) versus 69.3% (205/296) for topical resection and lamellar keratoplasty alone.²⁶

V. Pharmacokinetics of Topically Administered Ophthalmic Cyclosporine 0.05%

Successful treatment of ocular surface inflammatory conditions using topical cyclosporine formulations compounded by pharmacists suggested that a commercially available ophthalmic formulation of cyclosporine with increased bioavailability might be

therapeutically useful. The hydrophobic nature of the cyclosporine molecule, however, presented a challenge to developing an effective ophthalmic formulation. The poor water solubility of cyclosporine means that aqueous solutions at clinically useful concentrations are likely to be unstable. Attempts to overcome this have led to ophthalmic cyclosporine prepared in castor, corn, olive, and peanut oils. Burning, redness, itching, and epithelial keratitis limit the use of such oil vehicles.¹¹⁶

To improve delivery of cyclosporine to ocular tissues, an emulsion formulation in castor oil that also includes glycerin, polysorbate 80, and sodium hydroxide (to adjust the pH) was developed (Restasis [package insert]. Irvine, CA: Allergan, Inc.; 2004).¹¹⁶ Upon instillation, cyclosporine partitions from the oil droplets in the emulsion into ocular surface tissues. Animal studies showed that topical administration of the emulsion formulation achieved cyclosporine concentrations sufficient for immunomodulation in the cornea and conjunctiva, but resulted in very low concentrations ($< 1 \text{ ng}/\text{ml}$) in the aqueous humor, vitreous humor, and plasma.²

Topical administration of cyclosporine 0.05% or 0.1% ophthalmic emulsions in dry eye patients who participated in the phase 3 clinical trials resulted in plasma levels of cyclosporine that were undetectable in those receiving 0.05% cyclosporine and were very low in those receiving 0.1%.^{97,104} Using highly sensitive high-performance liquid chromatography (HPLC) tandem-mass spectroscopy with lower limit of quantitation of 0.1 ng/ml, cyclosporine was detected in only 6 of 310 blood samples, all from patients administered cyclosporine 0.1%.^{97,105} The concentrations detected were several orders of magnitude less than trough plasma concentrations (75–400 ng/ml) of cyclosporine during systemic immunosuppressive therapy for psoriasis, rheumatoid arthritis, and organ transplant patients.¹¹⁶ Because of the extremely low blood concentrations of cyclosporine after topical administration of cyclosporine 0.05% or 0.1%, systemic side effects were not anticipated, and nonocular treatment-related adverse events were not observed in clinical trials of the cyclosporine ophthalmic emulsions.^{12,97,104}

VI. Pharmacology of Ophthalmic Cyclosporine 0.05%

Many of the pharmacologic effects of topical cyclosporine on the ocular surface are consistent with what is known about its molecular mechanism of action. Treatment with topical cyclosporine has been shown to reduce cell surface markers of activated T lymphocytes and apoptotic cells in

Explore Litigation Insights

Docket Alarm provides insights to develop a more informed litigation strategy and the peace of mind of knowing you're on top of things.

Real-Time Litigation Alerts



Keep your litigation team up-to-date with **real-time alerts** and advanced team management tools built for the enterprise, all while greatly reducing PACER spend.

Our comprehensive service means we can handle Federal, State, and Administrative courts across the country.

Advanced Docket Research



With over 230 million records, Docket Alarm's cloud-native docket research platform finds what other services can't. Coverage includes Federal, State, plus PTAB, TTAB, ITC and NLRB decisions, all in one place.

Identify arguments that have been successful in the past with full text, pinpoint searching. Link to case law cited within any court document via Fastcase.

Analytics At Your Fingertips



Learn what happened the last time a particular judge, opposing counsel or company faced cases similar to yours.

Advanced out-of-the-box PTAB and TTAB analytics are always at your fingertips.

API

Docket Alarm offers a powerful API (application programming interface) to developers that want to integrate case filings into their apps.

LAW FIRMS

Build custom dashboards for your attorneys and clients with live data direct from the court.

Automate many repetitive legal tasks like conflict checks, document management, and marketing.

FINANCIAL INSTITUTIONS

Litigation and bankruptcy checks for companies and debtors.

E-DISCOVERY AND LEGAL VENDORS

Sync your system to PACER to automate legal marketing.