

negative diagnosis in which the correct diagnosis was made at 20 weeks' gestation.

Nuchal anomalies appeared in 14 of 22 fetuses (59%) with atrioventricular septal defect. This finding is in accordance with the high incidence of nuchal anomalies in fetuses with cardiac anomalies.<sup>1</sup> Allan<sup>4</sup> reported 49 fetuses with atrioventricular septal defect. Heterotaxia syndromes or isomerism of the atrial appendages was noted in 22 of these cases. In our series, there was only 1 fetus with heterotaxia syndrome. We have no explanation for the difference between the 2 studies.

The ability to diagnose atrioventricular septal defect relies on the skill of the observer. Gembruch et al<sup>9</sup> and Achiron et al<sup>10</sup> detected this anomaly in early pregnancy. Allan<sup>4</sup> recently estimated that only 50% of cases are detected in utero. In our series, the diagnosis was confirmed in 11 of 13 fetuses in which a postmortem examination was performed. The higher detection rate in our series may be attributed to the fact that all examinations were performed by the same experienced observer.

We are aware of 2 possible drawbacks in our study. (1) Because not all of our patients delivered in our hospital, we only had our own data on pregnancy outcome in 72% of patients. In the other cases we relied on information provided by patients or their obstetricians. We cannot exclude the possibility that we were not informed about a case of a false-negative diagnosis of atrioventricular septal defect. (2) Because of the destructive nature of the termination of pregnancy, a reliable postmortem examination was not possible in all cases.

**In summary, the data show that accurate sonographic diagnosis of fetal complete atrioventricular septal defect is possible in the first and early second trimesters of pregnancy. Many of these fetuses have associated abnormal sonographic findings; the most frequent was nuchal translucency. About 2/3 of the fetuses in whom chromosomal analysis was available had an abnormal karyotype.**

1. Berdahl LD, Wenstrom KD, Hanson JW. Web neck anomaly and its association with congenital heart disease. *Am J Med Genet* 1995;56:304–307.
2. Marino B. Pattern of congenital heart disease and associated cardiac anomalies in children with Down syndrome. In: Marino B, Pueschel SM, eds. *Heart Disease in Persons with Down Syndrome*. Baltimore: Brooks, 1996:133–140.
3. Ferencz C, Loffredo CA, Correa-Villasenor A, Wilson PD, eds. *Genetic and Environmental Risk Factors of Major Cardiovascular Malformations: The Baltimore-Washington Infant Study 1981–1989*. Armonk, NY: Futura, 1997:103–122.
4. Allan LD. Atrioventricular septal defect in the fetus. *Am J Obstet Gynecol* 1999;181:1250–1253.
5. Digilio MC, Marino B, Giannico S, Giannotti A, Dallapiccola B. Atrioventricular canal defect and hypoplastic left heart syndrome as discordant congenital heart defects in twins. *Teratology* 1999;60:206–208.
6. Allan L. Atrioventricular septal defect. In: Allan L, Homberger LK, Sharland G, eds. *Textbook of Fetal Cardiology*. London: Greenwich Media, 2000:163–193.
7. Pierpont MAM, Markwald RR, Lin AE. Genetic aspects of atrioventricular septal defect. *Am J Med Genet* 2000;97:289–296.
8. Bronshtein M, Coffler MS, Zimmer EZ. The cardiovascular system. In: Bronshtein M, Zimmer EZ, eds. *Transvaginal Sonography of the Normal and Abnormal Fetus*. New York: Parthenon, 2001:87–130.
9. Gembruch U, Hansmann M, Redel DA, Bald R, Knopfle G. Fetal complete heart block: antenatal diagnosis, significance and management. *Eur J Obstet Gynecol Reprod Biol* 1989;31:9–22.
10. Achiron R, Rotstein Z, Lipitz S, Mashiach S. First trimester diagnosis of fetal congenital heart disease by transvaginal ultrasonography. *Obstet Gynecol* 1994; 84:69–72.

## Diagnostic and Therapeutic Uses of Inhaled Nitric Oxide in Neonatal Ebstein's Anomaly

Andrew M. Atz, MD, Ricardo A. Munoz, MD, Ian Adatia, MB, ChB, and David L. Wessel, MD

Inhaled nitric oxide (NO) is a selective pulmonary vasodilator with few adverse effects using current delivery and monitoring techniques. Failure of the postoperative newborn with pulmonary hypertension to respond to NO has successfully discriminated anatomic obstruction to pulmonary blood flow from reversible pulmonary vasoconstriction.<sup>1</sup> Severe neonatal Ebstein's anomaly is a rare lesion with high mortality.<sup>2,3</sup> However, occasionally survivors demonstrate spontaneous clinical improvement as pulmonary vascular resistance declines.<sup>4</sup> The aim of this study was to determine whether a trial of NO could differentiate patients with functional pulmonary atresia<sup>5</sup> from structural pulmonary atresia, and therefore quickly identify those who would require surgery. Further-

more, we speculated that NO might therapeutically improve oxygenation in patients with a patent pulmonary valve by decreasing afterload on the right ventricle, causing improved cardiac output and reduced intracardiac shunt.

...

We identified all neonates presenting to a cardiac intensive care unit with echocardiographically diagnosed Ebstein's anomaly (Table 1). Patients with associated complex congenital heart disease were excluded. Fourteen (7 female and 7 male) patients had maximal arterial oxygen tension (PaO<sub>2</sub>) <65 mm Hg and all received a trial of inhaled NO. Prostaglandin E infusions were discontinued before NO testing in an effort to further encourage antegrade flow across the pulmonary valve.

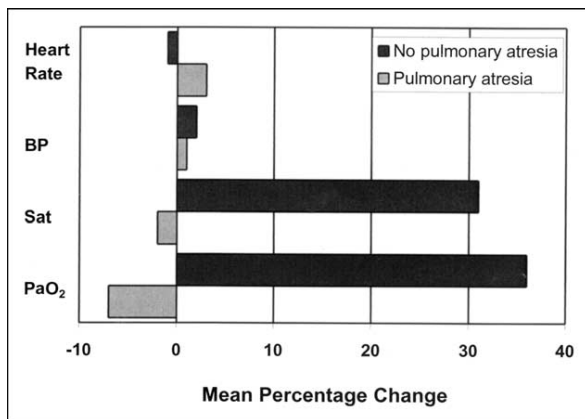
Hemodynamic variables were measured at (1) baseline—a stage in which patients were normothermic and hemodynamically stable (steady heart rate and blood pressure and no change in inotropic or ventilatory requirement), and (2) at the end of a 15-minute trial of inhaled NO at 80 ppm. Ventilation pa-

From the Children's Hospital, Harvard Medical School, Boston, Massachusetts. Dr. Atz's address is: The Children's Heart Center of South Carolina, Medical University of South Carolina, 165 Ashley Avenue, PO Box 250915, Charleston, South Carolina 29425. E-mail: atzam@musc.edu. Manuscript received September 18, 2002; revised manuscript received and accepted December 11, 2002.

**TABLE 1** Patient Characteristics

Patient Number	Age (d)	Weight (kg)	Celermajer Ratio (index)	Operation	Pulmonic Atresia	Arterial Saturation (%)		PaO <sub>2</sub> (mm Hg)		Outcome
						Base	NO	Base	NO	
1	4	1.7	0.79 (2)	B-T shunt	+	83	84	49	51	Died (17 d)
2	1	2.3	2.50 (4)	0	+	53	51	24	22	Died (1 d)
3	2	2.5	0.95 (2)	B-T shunt, TV closed, ASD created	+	81	72	41	34	Died (4 mo)
4	1	2.7	2.57 (4)	B-T shunt, PV opened, TV closed, ASD created	+	70	77	40	39	Died (5 d)
5	1	3.1	1.58 (4)	B-T shunt, PV opened, ASD created	+	86	78	34	30	Died (2 d)
6	1	3.0	1.68 (4)	0	Functional	58	70	31	36	Alive
7	1	3.1	1.20 (3)	0	Functional	31	77	20	46	Died (2 d)
8	2	3.2	0.61 (2)	0	Functional	47	66	26	34	Alive
9	1	4.5	0.63 (2)	0	Functional	84	90	33	36	Alive
10	1	2.4	0.67 (2)	TV closed	0	51	81	30	36	Died (6 d)
11	1	2.8	0.41 (1)	RVOT patch, VSD closed, ASD closed	0	82	79	49	45	Died (4 mo)
12	1	3.6	0.50 (2)	0	0	91	95	61	130	Alive
13	2	3.8	0.95 (2)	0	0	90	95	42	46	Alive
14	4	4.0	0.53 (2)	0	0	83	84	43	45	Alive

ASD = atrial septal defect; Base = before nitric oxide; B-T = Blalock-Taussig; PaO<sub>2</sub> = systemic arterial oxygen tension; PV = pulmonic valve; RVOT = right ventricular outflow tract; TV = tricuspid valve; VSD = ventricular septal defect.



**FIGURE 1.** Patients with a patent pulmonary valve (no pulmonary atresia) had improvement in systemic saturation (Sat) and PaO<sub>2</sub>—a mean percentage increase of 36% and 31%, respectively, after 15 minutes of NO. Those with structural pulmonary atresia had no improvement in oxygenation with NO. No change in heart rate or systemic blood pressure (BP) was seen in either group.

rameters were kept constant throughout the 15-minute trial. Nitrogen dioxide was continuously monitored and methemoglobin levels were measured by co-oximetry (CIBA-Corning model 2500, Medfield, Massachusetts). Heart rate, blood pressure, and blood gases were measured in all patients. Patients underwent echocardiography at baseline and at the end of the trial of NO to assess the presence or absence of forward flow across the pulmonary valve. Initial diagnostic echocardiograms were reviewed by a single investigator blinded to the results to determine the index of severity of Ebstein's anomaly as described by Celermajer et al<sup>2</sup> (ratio of the combined right atrial and atrialized right ventricular area to the area of the functional right ventricle and left heart.)

All patients acted as their own controls. A paired nonparametric test (Wilcoxon signed-rank test) was used to compare the difference between baseline hemodynamic variables and after 15 minutes of inhaled NO. A *p* value <0.05 was considered statistically

significant. Written informed consent was obtained from parents of all patients under approved protocols.

After all data were collected, the patients were divided into 2 groups: those with structural pulmonary atresia and those with a patent pulmonary valve as defined by echocardiographic evidence of antero- grade flow after inhaling NO for 15 minutes. The first group included 5 patients in whom antero- grade flow was never demonstrated by echocardiography either before or during treatment with NO; in all, atresia was confirmed at either catheterization or at operation. The second group included 5 patients in whom antero- grade flow was detected by echocardiography at baseline and during NO inhalation, and 4 patients with functional pulmonary atresia who had evidence of antero- grade flow only after inhaling NO.

There was no statistical difference seen in either group after 15 minutes of breathing inhaled NO with respect to heart rate, arterial blood pressure, arterial pH, or arterial carbon dioxide pressure. There was a significant increase in PaO<sub>2</sub> from baseline in the group with a patent pulmonary valve (39 to 53 mm Hg; *p* <0.05) and in arterial oxygen saturation (71% to 84%; *p* <0.05) after inhalation of NO at 80 ppm for 15 minutes. In the group with structural pulmonary atresia, there was no comparative change in arterial PaO<sub>2</sub> (41 to 39 mm Hg) or in arterial saturation (80% to 78%) (Figure 1).

In 6 patients with improvement in oxygenation by ≥10% during the initial trial of NO at 80 ppm, NO was reintroduced at 5 to 20 ppm. Patient 11 was the only patient with a patent pulmonary valve who did not have improvement in oxygenation, and he was found to have subpulmonic stenosis, which resulted in fixed obstruction to pulmonary blood flow. Nitrogen dioxide measured continuously in all patients remained at <2 ppm and methemoglobin concentration remained at ≤1.2%.

Six infants underwent surgery: four with structural pulmonary atresia, the patient with fixed subpulmonic stenosis, and patient 10, who underwent surgery for

rapidly progressive heart failure within 6 hours of life despite improved oxygenation with NO. The types of surgical procedure varied and are listed in Table 1. Only 2 of 6 postoperative patients survived to hospital discharge and neither survived beyond 4 months.

Eight patients did not undergo surgical procedures. Two patients were believed to be unsuitable candidates for surgery. One had pulmonary atresia and diminutive (1.5 mm) branch pulmonary arteries and died of severe hypoxia at 2 days despite reinitiating prostaglandin E. One with functional pulmonary atresia had severe neonatal hydrops and despite a positive response to NO had progressive acidosis and rapid onset multiorgan system failure. The other 6 patients remain alive during an average of 4.4 years (range 2.9 to 8.6) of follow-up.

In an effort to maximally encourage antegrade flow across the pulmonary valve, all patients in this study had prostaglandin discontinued before initiation of NO. The ductuses were patent in these patients at the time of testing but qualitatively were no larger than moderate in size. It is unclear whether our results would have been similar if performed during prostaglandin infusion. There has been a report of a neonate with Ebstein's anomaly with documented antegrade flow across the pulmonary valve in whom maintenance of a ductus arteriosus with prostaglandin resulted in worsened hypoxemia, acidosis, and systemic hypotension due to a steal phenomenon. Prolonged NO and closure of the ductus was speculated to help long-term right ventricular compliance and function.<sup>6</sup> Treatment with inhaled NO during prostaglandin infusion to maintain a widely patent ductus may theoretically have a deleterious effect on Ebstein's patients with excessive pulmonary blood flow by increasing the pulmonary-to-systemic flow ratio and worsening hemodynamics. We did not see this in our study patients, who were profoundly cyanotic and had prostaglandin discontinued. The present study confirms the

safe and beneficial therapeutic aspect of NO in a series of cyanotic patients with Ebstein's anomaly and illustrates the previously undescribed role of NO as a diagnostic tool for this disease. Use of this management strategy may have valuable utility in other scenarios where functional pulmonary atresia may be encountered, such as congenital tricuspid regurgitation<sup>7</sup> and Uhl's anomaly.<sup>8</sup>

**In conclusion, inhaled NO rapidly and effectively discriminated functional from structural pulmonary atresia shortly after birth in severely affected neonates with Ebstein's anomaly. Inhaled NO after discontinuation of prostaglandin may play an important diagnostic and therapeutic role in neonates with Ebstein's anomaly and may modify currently accepted prognostic indicators.**

1. Adatia I, Atz AM, Jonas RA, Wessel DL. Diagnostic use of inhaled nitric oxide after neonatal cardiac operations. *J Thorac Cardiovasc Surg* 1996;112:1403-1405.
2. Celermajer DS, Cullem S, Sullivan ID, Spiegelhalter DJ, Wyse RK, Deanfield JE. Outcome in neonates with Ebstein's anomaly. *J Am Coll Cardiol* 1992;19:1041-1046.
3. Yetman AT, Freedom RM, McCrindle BW. Outcome in cyanotic neonates with Ebstein's anomaly. *Am J Cardiol* 1998;81:749-754.
4. Bush A, Busst CM, Haworth SG, Hislop AA, Knight WB, Corrin B, Shinebourne EA. Correlations of lung morphology, pulmonary vascular resistance, and outcome in children with congenital heart disease. *Br Heart J* 1988;59:480-485.
5. Freedom RM, Culham JA, Moes CA, Olley PM, Rowe RD. Differentiation of functional and structural pulmonary atresia: role of angiography. *Am J Cardiol* 1978;41:914-920.
6. Bruckheimer E, Bulbul Z, Pinter E, Gailani M, Kleinman, CS, Fahey JT. Inhaled nitric oxide therapy in a critically ill neonate with Ebstein's anomaly. *Pediatr Cardiol* 1998;19:477-479.
7. Andelfinger G, Shirali GS, Rauniker RA, Atz AM. Functional pulmonary atresia in neonatal Marfan's syndrome: successful treatment with inhaled nitric oxide. *Pediatr Cardiol* 2001;22:525-526.
8. Tumbarello R, Adatia I, Yetman A, Boutin C, Izukawa T, Freedom RM. From functional pulmonary atresia to right ventricular restriction. Long term follow up of Uhl's anomaly. *Int J Cardiol* 1998;67:161-164.

## Early and Late Results of Thrombolytic Therapy Using Tissue-Type Plasminogen Activator to Restore Arterial Pulse After Cardiac Catheterization in Infants and Small Children

Duraisamy Balaguru, MBBS, MRCP, Muhammad Dilawar, MD, Pamela Ruff, BS, RDCS, and Wolfgang A.K. Radtke, MD

**P**ulse loss after cardiac catheterization has been reported to occur in 8% to 39% of infants weighing <14 kg<sup>1-3</sup> despite prophylactic use of heparin,<sup>4</sup> notably after retrograde balloon angioplasty or valvuloplasty.<sup>5</sup> Impaired limb growth is a possible late complication<sup>6,7</sup> and access is lost for future catheterization.

From the Children's Heart Center, Medical University of South Carolina, Charleston, South Carolina. Dr. Radtke's address is: Pediatric Cardiology, Medical University of South Carolina, 165 Ashley Avenue, PO Box 250915, Charleston, South Carolina 29425. E-mail: radtkew@muscc.edu. Manuscript received April 30, 2002; revised manuscript received and accepted November 27, 2002.

Thrombolytic therapy using streptokinase<sup>5,8,9</sup> and urokinase,<sup>10</sup> and, recently, tissue-type plasminogen activator (t-PA)<sup>11-14</sup> has been reported but without assessing long-term patency of the target vessel. The reports on t-PA<sup>11-14</sup> were based on a variety of doses given >24 hours after catheterization and patient numbers were small. We report our experience using a uniform t-PA dosing protocol that began 4 to 6 hours after cardiac catheterization with regard to safety, efficacy, and long-term patency of the target vessel.

•••

Medical records of patients who received throm-