

# Persistent Pulmonary Hypertension of the Newborn With Transposition of the Great Arteries

Marcus T. R. Roofthoof, MD, Klasina A. Bergman, MD, Tjalling W. Waterbolk, MD, Tjark Ebels, MD, PhD, Beatrijs Bartelds, MD, PhD, and Rolf M. F. Berger, MD, PhD

Departments of Paediatric Cardiology and Neonatology, Beatrix Children's Hospital, and Department of Thoracic Surgery, University Medical Centre Groningen, University of Groningen, Groningen, The Netherlands

**Background.** Persistent pulmonary hypertension of the newborn (PPHN) in patients with transposition of the great arteries (TGA) is reported to be a high-risk and often therapy-resistant condition, associated with a high mortality. However, data on its incidence and prognosis are scarce and originate mostly from the era before introduction of inhaled nitric oxide (iNO) therapy for PPHN.

**Methods.** This is a retrospective study of consecutive newborns with TGA, admitted to a tertiary cardiac and neonatal intensive unit over a 10-year period. In this period, iNO therapy was available.

**Results.** Fourteen out of 112 patients with TGA (12.5%) presented with associated PPHN. The PPHN occurred more frequently in patients with TGA and intact ventricular septum (IVS) compared with those with TGA and ventricular septal defect (13 out of 83 patients versus one out of 29 patients, respectively;  $p = 0.06$ , Fisher exact test).

Of those newborns, six presented with severe PPHN, whereas eight presented with mild-to-moderate PPHN. Despite currently available treatment modalities, including iNO, four out of 14 patients died before corrective surgical procedures were considered to be an option (TGA/PPHN preoperative mortality 28.6%). These included three out of six patients (50%) with severe PPHN and one out of eight (12.5%) with mild-to-moderate PPHN.

**Conclusions.** The combination of TGA with PPHN is a serious and often fatal condition. It may jeopardize the usually favorable outcome of newborns with TGA. Despite the introduction of iNO therapy, the combination of TGA and PPHN remains a condition with unacceptable high mortality (in our series). Additional treatment strategies need to be investigated.

(Ann Thorac Surg 2007;83:1446–50)

© 2007 by The Society of Thoracic Surgeons

Transposition of the great arteries (TGA) is the most common cyanotic congenital heart defect presenting in the neonate. Transposition of the great arteries is present in 5% to 7% of patients with congenital heart disease. The TGA has a 60% to 70% male predominance [1, 2]. Hallmark is a discordant ventriculoarterial connection. In TGA the systemic and pulmonary circulation are separated, resulting in hypoxemic systemic and hyperoxemic pulmonary flow. Mixing opportunities, like persistent ductus arteriosus (PDA), atrial septal defect (ASD), or ventricular septal defect (VSD), are obligatory for early survival. Untreated, TGA is a fatal congenital heart defect due to progressive hypoxia and acidosis.

The combination of persistent pulmonary hypertension of the newborn (PPHN) and TGA has serious implications on treatment and prognosis, with often deleterious outcome [3–6]. Limited data concerning the incidence and prognosis of this condition are available. The estimated incidences are based mainly on case reports or small series in the period before introduction of inhaled nitric oxide (iNO), and range from 1% to 3% in

patients with TGA and intact ventricular septum (IVS) [3–7].

Persistent pulmonary hypertension of the newborn (PPHN) is defined as failure of normal pulmonary vascular adaptation at or soon after birth, resulting in increased pulmonary vascular resistance, which exceeds systemic vascular resistance such that pulmonary blood flow is diminished and unoxygenated blood is shunted to the systemic circulation. This condition, usually diagnosed on clinical features, is confirmed by echocardiography [8]. We present the results of a single-center experience concerning the incidence and treatment of PPHN in TGA, with or without ventricular septal defects (VSD/IVS).

## Patients and Methods

In a retrospective study, a cohort of consecutive patients with TGA was studied for the presence of associated PPHN. All patients were admitted to a tertiary cardiac and neonatal intensive unit (Beatrix Children's Hospital, Groningen, The Netherlands) over a 10-year period (January 1995 to January 2005). Our Institutional Medical Ethics committee waived the need of patient consent in this retrospective study, because individual patients were not identified.

Accepted for publication Nov 1, 2006.

Address correspondence to Dr Roofthoof, Department of Paediatric Cardiology, Beatrix Children's Hospital, University Medical Centre Groningen, PO Box 30.001, 9700 RB, Groningen, The Netherlands; e-mail: m.t.r.roofthoof@bkk.umcg.nl.

© 2007 by The Society of Thoracic Surgeons  
Published by Elsevier Inc

0003-4975/07/\$32.00  
doi:10.1016/j.athoracsur.2006.11.001

Mallinckrodt Hosp. Prods. IP Ltd.  
Exhibit 2027  
Praxair Distrib., Inc. et al., v. Mallinckrodt Hosp. Prods. IP Ltd.  
Case IPR2016-00779

DOCKET  
ALARM

Find authenticated court documents without watermarks at [docketalarm.com](http://docketalarm.com).

At presentation, after optimal ventilation with 100% inspired oxygen, two groups of patients with pulmonary hypertension were defined. Group 1 (severe PPHN), presenting with profound cyanosis and associated with echocardiographic continuous right-to-left shunting (ie, pulmonary to systemic circulation) through a PDA on color flow Doppler and pulsed wave Doppler, or a predominant right-to-left shunt through the PDA associated with a preductal to postductal difference in transcutaneous oxygen saturation ( $\delta$ -SO<sub>2</sub>) 15% or greater, as measured between the right arm and a leg. Group 2, mild-to-moderate PPHN, presenting with echocardiographic bidirectional shunting through the PDA associated with  $\delta$ -SO<sub>2</sub> between 5% and 15%.

During the study period, a standard approach was used toward patients with PPHN in combination with a TGA. Intravenous prostaglandin E1 (PGE1) was started as soon as possible. In patients with insufficient mixing at the level of the open foramen ovale a balloon atrioseptostomy was performed. Therapies for PPHN in this group of patients were aimed at lowering pulmonary vascular resistance and improving mixing at the level of the atria and PDA. The ventilator strategy used is meant to reduce pulmonary vascular resistance by improving oxygenation, while aiming for a pH of 7.4 and an arterial CO<sub>2</sub> pressure (pCO<sub>2</sub>) between 4.0 and 5.5 kPa. Ventilator settings were adjusted according to the patient's pulmonary condition, tidal volume, and arterial blood gas determination. Patients received sedation with morphine and, if necessary, neuromuscular blockade with vecuronium. Inotropic agents (isoprenaline, dopamine, dobutamine, and noradrenaline) and intravenous volume replacement were used aggressively to maintain an adequate arterial blood pressure. During iNO therapy, nitric oxide was introduced into the inspiratory limb of the ventilator (5-40 ppm). In case of failure, intravenous vasodilators (tolazoline, epoprostenol, enoximone) were started in the absence of contraindications (hypotension, renal failure, hemorrhage). During the study period, newborns with major congenital heart defects were not eligible for preoperative cardiac extracorporeal membrane oxygenation (ECMO) in the Netherlands.

### Statistical Methods

To compare patients (TGA/PPHN) with VSD versus IVS, a Fisher exact test was used. The same statistic test was used to compare patients with or without PPHN and delayed sternal closure, as well as to compare the mortality in patients (TGA/PPHN) treated with or without iNO therapy. By a  $\chi^2$  test, differences in the incidence of a balloon atrioseptostomy in patients with TGA (PPHN vs non-PPHN) were tested. Differences in length of intensive care unit (ICU) stay or days on ventilatory support after the arterial switch operation (ASO) (PPHN vs non-PPHN) were tested by the Mann-Whitney U test. In all tests, a *p* value of 0.05 or less was considered

## Results

### Incidence

Between January 1995 and January 2005, 112 neonates were diagnosed with TGA. Eighty-three patients presented with TGA/IVS, whereas 29 had TGA with VSD. Fourteen patients (12.5%) fulfilled our criteria for PPHN. Of these, 13 had TGA with IVS, whereas one had a small, muscular VSD. Six patients were defined as having severe PPHN and eight had mild-to-moderate PPHN. In the group of severe PPHN the right arm (preductal) oxygen saturation ranged from 30% to 50% (mean  $\delta$ -SO<sub>2</sub> = 21%). In the patients with mild-to-moderate PPHN preductal oxygen saturation was observed between 70% and 85% (mean  $\delta$ -SO<sub>2</sub> = 12%).

### Medical Treatment

All 14 newborns with TGA and PPHN were treated with intravenous prostaglandins E1 (PGE1). Each of these infants had PPHN despite optimal mechanical ventilation and 100% inspired O<sub>2</sub>. All patients were sedated and paralyzed. In 13 patients (93%) a balloon atrioseptostomy was performed, compared with 53 of the 98 TGA patients without PPHN (54%) (*p* ≤ 0.01,  $\chi^2$  test). Additional iNO therapy (5 to 40 ppm) was started in 11 patients with TGA and PPHN (six with severe PPHN and five with mild-to-moderate PPHN). The remaining three patients (all with mild-to-moderate PPHN) responded well to maximal conservative therapy and did not need iNO. Additional therapy in the PPHN patients consisted of inotropics (isoprenaline [n = 6], dopamine [n = 9], dobutamine [n = 4] and norepinephrine [n = 3]) and intravenous vasodilators (epoprostenol [n = 5], tolazoline [n = 2], and enoximone [n = 1]).

### Outcome

Overall mortality (preoperative, operative, in-hospital [30 days] and late mortality) in this cohort of TGA patients was 15 out of 112 (13.4%). Seven of these patients (6.3%) were considered not eligible for corrective surgery because of various comorbidity; therapy-resistant PPHN (n = 4), necrotizing enterocolitis (n = 1), prematurity

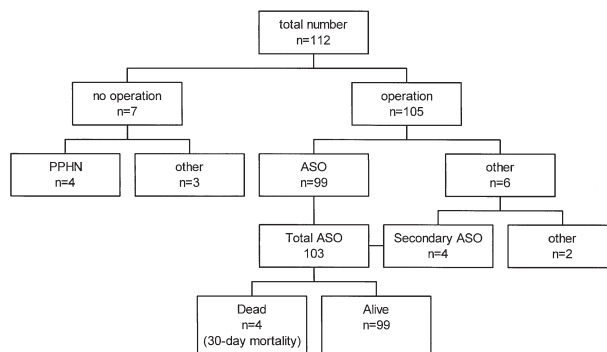


Fig 1. Surgical characteristics of transposition of the great arteries (intact ventricular septum/ventricular septal defect). (ASO = arterial switch operation; PPHN = persistent pulmonary hypertension)

Table 1. Postoperative Characteristics of Persistent Pulmonary Hypertension of the Newborn (PPHN)/Transposition of the Great Arteries Patients

Patient	PPHN	Coronary Anatomy	Postoperative Complications	Mechanical Ventilation	ICU Stay
1. Female	Mild-moderate	I LAD-CX II RCA	Uncomplicated	2 days	3 days
2. Male	Mild-moderate	I LAD-CX II RCA	Uncomplicated	2 days	3 days
3. Male	Mild-moderate	I LAD-CX II RCA	Pulmonary edema/atelectasis	5 days	6 days
4. Male	Mild-moderate	I LAD-CX II RCA	Atelectasis	5 days	6 days
5. Male	Mild-moderate	I LAD-CX II RCA	Chylothorax	9 days	10 days
6. Male	Mild-moderate	I LAD II RCA-CX	Pulmonary hypertension	10 days	11 days
7. Female	Mild-moderate	I LAD-CX II RCA	Cardiac infarction eci	14 days	15 days
8. Female	Severe	I LAD-CX II RCA	Uncomplicated	2 days	3 days
9. Female	Severe	I LAD-CX II RCA	Junctional ectopic tachycardia	10 days	11 days
10. Male	Severe	I LAD-CX II RCA	Open chest/obstruction left coronary ostium	23 days	33 days

CX = circumflex coronary artery; ICU = intensive care unit; LAD = left anterior descending artery; RCA = right coronary artery.

(gestational age 28 1/7 weeks)(n = 1) and associated debilitating coloboma of the eye, heart anomaly, choanal atresia, retardation, and genital and ear anomalies (CHARGE) syndrome (n = 1).

In 99 of the remaining 105 patients a primary ASO was performed. Six patients underwent alternative surgery; Senning procedure [n = 1], banding of the pulmonary artery ± atrioseptectomy ± modified Blalock-Taussig shunt (n = 5). In four of the latter five patients an ASO was performed at a later stage (see Fig 1). In the surgically treated patients we observed a 30-day mortality of four patients out of 105 (3.9%). Two of these children died operatively from heart failure due to impaired coronary artery perfusion. In the first child the circumflex coronary artery (CX) originated from the right coronary artery (RCA):(I LAD [left anterior descending artery], II RCA-CX), the second child showed a I LAD-RCA, II CX pattern. The third patient developed therapy-resistant pulmonary hypertensive crises postoperatively and died fourteen days after operation (I LAD, II RCA-CX). The fourth patient survived the ASO, despite associated complex coronary anatomy (I ramus descendens anterior, II RCA-CX); however, the patient suffered from cerebral edema and died due to cerebral herniation. In the remaining group of 99 patients who underwent a successful ASO we observed an unusual pattern of the coronary

anatomy in 26 patients ( $p = 0.006$  compared with the four out of four patients who died perioperatively) [9].

Four patients died during long-term postoperative follow-up (late mortality). One of these patients 16 months after uneventful ASO due to progressive idiopathic-unexplained pulmonary vascular disease not related to left ventricular dysfunction (usual coronary pattern I LAD-CX, II RCA). Three patients died unexpectedly at, respectively, 0.5, 1.5, and 3.75 years of age due to unknown cause, although two of these children had associated complex coronary anatomy and had shown temporary perioperative ischemia (I intramural LAD-CX, II RCA and I two right conal arteries, II LAD-CX-RCA) [9]. Of the 99 patients who underwent a primary ASO, ten had a history of PPHN (group A), whereas 89 had no PPHN (group B).

Considering the postoperative characteristics of ASO in both groups, we observed remarkable differences: patients with PPHN needed significantly longer ventilatory support (mean 8.2 days vs 3.9 days,  $p = 0.02$ ), and their ICU stay was significantly longer (mean 10.4 days vs 5.5 days,  $p = 0.03$ ) (Mann-Whitney *U* test). Delayed sternal closure was observed in one patient of group A and in two patients of group B ( $p = 0.03$ , Fisher exact test). In both groups one patient needed iNO therapy ( $p = 0.2$  Fisher exact test). The characteristics of the complicated postoperative course of group A are shown in Table 1. As mentioned, group B showed a 30-day mortality of four patients and a late mortality of four patients. In contrast to group B all patients of group A have survived thus far.

Four out of the 14 patients with TGA and PPHN died (29%) preoperatively, despite optimal conventional therapy including iNO therapy and adequate balloon atrioseptostomy. (see Fig 2). The PPHN that did not resolve despite that this therapy was considered a contraindication to ASO. In the group with severe PPHN the mortality was 50% (three out of six patients). All patients in this group received iNO therapy (10 to 40 ppm) for a median duration of 51 hours (range, 24 to 120 hours). The remaining three patients recovered successfully from PPHN and

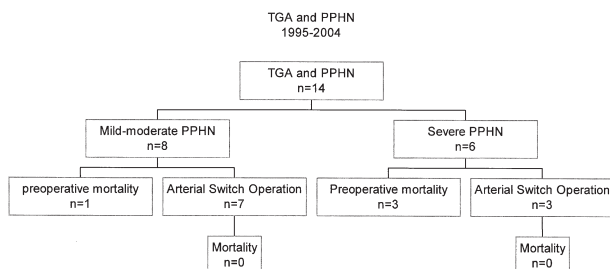


Fig 2. Characteristics of transposition of the great arteries and persistent pulmonary hypertension of the newborn (TGA and PPHN)

Table 2. Management of Neonates with Transposition of The Great Arteries/Intact Ventricular Septum and Pulmonary Hypertension

First Author	Year	No. of Patients	PGE1 (Patients)	BAS/BAH (Patients)	NO (Patients)	ECMO (Patients)	Repair (Patients)	Surgical Outcome	Follow-up
Hawker [4]	1974	4	None	4/1	None	None	2 atrial/2 none	3 dead/1 alive <sup>a</sup>	Lost to follow-up
Dick [3]	1981	2	1	2 <sup>b</sup> /1	None	None	1 atrial/1 none	2 dead	None
Chang [11]	1991	2	2	2/none	None	None	2 ASO	2 alive	2 alive (2 mo)
Kumar [5]	1993	3	3	3 <sup>b</sup> /2	None	None	2 atrial/2 ASO	3 dead	none
Luciani [6]	1996	2	2	2 <sup>b</sup> /none	2 <sup>c</sup>	2 <sup>c</sup>	2 ASO	2 alive	1 alive/1 dead
El-Segaier [12]	2005	3	3	3 <sup>b</sup> /none	3 <sup>c</sup>	None	3 ASO	3 alive	3 alive
Roofthoof [this article]	2006	13	13	13/none	11	None	9 ASO/4 none	9 alive	9 alive

<sup>a</sup> Patient who underwent only a Blalock-Hanlon atrial septectomy. <sup>b</sup> Multiple atrial septotomies. <sup>c</sup> Preoperative and postoperative support.

ASO = arterial switch operation; atrial = atrial switch operation; BAS = balloon atrial septostomy; BH = Blalock-Hanlon atrial septectomy; ECMO = extracorporeal membrane oxygenation; NO = nitric oxide; PGE1 = prostaglandin E1.

mild-to-moderate PPHN, the mortality was 12.5 % (one out of eight). Five of these patients received iNO therapy (10 to 40 ppm) for a median duration of 50 hours (range, 20 to 192 hours). One patient, who was severely asphyxiated, died within 24 hours after starting iNO. In a deviation from the standard approach at our institution, a successful rescue ASO was performed in one patient 24 hours after the start of iNO therapy, although the PPHN had not resolved at that time. The remaining six patients in this group underwent a successful ASO after complete recovery of the PPHN.

### Comment

Untreated, TGA is a fatal congenital heart defect due to progressive hypoxia and acidosis. Heart failure usually develops within the first weeks of life. Patients with reduced mixing opportunities (eg, TGA with IVS and restrictive open foramen ovale and [or] closure of the arterial duct), are the patients who become symptomatic with cyanosis early after birth. This group of patients usually responds well to PGE1 infusion and balloon atrioseptostomy. Patients with TGA and VSD show less cyanosis and usually present at a later time. In general, patients diagnosed as TGA and VSD/IVS have good prognosis after an ASO [10].

Sixteen patients with TGA/IVS and PPHN have been described previously (see Table 2) [3-6, 11]. In total, eight of those patients died in the neonatal period (50%). Inhaled nitric oxide therapy was not available in 11 of these patients. Five patients did receive iNO and survived. They underwent a successful ASO although additional perioperative ECMO was considered necessary in two patients. These limited data may suggest that the introduction of iNO therapy for PPHN may have improved the prognosis of newborns with TGA associated with PPHN (Table 2).

Ten years after the introduction of iNO in our institution, we reviewed our patient data concerning patients with TGA and PPHN. The incidence of PPHN in our cohort was higher than reported in previous reports in

by El-Segaier and colleagues [12]. If only the patients with severe PPHN were considered (group 1; n = 6), an incidence of 5.3% (6 of 112) was found. In this latter group all patients had TGA/IVS; three patients survived with iNO therapy (maximum duration 48 hours). The three nonsurvivors showed therapy-resistant PPHN with early (n = 2; maximum 48 hours) or intermediate mortality (n = 1, after eight days iNO). In these patients, additional treatment with enoximone (Perfan; Hoechst Marion Roussel, Höchst am Main, Germany), epoprostenol (Flolan; GlaxoSmithKline, Boronia, Australia), and isoprenaline was attempted unsuccessfully. The incidence and clinical outcomes in our series are comparable to those in the report of Luciani and colleagues [6]. In contrast to their treatment approach, preoperative cardiac ECMO was not used in the Netherlands during the study period. Its role in the management of TGA and PPHN is still unclear. The international experience with postoperative cardiac ECMO is limited but promising. So far, four cases of TGA/PPHN in which ECMO was used have been described in the literature. The results in those cases were promising; however, the high incidence of cerebral hemorrhage, associated with ECMO, may limit the use of mechanical cardiopulmonary support in those patients [13, 14]. One patient in our series successfully underwent a so-called "rescue switch," in which the ASO was performed in the presence of clinical PPHN. However, due to our limited experience we are not able to draw any conclusions regarding the place of such a procedure in the treatment of TGA/PPHN. The role of this approach needs further exploration.

Although iNO is considered to be the first choice therapy in neonates with PPHN, it is also known that about 30% of these patients are nonresponders to iNO [15]. This lack of response may be explained by the fact that PPHN is a complex, multifactorial disorder associated with a wide array of cardiopulmonary disorders. Airway obstruction or edema may decrease the response to iNO and atelectasis may cause intrapulmonary shunting and hypoxia, which is not remedied by vasodilators. A variety of cellular mechanisms is involved in the

consequently, in disturbances of this process. Persistent pulmonary hypertension of the newborn is associated with pulmonary endothelial and vascular smooth muscle cell dysfunction that may be caused by multiple factors, including hypoxia, inflammation, and mechanical forces. These vascular cells are crucially important in both pulmonary vascular adaptation and homeostasis. Its dysfunction may lead to a disturbed vasoconstrictor-vasodilator balance in the pulmonary vasculature.

Animal experiments have suggested a role for various vasoactive pathways in the pathogenesis of PPHN, including the endothelin-1 pathway with its A and B receptors, the prostacyclin-cGMP and the nitric oxide-cAMP pathway, and, finally, the vascular endothelial growth factor- fetal liver kinase receptor-1- kinase insert domain receptor pathway [16-18]. Treatment solutions are likely to be found also on multiple levels. Further studies are needed to unravel the cellular mechanisms of PPHN and to identify new treatment targets for newborns with this devastating disease.

The surgical mortality in our series is low (3.9%) and congruent with other reported series on the ASO for TGA [19,20]. However, preoperative mortality due to various comorbidity, a number that is usually not reported in surgical series, was 6% in our series. It should be noted that such a number importantly affects the overall survival rate in newborns with TGA.

The combination of TGA with PPHN is a serious and often fatal condition. It may jeopardize the usually favorable outcome of newborns with TGA. Its mechanism is, to a great extent, still unsolved. Restrictive patent foramen ovale and (or) premature closure of the ductus arteriosus have been suggested as potential causes of PPHN. Fetal echocardiography might play a role in identifying these fetuses with TGA at risk for PPHN. Our data do not allow conclusions on the value of prenatal echocardiography in these patients because none of the PPHN patients was diagnosed antenatally. Because of the retrospective nature of this study, and incomplete data regarding restriction of the PFO in the total patient group, it was not possible to determine the relative risk for PPHN in patients with restrictive PFO.

Despite the introduction of iNO therapy, the combination of TGA and PPHN remains a serious and often fatal condition. Newborns in which the PPHN could be successfully treated preoperatively, underwent ASO with good operative results and survival. However, the role of additional treatment modalities in patients with therapy-resistant PPHN, including new pulmonary vasoactive drugs, the perioperative use of ECMO, and the "rescue switch procedure," needs further investigation.

## References

1. Digilio MC, Casey B, Toscano A, et al. Complete transposition of the great arteries: patterns of congenital heart disease. *Circulation* 2001;104:2000.
2. Samanek M. Boy:girl ratio in children born with different forms of cardiac malformations; a population-based study. *Pediatr Cardiol* 1994;15:53-7.
3. Dick M, Heidelberger K, Crowley D. Quantitative morphometric analysis of pulmonary arteries in two patients with d-transposition of the great arteries and persistent fetal circulation. *Pediatr Res* 1981;15:1397-401.
4. Hawker RE, Freedom RM, Rowe RD. Persistence of fetal pattern of circulation in transposition of the great arteries. *Hopkins Med* 1974;134:107-17.
5. Kumar A, Taylor GP, Sandor GG, Patterson MW. Pulmonary vascular disease in neonates with transposition of the great arteries and intact ventricular septum. *Br Heart J* 1993;69:442-5.
6. Luciani GB, Chang AC, Starnes VA. Surgical repair of transposition of the great arteries in neonates with persistent pulmonary hypertension. *Ann Thorac Surg* 1996;61:800-5.
7. Kirklin JW, Blackstone EH, Tchervenkov CI, Castaneda AR. Clinical outcomes after the arterial switch operation for transposition. Patient, support, procedural, and institutional risk factors. *Congenital Heart Surgeon Society. Circulation* 1992;86:1501-15.
8. Dakshinamurti S. Pathophysiologic mechanism of persistent pulmonary hypertension of the newborn. *Pediatric Pulmonol* 2005;39:492-503.
9. Wernovsky G, Sanders SP. Coronary artery anatomy and transposition of the great arteries. *Coron Artery Dis* 1993;4:148-57.
10. Freed DH, Robertson CM, Sauve RS, et al. Intermediate-term outcomes of the arterial switch operation for transposition of great arteries in neonates: alive but well? *J Thorac Cardiovasc Surg* 2006;132:845-52.
11. Chang AC, Wernovsky G, Kulik TJ, Jonas RA, Wessel DL. Management of the neonate with transposition of the great arteries and persistent pulmonary hypertension. *Am J Cardiol* 1991;68:1253-5.
12. El-Segaier M, Hellstrom-Westas L, Wettrell G. Nitric oxide in neonatal transposition of the great arteries. *Acta Paediatr* 2005;94:912-6.
13. Jaillard S, Belli E, Rakza T, et al. Preoperative ECMO in transposition of the great arteries with persistent pulmonary hypertension. *Ann Thorac Surg* 2005;79:2155-8.
14. Soonswang J, Adiat I, Newman C, Smallhorn JF, Williams W, Freedom R. Mortality in potential arterial switch candidates with transposition of the great arteries. *J Am Coll Cardiol* 1998;32:753-7.
15. Travadi JN, Patole SK. Phosphodiesterase inhibitors for persistent pulmonary hypertension of the newborn: a review. *Pediatr Pulmonol* 2003;36:529-35.
16. Mata-Greenwood E, Meyrick B, Soifer SJ, Fineman JR, Black SM. Expression of VEGF and its receptors Flt-1 and Flk-1/KDR is altered in lambs with increased pulmonary blood-flow and pulmonary hypertension. *Am J Physiol Lung Cell Mol Physiol* 2003;285:L222-31.
17. Mata-Greenwood E, Grobe A, Kumar S, Noskina Y, Black SM. Cyclic stretch increases VEGF expression in pulmonary arterial smooth muscle cells via TGF-beta1 and reactive oxygen species: a requirement for NAD(P)H oxidase. *Am J Physiol Lung Cell Mol Physiol* 2005;289:L288-9.
18. Geiger R, Berger RM, Hess J, Bogers AJ, Sharma HS, Mooi WJ. Enhanced expression of vascular endothelial growth factor in pulmonary plexogenic arteriopathy due to congenital heart disease. *J Pathol* 2000;191:202-7.
19. Wernovsky G, Mayer JE, Jonas RA, et al. Factors influencing early and late outcome of arterial switch operation for transposition of the great arteries. *J Thorac Cardiovasc Surg* 1995;109:289-302.
20. Wetter J, Belli E, Sinzobahamvya N, Blaschzok HC, Brecher AM, Urban AE. Transposition of the great arteries associated with ventricular septal defect: surgical results and long-term outcome. *Ann Thorac Surg* 2001;72:816-22.