

## Review of the Tuberous Sclerosis Renal Guidelines from the 2012 Consensus Conference: Current Data and Future Study

J. Chris Kingswood<sup>a</sup> John J. Bissler<sup>d</sup> Klemens Budde<sup>g</sup> John Hulbert<sup>e</sup>  
Lisa Guay-Woodford<sup>f</sup> Julian R. Sampson<sup>c</sup> Matthias Sauter<sup>h</sup> Jane Cox<sup>a</sup>  
Uday Patel<sup>b</sup> Frances Elmslie<sup>b</sup> Chris Anderson<sup>b</sup> Bernard A. Zonnenberg<sup>i</sup>

<sup>a</sup>Sussex Kidney Unit, Royal Sussex County Hospital, Brighton, <sup>b</sup>South West Thames Regional Genetics Service, St. Georges Hospital, London, and <sup>c</sup>Institute of Medical Genetics, Cardiff University, Cardiff, UK; <sup>d</sup>Lebonheur Children's Hospital, University of Tennessee, and St. Jude Children's Research Hospital, Memphis, Tenn., <sup>e</sup>Urologic Physicians, PA, Edina, Minn., and <sup>f</sup>Children's National Health System, Washington D.C., USA; <sup>g</sup>Department of Nephrology, Charité Universitätsmedizin, Berlin, and <sup>h</sup>Klinikverbund Kempten-Oberallgäu, Kempten, Germany; <sup>i</sup>Oncology Department, Universitair Medisch Centrum, Utrecht, Netherlands

### Key Words

Tuberous sclerosis complex · Angiomyolipoma · Embolization · Mammalian target of rapamycin inhibitors · Everolimus · Sirolimus · Renal complications · Prevention · Treatment guidelines

### Abstract

Renal-related disease is the most common cause of tuberous sclerosis complex (TSC)-related death in adults, and renal angiomyolipomas can lead to complications that include chronic kidney disease (CKD) and hemorrhage. International TSC guidelines recommend mammalian target of rapamycin (mTOR) inhibitors as first-line therapy for management of asymptomatic, growing angiomyolipomas >3 cm in diameter. This review discusses data regarding patient outcomes that were used to develop current guidelines for embolization of renal angiomyolipomas and presents recent data on 2 available mTOR inhibitors – sirolimus and everolimus – in the treatment of angiomyolipoma. TSC-associated renal angiomyolipomas can recur after embolization. Both sirolimus and everolimus have shown effectiveness in reduction of angiomyolipoma volume, with an acceptable safety profile

that includes preservation of renal function with long-term therapy. The authors propose a hypothesis for mTORC1 haploinsufficiency as an additional mechanism for CKD and propose that preventive therapy with mTOR inhibitors might have a role in reducing the number of angiomyolipoma-related deaths. Because mTOR inhibitors target the underlying pathophysiology of TSC, patients might benefit from treatment of multiple manifestations with one systemic therapy. Based on recent evidence, new guidelines should be considered that support the earlier initiation of mTOR inhibitor therapy for the management of renal angiomyolipomas to prevent future serious complications, rather than try to rescue patients after the complications have occurred.

© 2016 S. Karger AG, Basel

### Overview of Renal Disease in Tuberous Sclerosis Complex

Guidelines relevant for tuberous sclerosis complex (TSC)-related angiomyolipoma, including updated diagnostic criteria and surveillance and management recommendations, were developed from the second Interna-

KARGER

© 2016 S. Karger AG, Basel

E-Mail: karger@karger.com

Dr. J. Chris Kingswood  
Sussex Kidney Unit  
Royal Sussex County Hospital

**Par Pharm., Inc.**  
**Exhibit 1120**  
**Par Pharm., Inc. v. Novartis AG**  
**Case IPR2016-00084**

**Table 1.** Kidney-related surveillance and management recommendations of the International Tuberous Sclerosis Complex Consensus Group [2]

Newly diagnosed or suspected TSC	Diagnosed with definite or possible TSC
<p><i>Surveillance of kidneys</i></p> <p>Obtain MRI of the abdomen to assess for the presence of angiomyolipoma and renal cysts</p> <p>Screen for hypertension by obtaining accurate blood pressure</p> <p>Evaluate renal function by determining GFR</p>	<p>Obtain MRI of the abdomen to assess angiomyolipoma progression and renal cystic disease (every 1–3 years for life)</p> <p>Assess renal function (GFR and blood pressure) at least annually</p>
Clinical presentation	Recommendation
<p><i>Management recommendations for renal angiomyolipoma</i></p> <p>Angiomyolipoma with acute hemorrhage</p>	<p>Embolization (followed by corticosteroids for 7 days to mitigate post-embolization syndrome) [3]. Embolization should be as selective as technically feasible to preserve renal parenchyma</p> <p>Avoid nephrectomy</p>
<p>Asymptomatic, growing angiomyolipoma &gt;3 cm in diameter</p>	<p>First-line: mTOR inhibitor</p> <p>Second-line: selective embolization or kidney-sparing resection</p>

tional TSC Consensus Conference in Washington, D.C., USA [1, 2], in which 79 experts from 14 countries participated. Table 1 summarizes the surveillance and management recommendations relevant to the kidney. The nephrology subcommittee recommended the use of mammalian target of rapamycin (mTOR) inhibitors for first-line therapy for management of asymptomatic, growing angiomyolipomas >3 cm in diameter [1, 2]. These guidelines were based on a search of PubMed and Scopus databases performed on March 12, 2012, for the consensus guidelines [2] and of the OVID database from 2000 to 2014. This review is based on those and subsequent relevant published papers.

The renal presentation of TSC most often encompasses renal cysts, angiomyolipoma, impaired kidney function and, more rarely, renal cell carcinoma (RCC) [4, 5]. Cysts occur in approximately 30–45% of patients with TSC and may be associated with kidney failure and hypertension [5]. The *TSC2* and *PKD1* contiguous gene-deletion syndrome affects approximately 1 in 20 patients with TSC. People with this syndrome have deletions involving both the *TSC2* and the *PKD1* genes [6]; in these patients, cystic disease is severe and commonly associated with early renal failure. Angiomyolipomas are benign tumors composed of blood vessels, smooth muscle-like cells, and adipose-like tissue [1]. They are rarely reported extrarenally but occur in the kidneys in up to 80% of patients with TSC and contribute to renal disease as the most common cause of TSC-related death [7]. A strong association between age, angiomyolipoma size, and chronic kidney disease (CKD)

has been reported; patients with higher CKD stage tend to be older and have more advanced angiomyolipoma [8]. CKD may develop as a result of loss of renal parenchyma because of growth of angiomyolipoma or cysts, or as a complication from surgery or embolization [4, 8]. Fat-poor angiomyolipomas (i.e. the epithelioid variant) are commonly observed in patients with TSC, whereas in the general population, they account for <0.1% of angiomyolipomas [1, 5]. RCCs (occurring in 2–3% of patients with TSC) [5] may be confused diagnostically with fat-poor angiomyolipomas [9, 10]. Contrast-enhanced MRI or CT may help in making this differentiation, but it remains challenging even in high volume centers. Biopsy might nevertheless be needed. A slower growth rate has been postulated as another way to distinguish fat-poor angiomyolipoma from RCC [10].

A retrospective analysis assessed the risk of long-term renal outcomes, including CKD, by evaluating records from patients diagnosed with TSC who were included in the UK Clinical Practice Research Datalink linked to the Hospital Episode Statistics database [11]. Overall, 105 of 341 total TSC patients (31%) had renal involvement (defined as presence of renal cysts, polycystic kidney disease, CKD, kidney stones, or kidney neoplasms such as angiomyolipomas). Among adult patients, 38% (91 of 237 patients) had recognized renal involvement or renal-related comorbidity (CKD, 35%; single cyst, 16%; hematuria, 21%; anemia, 21%). The prevalence of CKD (stages 3–5) in the TSC population up to age 64 was greater in every age group compared with the UK general population. The

crude prevalence estimates showed that TSC patients developed stage 3+ CKD 30 years earlier than the general UK population, and rates of stage 3+ CKD were more than 5 times higher than in the general UK population (relative risk 5.4, 95% CI 3.7–8.0;  $p < 0.001$ ) [11].

Patients with TSC-associated angiomyolipoma have an increased risk for hemorrhage, with risk factors considered to be angiomyolipoma size ( $>3$  or  $>4$  cm), aneurysm size  $>0.5$  cm, and serial growth [3, 7]. Although small angiomyolipomas are usually asymptomatic, angiomyolipomas  $\geq 4$  cm become symptomatic in 68–80% of patients, with 50–60% presenting as hemorrhage [12].

Renal complications associated with TSC were also assessed in retrospective analyses of natural history data collected from 2 large databases [7]. The first analysis evaluated retrospective data collected by questionnaires from 296 patients with TSC in the UK Renal Registry. Twenty-seven of 52 patients (52%) with serial measurements of angiomyolipoma lesions captured over 5 years showed growth. Serial growth was found to be a risk factor for bleeding (21% of patients with growing angiomyolipomas experienced renal bleeding, compared with only 4% of patients with stable angiomyolipomas;  $\chi^2 = 7.42$ ;  $p < 0.01$ ). The second analysis evaluated data from 278 patients with TSC who were followed up at the St. George's Hospital Clinic (London, UK), of whom 130 had renal angiomyolipoma. Data were analyzed from 53 adults with TSC and renal angiomyolipoma for whom serial imaging data were available. Sixty-seven percent of the angiomyolipomas exhibited serial growth in these adults, with a mean rate of growth of 5.5 mm/year. The growth rate of the angiomyolipomas was not correlated with the size of lesion or age of patient, although growth rate tended to be greater in younger patients [7].

### Outcome of Intervention

From our review, we identified 16 case series that reported embolization of renal angiomyolipoma with sufficient data to characterize patient details and outcomes (online suppl. table 1; for all online suppl. material, see [www.karger.com/doi/10.1159/000448293](http://www.karger.com/doi/10.1159/000448293)). Thereby, we found that after embolization, approximately 25% of TSC-associated renal angiomyolipoma recur.

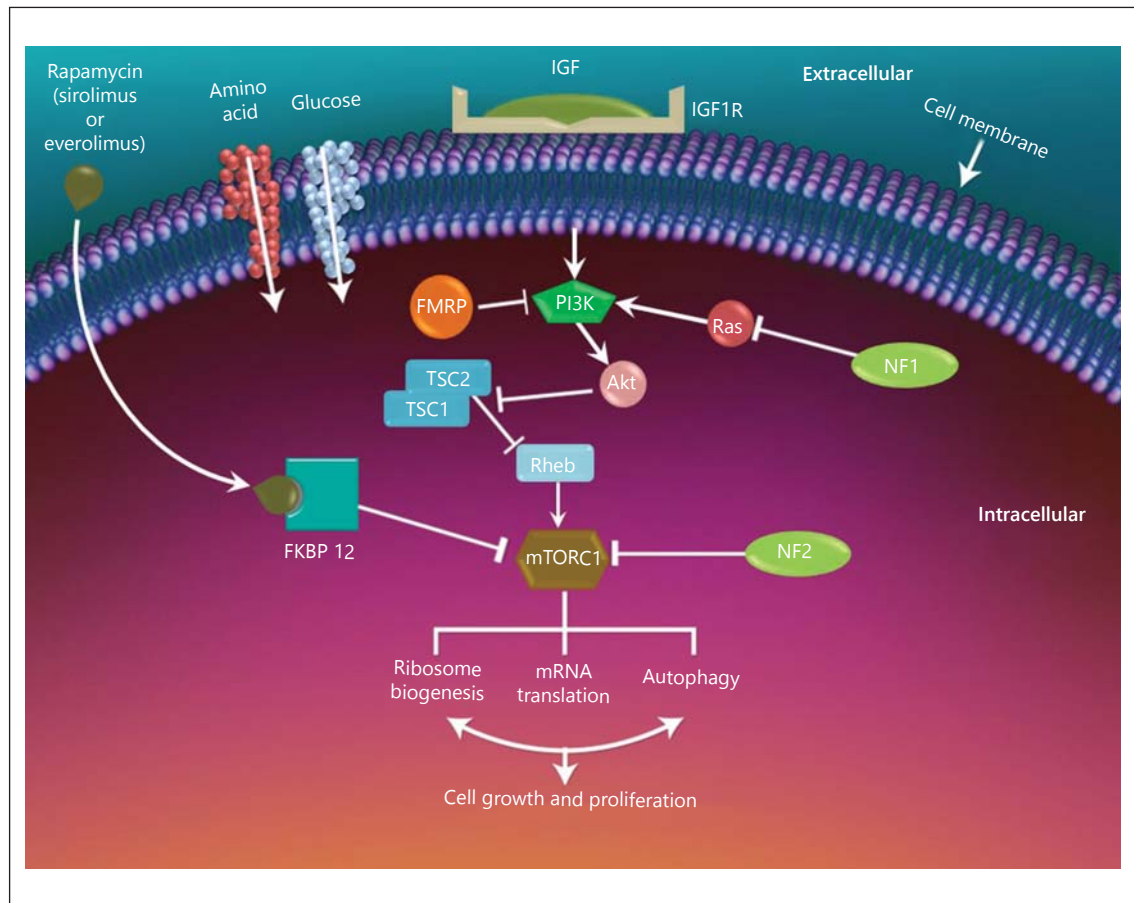
The incidence of CKD was assessed in a retrospective chart review of a TSC cohort treated in a single center in the Netherlands [13]. The mean duration of follow-up was 15.8 years, and the median age at the end of follow-up was 40 years. Of 351 patients with TSC, 244 (69.5%) had con-

firmed renal angiomyolipoma. Patients were assigned a renal angiomyolipoma stage (from none detected to 6) based on the number of angiomyolipomas in both kidneys, size of angiomyolipoma, and kidney anatomy (table 2). Fifty-nine percent of patients (144 of 244) with a confirmed renal angiomyolipoma reached a highest angiomyolipoma stage  $\geq 3$ , which indicated that the patient was at a high risk for hemorrhage and was a candidate for elective embolization. Hypertension, anemia, impaired kidney function, and need for blood transfusions increased with angiomyolipoma stage. Patients in higher stages were more likely to require more embolization. Yearly embolization rates ranged from 0.08 to 0.14 depending on angiomyolipoma stage, suggesting that patients with large, growing asymptomatic angiomyolipomas will require an embolization every 7–11 years. Additionally, impaired kidney function was more common in patients who had undergone embolization (29%) than in those who had not (10%) [13].

### Effectiveness/Risk of mTOR Inhibitors

mTOR inhibitors represent the first systemic approach to treating the underlying pathophysiology of TSC disease by blocking the activation of mTOR complex 1 and downstream signaling (fig. 1) [5]. Two oral mTOR inhibitors – sirolimus and everolimus – have been evaluated for management of angiomyolipoma (online suppl. table 2). Four small, open-label studies showed the effectiveness of sirolimus in the management of renal angiomyolipoma [14–17].

Data pertaining to the effects of everolimus on angiomyolipoma are more robust; results from 2 large randomized, double-blind, placebo-controlled, phase 3 trials are available [18, 19]. In a subgroup analysis of patients in the EXIST-1 trial, after a median follow-up duration of 9.7 months, angiomyolipoma response rate (an exploratory end point) was 53.3% for everolimus compared with 0% for placebo. Angiomyolipoma volume reductions with everolimus were sustained over 48 weeks of treatment (fig. 2) [20]. In EXIST-2, the primary end point of angiomyolipoma response was achieved in 42% of patients (33 of 79) compared with 0% for placebo (0 of 39,  $p < 0.0001$ ) after a median everolimus exposure of 8.7 months, and the median time to reach an angiomyolipoma response was 2.9 months [18]. Data from an open-label extension of the EXIST-2 study showed sustained reduction in angiomyolipoma volume to at least 192 weeks of treatment (fig. 3), with an angiomyolipoma response rate of 56.3% (63 of 112 patients) over a median 39.8 months of everolimus exposure. Among the 63 patients achieving angiomyolipoma response at any time, only 2 progressions



Color version available online

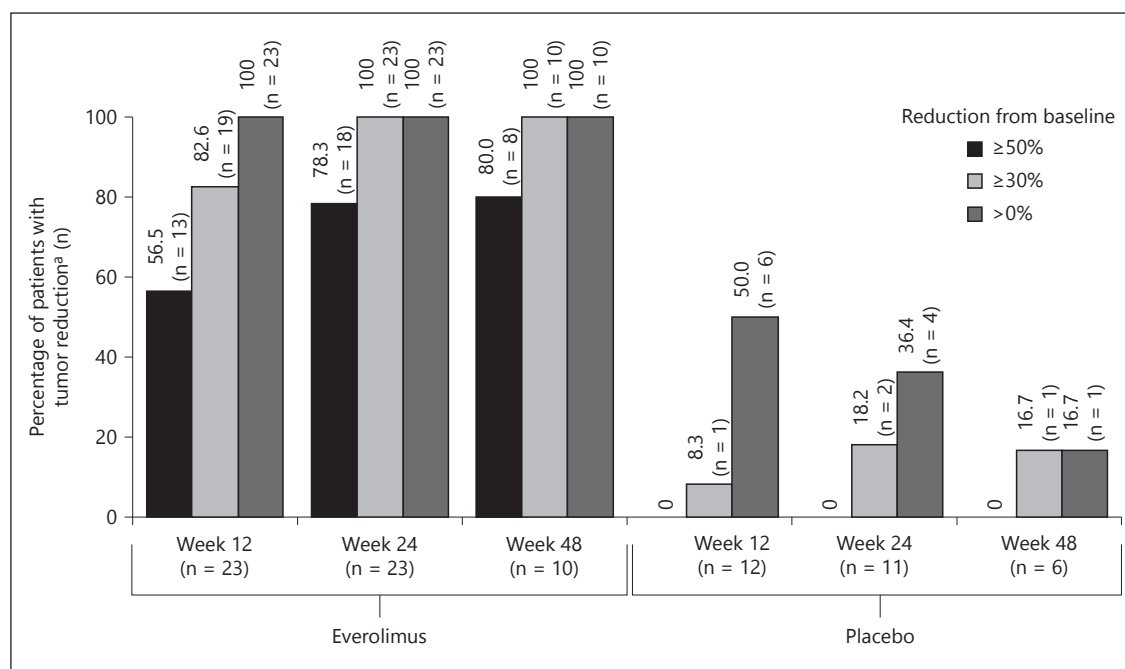
**Fig. 1.** The mTOR pathway.

**Table 2.** Renal angiomyolipoma staging criteria proposed in a retrospective study

Stage	Angiomyolipoma number	Angiomyolipoma size	Description of kidney anatomy
None detected <sup>a</sup>	None $\geq 1$ cm in longest diameter	–	Normal
1	$\leq 5$	$< 3.5$ cm	Normal
2	$> 5$	$< 3.5$ cm	Normal
3	$\leq 5$	At least 1 $\geq 3.5$ cm	Kidney intact
4	$> 5$	1–4 $\geq 3.5$ cm	Kidney intact
5	$> 5$	5 or more $\geq 3.5$ cm	Kidney recognizable
6	$> 5$	At least 1 $\geq 5.0$ cm	Kidney not recognizable

<sup>a</sup> Angiomyolipoma not detectable or lesions  $< 1$  cm unidentifiable as angiomyolipoma. Reprinted with permission from Eijkemans et al. [13].





**Fig. 2.** Percentage change from baseline of sum of volumes (3 cm<sup>3</sup>) of target angiomyolipoma lesions by time window. Percentages were calculated relative to the number of patients evaluated at baseline and at the corresponding visit. Reproduced with permission from Kingswood et al. [20].

were observed. Long-term data show continued shrinkage of angiomyolipoma with everolimus therapy. Notably, at this cutoff, no bleeding was observed with everolimus in a population with high risk for bleeding events before the initiation of the mTOR inhibitor therapy [21].

### Safety of mTOR Inhibitors

Class effects of mTOR inhibitors include stomatitis/mucositis/mouth ulceration (~50%), hypercholesterolemia (20–40%), hypertriglyceridemia (12–50%), infections (40–70%), hypophosphatemia (11%), amenorrhea (13–38%), hematologic abnormalities (leukopenia, neutropenia, 10–40%), and proteinuria (4–30%) [14–19]. The EXIST-2 extension data show a decrease in the number of newly emergent adverse effects over time [22]. In addition, data from the 3.5-year analysis of EXIST-2 reported that severe renal impairment (glomerular filtration rate (GFR) <30 ml/min/1.73 m<sup>2</sup>) was observed in only 7.1% of patients, all of whom had compromised renal function prior to everolimus initiation. Furthermore, overall GFR remained stable over time; median GFR at baseline was 85 ml/min/1.73 m<sup>2</sup> and median GFR at week 120 was 84 ml/min/1.73 m<sup>2</sup> [21].

### Potential Mechanisms for Renal Complications

CKD may not be entirely attributable to angiomyolipoma hemorrhage and subsequent treatment (i.e. surgery/embolization). A mechanism independent of bleeding may occur where large, benign angiomyolipomas encroach on normal renal tissue and lead to CKD [5]. We propose 2 additional hypotheses for the development of CKD. The first postulates that normal replacement renal tissue becomes TSC tissue because of somatic second-hit mutations [23] occurring during rapid cell division (when the kidney still has growth and repair potential at age <35–40); this would cause an accelerated loss of normal renal tissue leading to CKD. A second hypothesis is that *TSC1* or *TSC2* haploinsufficiency may lead to modest mTORC1 overactivity and, therefore, glomerular hypertrophy and hyperfiltration. It has been postulated that mTORC1 overactivity is a mechanism of CKD progression, especially in diabetic nephropathy [24] and may be one mechanism by which patients with TSC develop CKD in middle age. Data show that mTOR is activated in patients with diabetic nephropathy and that inhibition of mTOR signaling prevented glomerulosclerosis and ameliorated progression of glomerular disease in a mouse model [25]. In addition, either haploinsufficiency or second somatic mutation in the tubule cells could predispose

# Explore Litigation Insights

Docket Alarm provides insights to develop a more informed litigation strategy and the peace of mind of knowing you're on top of things.

## Real-Time Litigation Alerts



Keep your litigation team up-to-date with **real-time alerts** and advanced team management tools built for the enterprise, all while greatly reducing PACER spend.

Our comprehensive service means we can handle Federal, State, and Administrative courts across the country.

## Advanced Docket Research



With over 230 million records, Docket Alarm's cloud-native docket research platform finds what other services can't. Coverage includes Federal, State, plus PTAB, TTAB, ITC and NLRB decisions, all in one place.

Identify arguments that have been successful in the past with full text, pinpoint searching. Link to case law cited within any court document via Fastcase.

## Analytics At Your Fingertips



Learn what happened the last time a particular judge, opposing counsel or company faced cases similar to yours.

Advanced out-of-the-box PTAB and TTAB analytics are always at your fingertips.

## API

Docket Alarm offers a powerful API (application programming interface) to developers that want to integrate case filings into their apps.

## LAW FIRMS

Build custom dashboards for your attorneys and clients with live data direct from the court.

Automate many repetitive legal tasks like conflict checks, document management, and marketing.

## FINANCIAL INSTITUTIONS

Litigation and bankruptcy checks for companies and debtors.

## E-DISCOVERY AND LEGAL VENDORS

Sync your system to PACER to automate legal marketing.