

(3) Diminished fibrinolytic properties of the blood which would promote fibrin deposition and enhance fibrin deposition and clotting.

This tendency to abnormal stasis and clotting of blood in the superficial dermal venules in acrocyanosis (Crocq 1896) and the resulting alteration in the anatomy of the blood vessels in the upper dermis can explain the associated signs of micropapular chilblains (erythema pernio papulosum, Haxthausen 1930, Hutchinson 1878), pink cinnabar spots (Stern 1937), and reticular patterning (Estes 1956). Micropapular chilblains are visible on the skin when the clotting has affected a sufficiently large cluster of microvessels.

Since Sir Thomas Lewis (1927), many have tried to explain the signs of acrocyanosis on the basis of: functional disorder of some segment of acral blood vessels whether arterial, capillary or venous; pharmacological oddity of the cutaneous nerves, their endings or responses; a perversion of the action of vasoactive and other agents in the skin; occult immunological irregularities; and other physiological and pathological peculiarities. Burch & Phillips (1963), exhaustively reviewing all these writings, concluded that the signs could not be satisfactorily explained on such grounds alone.

I postulate that the signs in the skin of acrocyanosis or micropapular chilblains are merely different degrees of the same disorder. They result from an accentuation of the normal features of healthy whole blood flow, mainly stasis and clotting on exposure to cold. In these conditions the hyperviscosity of the blood allows clotting to occur only in the cutaneous microvessels exposed to the cold.

The disease, then, results from an intravascular defect rather than a blood vessel or skin disorder in the first instance. This blood coagulation disorder is probably not a simple matter but the result of a complex and interrelated series of defects. It only involves the skin and affects no other organs because they are at body temperature. If it were not for the special circumstances of its exposure to surface chilling in the skin microvessels, the blood's defects would have been sufficiently minor to have escaped detection.

REFERENCES

- Burch G F & Phillips J (1963) In: *Handbook of Physiology*: Section 2. Ed. W F Hamilton. American Physiological Society, Washington; 2, 1230-32
- Copeman P W M (1970) *British Journal of Dermatology* 82, Suppl. 5, 51
- Copeman P W M & Ryan T J (1971) *British Journal of Dermatology* 85, 205
- Crocq C (1896) *Semaine médicale (Paris)* 16, 298
- Estes J (1956) *Modern Concepts of Cardiovascular Disease* 25, 355
- Haxthausen H (1930) *Cold in Relation to Skin Diseases*. Heinemann, London; p 65

- Hutchinson J (1878) *Lectures on Clinical Surgery Vol. I: On Certain Rare Diseases of the Skin*. Churchill, London; p 362
- Lewis T H (1927) *The Blood Vessels of the Human Skin and Their Responses*. Shaw & Son, London
- Ryan T J & Copeman P W M (1969) *British Journal of Dermatology* 81, 563-73
- Stern S (1937) *British Journal of Dermatology* 49, 100-106
- Zweifach B W & Metz D B (1955) *Angiology* 6, 282-290

Histogenesis of the Inflammatory Component of Rosacea

by R Marks BSC MRCP
(*Institute of Dermatology,
St John's Hospital for Diseases of the Skin,
Lisle Street, Leicester Square, London WC2H 7BJ*)

Rosacea is characterized by a wide range of physical signs. On the one hand is erythema and telangiectasia making up the vascular component, and on the other papules and pustules which constitute the inflammatory aspect of the disease. It is impossible to say which of these components is primary or even whether the inflammation and the vascular components are causally related.

In a previous investigation it was shown that the hair follicles are not the initial focal points of the inflammation so characteristic of papular rosacea (Marks & Harcourt-Webster 1969). When there is infiltration and disruption or even abscess formation in the follicular epithelium it seems to be a secondary process and not of fundamental importance in the overall biology of the disorder. As the inflammation does not appear to be the result of a follicular disorder, the question remains - what is the cause of the inflammation?

Detailed examination of biopsy material from patients with papular rosacea has shown the cellular infiltrate to be predominantly distributed around the small blood vessels of the subpapillary venous plexus (Marks & Harcourt-Webster 1969). In addition, in disseminated rosacea there is pronounced vascular involvement amounting to a frank vasculitis in places (Marks & Wilson Jones 1969). Furthermore, telangiectasia and the oedema that is so commonly observed add to the suspicions that the blood vessels are more than incidentally affected and primary vascular involvement could be central to the pathogenesis of the inflammation. For these reasons, the role of small blood vessels in papular rosacea has been investigated in this study by histochemical and autoradiographic techniques. At the same time, and as a corollary to the blood-vessel studies, the rate of proliferation and the enzyme histochemical characteristics of the cellular infiltrate have been examined.

Dr. Reddy's Laboratories, Ltd., et al.

v.

Patients and Methods

Altogether 27 patients were studied. All had typical papular rosacea with a background of erythema and telangiectasia and a variable amount of swelling. There were 15 men and 12 women with an average age of 52.6 years (range 24-77). Seven patients were taking tetracycline at the time of biopsy; 2 had started two days previously and the other 5 had been treated for periods of one to three weeks. Seven other patients had used topical corticosteroids for varying periods. Biopsies were taken of papules with a 5 mm punch.

In order to identify cells about to divide by autoradiography, 14 papules were injected intracutaneously with tritiated thymidine. Ten papules were removed one hour after injection. The other four biopsies were removed at intervals of one, two, three and four days after injection. Ilford nuclear emulsion (K4) was used to coat the sections, and exposure times of two and three weeks were employed.

To give more precision to the kinetic data of the cells the inflammatory infiltrate was divided into three main cellular types: lymphocytes, histiocytes and endothelial cells. The number of cells labelled in each category was counted (between 500 and 1000 cells of each type for every specimen) and expressed as a percentage (labelling index). Cells difficult to classify were not counted.

Enzyme histochemical tests on the biopsies of 16 patients with papular rosacea were performed as follows: (1) to test enzymes concerned with respiratory activity - NADH diaphorase, lactic dehydrogenase (LDH) glucose-6-phosphate dehydrogenase (using the methods in Pearse 1960); (2) to test the integrity of the small vessel endothelium - alkaline phosphatase (Gomori 1952), adenosine triphosphatase (Wachstein & Meisel 1960).

Results and Comment

Table 1 shows the mean labelling indices for the three individual cell types in the ten specimens removed one hour after injection with tritiated thymidine. The overall labelling index of 3.3% is high and suggests a rapid cell turnover rate (Fig

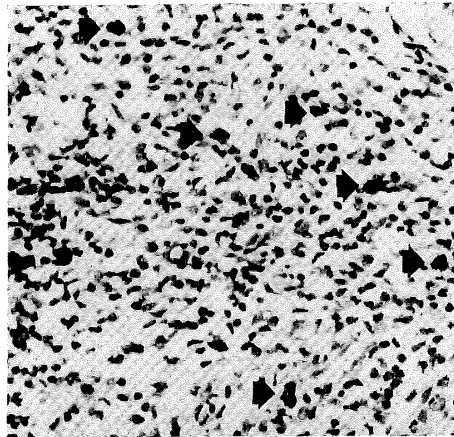


Fig 1 Autoradiograph from biopsy of lesion of papular rosacea injected one hour previously with tritiated thymidine. There are many labelled inflammatory cells (indicated by arrows). H&E. $\times 100$

1). Lachapelle (1972), using an *in vitro* method, found that the infiltrate in primary irritant dermatitis had a labelling index of 0.5% compared with 2.5% in allergic contact dermatitis. Furthermore, the figure of 3.3% obtained in the present investigation is higher than the range of values given by Spector (1971) as being characteristic of a 'low turnover' granuloma (0.5-2.0%) but below the value given by that author as an example of a high turnover granuloma (4.6%). The high overall labelling index is presumably the result of a rapid rate of cell destruction but does not imply any particular mechanism for cell death. Similar proliferative responses have been noted by Monis *et al.* (1968) in carrageenan granulomata and by Epstein & Krasnabrod (1968) in silica granulomata. Any actively phagocytic infiltrate may have a labelling index of the same order as that observed in the present investigation.

Table 2 sets out the values obtained for the labelling indices in the four biopsies removed between one and four days after intracutaneous injection with tritiated thymidine. It shows that there was a tendency for the total number of labelled cells to drop with increasing intervals from the time of injection. This observation also

Table 1

Mean labelling indices for three cell types in ten specimens removed one hour after injection with tritiated thymidine

Cell type	Mean labelling index (%)	Standard error of mean
Lymphocytes	3.1	0.6
Histiocytes	4.6	0.9
Endothelial cells	1.3	0.3
All cell types	3.3	0.5

Table 2

Values for labelling indices in four biopsies removed between one and four days after intracutaneous injection with tritiated thymidine

Interval	Labelling indices for cell types (%)			
	Lymphos.	Histos.	Endos.	All
1 day	3.1	2.8	3.1	3.0
2 days	0.6	0.3	5.6	2.1
3 days	0.4	2.4	2.0	1.0
4 days	1.2	3.1	2.0	1.8

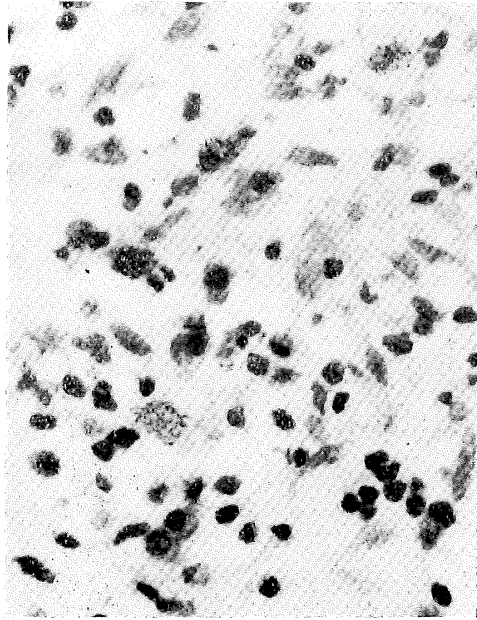


Fig 2 *Autoradiograph from papular rosacea to show labelled cells of the histiocytic series. H & E. $\times 185$*

implies a high rate of cell destruction in the infiltrate. Larger histiocytic types were labelled to a greater extent than lymphocytes in several specimens (Fig 2).

Spector & Lykke (1966) have shown that in experimental granulomatous inflammation apparently well-differentiated macrophage types remained capable of division. All the biopsies examined contained larger histiocytic types that reacted quite strongly in the nonspecific esterase reaction and were also strongly reactive for the NADH and LDH enzyme reactions. These positive reactions are characteristic of functional phagocytic cells.

There was a surprising degree of labelling of endothelial cells in the autoradiographs prepared from biopsy specimens injected one hour previously with tritiated thymidine. It is difficult to identify endothelial cells in routine histological sections. However, by restricting the scoring of endothelial cells to spindle-shaped cells lining vascular spaces this difficulty has been at least partially overcome. It was found that endothelial cells identified in this way had a labelling index of 1.3% (Fig 3). There have been very few studies of the proliferation kinetics of vascular endothelium and even fewer of capillary endothelium in inflamed human skin, so that the significance of this finding is uncertain. Not only were endothelial cells labelled but labelled perithelial cells were also obvious in many of the 'one hour' autoradiographs. The fact that endothelial and

perithelial cells showed an appreciable number of dividing cells suggests that these vessels, though 'irritated', were not severely damaged and retained the capacity for division. The small blood vessels were well delineated with the adenosine triphosphatase and alkaline phosphatase enzyme histochemical tests and the mitochondrial enzyme reactions. This retention of enzyme reactivity also suggests that the small vessels were not significantly injured.

From the foregoing it seems that the population kinetics and the histochemical characteristics of the infiltrate both suggest an actively phagocytic role for these cells. The observations also imply intimate vascular participation yet absence of a vasculitis. This interpretation of the data aids in understanding the pathogenesis of the inflammatory reaction in rosacea if some such mechanism as was suggested by Haxthausen (1930) is invoked. He suggested that small cutaneous blood vessels were in some way damaged by exposure to fluctuations of environmental temperature and other climatic stimuli. More elastotic change is found in the biopsies of rosacea patients than in age, sex and site-matched control biopsies (Marks & Harcourt-Webster 1969). Small vessels become dilated in elastotic tissue. If these vessels were in addition in some way injured, for example by cold, they would also become leaky. In rosacea it is possible that as

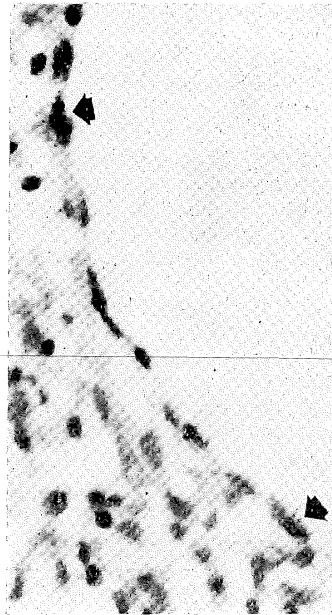

Fig 3 *Autoradiograph showing a large dilated thin-walled blood vessel with two labelled endothelial cells (indicated by arrows). H & E. $\times 185$*

a consequence of vessel malfunction macromolecules leak into the perivascular tissues and attract phagocytes. Furthermore, if fibrinogen was amongst these macromolecules, episodes of inflammation would result and the pathogenesis of the inflammation in rosacea be explained.

REFERENCES

- Epstein WL & Krasnabrod H (1968) *Laboratory Investigation* 18, 190
 Gomori I (1952) *International Review of Cytology* 1, 323
 Haxthausen H (1930) *British Journal of Dermatology* 42, 105
 Lachapelle JM (1972) *British Journal of Dermatology* 87, 460
 Marks R & Harcourt-Webster N (1969) *Archives of Dermatology* 100, 683
 Marks R & Wilson Jones E (1969) *British Journal of Dermatology* 81, 16
 Monis B, Weinberg T & Spector G J (1968) *British Journal of Experimental Pathology* 49, 302
 Pearse A G E (1960) *Histochemistry: Theoretical and Applied*, Churchill, London
 Spector W G (1971) *Proceedings of the Royal Society of Medicine* 64, 941
 Spector W G & Lykke A W J (1966) *Journal of Pathology and Bacteriology* 92, 163
 Wachstein M & Meisel E (1960) *Journal of Histochemistry and Cytochemistry* 8, 387

Chronic Fungal Infection (*E. floccosum*), Erythroderma, Immune Deficiency and Lymphoma

by G M Levene MB MRCP (*St John's Hospital for Diseases of the Skin, London WC2H 7BJ*)

This report concerns a man with multiple pathology. An attempt will be made to link his disorders together, which seem unlikely to have arisen solely by unhappy coincidence.

He is a civil engineer aged 36. He had a healthy childhood and the only early comment of note is that he had some scaling between his toes whilst at school. His main trouble started in 1957 whilst he was serving in the army in Cyprus at the age of 20. He developed a boil on his shin, followed by pustules on the feet and then a generalized weeping dermatitis. He was treated first in Nicosia and then in military hospitals in England until he was discharged from the army with a disability pension and a diagnosis of 'exfoliative dermatitis'.

In 1958, about a year after onset of the eruption, he was admitted to Guy's Hospital under Dr L Forman with a persisting generalized exudative eruption. He had an episode of septicæmia and pleurisy at this time which responded well to treatment. At this time also scrapings from the skin showed fungus which proved on culture to be *Epidermophyton floccosum*. He was given a course of oral griseofulvin which had a dramatic effect, clearing his skin in three weeks. He remained completely clear for three months after which there was a slight recurrence. From then on fungus has always been present in the finger-nails

and toe-nails and occasionally in the groins despite repeated courses of griseofulvin.

There was no further change in his skin until the summer of 1970 when he developed a generalized pruritic eruption. He was admitted to St John's Hospital in October 1970, at which time he was found to have a low-grade erythroderma involving particularly the trunk, groins and thighs. Several finger- and toe-nails showed minimal dystrophy. There were no other abnormal physical signs. He had further brief admissions in 1971 and 1972 for investigation. His erythroderma persisted more or less unchanged. Treatment with a mixture of equal parts of benzoic acid compound ointment and Propaderm ointment reduced pruritus and scaling.

In June of 1972, during his last admission, he gave a two-month history of indigestion, flatulence and the sensation of food sticking in his chest. A barium meal performed at his local hospital in Aberystwyth indicated an ulcer and tumour in the cardia of the stomach and he was referred to the Cardiothoracic Surgical Unit of Broadgreen Hospital, Liverpool. Œsophagoscopy was performed and two biopsies taken which showed tumour. In September his left chest and abdomen were surgically explored (Mr H R Matthews). A tumour of the cardia was found, partly in the stomach and partly in the Œsophagus, which was bulky but with no evidence of spread to the mediastinal or abdominal lymph nodes or liver. Œsophago-gastrectomy was performed with anastomosis of the Œsophagus to a gastric tube just below the aortic arch. Some local lymph-nodes were excised and, in view of the proximity of the tumour to the spleen, splenectomy was performed as well. He made a straightforward recovery and has apparently remained well since. The tumour was found on histology to be a reticulum cell sarcoma.

Investigations

Mycology: *E. floccosum* had been found on numerous occasions over the years and was isolated again in toe-nails, finger-nails and right palm in 1970. No fungus was seen in the scaly red lesions on the trunk and shins. The strain of *E. floccosum* isolated from the patient was found to be griseofulvin-resistant (minimum inhibitory concentration: patient strain >50.00, control strain 1.5 µg/ml; Dr Yvonne Clayton). In July 1972 fungus was found in palms, toes, toe-clefts, soles, hallux nails and left finger-nails, but not in wrists, trunk, groins, scalp, neck or legs.

Clinical immunology: Low IgG and IgA levels were found on the four occasions on which differential serum immunoglobulins were estimated. An average blood lymphocytopenia of 800/mm³ was found with counts below 1000/mm³ on 5 of 7 occasions (normal adult range 1000-