

JOURNAL of the
AMERICAN ACADEMY OF
DERMATOLOGY

VOLUME 16 NUMBER 2 PART 1

february 1987

CME article

Etretinate therapy


CHARLES N. ELLIS, M.D., and JOHN J. VOORHEES, M.D., Ann Arbor, MI

PUBLISHED BY THE C.V. MOSBY COMPANY

Dr. Reddy's Laboratories, Ltd., et al.

DOCKET
ALARM

Find authenticated court documents without watermarks at docketalarm.com.



JOURNAL of the
AMERICAN ACADEMY OF
DERMATOLOGY



VOLUME 16 NUMBER 2 PART 1

february 1987

CME article

Etretinate therapy

CHARLES N. ELLIS, M.D., and JOHN J. VOORHEES, M.D., Ann Arbor, MI

PUBLISHED BY THE C. V. MOSBY COMPANY
ST. LOUIS, MISSOURI 63146



Copyright © 1987 by the American Academy of Dermatology, Inc.

Editor

J. Graham Smith, Jr., M.D.

Associate Editor

Donald C. Abele, M.D.

Editorial Office

Department of Dermatology
Medical College of Georgia
Augusta, Georgia 30912-7400
404-828-4684

Assistant Editors

Philip C. Anderson, M.D.

Walter H. C. Burgdorf, M.D.

Richard L. Dobson, M.D.

John H. Epstein, M.D.

Stephen I. Katz, M.D.

W. Clark Lambert, M.D.

Walter G. Larsen, M.D.

Alan R. Shalita, M.D.

John S. Strauss, M.D.

Vol. 16, No. 2, Part 1, February 1987, the Journal of the American Academy of Dermatology (ISSN 0190-9622) is published monthly by The C. V. Mosby Company, 11830 Westline Industrial Dr., St. Louis, MO 63146.

Annual subscription rates: \$57.00 for individuals, \$104.00 for institutions.

Second class postage paid at St. Louis, MO, and additional mailing offices. Printed in the U.S.A. Copyright © 1987 by the American Academy of Dermatology, Inc.

Postmaster: Send address changes to The C. V. Mosby Company, 11830 Westline Industrial Dr., St. Louis, MO 63146.

Contents February, Part 1, 1987

CONTINUING MEDICAL EDUCATION

Etretinate therapy 267
Charles N. Ellis, M.D., and
John J. Voorhees, M.D.,
Ann Arbor, MI

CME examination 292

Answers for CME examination 294
(Identification No. 887-101, January 1987
issue of the JOURNAL OF THE AMERICAN
ACADEMY OF DERMATOLOGY)

CME examination answer sheet 295

CLINICAL AND LABORATORY STUDIES

Isotretinoin treatment of pityriasis 297
rubra pilaris
Charles H. Dicken, M.D., *Rochester, MN*

Zinc deficiency in two full-term breast-fed 301
infants
Lynne J. Roberts, M.D.,
Constance F. Shadwick, M.D., and
Paul R. Bergstresser, M.D., *Dallas, TX*

Bullous pemphigoid controlled 305
by tetracycline
Carl R. Thornfeldt, M.D., and
Andrew W. Menkes, M.D.,
San Diego, CA

Syringoma presenting as milia 310
Stephen J. Friedman, Major, MC, USA,
and David F. Butler, Major, MC, USA,
El Paso, TX

Continued on page 7A

5A

February, Part 1, 1987

Bullous pemphigoid controlled by tetracycline

Carl R. Thornfeldt, M.D., and Andrew W. Menkes, M.D. *San Diego, CA*

Two men with nonscarring, persistent, localized bullous pemphigoid, whose eruption is completely controlled with daily doses of oral tetracycline, are described. A review of the literature on persistent, localized bullous pemphigoid is presented. The effects of tetracycline on leukocytes that may play a role in the response of these patients are discussed. (*J AM ACAD DERMATOL* 1987;16:305-10.)

Bullous pemphigoid is an autoimmune disease characterized by large, tense, subepidermal bullae. These lesions arise on urticarial plaques, erythematous macules, or normal-appearing skin. They commonly involve flexural areas, especially the groin and axillae.^{1,2} In contrast to pemphigus, Nikolsky's sign is absent. Nearly 80% of the individuals afflicted are at least 60 years old, and generally the severity of the disease increases as the age of onset increases. Bullous pemphigoid begins at a localized site and rarely remains localized throughout its course.³⁻⁵ On the basis of the clinical presentation, persistent, localized bullous pemphigoid is divided into scarring and nonscarring forms. Corticosteroids, systemic and/or topical, are usually employed for the treatment of all types of bullous pemphigoid, although in severe cases, immunosuppressive agents or sulfones are required.²⁻⁶ Recently erythromycin has been successfully used to control this disease, as has a combination of tetracycline and niacinamide.^{7,8}

CASE REPORTS

Case 1

A 66-year-old Filipino man with hypertension and angina complained of a pruritic eruption of 10 years' duration on the lower part of both legs, which was not associated with pustules, painful lymph nodes, or fever.

From the Division of Dermatology, University of California, San Diego, School of Medicine.

Accepted for publication July 17, 1986.

Reprint requests to: Dr. Carl Thornfeldt, 1021 S.W. 5th Ave., Ontario, OR 97914.

He had received nitroglycerin, isosorbide, and nifedipine for his cardiovascular illness.

Physical examination revealed a healthy-appearing Oriental man with lesions distributed symmetrically over both pretibial surfaces. The lesions consisted of multiple hyperpigmented macules, several tense, clear vesiculobullae on erythematous and nonerythematous skin, and a few brown-black crusts on erythematous skin (Fig. 1). There was no fever, inguinal adenopathy, or signs of lymphangitis. The white blood cell count, differential count, erythrocyte sedimentation rate, fasting blood sugar level, and urinalysis results were normal, and there were no antinuclear antibodies. Biopsy of a blister on normal-appearing skin showed a non-acantholytic, subepidermal bulla containing a few eosinophils. There was also a mild papillary dermal and perivascular infiltrate consisting of mononuclear cells and a few eosinophils (Fig. 2). Direct immunofluorescence was positive for IgG and C3 in a linear pattern along the basement membrane zone. No circulating antibodies were detected by immunofluorescence with guinea pig esophagus used as a substrate.

The eruption was refractory to topical therapy with betamethasone valerate and dipropionate, the latter with plastic occlusion. A therapeutic trial of oral tetracycline, 250 mg twice daily for 2 to 3 weeks, cleared all the bullae and inflammatory lesions. This therapy was discontinued on two occasions, and within 3 weeks the bullae and erythematous plaques recurred. Reinstitution of oral tetracycline on each occasion resulted in clinical remission for over a year on a regimen of only 250 mg of tetracycline daily.

Case 2

A 48-year-old Mexican American man with a seizure disorder was referred for a 5-year history of an inter-

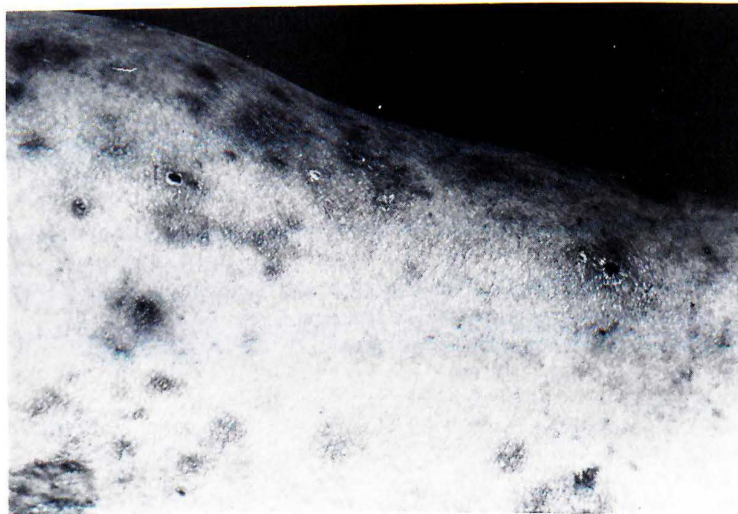

Fig. 1. Case 1. Several vesicles, crusts, and hyperpigmented macules on the pretibial area.

mittent pruritic, blistering eruption of the medial aspect of the left thigh. The eruption was not associated with other cutaneous lesions nor with systemic symptoms. It had been refractory to mid- and high-potency topical corticosteroids and topical and systemic antimycotic agents. The eruption also was refractory to short courses of diaminodiphenylsulfone and chloroquine. The patient had partial relief of itching and diminished blistering with 60 mg of prednisone daily for 2 weeks. He had initially received phenobarbital and phenytoin for his seizure disorder but had switched to carbamazepine shortly thereafter because of overt seizure activity.

Physical examination revealed an obese man with multiple tense bullae on erythematous plaques and on nonerythematous skin of the proximal medial portion of the left thigh and the left crural fold (Fig. 3). Multiple striae were present. There were no pustules, fever, or lymphadenopathy. Bacterial cultures from the blister fluid were negative. A Tzanck smear from the bulla base revealed no multinucleated giant cells, and a potassium hydroxide smear showed no hyphae. The white blood cell count, differential count, erythrocyte sedimentation rate, fasting blood sugar level, and urinalysis results were normal. There were no antinuclear antibodies. Biopsy of a bulla on an erythematous plaque showed a nonacantholytic, subepidermal bulla containing eosinophils. There was a dense, diffuse papillary dermal mixed infiltrate consisting predominantly of neutrophils, with many eosinophils and few mononuclear cells (Fig. 4). Direct immunofluorescence was positive for linear IgG and C3 along the basement mem-

brane zone. No circulating antibodies were detected by immunofluorescence.

Oral tetracycline, 500 mg twice daily, and prednisone, 60 mg in a single morning dose, produced complete resolution of the eruption in 3 weeks. Ten weeks after tapering off these two agents, the lesions recurred. Both this and a later episode completed cleared after 2 weeks of oral tetracycline, 500 mg three times daily. The patient has now been in clinical remission for 9 months on a regimen of 500 mg of tetracycline in a single daily dose.

DISCUSSION

Only fifty-eight cases of persistent, localized bullous pemphigoid have been documented in the English-language literature in the past 25 years, but the true incidence of this entity may be much greater. On initial evaluation of patients with bullous pemphigoid, 16.5% of patients in one large series had lesions localized to a single site. However, the lesions on only one fourth of them remained localized. On the other patients, the localized lesions eventually generalized, some even 14 years after the initial eruption.^{4,6,9-22} Lesions appearing first over areas of traumatized or preexisting skin disease or lesions distributed periumbilically are especially prone to generalization.³

Persistent, localized bullous pemphigoid is divided into Brunsting-Perry pemphigoid, which

Explore Litigation Insights

Docket Alarm provides insights to develop a more informed litigation strategy and the peace of mind of knowing you're on top of things.

Real-Time Litigation Alerts



Keep your litigation team up-to-date with **real-time alerts** and advanced team management tools built for the enterprise, all while greatly reducing PACER spend.

Our comprehensive service means we can handle Federal, State, and Administrative courts across the country.

Advanced Docket Research



With over 230 million records, Docket Alarm's cloud-native docket research platform finds what other services can't. Coverage includes Federal, State, plus PTAB, TTAB, ITC and NLRB decisions, all in one place.

Identify arguments that have been successful in the past with full text, pinpoint searching. Link to case law cited within any court document via Fastcase.

Analytics At Your Fingertips



Learn what happened the last time a particular judge, opposing counsel or company faced cases similar to yours.

Advanced out-of-the-box PTAB and TTAB analytics are always at your fingertips.

API

Docket Alarm offers a powerful API (application programming interface) to developers that want to integrate case filings into their apps.

LAW FIRMS

Build custom dashboards for your attorneys and clients with live data direct from the court.

Automate many repetitive legal tasks like conflict checks, document management, and marketing.

FINANCIAL INSTITUTIONS

Litigation and bankruptcy checks for companies and debtors.

E-DISCOVERY AND LEGAL VENDORS

Sync your system to PACER to automate legal marketing.