

archives of  
**Dermatology**

~~CLIPPING~~  
~~AWARENESS~~  
~~FILE~~

REC'D-MEDICAL LIBRARY  
RECEIVED  
DEC 02 1986  
SERIALS  
U OF MICH

**EDITORIALS**

- Adverse Reactions to Bovine Collagen Implants: Additional Evidence for Immune Response Gene Control of Collagen Reactivity in Humans** 643  
*D. E. Trentham*
- Concepts of Wart Regression** 644  
*M. E. Bender*

**SPLINTERS FROM THE BOARD**

- 1986—Dermatology at the Crossroads: Choices and Challenges** *I. M. Freedberg* 648

**ARTICLES**

- The Association of HLA and Immune Responses to Bovine Collagen Implants** 650  
*E. E. Vanderveen, J. P. McCoy, Jr, W. Schade, J. J. Kapur, T. Hamilton, C. Ragsdale, R. C. Grekin, N. A. Swanson*
- Plane Warts Under Spontaneous Regression: Immunopathologic Study on Cellular Constituents Leading to the Inflammatory Reaction** 655  
*K. Iwatsuki, H. Tagami, M. Takigawa, M. Yamada*
- Development of an Objective Comedogenicity Assay** 660  
*S. B. Tucker, S. A. Flannigan, M. Dunbar, Jr, R. B. Drotman*
- Methotrexate Pharmacokinetics in Psoriatic Patients Developing Hepatic Fibrosis** 666  
*S. K. Jones, G. W. Aherne, M. J. Campbell, J. E. White*
- The Treatment of Bullous Pemphigoid With Tetracycline and Niacinamide: A Preliminary Report** 670  
*M. A. Berk, A. L. Lorincz*
- Dermatologists in the Year 2000: Will Supply Exceed Demand?** 675  
*R. S. Stern*
- Localization of Peutz-Jeghers Macules to Psoriatic Plaques** 679  
*L. A. Banse-Kupin, M. C. Douglass*
- Sacral Hemangiomas and Multiple Congenital Abnormalities** 684  
*N. S. Goldberg, A. A. Hebert, N. B. Esterly*
- Pseudomonilethrix: An Artifact** 688  
*J. A. Zitelli*
- Sporotrichosis Masquerading as Pyoderma Gangrenosum** 691  
*E. M. Spiers, S. J. Hendrick, J. L. Jorizzo, A. R. Solomon*
- Giant *Mycobacterium fortuitum* Abscess Associated With Systemic Lupus Erythematosus** 695  
*S. J. Hendrick, J. L. Jorizzo, R. C. Newton*
- Aquarium-Borne *Mycobacterium marinum* Skin Infection: Report of a Case and Review of the Literature** 698  
*D. Huminer, S. D. Pitlik, C. Block, L. Kaufman, S. Amit, J. B. Rosenfeld*
- The Generalized Atrophic Benign Form of Junctional Epidermolysis Bullosa: Experience With Four Patients in the United States** 704  
*A. S. Paller, J.-D. Fine, S. Kaplan, R. W. Pearson*

**OFF-CENTER FOLD**

- Fever, Palpable Purpura, and a Positive Weil-Felix Reaction** 711  
*D. M. Siegel, R. G. Freeman*
- Shiny Amber Papules on the Face and Hands** 711  
*M. S. Stone, J. A. Tschen*
- A Case of Fungating Skin Tumors in a Young Man** 711  
*L. Barnes*

**Complete Contents, p 605**

Dr. Reddy's Laboratories, Ltd., et al.  
v.  
Galderma Laboratories, Inc.  
IPR2015-

# The Treatment of Bullous Pemphigoid With Tetracycline and Niacinamide

## A Preliminary Report

Mark Allan Berk, MD, FRCP(C), Allan L. Lorincz, MD

• Patients with moderate to severe bullous pemphigoid are usually treated with systemic corticosteroids. Four patients were treated with tetracycline hydrochloride and niacinamide because of the steroid-sparing anti-inflammatory properties of these agents. An excellent clinical response free of side effects was observed in all patients. The lesions recurred whenever treatment was discontinued. It is believed that these drugs suppress the complement-mediated inflammatory response at the basement membrane zone by suppressing neutrophil chemotaxis and mediators of the inflammatory response in this bullous disease.

(*Arch Dermatol* 1986;122:670-674)

Bullous pemphigoid (BP) is a major blistering disease most common in elderly patients. The almost universal finding of linear deposition of IgG and C3 at the basement membrane zone (BMZ) on direct immunofluorescence (DIF) staining<sup>1</sup> and the presence of anti-BMZ antibodies in more than two thirds<sup>2-4</sup> of patients with BP by indirect immunofluorescence (IIF) staining strongly support an autoimmune cause.

Effective treatment for BP in the recent past has included the use of oral<sup>5</sup> and topical adrenocorticosteroids; immunosuppressive drugs, such as azathioprine,<sup>6</sup> methotrexate,<sup>5</sup> and cyclophosphamide<sup>7</sup>; as well as sulfones.<sup>8</sup> Most recently, high-dose pulse methylprednisolone therapy<sup>9</sup> and plasma exchange<sup>10</sup> have been used in selected patients. The considerable morbidity caused by systemic adrenocorticosteroid

therapy given even for relatively short periods in elderly patients with other complicating medical problems often associated with BP<sup>11</sup> has necessitated the trial of less potentially hazardous drugs for the treatment of this bullous disease.

Herein, we describe four patients who had significant clinical improvement and then control of their disease with the oral combinations of tetracycline or erythromycin and niacinamide. Two patients' conditions were controlled following the administration of therapy with tetracycline and niacinamide alone. One patient was treated successfully with tetracycline or erythromycin and niacinamide, and one was able to suddenly discontinue dapsone therapy due to a complication.

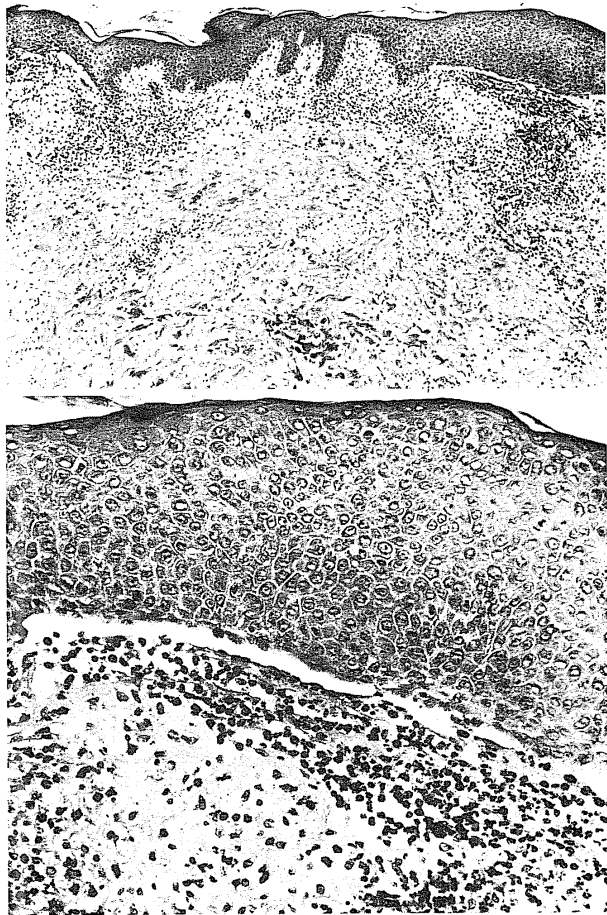
### REPORT OF CASES

**CASE 1.**—An 84-year-old man was sent to The University of Chicago Medical Center (UCMC) with a six-month history of a blistering skin rash. Tense, mildly pruritic blisters would erupt on the extensor surfaces of the arms and anterior aspects of the thighs and then would rupture, leaving denuded areas. He had a history of hypothyroidism and congestive heart failure. At the time of presentation, the patient was taking oral digoxin (0.25 mg) and oral levo-thyroxine (0.1 mg) daily. Therapy with various topical corticosteroid creams and ointments was ineffective. His family physician had administered intramuscular injections of triamcinolone acetonide on several occasions early in the eruption, with only temporary minimal improvement. On examination, the patient had mildly pruritic, large, tense bullae and erythematous plaques on the extensor surfaces of both arms and the anterior thighs as well as hyperpigmented and erythematous patches on the upper extremities and trunk. Several new blisters appeared daily. Nikolsky's sign was negative. Sections of a 3-mm punch biopsy specimen of a lesion stained with hematoxylin-eosin (Figure) showed a subepidermal blister containing fibrin and a modest number of eosinophils. The underlying dermis showed scattered infiltrates of lymphocytes and neutrophils as well as numerous eosinophils, consistent

Accepted for publication Jan 7, 1986.

From the Section of Dermatology, Department of Medicine, The University of Chicago, Pritzker School of Medicine.

Reprint requests to the Section of Dermatology, Department of Medicine, The University of Chicago, Pritzker School of Medicine, 5841 S Maryland Ave. Box 409, Chicago, IL 60637 (Dr Berk).



Low- (top) and high- (bottom) power magnifications showing focal acanthosis and subepidermal blisters containing eosinophils and fibrin. Numerous eosinophils and scattered infiltrates of lymphocytes and neutrophils in dermis are consistent with cell-rich bullous pemphigoid.

with cell-rich BP. Direct immunofluorescence studies of the biopsy specimen revealed linear deposition of IgG and C3 at the epidermal BMZ, also consistent with BP. Indirect immunofluorescence studies of a specimen of serum using monkey esophagus as substrate revealed anti-BMZ antibodies with a titer of 1:40. Therapy was initiated with niacinamide (500 mg orally three times a day) as well as a polymyxin-bacitracin ointment, which was applied twice daily to his lesions. Over the next few days, new blisters stopped appearing, erythematous plaques began to heal, and his pruritus resolved. Over the next two months, his lesions completely healed. Five months later, several tense bullae reappeared on the extensor surfaces of the arms. Increasing the dosage of oral niacinamide to 2,500 mg/day and adding 0.1% triamcinolone acetonide ointment twice daily did not improve his skin condition substantially. Tetracycline hydrochloride (1,500 mg daily in three divided doses) therapy was added. Once again, within two weeks, his skin condition had almost completely cleared. He was free of lesions six months later while still receiving oral niacinamide (2,500 mg/day) and tetracycline hydrochloride (1,500 mg/day in divided doses).

**CASE 2.**—An 80-year-old man was referred to UCMC with a one-month history of blisters on the upper arms and chest and erosions in the mouth. At the time of presentation, one or two new blisters were appearing daily. He had a four-year history of diabetes mellitus, which was controlled first by diet and then by hypoglycemic agents. The patient also had atherosclerotic heart disease and Paget's disease of the pelvic bones. He was taking oral digoxin (0.25 mg/day) and oral tolbutamide (1 g twice daily).

Physical examination revealed an obese elderly man with erythematous, mildly pruritic erosions and plaques on the malar area of the face. There were several erosions of the buccal mucosa and one on the lower right gingiva. Nonpruritic, intact, tense bullae were seen on the medial aspects of the upper arms. Laboratory studies revealed a random blood glucose level of 325 mg/dL (normal, 60 to 140 mg/dL). A skin biopsy specimen of a bulla revealed a subepidermal blister with a dermal infiltrate of eosinophils and polymorphonuclear cells, and DIF studies revealed linear deposition of IgG and C3 at the epidermal BMZ, confirming the clinical and histopathologic indications of BP; IIF studies on a specimen of serum using monkey esophagus as substrate revealed anti-BMZ antibodies in trace amounts. Therapy with oral niacinamide (500 mg three times daily) and oral tetracycline hydrochloride (250 mg four times daily) was begun. Over the next two months, there was significant improvement in his skin disease, with infrequent oral erosions only. The patient then decreased the oral tetracycline hydrochloride dosage to 750 mg/day; several new erosions appeared in the mouth within the first few days. The dosage was increased to 1,500 mg/day, and complete healing of the lesions ensued within a week. Over the next eight months, the patient decreased the medication to 500 mg of oral niacinamide and 250 mg of oral tetracycline hydrochloride twice daily. With this regimen, infrequent erosions occurred in the oral cavity. These would clear within a week's time with an increase in dosage to 500 mg of oral niacinamide twice daily and 1,000 to 1,500 mg/day of oral tetracycline hydrochloride. An endocrinology consultant initiated therapy with isophane insulin suspension (50 IU every morning) and regular insulin (10 IU every morning and every evening) subcutaneously for better control of his diabetes. Two years after presentation, the patient's condition is still under good control with 500 mg of oral niacinamide and 500 mg of oral tetracycline hydrochloride three times daily.

**CASE 3.**—An 80-year-old man, a patient in a chronic-care facility, presented to UCMC with a three-week history of a moderately pruritic blistering rash on the right upper arm, anterior aspect of the chest, abdomen, and upper back and in the axillae. He had tried topical corticosteroid ointments, antifungal creams, and diphenhydramine hydrochloride without relief. Approximately 20 years prior to presentation, he had had a massive right cerebrovascular accident, resulting in left hemiplegia. A childhood accident had necessitated a left below-the-knee amputation. The patient had had bilateral cataract extractions in the recent past, but he had no history of diabetes. Two years prior to this skin eruption, he had had a much milder but similar rash, which cleared following treatment with topical corticosteroid ointment.

Physical examination revealed tense bullae on erythematous, pruritic, indurated, excoriated plaques on the trunk, in the axillae, and on the right upper arm. There were no mucous membrane lesions, and Nikolsky's sign was negative. Representative sections of a skin biopsy specimen stained with hematoxylin-eosin showed modest acanthosis

and spongiosis in the epidermis. Subepidermal separation with accumulations of neutrophils and a few eosinophils and a moderately dense mixed perivascular infiltrate of lymphocytes, histiocytes, neutrophils, and eosinophils were also seen. Between the perivascular infiltrates, numerous eosinophils were seen. Direct immunofluorescence studies of a skin biopsy specimen showed linear deposits of IgG and C3 along the BMZ. Indirect immunofluorescence studies of a serum specimen using both monkey esophagus and normal human skin as substrates revealed anti-BMZ antibodies with a titer of 1:1. The histopathologic and immunopathologic diagnosis of cell-rich BP was made.

Although the patient received one oral 60-mg dose of prednisone, because of his infirm state, it was decided to treat him with the steroid-sparing regimen of 500 mg of oral tetracycline hydrochloride and 500 mg of oral niacinamide three times daily. For approximately two weeks, 0.1% triamcinolone acetonide ointment also was applied to lesional skin. New lesions stopped appearing after two days of treatment, and his condition totally cleared four weeks after presentation. Because of poor patient compliance over the next 15 months, he had three recurrences of his BP. Restarting oral tetracycline and niacinamide therapy caused clearing on two occasions. At the time of one recurrence, the patient was given 400 mg of oral erythromycin ethylsuccinate three times daily, resulting in complete remission. At the time of the last follow-up visit 18 months after presentation the patient was well while receiving 500 mg of oral tetracycline hydrochloride and 500 mg of oral niacinamide three times daily.

**CASE 4.**—A 68-year-old woman was referred to UCMC for treatment of a bullous eruption. She had a three-month history of mildly pruritic blisters on the arms, legs, thighs, buttocks, and anterior aspect of the chest. These would leave intensely pruritic erosions that were unresponsive to treatment with topical potent corticosteroid ointments. Therapy with 500 mg of oral tetracycline hydrochloride three times daily was begun, with, by history, a modest improvement. Her sister had systemic lupus erythematosus, but there was no history of diabetes. Physical examination revealed diffuse erythematous plaques on the extensor surfaces of the arms, anterior aspects of the chest and thighs, and lower legs. Several tense bullae were present on the lower legs and chest. At the time of referral, the hemoglobin level was 13.0 g/dL (normal, 11.5 to 15 g/dL), hematocrit was 38.3% (normal, 37% to 50%); and results of a 17-channel blood chemistry panel were normal, as were those of a glucose-6-phosphate dehydrogenase screen. Findings of a biopsy specimen examination of a bulla were consistent with BP, and DIF studies revealed deposition of IgG and C3 at the epidermal BMZ, also consistent with BP. Indirect immunofluorescence studies of a specimen of serum using monkey esophagus as substrate revealed anti-BMZ antibodies with a titer of 1:320. Therapy with oral niacinamide (500 mg four times daily), oral tetracycline hydrochloride (500 mg four times daily), and oral dapsone (50 and then 150 mg/day) was begun. Over the next two weeks, pruritus was relieved, with only a few occasional blisters after two months of therapy. Niacinamide therapy was discontinued. Complete blood cell counts, blood film results, and liver function test results were well within acceptable limits. Two months after beginning dapsone therapy, the hemoglobin level fell to 8.6 g/dL, hematocrit was 25.7%, and there was a modest increase in aspartate aminotransferase, alanine aminotransferase, and alkaline phosphatase levels. Dapsone therapy was discontinued. Over the next few days, a flare

of her disease, consisting of tense blisters on erythematous plaques on the trunk, was noted. These blisters rapidly disappeared over the next week with the addition of 500 mg of oral niacinamide four times daily. Over the next three months, her blood cell counts and liver function test results were normal. Eighteen months later, her skin remains clear while she is receiving 1,250 mg of oral tetracycline hydrochloride daily.

#### COMMENT

Autoantibodies specifically complexing with the BP antigen, a protein with a molecular weight of 220,000 in the lamina lucida layer of the BMZ,<sup>12</sup> are believed to cause activation of both the classic and alternative complement pathways.<sup>13</sup> Direct immunofluorescence staining with CIQ, C4, C3, C5, C3PA, and properdin<sup>14,15</sup> has been shown in the BMZ. Chemotactic factors liberated by complement activation and mast cell degranulation are the major causes of the characteristic leukocytic infiltration of neutrophils and eosinophils.

If human skin is incubated with BP blister fluid, there is cleavage at the BMZ, even without supplementary complement and neutrophils.<sup>16,17</sup> Baba et al<sup>18</sup> noted the presence of an eosinophilic chemotactic factor (ECF) in BP blister fluid. Czarnetzki et al<sup>19</sup> demonstrated ECF in the sera of four patients with BP. Thus, the activation of complement by the complement-activating antigen-antibody complexes at the BMZ produces anaphylatoxins and chemotactic factors that attract polymorphonuclear leukocytes and eosinophils and may also degranulate mast cells to subsequently cause a still further infiltration of inflammatory cells. The liberation of proteases then causes direct damage to the epidermal BMZ and subepidermal blister formation.

Niacinamide is a physiologic nutrient that has proved to be relatively nontoxic even at very high pharmacologic doses. The acidic form of this B vitamin was first found to be useful in the treatment of bullous disease with the early clinical observation of the efficacy of niacin in dermatitis herpetiformis, if given in adequate doses.<sup>20,21</sup>

Niacinamide has been shown to block antigen IgE-induced histamine release both in vitro and in vivo.<sup>22</sup> It has been shown to prevent degranulation of mast cells in sensitized guinea pig tissues.<sup>23</sup> Blister fluid from patients with BP contains high levels of histamine, IgE,<sup>18</sup> prekallikrein activator, Factor XII cleaver,<sup>24</sup> and various enzymes believed to be involved in the inflammatory process. Niacinamide may work partly by stabilizing the mast cell, prohibiting the release of ECF and other mediators of inflammation by anaphylatoxins produced by complement activation.

The release of proteases from leukocytes is decreased when leukocytes are incubated in vitro with pharmacologic doses of agents that specifically increase adenosine 3',5'-cyclic phosphate.<sup>25</sup> These agents have a stabilizing effect on leukocytes. Niacinamide has been shown to be a potent inhibitor of adenosine 3',5'-cyclic phosphate phosphodiester-

ase in vitro in rat livers.<sup>26</sup> Moreover, pyridoxal phosphate was shown by Korchak et al<sup>27</sup> to inhibit lysosomal enzyme secretion in human leukocytes by the inhibition of fusion of lysosomes with cellular plasma membranes, but it did not interfere with phagocytosis. Niacinamide, with its basic similar pyridine ring structure, may have the same effect.

Prolonged administration of daily doses of niacinamide in excess of 3 g on one occasion has been reported to be hepatotoxic.<sup>28</sup> Nicotinic acid (niacin) has, in high doses, produced flushing, acanthosis nigricans,<sup>29</sup> and ichthyosiform skin changes. These side effects, in the experience at UCMC, have not been seen with niacinamide, even at doses of 2,500 mg/day for many months.

Tetracycline causes marked suppression of leukocyte chemotaxis in vitro<sup>30</sup> and in vivo at therapeutic serum concentrations. Esterly et al<sup>31</sup> postulated that tetracycline hydrochloride and some other antimicrobials might suppress inflammatory skin disease by this action. Evidence for this was found with the observation that neutrophils of patients with inflammatory acne vulgaris have heightened random migration and chemotactic response to zymosan-activated serum chemotactic factor. Moreover, polymorphonuclear leukocytes from patients with acne who are treated with oral tetracycline show significant suppression of both random migration and chemotaxis, with the greatest suppression at a dosage of 1 g/day.<sup>32</sup> Tetracycline may work in a similar way as an anti-inflammatory agent in the treatment of various other inflammatory diseases. A synergistic role along with niacinamide has already been shown in the treatment of erythema elevatum diutinum, another disease in which neutrophil chemotaxis is believed to be excessive.<sup>33,34</sup>

Erythromycin has recently been used as an anti-inflammatory drug.<sup>35</sup> Plewig and Schopf,<sup>36</sup> in experimentally induced potassium iodide pustular dermatitis, found that erythromycin and tetracycline hydrochloride, administered both topically and systemically, produced marked improvement in the pustular erythematous eruption. The absence of a microbial element in the cause of these lesions suggested that the improvement was related to some anti-inflammatory property of the drugs and not to their antibacterial actions. Erythromycin is actively transported and then concentrated in polymorphonuclear leukocytes.<sup>37</sup> It is postulated that the anti-inflammatory properties of erythromycin are very similar to those of tetracycline hydrochloride. This,

presumably, is why it is effective in the treatment of BP.

Various alternate treatment modalities have been suggested for patients with BP. The time-honored regimen of oral steroid therapy has well-recognized deleterious side effects. Bullous pemphigoid is a disease that primarily affects the elderly, many of whom have associated multisystem disease. Certainly, any treatment that would be steroid sparing would be an excellent choice either alone, in combination with other steroid sparing agents, or together with oral prednisone in the treatment of this potentially serious disease.

Oral prednisone therapy and its problems were avoided or minimized in treating the patients described herein. The first patient's condition was controlled with niacinamide therapy alone for several months, after topical steroid therapy had failed. A flare of his disease necessitated the addition of tetracycline hydrochloride in a pharmacologically effective anti-inflammatory dose along with topical steroids to his treatment regimen. Patient 2 had insulin-dependent diabetes mellitus and managed to avoid systemic steroid therapy with the combination of tetracycline hydrochloride and niacinamide. Patient 3 was in a chronic-care facility not capable of caring for an infirm patient receiving steroid therapy. Steroid-sparing anti-inflammatory medication controlled his BP while he was compliant with the medication. Patient 4 had a hemolytic reaction to therapy with sulfones and was spared an imminent flare of her disease by the sudden discontinuation of dapsone therapy with the addition of niacinamide therapy.

We suggest that a trial of an anti-inflammatory antibiotic and niacinamide be considered in patients with BP using tetracycline hydrochloride or erythromycin in dosages of 1,000 to 2,500 mg/day concomitantly with niacinamide in dosages of 1,500 to 2,500 mg/day. If this regimen alone is insufficient, an anti-inflammatory antibiotic and niacinamide would then be given in combination with other drugs, such as dapsone or steroids, to minimize dosage requirements of these other effective but more hazardous medicines, thereby decreasing the possibility of harmful side effects. If complete remission occurs while the patient is undergoing treatment with the antibiotic and niacinamide, after six months of therapy, a trial of gradual drug withdrawal would be appropriate.

## References

1. Jordon RW, Trifishauser CT, Schroeter AL: Direct immunofluorescent studies of pemphigus and bullous pemphigoid. *Arch Dermatol* 1971;103:486-491.
2. Tuffanelli DL: Cutaneous immunopathology: Recent observations. *J Invest Dermatol* 1975;65:143-153.
3. Person JR, Rogers RS III: Bullous and cicatricial pemphigoid: Clinical, histopathologic, and immunopathologic correlations. *Mayo Clin Proc* 1977;52:54-66.
4. Ahmed AR, Maize JC, Provost TT: Bullous pemphigoid: Clinical and immunologic follow-up after successful therapy. *Arch*

*Dermatol* 1977;113:1043-1046.

5. Lever WF: Pemphigus and pemphigoid: A review of the advances made since 1964. *J Am Acad Dermatol* 1979;1:2-31.

6. Greaves MW, Burton JL, Marks J, et al: Azathioprine in treatment of bullous pemphigoid. *Br Med J* 1971;1:144-145.

7. Krain LS, Landau JW, Newcomer VO: Cyclophosphamide in the treatment of pemphigus vulgaris and bullous pemphigoid. *Arch Dermatol* 1972;106:657-661.

8. Person JR, Rogers RS III: Bullous pemphigoid responding to sulfapyridine and the sulfones. *Arch Dermatol* 1977;113:610-615.

# Explore Litigation Insights

Docket Alarm provides insights to develop a more informed litigation strategy and the peace of mind of knowing you're on top of things.

## Real-Time Litigation Alerts



Keep your litigation team up-to-date with **real-time alerts** and advanced team management tools built for the enterprise, all while greatly reducing PACER spend.

Our comprehensive service means we can handle Federal, State, and Administrative courts across the country.

## Advanced Docket Research



With over 230 million records, Docket Alarm's cloud-native docket research platform finds what other services can't. Coverage includes Federal, State, plus PTAB, TTAB, ITC and NLRB decisions, all in one place.

Identify arguments that have been successful in the past with full text, pinpoint searching. Link to case law cited within any court document via Fastcase.

## Analytics At Your Fingertips



Learn what happened the last time a particular judge, opposing counsel or company faced cases similar to yours.

Advanced out-of-the-box PTAB and TTAB analytics are always at your fingertips.

## API

Docket Alarm offers a powerful API (application programming interface) to developers that want to integrate case filings into their apps.

## LAW FIRMS

Build custom dashboards for your attorneys and clients with live data direct from the court.

Automate many repetitive legal tasks like conflict checks, document management, and marketing.

## FINANCIAL INSTITUTIONS

Litigation and bankruptcy checks for companies and debtors.

## E-DISCOVERY AND LEGAL VENDORS

Sync your system to PACER to automate legal marketing.