

Dry Eye, Blepharitis and Chronic Eye Irritation: Divide and Conquer

Jeffery P. Gilbard, MD

Patients with chronic eye irritation are probably some of the most time-consuming and vexing for the doctor. The good news is that a good history by an ophthalmic assistant who knows what to ask can frequently make the diagnosis before the doctor steps into the room. In addition, there are now treatments that really work.

Most patients presenting to the office with chronic eye irritation will ultimately turn out to have either dry eye or blepharitis. Dry eye is caused by any condition that decreases tear production or increases tear evaporation sufficiently to result in a loss of water from the tear film and an increase in tear film osmolarity. Tear production can be decreased by lacrimal gland disease, as seen in Sjogren's syndrome, or by any condition that decreases corneal

sensation. Included among the more common causes for decreased corneal sensation are laser in situ keratomileusis (LASIK) and photorefractive keratectomy (PRK) procedures that interrupt or ablate corneal nerves, and long-term hard contact lens wear.

Tear evaporation can be increased in the presence of large palpebral fissure

are the mucous-producing cells on the eye surface that provide the natural lubrication for the eye; corneal glycogen is the energy source for corneal healing.

Before discussing the patient history it is important to understand that blepharitis can be divided into two major types: anterior and posterior. Anterior blepharitis is less common and is characterized by a dandruff-like process that occurs at the base of the lashes. This is different from the purulent drainage and crusting seen on the eyelashes in the still more uncommon type of anterior blepharitis caused by *Staphylococcus aureus*.

Posterior blepharitis is the most frequent type of blepharitis and involves an inflammatory process centered around the meibomian glands; this inflammatory process can spread throughout the lid margin and spill over to involve the ocular surface as well. Ultimately inflammation involving the meibomian gland leads to fibrosis, causing increasing disorganization and dysfunction of the meibomian glands.

The Patient History

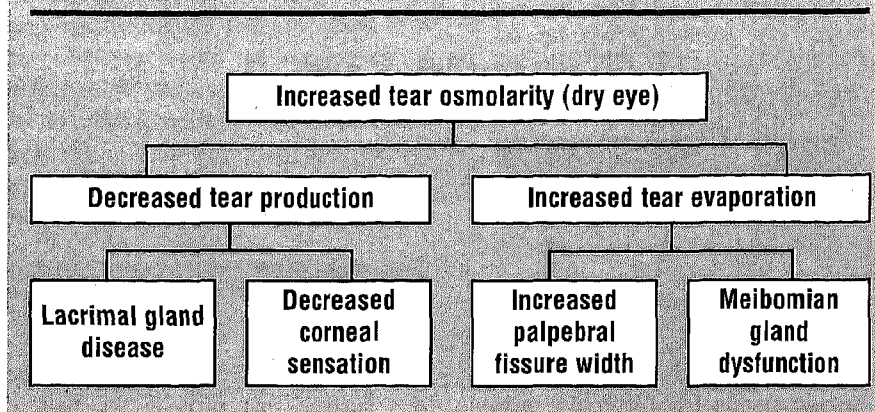
A good history is one of the most powerful tools available to reach a diagnosis in a patient who complains of chronic eye irritation. There are seven questions that need to be answered to extract the most information from a patient.

Before discussing the patient history, it is important to understand that blepharitis can be divided into two major types: anterior and posterior.

widths (i.e., over 10 mm) or from meibomian gland dysfunction resulting from posterior blepharitis or meibomitis (Figure 1). Increased tear film osmolarity, no matter what the cause, osmotically dehydrates the eye surface, increases epithelial cell desquamation, decreases conjunctival goblet cell density, decreases corneal glycogen levels, and ultimately results in the loss of cell surface glycoproteins necessary for tear film stability. Conjunctival goblet cells

From the Schepens Eye Research Institute, Boston, Massachusetts; the Department of Ophthalmology, Harvard Medical School, Boston, Massachusetts; The Cornea & Vision Correction Center, Woburn, Massachusetts; and Advanced Vision Research, Inc., Woburn, Massachusetts. Portions of this article have been adapted from Gilbard JP: Dry Eye Disorders. In Albert DM, Jakobiec PA eds. Principles and Practice of Ophthalmology. Philadelphia: W.B. Saunders Company, 1994:257-276. Address correspondence to Jeffrey P. Gilbard, MD, 7 Alfred Street, Suite 330, Woburn, Massachusetts 01801. Dr. Gilbard is Founder and CEO of Advanced Vision Research, Inc., (800) 979-8327.

Figure 1. Mechanisms for Increased Tear Osmolarity



1. *Character.* What does the irritation feel like? Is it a sandy-gritty feeling, burning, foreign body sensation, or increased “awareness” of the eyes? Do the eyes itch?

2. *Location.* Where is the irritation located? Is it on the surface of the eye, in the eye, on the lid margin, or on the skin?

3. *Diurnal variation.* Are the symptoms worse at any particular time of day? Patients typically have difficulty with this question. It helps to ask patients what symptoms are like upon awakening, at the breakfast table, at lunch and after dinner in the evening. Are they worse on awakening or late in the day? Are there two symptoms peaks—on awakening in the morning and then late in the day?

4. *Onset.* Did the symptoms start suddenly, or did they develop gradually? Do symptoms occur in clearly delineated episodes or is this a continuous problem?

5. *Duration.* How long have the symptoms been present?

6. *Aggravating factors.* Is there anything that makes the symptoms worse—wind, smoke, low humidity (i.e., airplane cabins), reading, watching TV, contact lens wear, artificial tears?

7. *Alleviating factors.* Is there anything that makes the symptoms better—

hot compresses, eye closure, high humidity, artificial tears?

Once this information is collected the examiner will have a constellation of symptoms that will match those associated with one or more of the conditions detailed below.

Dry Eye

Patients with dry eye most commonly complain of a sandy-gritty feeling in their eyes that becomes worse as the day progresses. This is because at night the closed eyelids form a watertight barrier completely blocking evaporation, and the eye surface has a chance to recover. With eye opening, evaporation begins, and as the day progresses evaporation pulls further and further ahead of tear production. For this reason, the symptoms increase as the day proceeds.

The symptoms are insidious in onset, and initially patients may only complain of an increased awareness of their eyes. Late in the disease symptoms may be present throughout the day, but usually the diurnal variation persists. As the cornea becomes involved, patients develop sensitivity to light.

Meibomitis and Meibomian Gland Dysfunction

Patients with meibomitis also com-

plain of chronic sandy-gritty irritation (or burning) in their eyes, but in these patients the symptoms are worse upon awakening in the morning. This is because at night the inflamed eyelids are up against the cornea, tear secretion decreases, and inflammatory mediators have all night to act on the surface of the eye.

Since this is an inflammatory condition, patients also frequently complain of redness of their eyes in the morning. The symptoms are insidious in onset. Some patients may have discovered that hot compresses provide some relief.

With time, meibomian gland inflammation causes gland damage and meibomian gland dysfunction develops. Tear film evaporation then increases, and these patients develop a second peak in their symptoms late in the day. Finally, after several years, the meibomian gland inflammation resolves as gland architecture is destroyed and heals with fibrosis. These patients will then experience a resolution of their early morning symptoms but an intensification of their symptoms late in the day.

Occasionally patients with meibomian gland dysfunction and orifice closure report that it feels as if their eyes are tearing. It is important to note that these patients do not complain of tear overflow. How does closure of the meibomian gland orifice and loss of the tear film lipid layer cause these symptoms? The lipid layer, in addition to decreasing tear film evaporation, also decreases the surface tension of the tear film, thereby holding the tear film tight to the globe. With loss of this lipid layer the tears splash around more, and the aqueous layer from the tear film can begin to touch the mucocutaneous junction of the lid margin, especially with concomitant loss of lipid from the lid margin as well. When this occurs it feels to the patient as if their eye is tearing. (If tear overflow occurs, the examiner will need to consider the diagnosis of nasolacrimal drainage dysfunction.)

Anterior Blepharitis

These patients have symptoms at the anterior lid margin. Specifically, patients complain of crusting or irritation at the base of the lashes. The adjacent lid skin may be involved. Later in the disease there can be loss of lashes. There is no diurnal variation, and the onset is usually insidious.

Large Palpebral Fissure Width

The symptoms in these patients are nearly identical with those of patients with lacrimal gland disease. Sandy-gritty feelings and burning become worse as the day progresses. Because lacrimal gland function is normal in these cases, patients can notice excess tearing.

Decreased Corneal Sensation

A history of fifth nerve trauma or surgery may be present. Recently, refractive corneal surgery has become a common cause of decreased corneal sensation. It is important to recognize, however, that there are many other causes for decreased corneal sensation, any one of which may play a role in the dry eye disease of a specific patient. Remember that any condition that decreases corneal sensation decreases tear secretion and may increase tear film osmolarity.

One of the less frequently recognized syndromes is the dry eye condition, associated with elevated tear film osmolarity, that may develop after long-term contact lens wear, particularly long-term hard contact lens wear.^{1,2} Contact lens wear decreases corneal sensation, and the effect is more pronounced with hard contact lenses and extended wear soft contact lenses.^{3,4} The effect is cumulative, and it is not uncommon to see patients who have worn hard lenses for longer than 15 years develop lens intolerance requiring discontinuation of lens wear. Many of these patients complain of dryness

and sandy-gritty feelings in their eyes that become worse as the day goes on even in the absence of contact lens wear. For this reason it is important to ask about contact lens wear in patients who complain of eye irritation.

Once the contact lens history is positive, and if contact lens wear continues, it is important to determine whether

Ocular irritation due at least in part to eye drop use should be suspected in all patients using traditional artificial tears more than 4 times a day. Both preserved and nonpreserved solutions can be responsible.

there are any features of the contact lens cleaning and sterilization system (i.e., preservatives) or contact lens fit that may be contributing to ocular irritation.

Medicameneosa

Ocular irritation due at least in part to eye drop use should be suspected in all patients using traditional artificial tears more than four times a day. These patients generally give a history of regular and frequently escalating eye drop use. Both preserved and nonpreserved solutions can be responsible, although there is now one commercially available preservative-free solution that appears to be free of this side effect.

In these cases, complaints of stinging with eye drop use should raise suspicions. Patients with medicamentosa characteristically are unable to describe a diurnal pattern to their symptoms—symptoms are equivalent

throughout the day. This is because the damage is promoted by continued overuse of topical medications, even though use of these medications may temporarily mask symptoms by increasing the lubrication of the ocular surface.

Lacrimal Drainage Obstruction

The most likely basis for symptoms of tearing and tear overflow is lacrimal drainage obstruction. Some patients may complain of irritation of the skin at the lateral canthus rather than frank tearing. The skin here can become "chapped" from repeated exposure to tear fluid. Symptoms from lacrimal drainage obstruction are insidious in onset, and are usually exacerbated by exposure to wind and environmental irritants.

Allergic Conjunctivitis

Patients with allergic conjunctivitis complain of ocular itching. They may also complain of increased mucus production by the eye. The onset is commonly seasonal and may be associated with exacerbation of hay fever, asthma, or eczema.

Nocturnal Lagophthalmos

These patients commonly complain of burning in the eyes that is worse on awakening. There is frequently a history of previous lid surgery or thyroid eye disease.

Superior Limbic Keratoconjunctivitis Sicca

Patients with superior limbic keratoconjunctivitis (SLK) complain of burning and irritation and develop symptoms and remissions somewhat abruptly. A diurnal pattern to the symptoms is not usually evident. The factors initiating the development of exacerbations and remissions are not known.

Episodes may last from months to years, and remissions may last for

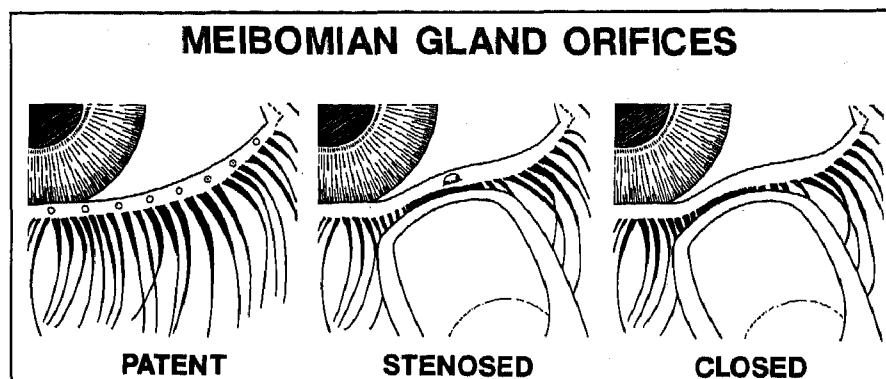


Figure 2. Chronic meibomitis lead to the development of meibomian gland dysfunction. As the meibomian gland dysfunction progresses, the meibomian gland orifice goes from patent, to stenosed, to closed.

weeks or may be permanent. Vision is not affected. Females are affected more frequently than males, and it is common to see a history of thyroid dysfunction.

Superficial Punctate Keratitis (Thygeson's)

Thygeson's superficial punctate keratitis is characterized by the insidious onset of photophobia, irritation, and decreased vision. The course of the disease is episodic in nature and lasts about 2 to 3 years. The cornea will show elevated punctate staining with fluorescein.

Dry Eyelid Skin

Some patients will say their "eyes" feel dry, but when questioned carefully reveal that they are referring to their eyelid skin. This common ambiguity underlines the need to determine the location of the symptoms. Frequently these patients will report the daily use of soap on the skin around their eyes.

Tarsal Foreign Body

Patients with a chronic foreign body sensation may have a tarsal foreign body. Symptoms are frequently monocular. In addition to exogenous material, a meibomian gland-derived conjunctival concretion (or concretions) can

form the basis for symptoms that remain enigmatic for years.

Mucus Fishing Syndrome

Some patients with ocular irritation develop the practice of reaching into their conjunctival cul-de-sac with their fingers and "fishing" out the mucus strand that they find there. These patients complain of eye irritation and increased mucus production by the eye. Conjunctival trauma induces an additional increase in mucus production and a vicious circle follows. Traumatized areas stain with rose Bengal, and the condition resolves once patient behavior is altered.⁹

Blepharospasm

Patients with primary blepharospasm may complain of a "tired feeling" in the eyes that is actually their interpretation or description of their difficulty keeping their eyes open. On careful questioning it becomes apparent that there is actually no eye irritation, but rather an involuntary closure of the eyes or an inability to keep their eyes open. Driving, reading and exposure to sunlight may exacerbate these symptoms. Since dry eye symptoms are commonly exacerbated by the same factors, it is very important to keep this frequently missed diagnosis in mind.

In patients with secondary blepharospasm there is underlying chronic eye irritation. Failure of the patient to respond to dry eye treatment may highlight the presence of this second condition.

Nonspecific Ocular Irritation

Not all ocular irritation is due to eye disease. The eye may be normal, and there may be environmental irritants, such as smoke and chemicals, responsible for symptoms.

Normal Eyes with Hypochondriasis

This is a relatively uncommon problem. Usually ocular irritation is due to one or more of the entities previously mentioned. Nevertheless, it is important to recognize patients without organic disease, and sometimes a careful history, which in turn fails to mesh with the examination, can provide the first clue.

The Examination

The two most common causes for chronic eye irritation are dry eye and meibomitis. The dry eye diagnosis can usually be made from the history, and the examination permits a determination of the cause or causes of dry eye in the patient. Signs of meibomitis can be very subtle and it helps to know exactly what the earliest signs are. The key elements in the examination of these two groups of patients are detailed below.

Palpebral fissure width. Tear film evaporation is directly proportional to the distance between the upper lid and the lower lid. With the patient looking directly at the examiner's open eye, measure the distance between the upper lid and the lower lid.

Once palpebral fissure width measures 10 mm or more, it becomes a significant factor in increasing the evaporative stress on the tear film.

Meibomian gland orifice. As meibomian gland function declines the mei-

bomian gland orifice goes from patent to stenosed to closed (Figure 2). Patent orifices are visible on the lid margin. Stenosed orifices are not visible but when gentle pressure is applied to the lid, droplets of oil appear on the lid margin. Closed orifices also are not visible but here, when gentle pressure is applied to the lid, no oil appears on the margin.

Lid margin. The normal lid margin is free of visible blood vessels. The earliest change seen with meibomitis is the appearance of telangiectatic blood vessels on the lid margin.

Tear volume and quality. The best way to examine the tear film is with fluorescein—not the drop from a bottle but with a wetted fluorescein strip. The problem with the drop from a bottle is that it replaces the tear film so the examiner is examining the drop rather than the tear film. Instead, take a fluorescein strip, wet it with a drop of sterile saline or irrigating solution, shake off the excess, pull the lower lid down, and paint the strip along the inferior tarsal conjunctiva.

In cases where tear volume is decreased the fluorescein will not fluoresce under the cobalt blue light of the slit lamp, but instead remain dark. As tear volume decreases further, the tear film will assume a more viscous appearance—as the upper lid rises following a blink, the tear film, rather than snapping up quickly with it, will rise more slowly. Ultimately, patients with decreased volume develop debris in the tear film as well.

In patients with meibomian gland dysfunction the tear film assumes a watery appearance due to a loss of the lipid layer. It will be apparent in these cases that the tear film is not lying tight to the globe.

Ocular surface staining. In the presence of dry eye alone, whether the dye used is fluorescein, lissamine green or rose Bengal, the conjunctiva

always stains more than the cornea. With posterior blepharitis alone, if there is any staining, the cornea always stains at least as much as the conjunctiva. In both early dry eye and mild blepharitis, there may be no ocular surface staining at all.

Corneal sensation. In patients with a history of contact lens wear, corneal surgery, Trigeminal nerve damage, herpes simplex or zoster, or diabetes, and with dry eye symptoms as well, it makes sense to test corneal sensation. This can be done easily with a cotton wisp. With experience the range of normal is easily appreciated.

The history is the most sensitive indicator of dry eye, and these elements just detailed will enable the

The two most common causes for chronic eye irritation are dry eye and meibomitis.

The dry eye diagnosis can usually be made from the history.

examiner to determine the cause of the dry eye symptoms. In the case of other causes for eye irritation, the history together with the careful examination of these elements, will narrow the differential diagnosis and enable a definitive diagnosis.

Dry Eye Treatment

It has been commonly taught that dry eye treatment begins with lubricating eye drops, also known as artificial tears. Attempting to treat dry eye patients with lubricant solutions is frequently a frustrating experience. Dissatisfaction with the results of treat-

ment has been attributed to the effect of preservatives or the short retention time of these drops in the eye. The toxicity of preservatives has been well documented.

Until recently, the efficacy of traditional artificial tear solutions has been limited by an additional important mechanism. In order to understand this additional mechanism, it is necessary to review what is known about ophthalmic solutions and the electrolyte requirements of the surface of the eye.

In 1960, Merrill and coworkers reported that 0.9% (isotonic) sodium chloride solution was toxic to conjunctival epithelium in tissue culture. Solutions that had a more complete ionic composition did not show the same toxicity.¹³ Nine years later, in 1969, Sussman and Friedman showed that frequent instillation of 0.9% sodium chloride solution in normal rabbit eyes led to eye redness and photophobia and eventually to corneal epithelial breakdown.⁸

This work was largely ignored until 1985, when Bachman and Wilson studied desquamation from rabbit corneas. They found that corneal desquamation, or peeling, was increased with exposure to 0.9% sodium chloride solution in comparison to a solution also containing potassium, bicarbonate, calcium, magnesium, and phosphate.¹⁴ These data were later corroborated with morphologic studies.¹⁵ In 1986, Fullard and Wilson demonstrated increased desquamation with a saline solution in vivo in human corneas using clinically relevant 30-second exposure times.¹⁶

Electrolyte Balance Crucial

What emerges from this work is that the cornea and conjunctiva have electrolyte requirements that are not met by solutions containing only sodium and chloride. Ultimately it was shown that the electrolyte requirements of the sur-

Explore Litigation Insights

Docket Alarm provides insights to develop a more informed litigation strategy and the peace of mind of knowing you're on top of things.

Real-Time Litigation Alerts



Keep your litigation team up-to-date with **real-time alerts** and advanced team management tools built for the enterprise, all while greatly reducing PACER spend.

Our comprehensive service means we can handle Federal, State, and Administrative courts across the country.

Advanced Docket Research



With over 230 million records, Docket Alarm's cloud-native docket research platform finds what other services can't. Coverage includes Federal, State, plus PTAB, TTAB, ITC and NLRB decisions, all in one place.

Identify arguments that have been successful in the past with full text, pinpoint searching. Link to case law cited within any court document via Fastcase.

Analytics At Your Fingertips



Learn what happened the last time a particular judge, opposing counsel or company faced cases similar to yours.

Advanced out-of-the-box PTAB and TTAB analytics are always at your fingertips.

API

Docket Alarm offers a powerful API (application programming interface) to developers that want to integrate case filings into their apps.

LAW FIRMS

Build custom dashboards for your attorneys and clients with live data direct from the court.

Automate many repetitive legal tasks like conflict checks, document management, and marketing.

FINANCIAL INSTITUTIONS

Litigation and bankruptcy checks for companies and debtors.

E-DISCOVERY AND LEGAL VENDORS

Sync your system to PACER to automate legal marketing.