

REVIEW

Dry eye: an update on clinical diagnosis, management and promising new treatments

Julie M Albietz BAppSc(Optom) (Hons)
PhD
School of Optometry, Queensland
University of Technology

Accepted for publication: 20 December
2000

Dry eye conditions are prevalent with one in four to five patients presenting to eye care practitioners having dry eye signs and/or symptoms. An intimate relationship exists between the ocular surface and the tear film. The cycle of tear film instability and ocular surface damage characteristic of dry eye conditions suggests that dry eye represents a dysfunction of an integrated ocular surface-lacrimal gland unit. Therefore, dry eye is a multifactorial condition and an approach based on clinical subtypes is required for diagnosis and management. There is increasing evidence that inflammation is a contributing and exacerbating factor in dry eye conditions and anti-inflammatory or immunomodulatory therapy for chronic dry eye conditions may facilitate ocular surface healing. Other promising new treatments for dry eye include new generation artificial tear polymers and preservative systems, secretagogues, topical androgen supplements and surgical techniques for ocular surface reconstruction.
(*Clin Exp Optom* 2001; 84: 1: 4–18)

Key words: artificial tear supplements, dry eye, dry eye treatments, evaporative dry eye, ocular surface disorders, tear deficient dry eye, tear film

The concept of the 'dry eye' was initially used to describe symptoms of ocular irritation due to insufficiency in lacrimal gland aqueous tear secretion and leading to ocular surface damage. Keratoconjunctivitis sicca was the term given to the ocular surface disease that develops in patients with aqueous tear deficiency. Over the past 30 years, knowledge of the pathogenic factors involved in dry eye states has grown significantly. Many patients with dry eye symptoms produce a normal quantity of aqueous tears but have other tear film and/or ocular surface disorders.^{1,2} The definition of dry eye has been expanded to include any anomaly in a gland associated with tear production or an anomaly in lid and/or

blinking function in which the quality and/or quantity of the tear film is adversely affected and there is an inability to maintain a healthy ocular surface.^{2,3}

The multifactorial nature of dry eye conditions has produced the term 'tear film and ocular surface disorders'⁴ as an alternative to the term dry eye. This recognises the intimate relationship between the ocular surface and the tear film and the cycle of tear film instability and ocular surface damage characteristic of dry eye. It also acknowledges recent suggestions that dry eye represents a dysfunction of an integrated ocular surface-lacrimal gland unit.^{5,6} The ocular surface (conjunctiva, cornea, accessory lacrimal glands and meibomian glands), the lacrimal gland and the inter-

connecting neural reflex loops appear to comprise a tightly integrated functional unit, the parts of which act together and not in isolation.⁵ Decreased lacrimal gland secretion damages the ocular surface, which creates a negative feedback loop resulting in damage to the lacrimal gland. There are probably several mechanisms by which this feedback occurs:

1. interruption or damage to the sensory corneal nerves
2. damage to the lacrimal gland
3. alteration of growth factor levels in the lacrimal gland following corneal damage.

Contact lenses and corneal refractive surgery are additional factors that may create negative feedback to the lacrimal gland.⁵

Dry eye type	Main Causes
Tear deficient dry eye	<ol style="list-style-type: none"> 1. Sjögren's syndrome 2. Non-Sjögren's lacrimal disease <ul style="list-style-type: none"> Ageing Menopause Medicamentosa Cicatricial disease Neurotrophic keratitis
Evaporative dry eye	<ul style="list-style-type: none"> Meibomian gland disease Lid surfacing/blinking anomalies Contact lens related Chronic allergy/toxicity Cicatricial ocular surface disease

Table 1. Classification of dry eye: main subtypes and main causes (adapted from ³)

The National Eye Institute/Industry Workshop on Clinical Trials of Dry Eye³ has recommended a revision of the classification of dry eye, given its multifactorial nature. The major dry eye categories proposed were tear deficient dry eye and evaporative dry eye. In the tear deficient category were Sjögren's syndrome and non-Sjögren's syndrome forms of aqueous tear deficiency. Evaporative forms of dry eye were oil deficient (meibomian gland anomalies), lid surfacing and blinking anomalies, chronic allergy/toxicity, contact lens-related anomalies and cicatricial ocular surface disease (Table 1).

Dry eye is a prevalent condition with one in four patients presenting for eye examination manifesting dry eye symptoms⁷ and 10 to 18 per cent being diagnosed with dry eye depending on the diagnostic criteria used.^{8,9} The prevalence of dry eye has increased in recent years due to the general ageing of the population,¹⁰ increased medication use¹⁰ and increase in environmental allergens and irritants.^{11,12} It was estimated that there were 30 million dry eye sufferers in the United States of America in 1990 and the incidence of dry eye increased to 59 million in 1997.¹³ In addition to symptoms of chronic ocular surface irritation, dry eye is characterised by blurred vision,

increased risk of infection,^{14,15} medication toxicity,^{16,17} contact lens intolerance¹⁶ and progressive ocular surface disease, scarring and corneal morbidity.¹⁸⁻²⁰ Hence correct diagnosis and appropriate management of dry eye is essential.

THE TEAR FILM AND OCULAR SURFACE

The tear film is composed of an external lipid layer, an aqueous layer, a semi-solid conjunctival goblet cell mucous layer and the non-goblet epithelial mucin layer (the glycocalyx). The lipid layer is produced by the meibomian glands and its principal role is to reduce tear film evaporation.²¹ The aqueous layer contains electrolytes, glucose, antibacterial proteins, antibodies and glycoproteins and is secreted primarily by the lacrimal gland.²² The inner layer of the tear film is composed of mucin secreted by the goblet cells of the conjunctiva^{23,24} and the non-goblet epithelial cells of the cornea²⁵ and conjunctiva.²⁵⁻²⁷ The superficial epithelial cells have microvilli and microplicae that are covered by the glycocalyx, a non-goblet cell mucin, which appears to anchor the goblet cell mucin to the underlying surface epithelium and may facilitate tear film spread and stabilisation.²⁵ The thick-

ness of the tear film remains controversial. Interferometric estimates of 40 microns²⁸ (with the bulk of the tear film being mucin and the tear film thought to be a hydrated mucin gel) and more recently three microns²⁹ have been reported.

The ocular surface epithelium is non-keratinised and multi-layered with morphological variations in the corneal, limbal and conjunctival epithelia.^{30,31} The corneal and conjunctival epithelial barrier functions are formed and maintained by tight, intercellular desmosomes between the adjacent superficial cells.^{32,33} The limbal epithelium is thought to contain the stem cells of the corneal epithelium and serves as the junctional epithelium to prevent conjunctival epithelial ingrowth onto the corneal surface during the healing of a large corneal epithelial defect.^{34,35} The limbal epithelium represents the true germinative zone for corneal epithelium. In normal conditions, the epithelial cells continuously migrate from the limbus toward the corneal centre. This process is accelerated in epithelial wound healing.³⁶ As the limbal epithelial stem cells have very slow cycling time, loss or damage to the limbal area from chemical or surgical trauma, chronic inflammation or contact lens-related pathology can result in limbal stem cell deficiency and a gradual conjunctivalisation of the cornea.³⁷

Numerous hormones, growth factors, retinoids, cytokines and reciprocal receptors for these factors have been identified in the lacrimal glands and on the ocular surface.³⁸⁻⁴² The meibomian glands and lacrimal glands appear to require androgens to support their normal function.⁴²⁻⁴⁵ Androgen loss may play a critical role in the initiation of meibomian gland dysfunction, and decreases in androgen, particularly evident in Sjögren's syndrome, may serve to lessen tissue function as well as to promote (but not cause) the autoimmune process in the lacrimal gland.^{43,45} Programmed cell death (or apoptosis) of lacrimal gland acinar cells may be the primary event proceeding the damage to the lacrimal gland in tear deficient dry eye, even in the absence of autoimmune disease.⁴⁶

Tear deficient dry eye

Aqueous tear deficient dry eye affects up to three per cent of the population and is more prevalent in females and the elderly.^{8,47-49} The lacrimal gland abnormalities include lack of stimulation of tear secretion, inflammation and destruction of the lacrimal gland and accessory lacrimal glands and scarring or occlusion of the lacrimal gland secretory ducts.⁵⁰ The most severe forms of aqueous tear deficiency are due to destruction or absence of the lacrimal gland and include Sjögren's syndrome,⁵¹ human immunodeficiency syndrome,⁵² graft versus host disease⁵³ and congenital or surgical removal of the lacrimal gland.¹ Cicatricial diseases such as trachoma, chemical burns, Stevens-Johnson syndrome and ocular cicatricial pemphigoid can also cause a severe secondary aqueous tear deficiency through the scarring, narrowing and obliteration of the lacrimal gland and accessory lacrimal gland secretory ducts.¹

AUTOIMMUNE AQUEOUS TEAR DEFICIENCY

Sjögren's syndrome is the main cause of severe aqueous tear deficiency and has a prevalence of approximately one per cent, with the majority of sufferers being female.^{8,49} The condition is a slowly-progressing, chronic multi-system condition affecting excretory glands in all patients and extra-glandular organs in some patients with the major features being aqueous tear deficiency and xerostomia (dry mouth).⁵⁴ Approximately half of the cases are associated with other connective tissue disorders, the most common being rheumatoid arthritis and others include systemic lupus erythematosus, scleroderma and polymyositis.⁵⁵ The disease process is extremely complex and the ocular component is characterised by lacrimal gland inflammation, conjunctival inflammation and severe ocular surface desiccation, including punctate keratitis, mucous filaments, corneal ulceration and scleritis^{56,57} (Figure 1). Although the exact mecha-

nism that triggers Sjögren's syndrome is unknown, it seems that some events cause changes in the cell membranes of the lacrimal and salivary glands and the immune system then attacks these glands as if they were foreign.⁵⁷ The infiltrative cells seen in lacrimal gland biopsy are specific to Sjögren's syndrome and they differ in type and number from the infiltration that occurs as a function of ageing.⁵⁸ Recent research indicates that androgen deficiency may promote the progression of Sjögren's syndrome and associated lacrimal gland inflammation but does not cause Sjögren's syndrome or aqueous tear deficiency in human and animal models.⁴³ The relative roles of viral infections such as Epstein-Barr virus, cytomegalovirus and herpes virus-6 in the pathogenesis of Sjögren's syndrome have been suggested and there is evidence that these viruses activate or precipitate immune responses in the lacrimal glands, leading to increased inflammation.⁵⁹⁻⁶¹

NON-AUTOIMMUNE AQUEOUS TEAR DEFICIENCY

Less severe forms of aqueous tear deficiency occur due to abnormalities of the regulation of tear secretion. These may be precipitated by ageing and age-related alterations in hormone levels.⁶²⁻⁶⁴ Diffuse fibrosis, diffuse atrophy and periductal fibrosis predominantly found in elderly women suggest a relationship with aqueous tear deficiency in post-menopausal women.¹ Many commonly-prescribed oral and topical medications may reduce aqueous tear production including topical and systemic anti-histamines, tricyclic antidepressants, topical and systemic beta-blockers, the oral contraceptive pill and systemic and topical non-steroidal anti-inflammatory agents.¹⁰

Loss of corneal sensitivity as is observed in diabetes,⁶⁵ excimer laser photorefractive keratectomy and LASIK⁶⁶ and contact lens wear,⁶⁷ has been implicated in causing dry eye conditions through reduced reflex tearing⁶⁸ and reduced blink rate.³ Reduced tear secretion may actually lead to reduction in corneal sensitivity,⁶⁹ thereby creating a cycle of declining sensitivity and declining tear production.

Evaporative dry eye

MEIBOMIAN GLAND ANOMALIES

Meibomian gland anomalies cause the most prevalent form of evaporative dry eye with a prevalence of four per cent for lipid anomaly dry eye.⁸ Approximately 40 per cent of the general population has signs of meibomian gland dysfunction⁷⁰ and a 100 per cent incidence of poor tear film stability and ocular surface staining has been reported in subjects with chronic meibomianitis.⁷¹ An increased prevalence of meibomian gland dysfunction occurs with age⁷⁰ due to normal ageing changes in the lids and meibomian glands.⁷² The most common causes of meibomian gland dysfunction are damage or destruction of meibomian glands due to meibomian seborrhoea,⁷¹ meibomianitis⁷³ and senile or cicatricial meibomian gland changes.⁷⁴ Less common causes of meibomian gland disease include congenital absence of meibomian glands,² replacement of meibomian glands due to congenital or acquired distichiasis⁷⁴ and meibomian neoplasia.⁷⁴ The dermatological conditions, acne rosacea and seborrhoeic dermatitis, have a 51 per cent and 74 per cent incidence of meibomianitis, respectively.⁷³ Stagnation of the meibomian gland lipids in meibomian gland dysfunction gives bacterial lipase an opportunity to break down the meibomian lipid into free fatty acids which cause increased tear film evaporation, an unstable tear film,⁷⁵ marginal keratitis and a superficial punctate keratopathy⁷³ (Figures 2, 3 and 4).

CHRONIC ALLERGY

Chronic allergy destabilises the tear film and can induce ocular surface disease.^{76,77} An allergic history has been reported by 36 per cent of dry eye subjects.⁷ The allergic inflammatory mechanism in giant cell papillary conjunctivitis (GPC) causes excessive mucin production through hyperplasia of goblet cells and hypermitosis of non-goblet epithelial cells.^{76,77} In addition, decrease in tear production has been reported in subjects who have nasal mucosal pathology following chemical destruction or chronic allergy resulting in reduction or loss of the nasolacrimal reflex.⁷⁸ Vernal

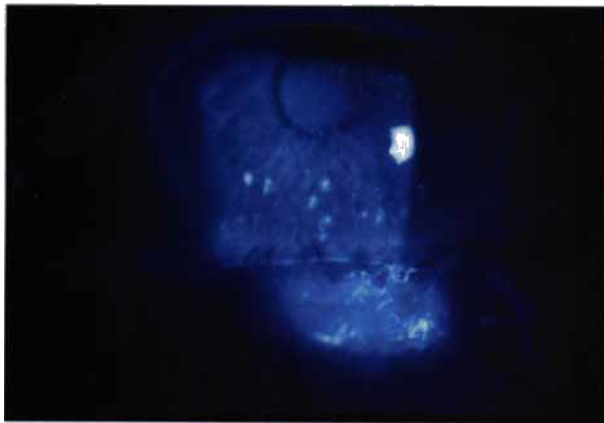


Figure 1. Chronic aqueous tear deficiency in Sjögren's syndrome. Corneal filaments and widespread staining are characteristic features. Inferior neovascular changes are secondary to aqueous tear deficiency and are due to chronic inflammation of the meibomian glands.

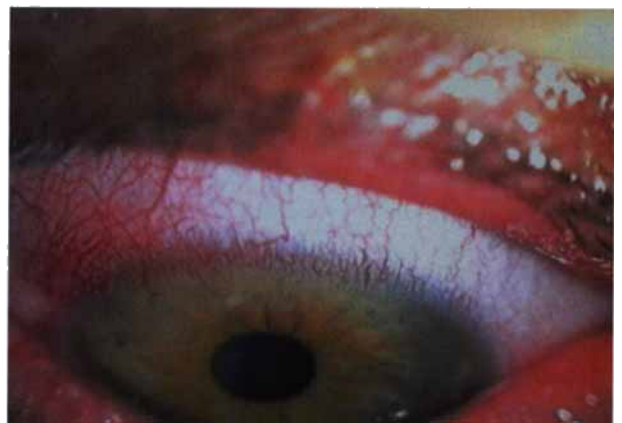

Figure 2. Marginal infiltrative keratitis associated with meibomian seborrhoea

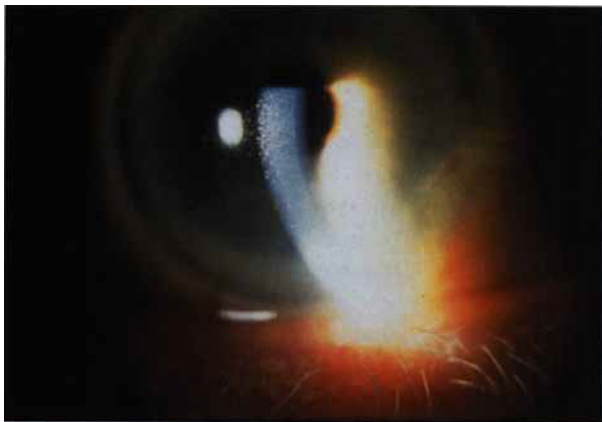


Figure 3. Particulate meibomian gland debris in the tear film. The significant nasal pterygium will exacerbate the evaporative dry eye condition caused by the meibomian gland dysfunction.

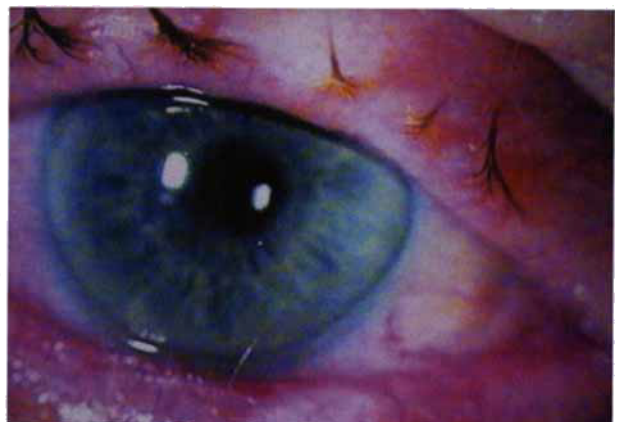

Figure 4. Trichiasis, madarosis, lid thickening and telangiectas associated with chronic meibomian gland dysfunction. Staphylococ blepharitis is also present.

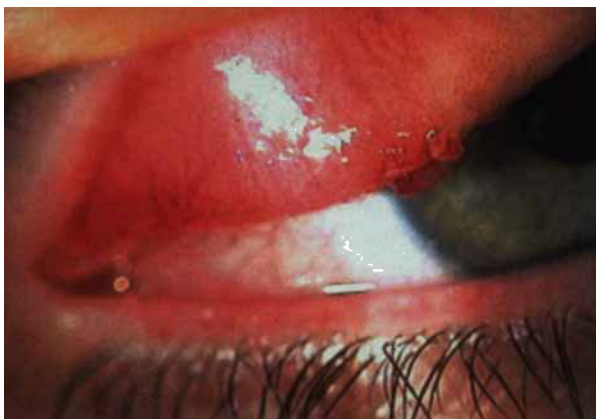

Figure 5. Micro- and macropapillae in vernal kerato-conjunctivitis. The larger papillae can act as a foreign body, further disrupting the ocular surface.

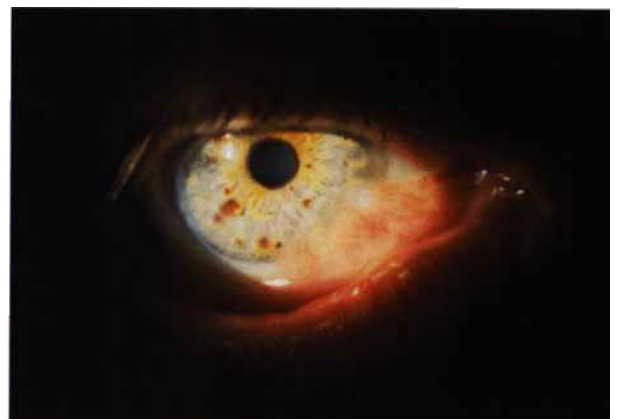

Figure 6. Lid surfacing anomalies causing increased tear evaporation: large fleshy pterygium and senile ectropion

keratoconjunctivitis is associated with a 38 per cent incidence of dry eye⁷⁹ (Figure 5).

OCULAR SURFACE TOXICITY

Toxic effects of topical therapeutic agents can result in ocular surface damage, inflammation and tear film disruption.^{80,81} Preservatives such as benzalkonium chloride^{82,83} and cetrimide⁸⁴ are known to be toxic to the epithelium. Intrinsic toxicity can also result from the active ingredient in the medication itself. For example, long-term use of topical anti-glaucoma medications can induce and/or exacerbate dry eye conditions through squamous metaplasia, loss of goblet cells and ocular surface inflammation.⁸⁵⁻⁸⁷

CONTACT LENS WEAR

Dry eye is prevalent in contact lens wear^{88,89} with 20 to 30 per cent of contact lens wearers having dry eye symptoms.⁹⁰ Contact lens wear is associated with increased mucous production,⁷ reduced blink frequency,⁹¹ blink inefficiency,¹⁶ 3 and 9 o'clock staining,⁹¹ reduced tear break-up time,⁹² increased tear evaporation⁹³ and increased tear osmolarity,⁹⁴ all of which can produce and/or exacerbate dry eye signs and symptoms.

CICATRICAL OCULAR SURFACE DISEASE

Cicatricial ocular surface diseases, although rare, can result in gross tear film instability through destruction of ocular surface epithelia, loss of goblet cells and cicatricial changes such as symblepharon and scarring of lacrimal gland ductules.¹⁹ These conditions are potentially the most vision-threatening of all dry eye types with limbal stem cell loss and conjunctivalisation of the cornea being potential consequences of cicatricial disease.

LID SURFACING ANOMALIES

Dry eye due to lid surfacing anomalies affects approximately two per cent of the population. Any anomaly preventing or restricting complete lid closure and normal blinking patterns can disrupt tear film stability, increase tear evaporation and induce ocular surface staining.⁹¹ Potential causes are ectropion, entropion, large pterygia,⁹⁵ facial palsies, symblepharon,²

incomplete blinking, nocturnal lagophthalmos,⁹⁶ lid retraction and proptosis in thyroid disease,⁹⁷ involuntary blepharospasm,⁹⁸ dermatochalasis,⁹⁹ conjunctivochalasis,¹⁰⁰ lower lid laxity¹⁰¹ and contact lens wear.^{16,91,102} Extensions of the interblink period due to intense concentration during close work and computer work concentration^{103,104} and in Parkinson's disease may lead to dessication of the ocular surface.³ Reduction in lid rigidity and tonus occurs with age.¹⁰⁵ Dellen occur in lid surfacing anomalies in association with pterygia, pingueculae and contact lens wear¹⁸ (Figure 6).

ENVIRONMENTAL INFLUENCES

Environmental factors such as dehydrating temperature-controlled environments⁹⁶ can cause or contribute to evaporative dry eye conditions. Several terms have been used to describe the ocular irritation, poor tear film stability and ocular surface desiccation associated with the poor indoor air-quality in temperature-controlled office environments. These include 'pollution keratoconjunctivitis',¹² 'office dry eye syndrome' and 'sick building syndrome'.¹⁰⁶ Studies indicate that 35 per cent to 48 per cent of individuals working in such environments are afflicted by the ocular signs and/or symptoms.^{106,107}

The multifactorial nature of dry eye

A dry eye condition can have multiple causative mechanisms.¹⁰⁸ A common example is the elderly, post-menopausal, tear-deficient patient taking systemic medications that further reduce tear production.^{109,110} In chronic forms of dry eye, the complications from the primary condition can cause a secondary source of tear film instability and a further exacerbation of the ocular surface disease. An association between tear deficient dry eye and evaporative dry eye has been reported by several authors. McCulley and coworkers⁷³ reported a 25 per cent to 40 per cent incidence of aqueous tear deficiency in subjects with conditions of meibomian gland dysfunction. Chronic lid inflammation

from meibomian gland dysfunction may cause scarring of lacrimal and accessory lacrimal gland ductules, subsequently resulting in deficiency in aqueous tear production¹⁴ (Figure 4). Alternatively, concentration of tear proteins at the inferior lid margin resulting from reduced aqueous tear production can induce inflammation in meibomian glands.⁹⁵ Meibomian gland anomalies are commonly reported in Sjögren's syndrome.^{111,112}

The tear film and ocular surface in dry eye

Specific deficiencies of tear components have been identified in dry eye. These include deficiencies in tear proteins (for example, lactoferrin, lysozyme, prealbumin)^{113,114} and growth factors (for example, epidermal growth factor, transforming growth factors)¹¹⁵ and increase in inflammatory cells.^{31,116}

In all forms of dry eye, irrespective of the mechanism, the conjunctival ocular surface undergoes squamous metaplasia, a progressive transition to a non-secretory, keratinised epithelium.^{80,117,118} The loss of conjunctival goblet cells appears to be a very sensitive indicator of ocular surface disease.^{19,119} Goblet cell loss occurs within weeks of the onset of dry eye disease.¹²⁰ There also appears to be an alteration to conjunctival mucin distribution and/or chemical properties in dry eye.¹²¹ Inflammatory mechanisms are the most likely cause for the loss of goblet cells in dry eye.^{19,119} Up regulation of immune-mediated markers of conjunctival ocular surface inflammation and infiltration of T-lymphocytes occur in the conjunctival epithelium in both Sjögren's syndrome and non-Sjögren's dry eye.^{56,81,122-126} The inflammatory mediators released as a result of cellular damage appear to exacerbate the ocular surface and lacrimal gland inflammation and damage in dry eye.¹²⁷⁻¹³⁰

CLINICAL DRY EYE ASSESSMENT

While there are many tests for dry eye, there remains a great disparity among the symptoms and signs in many dry eye patients. Determining the cause of dry eye when minimal clinical signs are present

Explore Litigation Insights

Docket Alarm provides insights to develop a more informed litigation strategy and the peace of mind of knowing you're on top of things.

Real-Time Litigation Alerts



Keep your litigation team up-to-date with **real-time alerts** and advanced team management tools built for the enterprise, all while greatly reducing PACER spend.

Our comprehensive service means we can handle Federal, State, and Administrative courts across the country.

Advanced Docket Research



With over 230 million records, Docket Alarm's cloud-native docket research platform finds what other services can't. Coverage includes Federal, State, plus PTAB, TTAB, ITC and NLRB decisions, all in one place.

Identify arguments that have been successful in the past with full text, pinpoint searching. Link to case law cited within any court document via Fastcase.

Analytics At Your Fingertips



Learn what happened the last time a particular judge, opposing counsel or company faced cases similar to yours.

Advanced out-of-the-box PTAB and TTAB analytics are always at your fingertips.

API

Docket Alarm offers a powerful API (application programming interface) to developers that want to integrate case filings into their apps.

LAW FIRMS

Build custom dashboards for your attorneys and clients with live data direct from the court.

Automate many repetitive legal tasks like conflict checks, document management, and marketing.

FINANCIAL INSTITUTIONS

Litigation and bankruptcy checks for companies and debtors.

E-DISCOVERY AND LEGAL VENDORS

Sync your system to PACER to automate legal marketing.