

sucrase-isomaltase deficiency. It is tempting to postulate that it represents a genetically determined condition, which was unmasked by an episode of gastroenteritis. The alternative that it may represent a truly acquired condition possibly, precipitated by an enteric infection, has also to be considered.

ACKNOWLEDGMENT

We thank the Department of Gastroenterology, University College Hospital, Galway, for their assistance with this case.

Reprint requests and correspondence: Professor F. Gleeson, James Connolly Memorial Hospital, Blanchardstown, Dublin 15, Ireland.

Received June 27, 1997; accepted Jan. 11, 1999.

REFERENCES

1. Weijers HA, Van De Kamer JH, Mosel DAA, et al. Diarrhoea caused by deficiency of sugar splitting enzymes. *Lancet* 1960; 2:296.
2. Auricchio S, Rubino A, Prade A, et al. Intestinal glycosidase activities in congenital malabsorption of disaccharides. *J Pediatr* 1965;66:555.
3. Sonntag WM, Brill ML, Troyer ME, et al. Sucrase-isomaltase malabsorption in an adult woman. *Gastroenterology* 1964;47: 18.
4. Neale G, Clark M, Levin B. Intestinal sucrase deficiency presenting as sucrose intolerance in adult life. *Br Med J* 1965;2:1223.
5. Santagelo WC, Dueno MI, Krejs GJ. Pseudopancreatic cholera syndrome: Effect of a synthetic Somatostatin analogue. *SMS* 201-995. *Am J Med* 1987;82(suppl 58):84.
6. Stevens F, Lloyd R, Geraghty S, et al. Schizophrenia and coeliac disease—The nature of the relationship. *Psychol Med* 1977;7:259-63.
7. Cooper BT, Scott J, Hopkins J, et al. Adult onset sucrase-isomaltase deficiency with secondary disaccharidase deficiency resulting from severe dietary carbohydrate restriction. *Dig Dis Sci* 1983;28:473.
8. Ringrose RE, Preiser H, Welsh JD. Sucrase-isomaltase (Palatinase) deficiency diagnosed during adulthood. *Dig Dis Sci* 1980;25:384.
9. Gudmand-Hoyer E. Sucrase malabsorption in children: A report of thirty one Greenlanders. *J Pediatr Gastroenterol Nutr* 1985;4:873.
10. Gray GM, Conklin KA, Townley RR. Sucrase-isomaltase deficiency. *N Engl J Med* 1976;294:750-3.
11. Prader A, Auricchio S. Defects of intestinal disaccharide absorption. *Annu Rev Med* 1965;13:345.
12. Smith MW, Phillips AD, Walker-Smith JA. Selective inhibition of brush border hydrolase development in coeliac disease and cows milk protein intolerance. *Paediatr Res* 1986;20:693 (abstract).
13. Lifshitz F. Perspectives of carbohydrate intolerance in infants with diarrhoea. In: Lifshitz F, ed. *Carbohydrate intolerance in infancy*. New York: Marcel Dekker, 1982:3.
14. Dahlqvist A. Assay of intestinal disaccharidases. *Anal Biochem* 1968;22:99-107.

Bromfenac(Duract)-Associated Hepatic Failure Requiring Liver Transplantation

Ellen B. Hunter, M.D., Philip E. Johnston, Pharm.D., Gordon Tanner, M.D., C. Wright Pinson, M.D., M.B.A., and Joseph A. Awad, M.D.

Departments of Medicine, Surgery, and Pharmacology, Divisions of Gastroenterology, Clinical Pharmacology, and Hepatobiliary Surgery and Liver Transplantation, Vanderbilt University, Nashville, Tennessee

ABSTRACT

Bromfenac sodium (Duract) is a phenylacetic acid-derived nonsteroidal anti-inflammatory agent introduced in the United States in 1997 and withdrawn in 1998. We describe the first case of fulminant hepatic failure associated with this agent treated successfully with liver transplantation. Similarities to hepatotoxicity with related agents is discussed. (*Am J Gastroenterol* 1999;94:2299-2301. © 1999 by Am. Coll. of Gastroenterology)

INTRODUCTION

Bromfenac sodium (Duract) is a phenylacetic acid-derived, nonsteroidal anti-inflammatory agent (NSAID). It was approved by the United States Food and Drug Administration (FDA) July 15, 1997, and withdrawn by the manufacturer June 22, 1998, after drug-associated severe hepatic injury resulted in death or liver transplantation. We describe the first case of fulminant hepatic failure associated with bromfenac sodium reported to the FDA that was treated successfully with liver transplantation, and discuss the similarities of this case to liver dysfunction reported with other members of this class of NSAIDs.

CASE REPORT

A 36-yr-old man was transferred to Vanderbilt University Hospital with severe hepatic dysfunction. Past medical history was significant only for osteoarthritis treated with bromfenac sodium 50 mg *t.i.d.* for 3 months. He was admitted to a local hospital 8 days before transfer with jaundice and epigastric pain. Bromfenac was discontinued at that time. His serum bilirubin was 11.4 mg/dl, alkaline phosphatase 130 U/L, AST 1805 U/L, ALT 1451 U/L, prothrombin time 5 s prolonged, and albumin 3.0 mg/dl. Computed tomography of the abdomen was notable for edema and thickening of the gallbladder wall. Endoscopic retrograde cholangiography was normal. Hepatitis B surface antigen, and IgM antibodies to hepatitis B core antigen and hepatitis A were not detected. Antibodies to hepatitis B surface antigen and hepatitis C (ELISA II) were also not detected. Continued nausea and vomiting, development of grade I-II

encephalopathy, and serum glucoses <55 mg/dl prompted transfer of the patient.

The patient denied a history of significant alcohol use, injection drug use, blood transfusion, mushroom ingestion, or toxin exposure. He had no personal or family history of liver disease. Vital signs were within normal limits with no recorded fever. He was jaundiced, but without tattoos, cutaneous stigmata of chronic liver disease, or hypersensitivity reaction. Kaiser-Fleischer rings were absent and cardiopulmonary examination was within normal limits. The liver was palpable just below the costal margin, but the spleen was not. The patient was somnolent with asterixis. The serum bilirubin had increased to 29 mg/dl and prothrombin time was 12 s prolonged. The AST was 892 U/L, ALT 1480 U/L, and alkaline phosphatase 144 U/L. Factor V activity was 26%. Hematocrit was 44% with a reticulocyte count of 2.4%, and creatinine was 0.7 mg/dl.

The FDA was contacted November 25, 1997, and a MedWatch report was subsequently filed because of concern regarding hepatic failure related to bromfenac. At that point, no similar reports had been filed. The patient's condition continued to deteriorate and he underwent orthotopic liver transplantation December 17, 1997, 31 days after presentation.

Pretransplant evaluation at our facility revealed no other cause of liver disease, although repeat serological testing for viral hepatitis was confusing. Hepatitis B surface antigen and hepatitis C ELISA II testing were both positive at low levels despite the absence of all other serological markers of hepatitis B, negative DNA testing for hepatitis B (<5 pg/ml), and negative RNA detection for hepatitis C (qualitative polymerase chain reaction). Antinuclear and antismooth muscle antibodies were absent. Histological examination of the explanted liver showed hepatic necrosis and parenchymal collapse with only scant fibrous tissue within the bridging necrosis consistent with severe acute injury. There was marked subacute inflammation, cholangiolar proliferation, and extensive bile ductular stasis with plugging. An orcein stain was negative. One year posttransplant, the patient has normal allograft function. Hepatitis B surface antigen and core antibody remain negative. Testing for hepatitis C by ELISA II and polymerase chain reaction also remain negative.

DISCUSSION

Bromfenac sodium (Duract) is a phenylacetic acid NSAID related to diclofenac sodium (Voltaren) approved by the FDA July 15, 1997, and withdrawn voluntarily by the manufacturer June 22, 1998, after >2.5 million prescriptions for the drug were written (1). Bromfenac sodium was approved only for short term treatment of pain (≤ 10 days). The package insert reported a 15% rate of AST or ALT elevation of up to three times the upper limit of normal (ULN) in short term clinical trials of bromfenac including 926 patients. Transaminase elevations of more than three times the ULN were noted in 2.7% of patients, and elevations more than eight times the ULN were seen in 0.4% of patients in short

and longer term trials. The package insert advised monitoring hepatic biochemistries of patients treated for >4 wk (2).

NSAIDs are among the most commonly used medications worldwide. Liver injury does not appear to be common, but severe hepatic injury and death have been reported sporadically with many agents representing a variety of chemical classes (3, 4). However, at least two other phenylacetic acid derivatives, diclofenac sodium and ibufenac, cause hepatic biochemical abnormalities in >10% of patients, and ibufenac was abandoned in the late 1960s (3). Diclofenac sodium received attention because of reports of severe hepatic injury shortly after its introduction in the United States (5, 6). The pattern of liver injury in our patient was similar to that described in most patients with diclofenac-induced hepatotoxicity. He presented with severe hepatitis that progressed to fulminant hepatic failure without signs of hypersensitivity, had no history or histological evidence of chronic liver disease, and no other recognizable cause of hepatitis was identified. The common occurrence of hepatic biochemical abnormalities after treatment with phenylacetic NSAIDs suggests a definable mechanism of injury in some patients that may result in hepatic failure in a rare patient.

This is the first case of fulminant hepatic failure in a patient treated with bromfenac sodium after its approval by the FDA. Reporting of this and other cases to the MedWatch program caused issuance of a letter by Wyeth-Ayerst Laboratories in February 1998, informing health care providers of revised product labeling including a new boxed warning of severe hepatitis and liver failure in patients taking bromfenac sodium (7). On June 22, 1998 bromfenac sodium was withdrawn voluntarily from the market by the manufacturer because of four liver failure-related deaths and eight liver transplantations of patients using bromfenac sodium, most for longer than the recommended length of time (1).

We believe that this case illustrates why health care providers should exercise caution when prescribing new medications, especially if the drug has recognized organ toxicity and there are efficacious alternatives. This case also emphasizes the need for gastroenterologists to be vigilant for cases of gastrointestinal and hepatic injury that may be related to new medications, and the importance of reporting these cases to the MedWatch program.

Reprint requests and correspondence: Joseph A. Awad, M.D., Division of Gastroenterology, Vanderbilt University, MCN/C-2104, Nashville, TN 37232-2279.

Received July 14, 1998; accepted Jan. 26, 1999.

REFERENCES

1. Dear Health Professional Letter-Duract. Philadelphia, PA: Wyeth Laboratories Inc., June 22, 1998.
2. Package insert, Duract (bromfenac sodium capsules). Philadelphia, PA: Wyeth Laboratories Inc., May 16, 1997.
3. Rabinowitz M, Van Thiel DH. Hepatotoxicity of nonsteroidal anti-inflammatory drugs. *Am J Gastroenterol* 1992;87:1696-1704.

4. Boerlsterli UA, Zimmerman HJ, Kretz-Rommel A. Idiosyncratic liver toxicity of nonsteroidal antiinflammatory drugs: Molecular mechanisms and pathology. *Crit Rev Toxicol* 1995; 25:207-35.
5. Helfgott SM, Sandberg-Cook J, Zakim D, et al. Diclofenac-associated hepatotoxicity. *JAMA* 1990;264:2660-2.
6. Scully LJ, Clarke D, Barr RJ. Diclofenac induced hepatitis: 3 Cases with features of autoimmune chronic active hepatitis. *Dig Dis Sci* 1993;38:744-51.
7. Dear Health Professional Letter-Duract. Philadelphia, PA: Wyeth Laboratories Inc., February 1998.

Pancreatitis Associated With Crohn's Disease: A Premalignant State for Cystadenocarcinoma of Pancreas?

Amnon Gotian, M.D., and

Seymour Katz, M.D., F.A.C.G., F.A.C.P.

Department of Medicine, North Shore University Hospital, Manhasset, New York; and New York University School of Medicine, New York, New York

ABSTRACT

We report a 74-yr-old woman with Crohn's disease and acute pancreatitis who, 3 yr after resolution of the latter, developed cystadenocarcinoma of the pancreas. No drug, toxin, or other etiologies including contiguous duodenal involvement were identified as responsible for the pancreatitis, suggesting that pancreatitis was an extraintestinal manifestation of her Crohn's disease. Could Crohn's-associated pancreatitis be a premalignant state for cystadenocarcinoma of the pancreas? (*Am J Gastroenterol* 1999;94:2301-2302. © 1999 by Am. Coll. of Gastroenterology)

INTRODUCTION

The association between pancreatitis and Crohn's disease has been increasingly recognized (1-3). In several studies, pancreatitis as an extraluminal manifestation of Crohn's disease itself was the only explanation. We report the first case of Crohn's-related pancreatitis without contiguous duodenal involvement and with subsequent development of cystadenocarcinoma of the pancreas.

CASE REPORT

A 74-yr-old white woman of Hungarian descent was admitted in 1987 to the hospital with intermittent melena and black stool. Her past medical history included mitral valve prolapse, uterine prolapse, chronic urinary tract infections, bilateral carotid disease, and bilateral subtotal thyroidectomy for benign nodules, and 15 years of "irritable bowel syndrome." Esophagogastrosocopy, sigmoidoscopy, and subsequent colonoscopy were all negative. Enteroclysis showed extensive ileitis, ulcerations, and pseudopolyposis consistent with Crohn's disease.

In March 1988 she was readmitted for anemia, weakness, and fatigue. Biopsies of colonic mucosa were negative for inflammation. Subsequent CT of the abdomen and pelvis demonstrated a thickened wall and narrowed lumen of the terminal ileum consistent with inflammatory bowel disease. A small focal abnormality was found in the liver consistent with a small hemangioma. The pancreas was normal.

In June 1988, the patient underwent a resection of 31 cm of the terminal ileum with a 5-cm-long segment of attached cecum because of persistent debility. The pathology report described extensive ulcerations and pseudopolyp formation with a small fistula into the mesentery. A follow-up small bowel series in October 1989 showed no evidence of recurrence. A colonoscopy performed in July 1991 revealed normal colonic mucosa. The patient remained asymptomatic and off all medications.

In March of 1994, while not taking any medications, the patient developed abdominal pain and underwent ultrasonography of the abdomen. A focal lesion on right lobe of liver was found to be consistent with small hemangioma and dilatation of the pancreatic duct with no discrete mass in the pancreas. The pancreatic body was slightly heterogeneous, consistent with pancreatitis. Her amylase level was 1188 (24-97 normal), her white blood cells 13,600 with 90% polymorphonuclears, hemoglobin 12.7, hematocrit 38.0, and platelets 231. Serum amylase fell to 346 (normal 34-122), lipase 130 (normal < 60), total bilirubin 0.8, albumin 3.3, alkaline phosphatase 58, AST 18, ALT 18, CPK 45, LDH 154, and calcium 8.8.

A computed tomography scan of the abdomen and pelvis was consistent with the clinical history of pancreatitis. No biliary tract stones or disease were identified. A suggestion of possible duodenal wall thickening was believed to be secondary to the surrounding peripancreatic inflammation. The pancreatitis resolved shortly afterward, and the patient was discharged 6 days later with an amylase level of 44. The patient continued to remain asymptomatic with normal amylase levels until June 1997, when she noted weight loss and

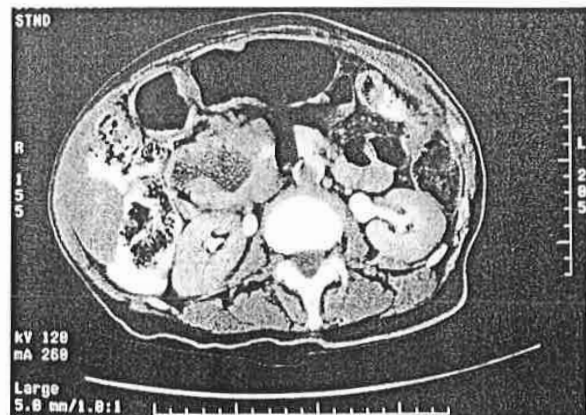


Figure 1. CT scan of abdomen demonstrating 6 × 3-cm mass on the head of the pancreas.