

Topical nonsteroidal anti-inflammatory agents in ophthalmology

John Nichols, MD,* and Robert W. Snyder, MD, PhD†

Nonsteroidal anti-inflammatory agents or NSAIDs are potent inhibitors of prostaglandin synthesis. As such, they have found many useful roles in ophthalmology. NSAIDs are approved by the FDA to prevent intraoperative miosis during cataract surgery, reduce postoperative inflammation following cataract surgery, and control symptoms of allergic conjunctivitis and pain following refractive surgery. In addition, they have been shown to be effective in preventing cystoid macular edema following cataract surgery or treating cystoid macular edema once it occurs.

*Tucson Hospital Medical Education Program, Tucson Medical Center, Tucson; and †Department of Ophthalmology, University of Arizona, Tucson, AZ 85719, USA.

Current Opinion in Ophthalmology 1998, 9;IV:40-44

Abbreviations

AA	arachidonic acid
CME	cystoid macular edema
NSAIDs	nonsteroidal anti-inflammatory drugs
PRK	photorefractive keratectomy

© 1998 Lippincott Williams & Wilkins
ISSN 1040-8738

Nonsteroidal anti-inflammatory drugs (NSAIDs) inhibit the production of prostaglandins. When used preoperatively and postoperatively they can reduce or alleviate unwanted sequelae of prostaglandin synthesis and release. During the past few years, NSAIDs have been widely investigated and their use in ophthalmology is expanding. The NSAIDs are useful in preventing prostaglandin-mediated miosis during intraocular surgery, minimizing postoperative photophobia, reducing postoperative inflammation and discomfort, decreasing the incidence of cystoid macular edema (CME), and speeding the resolution of CME if it should occur. They are also useful in diminishing the symptoms associated with seasonal allergies.

Nonsteroidal anti-inflammatory drugs mechanism of action

There are a wide range of inflammatory responses in the eye following mechanical, chemical, and thermal stimuli. Many of these responses are to be mediated by the formation of prostaglandins from the fatty acid, arachidonic acid (AA), which is generated from phospholipids in the plasma membrane. Once formed, these prostaglandins can cause breakdown of the blood aqueous barrier, lower the pain threshold, and augment photophobia. They can also potentiate effects of other inflammatory mediators [1]. The NSAIDs achieve their anti-inflammatory effects by inhibiting cyclooxygenase and thus, preventing the formation of prostaglandins from AA.

Tissue injury or manipulation may initiate the chain of reactions that result in prostaglandin synthesis. Early on, AA may be liberated directly from cellular membrane phospholipids by phospholipase A2 (PLA2). The AA may then be converted into prostaglandins by cyclooxygenase. Phospholipase A2 and the inducible form of cyclooxygenase (COX-2) are inhibited by glucocorticoids [2**], whereas the NSAIDs inhibit both the constitutive form of cyclooxygenase (COX-1) and COX-2. However, in the presence of NSAIDs, the AA instead may be converted to leukotrienes resulting in polymorphonuclear leukocyte chemotaxis (Fig. 1).

Phospholipase A2 is also important in transforming 1-O-alkyl-2-acyl-glycerol to lyso-PAF (platelet activating factor). Lyso-PAF is then converted into PAF which stimulates phospholipase C (PLC) via a G-protein. The PLC then liberates AA-diacylglycerol that is further lysed into AA and diacylglycerol. This AA can also be transformed into prostaglandins via cyclooxygenase.

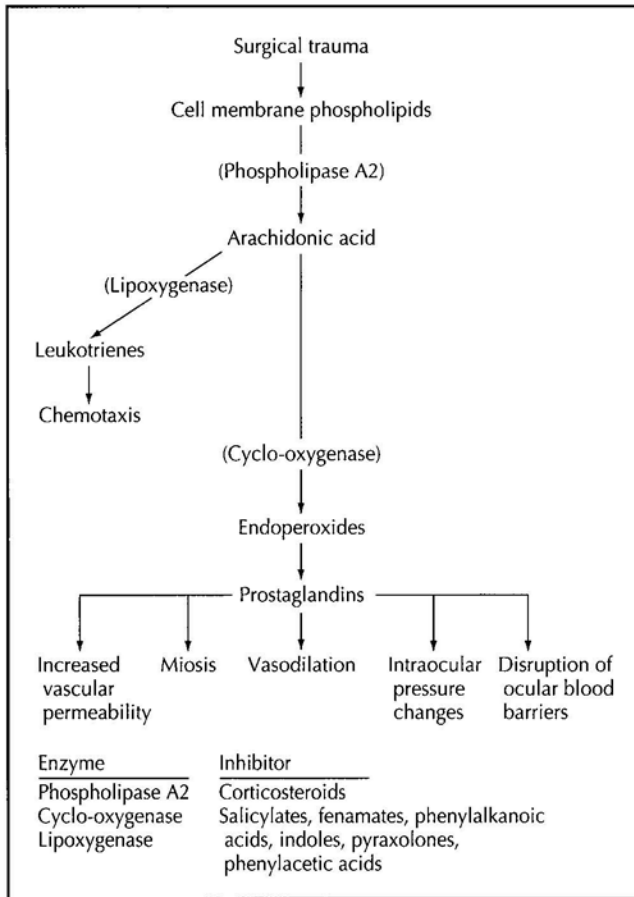


Fig.1. Prostaglandin and leukotriene synthesis. (Adapted from Flach [30]; with permission.)

Maintenance of intraoperative mydriasis

Small pupils or intraoperative miosis make cataract surgery more challenging and increase the risk of capsule rupture [3]. Adrenalin in the irrigating bottle, as well as preoperative NSAIDs have been used to maintain a dilated pupil. Currently, suprofen 1% and fluorbiprofen 0.03% are approved by the FDA for use in the prevention of intraoperative miosis. Diclofenac and ketorolac are currently not approved by the FDA for prevention of intraoperative miosis but have also been found to be effective [4*,5*,6, and RW Snyder, unpublished data, 1998]. When preoperative diclofenac or ketorolac has been compared with fluorbiprofen, there was no statistical difference in the size of the pupil following cataract surgery [6, and RW Snyder, unpublished data, 1998] suggesting that they are equally as effective.

Although suprofen or fluorbiprofen is frequently used to prevent intraoperative miosis, their routine use to prevent miosis is not universally accepted. The addition of 0.3 mL of 1:1000 epinephrine without preservative to each 500-mL bottle of buffered saline irrigating solution

may be more effective than NSAID alone [7]. However, there is probably an additive effect with NSAID and epinephrine and, as will be discussed later, the NSAID may provide the additional benefit of minimizing postoperative discomfort and photophobia.

Pain

Prostaglandins appear to be very potent mediators of pain. Once they are released it is difficult to reverse the prostaglandin-mediated effect. The NSAIDs effectively block the production of the prostaglandins and are very potent analgesics. In well-controlled studies comparing systemic NSAIDs to narcotics for relief of dental and postoperative pain, 30 and 90 mg of ketorolac were found to be more effective than 12 mg of morphine for pain control [8]. Because NSAIDs could be delivered easily via topical preparation, they were used early on to control pain following photorefractive keratectomy (PRK). Arshinoff *et al.* [9] were the first to propose the use of NSAIDs for post-PRK pain. They found that topical 0.1% diclofenac or 0.5% ketorolac with a bandage contact lens was an effective regimen for post-PRK pain control. This has been confirmed by others [10,11] and has become standard practice for PRK, PTK (phototherapeutic keratectomy), RK (radial keratotomy) and LASIK (laser in situ keratomileusis). In addition to control of postoperative pain, photophobia also appears to be diminished. Acular Preservative Free (0.5% ketorolac tromethamine) (Allergan, Irvine, CA) has recently been approved by the FDA for pain and photophobia control following refractive surgery. We have also investigated the use of NSAIDs in clear cornea cataract surgery with topical tetracaine and intracameral lidocaine as anesthetics. In patients who are continued on topical ketorolac, there is minimal discomfort in the early 24-hour postoperative period. We believe the same analgesic effect as seen in postrefractive surgery patients occurs following topical anesthetic cataract surgery in which the patient is not patched. This can be an important adjunct in optimizing patient comfort in the postoperative period.

Postoperative inflammation

There are numerous studies that demonstrate the effectiveness of NSAIDs in preventing or minimizing postoperative inflammation. Both 0.1% diclofenac and 0.5% ketorolac have been approved by the FDA for prevention of postoperative inflammation following cataract extraction. (It should be noted that cortical steroids do not carry this indication). In its most severe form, excess breakdown of the blood aqueous barrier can lead to a plasmoid aqueous with resulting synechia of the iris to the implanted intraocular lens or chamber angle, development of a pupillary membrane, or formation of cystoid macular edema. In prospective, randomized controlled studies both 0.1% diclofenac and 0.5% ketorolac have been shown to be as effective or more effective than a

corticosteroid in minimizing postoperative inflammation following cataract surgery [4*,12,13,14*,15–18]. A prospective study of 52 patients who were randomly assigned to receive either 1.0% diclofenac eyedrops or 0.1% prednisolone eyedrops were examined at day one, 1 week, and 1 month after surgery. Postoperative inflammation was determined subjectively by slit lamp, or objectively with a laser cell and flare meter. There was no statistical difference in inflammation between the corticosteroid and the NSAID treatment [19].

In a different large multicenter study, ketorolac was compared with 1% prednisolone and 0.1% dexamethasone for postoperative inflammation control following extracapsular cataract extraction or phacoemulsification with posterior chamber intraocular lens implantation. Patients were evaluated postoperatively for slit-lamp evidence of cell and flare as well as for fluorescein leakage across the blood aqueous barrier as measured by fluorophotometry. No significant difference was seen between ketorolac and glucocorticoid with respect to subjective or objective evaluation of inflammation [14*].

Prevention of cystoid macular edema

The NSAIDs have been evaluated for both prophylaxis and treatment of postoperative CME. The Italian Diclofenac Study Group [5*] looked at the prevention of postoperative angiographic-identified CME following extracapsular cataract extraction. They found that diclofenac 0.1% eye drops were effective in reducing the incidence of angiographic-demonstrated CME. This complication rate occurs in approximately 20% of eyes. After 140 days, the incidence of CME was two times higher in the control group (1% dexamethasone plus 0.1% diclofenac days 1–5 postoperative, and placebo days 6–140 versus the 0.1% diclofenac group which was 0.1% diclofenac plus 0.1% dexamethasone days 1–5 postoperative and diclofenac days 6–140 postoperative). There were no undesirable side effects such as increased intraocular pressure or ocular discomfort noted in this study. A double-masked study of prophylaxis of CME in which NSAIDs alone (without concurrent corticosteroid) was used showed that 0.5% ketorolac decreased angiographic CME when compared with placebo [20]. Other studies by Flach *et al.* [12,13] have shown that 0.5% ketorolac is more effective than dexamethasone phosphate when used postoperatively following extracapsular cataract surgery in maintaining the blood aqueous barrier.

The NSAIDs have also been shown to be effective in treating postoperative CME. In a prospective randomized study [21] evaluating 61 patients with either aphakic or pseudophakic cystoid macular edema treated with ketorolac 0.5% or placebo, there was a statistically significant improvement of at least two lines of visual acuity at 30, 60, 90, and 120 days with patients taking ketorolac.

Other uses for nonsteroidal anti-inflammatories

Topical nonsteroidal anti-inflammatories have recently been advocated as an adjunct to pain control following traumatic corneal abrasion [22]. Jayamanne *et al.* [23*] showed that diclofenac was effective in relieving discomfort following traumatic corneal abrasion and suggested that a regimen of topical diclofenac 0.1% in antibiotic four times daily provided a superior alternative to traditional antibiotic ointment, cycloplegics, and oral analgesics. Donnenfeld *et al.* [22] also examined a regimen of 0.5% ketorolac and topical 0.3% ofloxacin for management of traumatic corneal abrasions and found the patients were comfortable with this regimen.

As noted earlier, 0.5% Ketorolac Preservative Free (Algergan, Irvine CA) has recently been approved by the FDA for use in controlling postoperative pain following incisional refractive surgery. This is an important adjunct because postoperative photophobia in refractive surgery, as well as cataract surgery, is troublesome to the patient and eradication of light sensitivity provides significant improvement in their comfort during the immediate 24 to 48 hours following surgery.

Allergic conjunctivitis

Ketorolac 0.5% was first approved by the FDA for the treatment of symptoms of allergic conjunctivitis. In a large double-masked paired comparison of ketorolac 0.5% versus placebo eye drops in the treatment of seasonal allergic conjunctivitis [24], ketorolac was found to be superior to placebo in reducing conjunctival inflammation and itching. Similar results have also been reported by Ballad *et al.* [25] In this study as well as others, there was mild transient burning and stinging reported with a higher frequency in the ketorolac-treated eyes versus the placebo. This is not found in patients treated for postoperative cataract inflammation and may represent a subset of patients with “more sensitive eyes.”

Diclofenac 0.1% has also been shown to be effective for seasonal allergic conjunctivitis [25], while suprofen has been shown to be effective in giant papillary conjunctivitis [26] and neural conjunctivitis [27].

Toxicity

Nonsteroidal anti-inflammatory drugs are known to have a high incidence of burning and stinging upon application. However, as noted earlier this was reported in patients who had allergic conjunctivitis and arguably were more sensitive from the onset. In published studies, however, a small subset of patients do complain of burning upon instillation. Experience with cataract extraction [5*,21] has not identified this as a significant side effect. There is also concern that nonsteroidal anti-inflammatory drops may inhibit epithelial healing. In a presentation to the Castro-

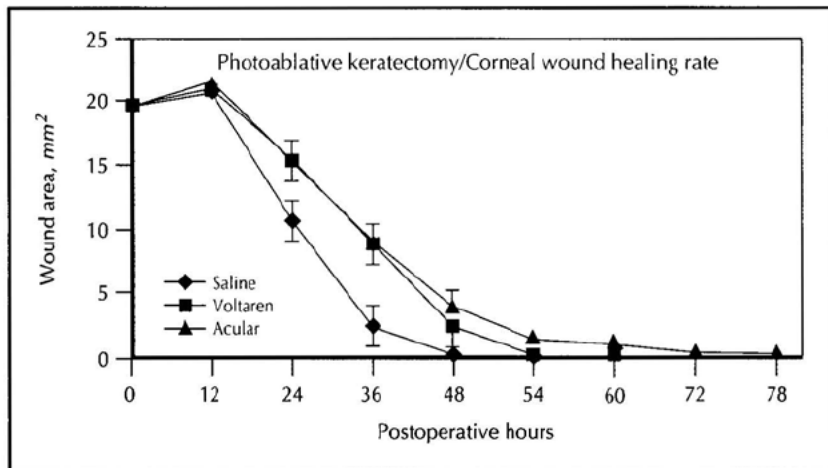


Fig. 2. Corneal wound healing with ketorolac versus diclofenac.

vicjo Society in 1996 [29], we reported our assessment of topical diclofenac and ketorolac on epithelial healing in a rabbit model. Initially, we evaluated a 7.2-mm epithelial defect created by mechanical scraping. Animals were treated postoperatively with 0.5% ketorolac, 0.1% diclofenac, or phosphate buffered saline as the control using two drops every 6 hours until the epithelial healing was completed. At 0, 12, 36, 48, 54, 60, 66, 72, and 78 hours, the rabbit's epithelial defect was stained with fluorescein, photographed, and digitized. The digital photography was then analyzed. There was no statistical difference in the healing between ketorolac, diclofenac, and phosphate buffered saline in this surface scrape model. A second set of experiments were also performed in which a 5-mm phototherapeutic keratectomy (300 pulses) was created in a rabbit eye. These animals were then treated postoperatively with 0.5% ketorolac, 0.1% diclofenac, 0.5% preservative-free ketorolac, or phosphate buffered saline, two drops every 6 hours until the epithelium was complete. The wound healing was again assessed using digital fluorescein photography and wound healing curves generated.

As can be seen in Figure 2, there was a significant delay in epithelial healing when diclofenac and ketorolac were compared with saline. There was significantly less delay when preservative-free ketorolac was compared with ketorolac (Fig. 3). However, in all cases the epithelium was healed within 78 hours and the delay appeared minimal. This suggests that the nonsteroidals do exhibit a moderate to modest delay in epithelial wound healing and their use should be monitored closely in situations where epithelial healing may be problematic.

Conclusions

In summary, NSAIDs provide effective prevention of intraoperative miosis, good control of postoperative pain and inflammation, prophylaxis of postoperative CME following cataract surgery, and are even effective at treating cystoid macular edema following cataract surgery. They have minimal adverse effects. They play a very important role in optimizing surgical outcome and may circumvent some of the unwanted side effects that occur with corticosteroid treatment.

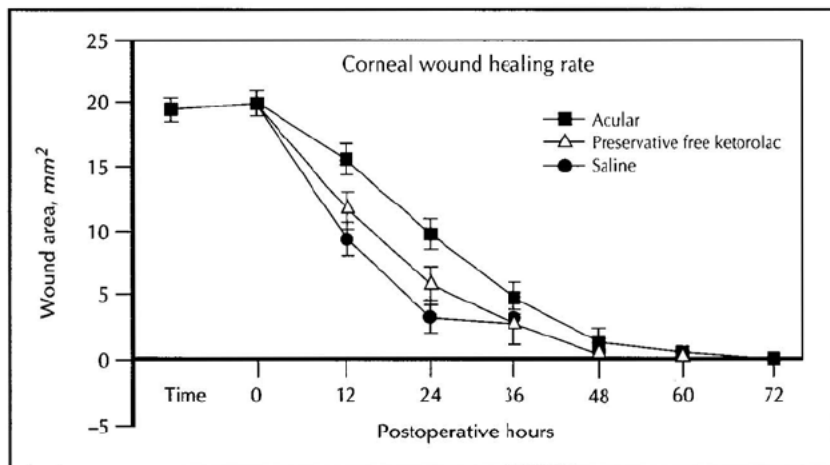


Fig. 3. Corneal wound healing with ketorolac versus preservative free ketorolac.

References and recommended reading

Papers of particular interest, published within the annual period of review, have been highlighted as

- Of special interest
- Of outstanding interest

1. Greaves MW, McDonald-Gibson W: Itch: role of prostaglandins. *BMJ* 1973, 3:608–609.
2. Masferrer JL, Kulkarni PS: Cyclooxygenase-2 inhibitors: a new approach to the therapy of ocular inflammation. *Surv Ophthalmol* 1997, 41(suppl 2):S35–S40.

This article reviews the mechanism of action of anti-inflammatory agents but emphasizes NSAIDs. Briefly, NSAIDs nonselectively inhibit cyclooxygenase-1 (COX-1), responsible for constitutive prostaglandin expression, and cyclooxygenase-2 (COX-2), responsible for prostaglandin synthesis in response to inflammation. Corticosteroids inhibit only COX-2 but have other undesirable systemic and ocular effects. Systemic selective COX-2 inhibitors are effective anti-inflammatory agents but do not cause gastrointestinal irritation and ulcers, and are postulated as effective ocular anti-inflammatories delivered either topically or systemically.

3. Guzek JP, Holm M, Cotter JB, Cameron JA, Rademaker WJ, Wissinger DH, et al.: Risk factors for intraoperative complications in 1000 extracapsular cataract cases. *Ophthalmology* 1987, 94:461–466.
4. Antcliff RJ, Trew DR: The maintenance of peri-operative mydriasis in phacoemulsification with topical diclofenac sodium. *Eye* 1997, 11:389–391.

This study showed statistically significant differences in pupillary diameters between eyes treated with diclofenac ($n = 32$) and untreated eyes ($n = 32$) post-phacoemulsification ($P = 0.03$), postinfusion/postaspiration ($P = 0.008$), and 1 day postoperatively ($P = 0.003$).

5. Italian Diclofenac Study Group: Efficacy of diclofenac eyedrops in preventing postoperative inflammation and long term cystoid macular edema. *J Cataract Refract Surg* 1997, 23:1183–1189.

This study addressed several questions regarding NSAID use during and after cataract extraction. The findings were as follows. No difference was noted in inflammation between post-ECCE eyes treated with diclofenac ($n = 141$) and a control group ($n = 140$) receiving a 5-day postoperative course of dexamethasone followed by placebo. Pupil size in the diclofenac group ($n = 141$) was significantly larger ($P < 0.05$) than pupil size in the control group ($n = 140$) at aspiration during ECCE. There was no significant difference in intraocular pressure between eyes treated with diclofenac and control eyes, and no statistically significant difference between burning and blurry vision as assessed by patient questionnaire after instillation of diclofenac or placebo. A statistically significant decrease in incidence of CME was noted at 36 and 140 days postoperatively ($P = 0.033$ and $P = 0.05$, respectively).

6. Roberts CW: A comparison of diclofenac sodium to fluorobipropfen for the inhibition of surgically induced miosis. *J Cataract Refract Surg* 1996, 22 (suppl1):780–787.
7. Gimbel HV: The effect of treatment with topical nonsteroidal anti-inflammatory drugs with and without intraoperative epinephrine on the maintenance of pupillary mydriasis during cataract surgery. *Ophthalmology* 1989, 96:585–588.
8. Fricke JR, Angelocci D, Fox K, McHugh D, Bynum L, Yee JP, et al.: Comparison of the efficacy and safety of ketorolac and meperidine in the relief of dental pain. *J Clin Pharmacol* 1992, 32:376–384.
9. Arshinoff S, D'Addario D, Sadler C, Bilotta R, Johnson TM, et al.: Use of topical non steroidal anti-inflammatory drugs in excimer laser photorefractive keratectomy. *J Cataract Refract Surg* 1994, 20:216–222.
10. Sher NA, Barak M, Daya S, DeMarchi J, Tucci A, Hardten DR, et al.: Excimer laser photorefractive keratectomy in high myopia: a multicenter study. *Arch Ophthalmol* 1992, 110:935–943.
11. Sher NA, Frantz JM, Talley A, Parker P, Lane SS, Ostrov C, et al.: Topical diclofenac in the treatment of ocular pain after excimer photorefractive keratectomy. *Refract Corneal Surg* 1993, 9:425–436.
12. Flach AJ, Kraff MC, Sanders DR, Tanenbaum L: The quantitative effect of 0.5% ketorolac tromethamine solution and 0.1% dexamethasone sodium phosphate solution on postsurgical blood-aqueous barrier. *Arch Ophthalmol* 1988, 106:480–483.

13. Flach AJ, Graham J, Kruger LP, Stegman RC, Tanenbaum L: Quantitative assessment of postsurgical breakdown of the blood-aqueous barrier following administration of 0.5% ketorolac tromethamine. *Arch Ophthalmol* 1988, 106:344–347.
14. Ostrov CS, Sirkin SR, Deutsch WE, Masi RJ, Chandler JW, Lindquist TD: Ketorolac, prednisolone, and dexamethasone for postoperative inflammation. *Clin Ther* 1997, 19:259–272.

There was no difference between ketorolac ($n = 56$), prednisolone ($n = 58$), and dexamethasone ($n = 41$) with respect to indicators of inflammation (ie, slit-lamp examination and laser cell and flare meter) after cataract extraction. Ketorolac also showed greater efficacy than either prednisolone or dexamethasone against breakdown of blood-aqueous barrier by photofluorometrics at day 5 and week 2 ($P < 0.001$ and $P = 0.016$, respectively).

15. Roberts CW: A comparison of non-steroidal anti-inflammatory drugs to steroids for postoperative inflammation [abstract]. *Ophthalmology* 1992, 99:122.
 16. Roberts CW: Voltaren ophthalmic is as effective as Pred Forte for post cataract inflammation. Presented at IXth Congress of Societas Ophthalmologica Europaea, May 23–28, 1992.
 17. Roberts CW: Voltaren ophthalmic is as effective as Pred Forte for post cataract inflammation. Presented at American Society of Cataract and Refractive Surgery, April 12–15, 1992.
 18. Roberts CW, Brennan KM: A comparison of topical diclofenac sodium with prednisolone acetate for post cataract inflammation. *Arch Ophthalmol* 1995, 113:725–727.
 19. Roberts CW, Brennan KM: A comparison of topical diclofenac with prednisolone for post cataract inflammation. *Arch Ophthalmol* 1995, 113:725–727.
 20. Flach AJ, Stegman RC, Graham J, Kruger LP: Prophylaxis of aphakic cystoid macular edema without corticosteroids. *Ophthalmology* 1990, 97:1253–1258.
 21. Flach AJ, Jampol LM, Weinberg D, Kraff MC, Yannuzzi LA, Campo RV, et al.: Improvement in visual acuity in chronic aphakic and pseudophakic cystoid macular edema after treatment with topical 0.5% ketorolac tromethamine. *Am J Ophthalmol* 1991, 112:514–519.
 22. Donnenfeld ED, Selkin BA, Perry HD, Moadel K, Selkin GT, Cohen A, et al.: Controlled evaluation of bandage contact lens and topical non-steroidal anti-inflammatories in the treatment of traumatic corneal abrasions. *Ophthalmology* 1995, 102:979–984.
 23. Jayamanne DGR, Fitt AW, Dayan M, Andrews RM, Mitchell KW, Griffiths PG: The effectiveness of topical diclofenac in relieving discomfort following traumatic corneal abrasions. *Eye* 1997, 11:79–83.
- Patients with traumatic corneal abrasions treated with diclofenac ($n = 20$) had statistically significant ($P < 0.02$) less pain as assessed by an objective patient questionnaire than patients with traumatic corneal abrasion and no treatment ($n = 20$).
24. Tinkelman DG, Rupp G, Kaufman H, Pugely J, Schultz N: Double-masked, paired-comparison clinical study of ketorolac tromethamine 0.5% ophthalmic solution compared with placebo eyedrops in the treatment of seasonal allergic conjunctivitis. *Surv Ophthalmol* 1993, 38:133–140.
 25. Ballad Z, Blumenthal M, Tinkelman DG, Kriz R, Rupp G: Clinical evaluation of ketorolac tromethamine 0.5% ophthalmic solution for the treatment of seasonal allergic conjunctivitis. *Surv Ophthalmol* 1993, 38:141–148.
 26. Laibovitz RA, Koester J, Schaich L, Reaves TA: Safety and efficacy of diclofenac sodium 0.1% ophthalmic solution in acute seasonal allergic conjunctivitis. *J Ocul Pharmacol Ther* 1995, 11:361–368.
 27. Wood T, Steward R, Bowman R: Suprofen treatment of contact lens associated GPC. *Ophthalmology* 1988, 96:822–829.
 28. Buckley DC, Caldwell DR, Reaves TA: Treatment of vernal conjunctivitis with suprofen [abstract]. *Invest Ophthalmol Vis Sci* 1986, 27:29.
 29. Snyder RW: The effects of topical antibiotics NSAIDs on epithelial wound healing in a PRK animal model. Presented to The Castroviejo Cornea Society, Chicago, IL, October 26, 1996.
 30. Flach AJ: Cyclo-oxygenase inhibitors in ophthalmology. *Surv Ophthalmol* 1992, 36:264.