

# Keratitis, Ulceration, and Perforation Associated with Topical Nonsteroidal Anti-inflammatory Drugs

Ann C. Guidera, MD,<sup>1,2</sup> Jodi I. Luchs, MD,<sup>1,2</sup> Ira J. Udell, MD<sup>1,2</sup>

**Purpose:** To report corneal complications associated with topical nonsteroidal anti-inflammatory drugs (NSAIDs).

**Design:** Retrospective, noncomparative interventional case series.

**Participants:** Eighteen eyes of 16 patients with adverse corneal events associated with NSAID use.

**Methods:** Evaluation of 16 patients referred for management of corneal complications during use of topical NSAIDs (ketorolac tromethamine [Acular], diclofenac sodium [Voltaren], diclofenac sodium [Falcon DSOS]).

**Main Outcome Measures:** Type and severity of corneal complications.

**Results:** Of the 16 patients, two experienced severe keratopathy, three experienced ulceration, six experienced corneal or scleral melts, and five experienced perforations. Eleven patients had recent cataract surgery; nine of these were on concurrent topical steroids and antibiotics. Another patient who did not have recent surgery was using concurrent topical steroids without antibiotics for sarcoid uveitis. Systemic associations included two patients with rheumatoid arthritis, one patient with asymptomatic Sjogren's syndrome, and two with rosacea.

**Conclusions:** Topical NSAIDs were associated with corneal complications in 18 eyes of 16 patients. Potential risk factors include conditions that predispose the patient to corneal melting, concurrent topical steroids, and epithelial keratopathy in the early postoperative period. *Ophthalmology* 2001;108:936-944 © 2001 by the American Academy of Ophthalmology.

Nonsteroidal anti-inflammatory drugs (NSAIDs) are cyclooxygenase inhibitors with well-established anti-inflammatory, analgesic, and antipyretic effects. Topical formulations of NSAIDs for ophthalmic use became commercially available worldwide by the early 1990s. Currently, their multiple and varied uses in ophthalmology include the inhibition of intraoperative miosis, management of postoperative inflammation, treatment of ocular allergic conditions, and, more recently, the control of pain after photorefractive keratectomy (PRK) and other excimer laser procedures. Nonsteroidal anti-inflammatory drugs are also widely used for the prevention and treatment of postoperative cystoid macular edema (CME) despite the lack of definitive proof of efficacy and without US Food and Drug Administration approval for these indications. There have been multiple reports that NSAIDs decrease the incidence of postoperative angiographic CME,<sup>1-6</sup> as well as improve visual acuity.<sup>7-9</sup>

Topical NSAIDs are often considered a safer alternative

to topical corticosteroids, avoiding the potential undesirable side effects associated with topical steroids, such as elevations in intraocular pressure (IOP), progression of cataracts, increased risk of infection, and worsening of stromal melting. It is well known that topical corticosteroids can suppress the repair process and potentiate corneal ulceration. Although topical NSAIDs have been associated with delayed epithelial healing, to our knowledge there is only one recent report published subsequent to our submitting this paper of corneal ulceration with melting and perforation associated with topical NSAID use.<sup>10</sup>

We describe 16 patients (18 eyes) with corneal complications suspected to be related to the use of topical NSAIDs. Two patients had severe surface toxicity at presentation; the other 14 experienced frank ulcerations. Of these 14, perforations developed rapidly in five (one bilateral) and six experienced corneoscleral or corneal stromal thinning (one bilateral).

Originally received: December 13, 1999.

Accepted: September 11, 2000.

Manuscript no. 99820.

<sup>1</sup>Department of Ophthalmology, Long Island Jewish Medical Center, New Hyde Park, New York.

<sup>2</sup>Long Island Campus, Albert Einstein College of Medicine, New Hyde Park, New York.

Presented in part as a poster at the American Academy of Ophthalmology annual meeting, Orlando, Florida, October 1999.

Reprint requests to Ann C. Guidera, MD, Department of Ophthalmology, Long Island Jewish Medical Center, 600 Northern Boulevard, Suite 214, Great Neck, NY 11021.

## Patients and Methods

Sixteen patients referred for corneal complications while using topical NSAIDs were studied. For each patient, a clinical history was evaluated for concurrent topical medications and preexisting ocular or systemic conditions. When possible, blood tests were performed to screen for autoimmune processes that may predispose patients to corneal complications. Every attempt was made to verify the accuracy of the patients histories, which were primarily obtained from the patient or referring physician.

Table 1. Patient Data

Patient No.	Age (Range, 43–90 yrs)	Gender (M:F, 7:9)	Eye (Right: Left: Bilateral, 8:6:2)
1	52	Male	Right
2	90	Female	Left
3	83	Male	Right
4	76	Female	Right
5	72	Female	Right
6	77	Male	Right
7	86	Male	Right
8	82	Female	Right
9	70	Female	Left
10	43	Male	Right and left
11	67	Female	Left
12	88	Female	Left
13	43	Male	Left
14	62	Female	Right and left
15	79	Female	Right
16	80	Male	Left

**Results**

The 16 patients ranged in age from 43 to 90 years. There were seven men and nine women. Eight cases involved the right eye, six

the left eye, and two were bilateral (Table 1). The findings in the sixteen patients are summarized in Tables 2, 3, and 4.

Severe keratitis developed in two patients (Table 2). One patient had been using ketorolac for 16 days, and the other initially used preserved, then preservative-free, ketorolac for 5 to 6 weeks. Both patients 1 and 2 had slow but complete resolution of their keratitis over several months with return to their baseline vision.

Ulceration of the conjunctiva or cornea without tissue loss developed in three patients (Table 2). These ulcerations were noted in the area of cataract incisions, all within 2 weeks of surgery. All three ulceration patients were receiving diclofenac (diclofenac sodium ophthalmic solution [DSOS]; Alcon, Fort Worth, Texas) with concurrent topical steroids and antibiotics. In two of these three, patients 3 and 4, the ulcerations healed within 10 days of discontinuing diclofenac with excellent postoperative visual acuities of 20/25 and 20/20. Patient 5 moved out of state and was lost to follow-up.

Corneal or scleral melts developed in six patients (Table 3). Five were at the site of clear corneal or scleral tunnel cataract incisions. These five were using diclofenac (DSOS) with concurrent topical steroids and antibiotics. One of these five had used diclofenac (DSOS) before surgery as well. One of the six patients (Patient 10, with sarcoid) had not had recent cataract surgery and experienced bilateral central corneal melting on diclofenac (Voltaren, CIBA Vision, Duluth, Georgia), while using glaucoma medications as well as steroids. In each of these patients, the

Table 2. Keratitis and Ulceration (without Loss of Tissue)

Patient No.	Corneal Complication	Nonsteroidal Anti-inflammatory Drug Regimen	Type of Cataract Surgery	Nonsteroidal Anti-inflammatory Drug Use (Initiation) Duration	Other Medications at Time of Presentation	Treatment Regimen	Associated Conditions
1	Keratitis, right eye, (stromal and epithelial)	Ketorolac four times daily for CME, then nonpreserved ketorolac self-dosed every 2 hrs	Scleral tunnel	(6 wks p/o) 5 wks	None	Tears every 2 hrs ofloxacin twice daily	CME
2	Keratitis, left eye	Ketorolac four times daily	Temporal clear cornea; right eye 7 yrs earlier	(POD 12) 16 days	None	Topical twice daily steroids, nonpreserved tears	Glaucoma (large bleb), dry eyes
3	Ulceration, right eye, of conjunctiva over incision	Diclofenac (DSOS) four times daily	Scleral tunnel	(POD 1) 13 days	Prednisolone, ciprofloxacin	Tobramycin, dexamethasone	Anemia ASCVD
4	Ulceration, right eye, and infiltrate at limbus and peripheral cornea	Diclofenac (DSOS) four times daily	Temporal scleral tunnel	(POD 1) 6 days	Prednisolone, ciprofloxacin	Tobramycin, dexamethasone	None
5	Conjunctival abscess, ulcer, right eye, with infiltrate; culture neg	Diclofenac (DSOS) four times daily	Clear cornea; OS 3 wks earlier, same meds, no problems	(POD 1) 11 days	Prednisolone, ciprofloxacin	Neomycin, polymyxin B, gramacidin, ciprofloxacin, bacitracin; then fort antibiotics, prednisolone, bacitracin	None

ASCVD = atherosclerotic cardiovascular disease; CME = cystoid macular edema; DSOS = diclofenac sodium ophthalmic solution (Alcon Pharmaceuticals); OS = left eye; POD = postoperative day.

Table 3. Corneal and Scleral Melts

Patient No.	Corneal Complication	Nonsteroidal Anti-inflammatory Drug Regimen	Type of Cataract Surgery	Nonsteroidal Anti-inflammatory Drug Use (Initiation) Duration	Other Medications at Time of Presentation	Treatment Regimen	Associated Conditions/Rheumatoid Status (If Known)
6	Melt, right eye, of sclera with conjunctival defect; culture negative	Diclofenac (DSOS) four times daily	Temporal scleral tunnel	(POD 2) 10 days	Rimexolone, ciprofloxacin	Discontinue diclofenac, more ciprofloxacin, less rimexolone	ABM dystrophy
7	Melt, right eye, at cataract wound and ulceration at sideport; culture negative	Diclofenac (DSOS) four times daily	Temporal clear cornea	(POD 1) 18 days	Prednisolone, ciprofloxacin	BSCL, topical antibiotics	Rosacea, NIDDM, heart disease, -ANA, -RF, -Sjögren's Ab
8	Melt at scleral tunnel noted at vitrectomy; culture negative	Diclofenac (DSOS) four times daily	Scleral tunnel, retained nucleus	(POD 1) 1 mo	Prednisolone, ciprofloxacin, timolol, dorzolamide, cyclogyl	Discontinue diclofenac	Glaucoma
9	Melt, left eye, at cataract wound	Diclofenac (DSOS) four times daily	Temporal clear cornea; right eye 15 mos earlier with CME treated with diclofenac, <sup>6</sup> no problems	(POD 1) 3.5 mos (ulceration first noted at day 6)	Neomycin, polymyxin B, dexamethasone	Discontinue diclofenac	IDDM, RA
10	Central melt, right eye Central melt, left eye	Diclofenac (Voltaren) Diclofenac (Voltaren)	N/A	19 days	Fluoromethalone, betaxolol, hyoscine	Glue/BSCL, topical antibiotics, lubricating ointment	Sarcoid uveitis, scar, SPK, IDDM
11	Ulceration, melt, left eye, and infiltration; culture negative	Diclofenac (DSOS) twice daily	Temporal clear cornea; right eye 1/99, no nonsteroidal anti-inflammatory drugs, no problems	(2 mos after surgery) 3 wks	Tobramycin, tears	Topical antibiotics	None

ABM = anterior basement membrane; ANA = antinuclear antibodies; BSCL = bandage soft contact lens; CME = cystoid macular edema; DSOS = diclofenac sodium ophthalmic solution (Alcon); IDDM = insulin-dependent diabetes mellitus; N/A = not applicable; NIDDM = non-insulin-dependent diabetes mellitus; POD = postoperative day; RA = rheumatoid arthritis; RF = rheumatoid factor; SPK = superficial punctate keratopathy.

epithelium healed 2 weeks to several months after stopping diclofenac, with stable thinning of 50% to 80% of stromal thickness. Patient 6 achieved a visual acuity of 20/25. Patient 7 healed with 50% thinning and a visual acuity of 20/30 with his native cylinder. Patient 8 was lost to follow-up. Patient 9 healed with 80% thinning and a visual acuity of 20/30, with significantly increased cylinder. Patient 10 experienced central corneal scarring and thinning with visual acuities of 20/100 and counting fingers. Patient 11 had corneal decompensation with a visual acuity of counting fingers.

Perforations developed in five patients (Table 4). One was at the site of a scleral tunnel cataract incision. This patient had been

receiving diclofenac (DSOS), topical steroids, antibiotics, and glaucoma medications, and required a pericardial patch graft. One month after surgery, visual acuity was 20/50. Four patients experienced central perforations requiring corneal transplant surgery. Two were using ketorolac and one was using preservative-free ketorolac. None of these four central corneal perforation patients had been taking concurrent steroids. All have clear grafts with postoperative visions of roughly 20/70.

Representative case reports of patients with keratitis, ulceration with melt, and scleral and corneal perforations are presented. All cases are presented in the tables.

Table 4. Corneal and Scleral Perforations

Patient No.	Corneal Complication	Nonsteroidal Anti-inflammatory Drug Regimen	Type of Cataract Surgery	Nonsteroidal Anti-inflammatory Drug Use (Initiation) Duration	Other Medications at Time of Presentation	Treatment Regimen	Associated Conditions/Rheumatic Status (If Known)
12	Perforation, left eye, at scleral tunnel; culture negative	Diclofenac (DSOS) four times daily	Scleral tunnel; other eye, no nonsteroidal anti-inflammatory drugs, no problems	(POD 2) 18 days	Prednisolone, tobramycin, atropine, timolol, latanaprost	Patch graft	Atrial fibrillation/+RA
13	Central perforation	Ketorolac as required	N/A	3 wks	None	PK	Rosacea/weakly +ANA, -RF -Sjögren's AB
14	Central perforation, left and right eyes; culture negative	Nonpreserved ketorolac	N/A	4 days	None	PK both eyes	Previously undiagnosed Sjögren's, +ANA, +RF
15	Central perforation, right eye	Ketorolac as required	N/A	1 mo	Tears as required	PK	Old scar, epithelial downgrowth/weakly +ANA, -RF, -Sjögren's AB
16	Corneal perforation, left eye	Diclofenac (Voltaren), then diclofenac (DSOS) twice daily	N/A	10 mos 5 mos	Ofloxacin each hr	PK	CME <sup>6</sup> , -ANA, -RF

ANA = antinuclear antibodies; CME = cystoid macular edema; DSOS = diclofenac sodium ophthalmic solution (Alcon); N/A = not applicable; PK = penetrating keratoplasty; POD = postoperative day; RA = rheumatoid arthritis; RF = rheumatoid factor.

## Case Reports

### Patient 1

A 52-year-old male underwent uncomplicated phacoemulsification cataract surgery with posterior chamber lens implantation in the right eye. Postoperative best-corrected visual acuity was 20/15. Six weeks later, his vision in the right eye decreased to 20/100-2 as a result of angiographically proven CME. He was treated with ketorolac and prednisolone acetate (Pred Forte, Allergan, Irvine, CA), both four times daily. The vision improved to 20/20-1 over the next 3 weeks, at which time he was instructed to taper off both drops.

After 5 weeks of topical NSAID use, he sought treatment for cloudy vision that he had been experiencing for 2 weeks. Central, disciform-like stromal edema with mild microcystic edema was present, and the acuity was decreased to 20/60-3. He was still taking prednisolone acetate and ketorolac once daily, which he was instructed to stop, and started sodium chloride (Muro 128, Bausch & Lomb, Tampa) 2% solution four times daily in the right eye. However, he continued to take ketorolac, up to every 2 hours, partially for pain relief (Figs 1 and 2).

One week later, he sought treatment for extreme pain in the right eye with increasingly blurry vision over 2 weeks. Medicamentosa was suspected as a result of ketorolac toxicity. Ketorolac was discontinued. A pressure patch was placed the following day because of pain from the punctate epithelial keratitis surrounding

the central plaque-like epithelial lesion. Descemet's striae were present.

Three days later, the cornea was slightly clearer surrounding the central plaque. Ultrasound pachymetry (Sonogage, Chiron, Ophthalmics) was 0.621 in the right eye and 0.540 in the left eye. He was treated with ofloxacin (Ocuflox) and prednisolone acetate twice daily, and he improved slowly.

### Patient 7

An 86-year-old man with non-insulin-dependent diabetes mellitus and a history of atherosclerotic heart disease underwent uneventful cataract surgery in the right eye by phacoemulsification through a temporal clear corneal incision under peribulbar anesthesia. On the first postoperative day, the patient had an elevated IOP and was placed on betaxolol (Betoptic, Alcon, Fort Worth, TX) and brimonidine (Alphagan, Allergan, Irvine, CA) in addition to prednisolone four times daily, ciprofloxacin (Ciloxan, Alcon, Fort Worth, TX) four times daily, and diclofenac (DSOS) four times daily. He had also been pretreated with diclofenac (DSOS) four times daily for 1 day before surgery. Three days after surgery, his IOP was well controlled, and both betaxolol and brimonidine were discontinued. At a routine postoperative visit 2.5 weeks after surgery, the patient was asymptomatic, but was found to have ulcerations with corneal thinning at the sites of the cataract wound and sideport incision. The patient was referred to Long Island Jewish Medical Center Cornea Service.

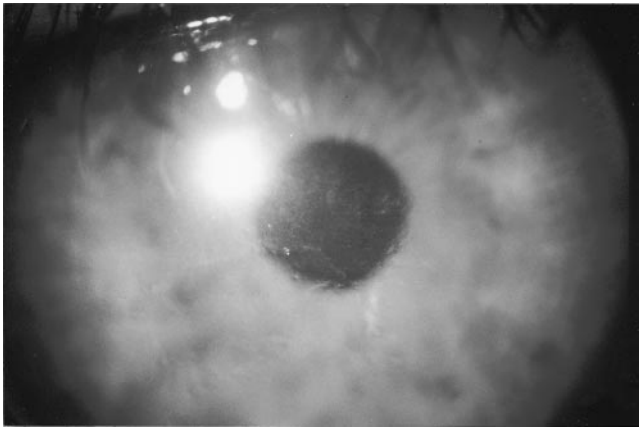


Figure 1. Patient 1. The photograph shows severe stromal and epithelial keratitis.

On examination, the patient's visual acuity was counting fingers at 3 feet, pinholing to 20/80 in the right eye and 20/50 in the left eye. Slit-lamp examination of the right eye revealed diffuse superficial punctate keratopathy and localized corneal ulceration at both the temporal cataract wound (50% thinned) and the 12-o'clock SidePort incision (Figs 3 and 4). There was a moderate anterior chamber reaction. He was noted to have facial features suggestive of rosacea.

Cultures were sent that later showed no growth. The diclofenac (DSOS) was discontinued and topical steroids were tapered. Topical antibiotics were increased to one drop every 2 hours while awake. One week later, the patient had persistent epithelial defects with stable stromal thinning at the temporal clear corneal cataract incision. A bandage soft contact lens was placed for several weeks, topical antibiotics were tapered, and doxycycline 50 mg orally twice daily was added. The epithelium healed very slowly over 1 month, with stable thinning. Four months after surgery, the patient was correctable to 20/30 in the right eye with his native cylinder.

### Patient 12

An 88-year-old woman with a history of rheumatoid arthritis and atrial fibrillation underwent uneventful cataract surgery of the left eye by phacoemulsification through a scleral tunnel incision. She had an elevated IOP with significant inflammation on her first postoperative day and was treated with timolol (Timoptic, Merck, West Point, PA) and latanoprost (Xalatan, Pharmacia & Upjohn,

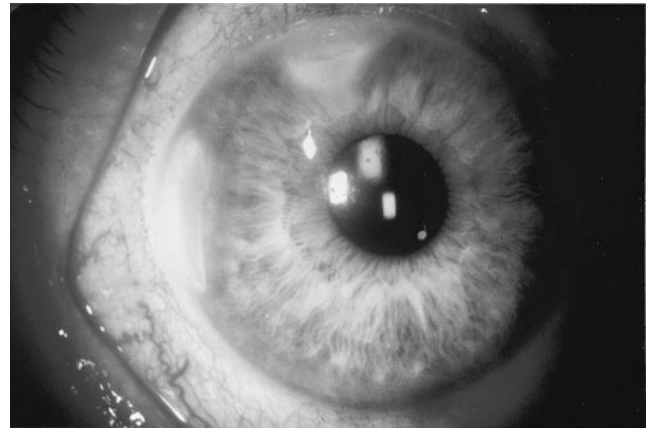


Figure 3. Patient 7. The photograph shows corneal ulceration and melt at clear corneal cataract and SidePort incisions.

Peapack, NJ) in addition to prednisolone acetate 1% every 2 hours, tobramycin four times daily, and diclofenac (DSOS) four times daily. One week after surgery, her IOP was controlled and the timolol, the latanoprost, and the tobramycin were discontinued. Three weeks after surgery, she was noted to have anterior lamellar melting of the scleral tunnel incision. Pred Forte was discontinued, and diclofenac was increased to every 3 hours. Ofloxacin every hour was added. Over 2 days, melting progressed to become Seidel positive with pressure, and the patient was referred to LIJ (Fig 5).

Cultures were taken which later revealed no growth. The diclofenac (DSOS) was discontinued. Fortified cefazolin and fortified tobramycin were started every hour while awake in place of the ofloxacin. Oral ciprofloxacin 250 mg orally bid was added. Because of persistent leak and progressive hypotony despite medical therapy and a trial of a bandage soft contact lens, a patch graft of pericardial tissue was performed over the site of the thinning scleral tunnel incision and adjacent limbal area. One month later, the patient was improved with a visual acuity of 20/50 (Fig 6).

Of note, the patient had undergone cataract surgery in the right eye 1 year earlier, was treated after surgery with topical steroids but not topical NSAIDs, and had an uneventful postoperative course.

### Patient 14

A 62-year-old woman with a history of dry eyes, suspected glaucoma, and cataracts experienced irritation of both eyes. Her med-

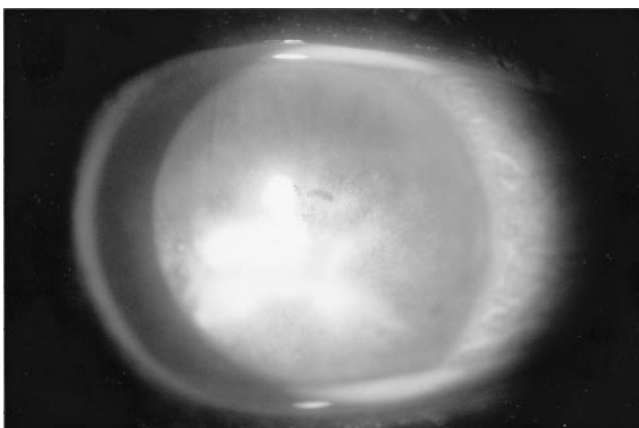


Figure 2. Patient 1. The photograph shows fluorescein staining.

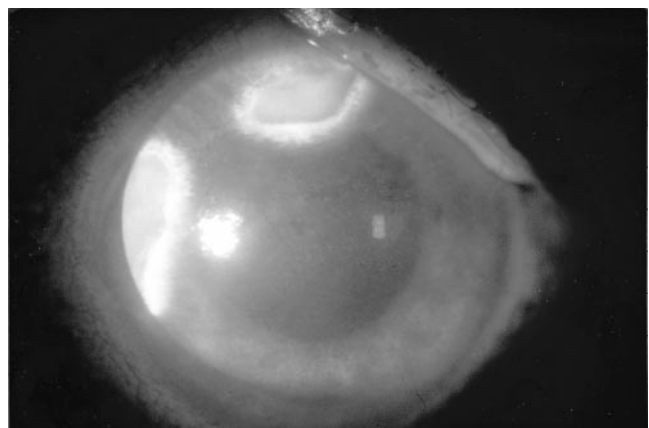


Figure 4. Patient 7. The photograph shows fluorescein staining.

# Explore Litigation Insights

Docket Alarm provides insights to develop a more informed litigation strategy and the peace of mind of knowing you're on top of things.

## Real-Time Litigation Alerts



Keep your litigation team up-to-date with **real-time alerts** and advanced team management tools built for the enterprise, all while greatly reducing PACER spend.

Our comprehensive service means we can handle Federal, State, and Administrative courts across the country.

## Advanced Docket Research



With over 230 million records, Docket Alarm's cloud-native docket research platform finds what other services can't. Coverage includes Federal, State, plus PTAB, TTAB, ITC and NLRB decisions, all in one place.

Identify arguments that have been successful in the past with full text, pinpoint searching. Link to case law cited within any court document via Fastcase.

## Analytics At Your Fingertips



Learn what happened the last time a particular judge, opposing counsel or company faced cases similar to yours.

Advanced out-of-the-box PTAB and TTAB analytics are always at your fingertips.

## API

Docket Alarm offers a powerful API (application programming interface) to developers that want to integrate case filings into their apps.

## LAW FIRMS

Build custom dashboards for your attorneys and clients with live data direct from the court.

Automate many repetitive legal tasks like conflict checks, document management, and marketing.

## FINANCIAL INSTITUTIONS

Litigation and bankruptcy checks for companies and debtors.

## E-DISCOVERY AND LEGAL VENDORS

Sync your system to PACER to automate legal marketing.