

# History of Cataract Surgery

---

Norman S. Jaffe, MD

Several philosophers have reminded us that those who forget the mistakes of the past are destined to repeat them in the future. In this historical survey, it is hoped that the knowledge we inherited will be an incentive for us to continue to strive to improve the quality of life of our patients.

The earliest recorded ophthalmologic reference to be found dates back to Babylonia-Assyria (2250 B.C.) in the Code of Hammurabi, which is a legal document concerned with civil laws administered by the Babylonian king, Hammurabi.

The origin of the term *cataract* is interesting, but according to Celsus,<sup>1</sup> the term is logical because it means a waterfall or flowing down. It was believed that a cataract was an inspissated humor that had seeped from the brain into the space between the cornea and the iris. Rufus,<sup>2</sup> the author of the earliest anatomy book (*On Naming the Parts of the Human Body*) was the first to use the term *crystalline lens*.

Jacques Daviel<sup>3</sup> (Fig 1) started a revolution in ophthalmic surgery on April 8, 1747. A couching procedure failed, so through an inferior corneal incision, he inserted a needle behind the lens and delivered it with some loss of vitreous. This was the first report of cataract extraction from its normal position behind the iris. In 1753, he presented one of the landmark articles<sup>4</sup> in ophthalmic history to the Royal Academy of Surgery. He reported 115 cataract extractions with 100 successes. By 1756, he had performed 434 extractions with only 50 failures.<sup>5</sup> Because Daviel opened the anterior capsule, this was an extracapsular extraction. It is remarkable that the intracapsular method was born during this same period. Samuel Sharp<sup>6</sup> (1753) of London and George de la Faye<sup>7</sup> (1752) are credited with the first such procedures. Sharp expelled the lens from the eye by pressure of his thumb. Shortly thereafter, a more direct method was adopted by Richter<sup>8</sup> (1773), who pushed the lens out after impaling its posterior pole with a needle thrust through the sclera. This method was also used by Beer<sup>9</sup> and von Canstatt.<sup>10</sup> A. and H. Pagenstecher<sup>11,12</sup> (1866–1871) introduced the method of removing the lens with a spoon. Alternate techniques included pressure on the globe by instruments,

such as a curette,<sup>13</sup> a spoon,<sup>14</sup> or a strabismus hook, a method popularized by Col. Henry Smith<sup>15</sup> (1900–1926).

Many distinguished surgeons of that time continued to use the old procedure of couching (Fig 2), a technique that did not die easily. It continued to be used well into the second half of the 19th century, primarily because of the technical complexity of the new procedures and the high rate of postoperative infections.

Although the extracapsular and intracapsular methods were developed at nearly the same time, it took much longer for the latter to gain popularity. The earlier intracapsular techniques involved expression of the entire lens with its capsule intact by some form of pressure on the globe, either with a thumb or with an instrument, but because of the high rate of vitreous loss, techniques were designed to remove the lens using traction.

Mention should be made also of the first attempt at intraocular lens implantation. It has been reported<sup>16–18</sup> that Casanova (1725–1798) referred in his memoirs to the Italian oculist Tadini, who discussed with him the idea of implanting an artificial lens after a cataract surgery in 1764 to 1765. Casanova is said to have passed this idea on to the Dresden court ophthalmologist Casaamata. Around 1795, Casaamata did, indeed, attempt to introduce a glass lens into an eye after a cataract surgery, but the lens immediately slid posteriorly toward the retina. But despite this problem, it is still remarkable that this attempt preceded Ridley's first case by more than 150 years.

## The Last 100 Years

---

The Centennial anniversary of the American Academy of Ophthalmology (formerly known as the American Academy of Ophthalmology and Oto-laryngology) is celebrated in 1996. No other surgical specialty has been so dominated by a single surgery as has ophthalmology by cataract extraction. Old concepts change, and new ideas are plentiful in all fields of science and medicine; cataract surgery is no exception. However, when one considers the progress in cataract surgery during the past 100 years, it is clear that the previous 8000 years produced few dynamic changes, except for the switch from couching to cataract extraction.

In the first decade of the Academy, what was known as simple cataract extraction (i.e., extracapsular) was the procedure of choice. This is despite the fact that the in-

---

From Bascom Palmer Eye Institute, University of Miami School of Medicine, Miami.

Reprint requests to Norman S. Jaffe, MD, 5130 Linton Blvd, Delray Beach, FL 33484.



Figure 1. Daviel's first surgery for cataract. Daviel is seen ready to perform surgery on Brother Felix, the hermit of Aiguill en Provence, on April 8, 1745. (Reprinted with permission from Duke-Elder S. *System of Ophthalmology*, Vol. XI. St. Louis: CV Mosby Co, XI;253.)

tracapsular method was gaining favor among the more experienced cataract surgeons of the time. No matter the method favored, considerable attention was directed toward improving the success rate of the surgery. Surgeons of today should appreciate the statement made by DW Greene<sup>19</sup> at the 1905 Academy meeting, a statement that still applies in 1996:

"A well conceived and properly executed extraction is probably the acme of surgical skill. No other surgery approaches it in definiteness of conception, delicacy of execution, in the nicety with which the different steps are carried out, the object to be attained, and lastly, the contentment and joy it has brought to humanity. Other surgeries relieve suffering, some prolong life, and some correct deformity, but the extraction of the opaque lens does all of these and more."

The simple cataract extraction consisted of opening the anterior capsule and expressing the nucleus. This is the essence of a planned extracapsular cataract extraction (ECCE) as performed today, but the similarity ends. There were dozens of methods for the anterior capsulectomy, but none were considered ideal. H. Knapp<sup>20</sup> stated at the 1905 Academy meeting, "I saw that the capsule was the most difficult factor in the cataract operation. In one of the periodical statistical reports of my cataract operations, I said: 'The man who invents a safe method of removing the central part of the anterior capsule will be the greatest benefactor of the hosts of countless old blind people.'" Homer Smith<sup>21</sup> echoed these comments during the 1906 Academy meeting: "It is admitted that the latter (capsulotomy) is the most difficult and dangerous step in the operation."

## Preliminary Iridectomy

During the first 20 years of Academy history, the question of whether an iridectomy done a few days or weeks before lens extraction was advantageous in the average case remained unanswered. Reber<sup>22</sup> gave an excellent summary of the views of ophthalmologists on this subject in 1907. He sent letters to 160 American ophthalmologists asking whether they did a preliminary iridectomy, and, if so, why. Well over one half of the respondents favored the preliminary iridectomy.

## Preliminary Capsulotomy

The main advantage of a preliminary capsulotomy performed hours, days, or even weeks before lens extraction was in cases of immature cataract. In the senile form, mature referred to the condition of the lens cortex. It was well known that nuclear cataracts often progressed slowly, leaving many patients with a prolonged period of visual disability. Some ophthalmologists of that era used a needle or a knife-needle to open the anterior capsule and allow

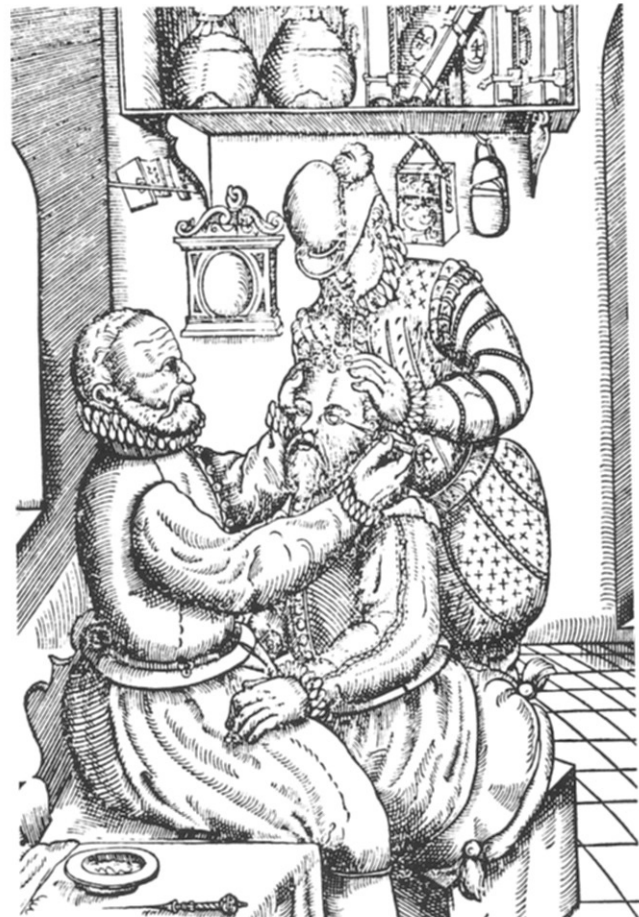

Figure 2. Couching for cataract as performed in Medieval Europe and practiced by Bartisch. (Reprinted with permission from Bartisch G. *Ophthalmodouleia, das ist, Augendienst*. Dresden: Matthes Stocke, 1583.)

the relatively clear lens cortex to opacify. This was best done with an ab externo puncture so that the anterior chamber remained formed. The capsulotomy occasionally was combined with a preliminary iridectomy. However, many ophthalmologists shied away from this, among them DW Greene,<sup>23</sup> who stated at the 1908 Academy meeting, "For the extraction of immature cataract, the method (Smith's intracapsular cataract extraction [ICCE] operation) is superior to any process of artificial ripening and extraction afterward."

It was agreed by many ophthalmologists that a secondary cataract was inevitable, and that no matter which technique was used for the anterior capsulectomy, there was no way to prevent it. Among these were C. Barck<sup>24</sup> at the 1903 Academy meeting, and Hotz<sup>25</sup> and H. Knapp<sup>20</sup> at the 1905 Academy meeting. As a result, some surgeons performed a puncture of the posterior capsule as a routine procedure, whereas others did a posterior capsulotomy only if a central opacity in the capsule was observed during the surgery. It was considered an advantage if this was associated with a forward pressure of the vitreous to realign the wound margins. If vitreous was seen at the incision, it merely was snipped off.

After the anterior capsulectomy, expression of the nucleus was performed. One method consisted of retracting the upper eyelid with an instrument held in the surgeon's left hand, while the thumb of the right hand pressed against the globe at the inferior limbus in an anteroposterior direction. When the edge of the nucleus presented through the incision, an assistant rolled the nucleus out of the eye with a spatula.

An interesting comment was made by DW Greene<sup>26</sup> at the 1910 Academy meeting. Keep in mind that this was said in 1910. One cannot hear such a statement today. This statement was:

"...men who discuss this subject seem to think the question of the future of the cataract operation is settled. So far as the old operation (i.e., ECCE) is concerned, this may be true, it having been practiced since 1753, now 157 years, it has probably reached its limits of improvement in technic and visual results."

As noted previously, the intracapsular method was developed at nearly the same time as was the extracapsular technique, but it never enjoyed much popularity because it was considered to be too technically demanding and was associated with a high incidence of vitreous loss and postoperative infection. Results did improve, however, when techniques were introduced that allowed intracapsular lens extraction using traction.

Various methods of applying traction gained popularity. Phacoeresis involved lens extraction with a suction cup, as originally used by Stoewer<sup>27</sup> (1902) and Hulen<sup>28</sup> (1910). This technique became more sophisticated when I. Barraquer<sup>29-32</sup> (1917-1924) designed an erisophake controlled by an electric pump. This was later simplified by Dimitry<sup>33</sup> (1933), who used suction with a syringe, and Bell<sup>34</sup> (1948), who designed a stiff rubber bulb for this purpose. Another method was that of Lacarrère<sup>35</sup> (1932), who used diathermo-coagulation with a double-pronged needle. Finally, the

very popular cryoextraction technique was introduced by Krwawicz<sup>36</sup> (1961).

Early meetings of the American Academy of Ophthalmology and Oto-laryngology included many presentations that contributed to the progress of intracapsular lens extraction. Many of these built on the work of Henry Smith, who in 1960 had published an article in the *Indian Medical Gazette of Calcutta*.<sup>37</sup> Smith was a civil surgeon at Jullundur, Punjab, North India. He advised a return to the method of extracting the lens in its capsule by external manipulation.

At the 1906 Academy meeting, DW Greene<sup>38</sup> lamented the fact that one had to wait for ripening of a cataract before surgery (i.e., ECCE) could be done. After a presentation by Smith on a visit to the United States, Greene, accompanied by D. Vail, left for India. There they worked with Smith and performed the Indian surgery under the tutelage of the master. Upon their return, Greene published a paper (in 1910)<sup>39</sup> on the Smith surgery. Vail, at the 1910 Academy meeting, presented a paper<sup>40</sup> and gave a detailed lantern demonstration of the unmodified Smith surgery (Figs 3-6). Clark, who had arrived in India 2 weeks before Greene and Vail, also reported on the Smith surgery.<sup>41</sup>

At approximately this same time, there also was some discussion as to whether a mature unilateral cataract should be removed. The advantages of such surgery included removal of cosmetic blemish (in the case of a white cataract), increased visual field, and avoidance of the sequelae of a hypermature cataract.

Because of the relatively high incidence of postoperative iris prolapse, there was renewed interest in using a corneal

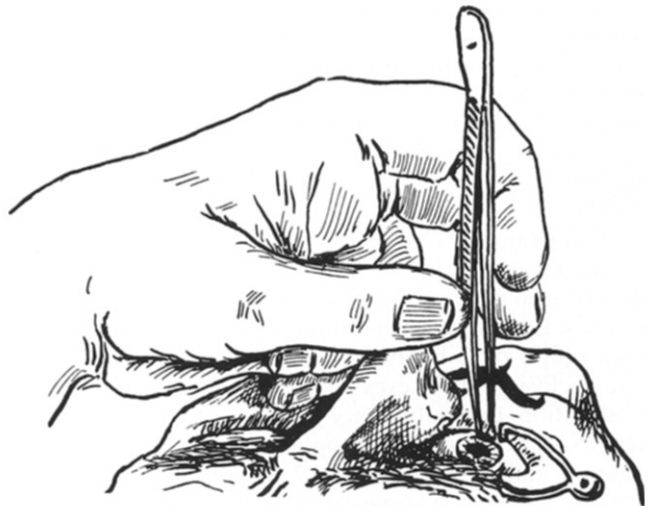
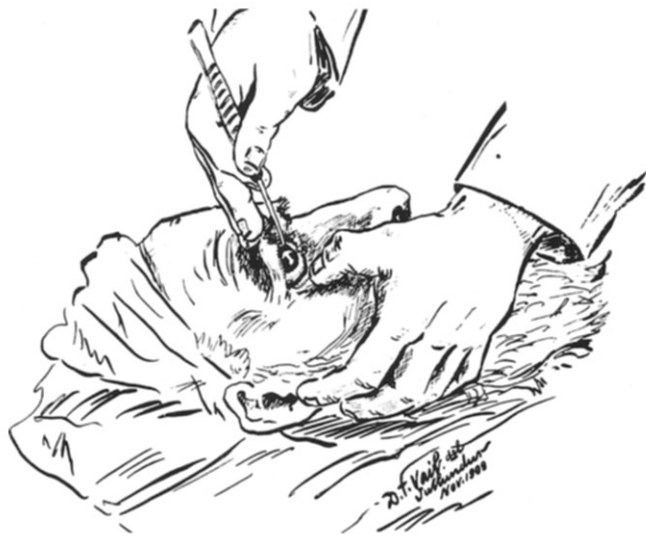

Figure 3. Smith surgery for cataract. The operator's left hand is shown in the act of grasping the conjunctiva below the cornea before section, while he is steadying his hand on the side of the patient's nose and, incidentally, steadying the patient's face. At this stage, the assistant applies the thumb of his right hand to the eyebrow to keep it under control during the section about to be made. (Reprinted with permission from Vail DT. Lantern demonstration of the unmodified Smith surgery for cataract. *15th Meeting of the Transactions of the American Academy of Ophthalmology and Otolaryngology* 1910; 72-97.)



**Figure 4.** Sketched at Jullundur, India. Notice the straight position of all the fingers of the right hand, the hook being held between the thumb and index finger and elbow high. The thumb of the left hand is flexed in depressing the lower lid, while the palm of the left hand and the fingers are grasping the cheek and jaw to steady the patient's head. The handle of the instrument is directed a little toward the crown of the patient's head. (Reprinted with permission from Vail DT. Lantern demonstration of the unmodified Smith surgery for cataract. *15th Meeting of the Transactions of the American Academy of Ophthalmology and Otolaryngology* 1910; 72-97.)

suture (silk or cotton at that time) to close the wound. Williams,<sup>42</sup> Kalt,<sup>43</sup> and Suarez de Mendoza<sup>44</sup> advocated sutures in the 1890s. EC Ellett<sup>45</sup> addressed this subject at the 1911 Academy meeting, where he reviewed previous techniques and presented his own. Kalt<sup>46</sup> modified the suture technique and reported on 2000 cases. He stated that prolapse of the iris occurred in 10% to 12% of cases after simple extraction (i.e., ECCE) without a suture in the hands of excellent surgeons. In his earlier cases with a suture, Kalt reported the incidence was 6%, but with his improved technique, this dropped to 3% in his last 1100 cases.

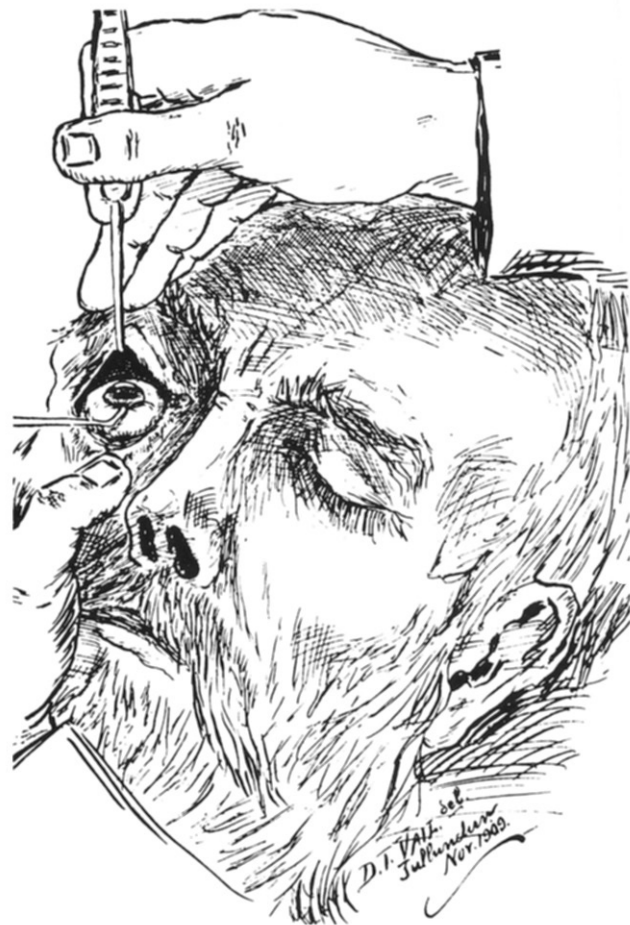At the same 1911 Academy meeting, GF Keiper<sup>47</sup> presented an interesting paper on cataract surgeries in the eyes of aged patients. Surgeons of today might be amused to learn that such surgery among the elderly was considered rather risky because the prolonged forced bed rest and occlusion of the eyes often led to delirium, prostatic obstruction, and pulmonary problems. He addressed letters to approximately 300 ophthalmologists around the country and found that only 7 patients older than 100 years of age had undergone cataract surgery. All seven were women. To appreciate the changes in life span during the past 75 years, actuarial data from 1911 are listed in Table 1; consider the incidence of surgery in these age groups today.

Discussions regarding the cataract surgery of choice continued for the next 20 years. It was generally agreed on that the intracapsular method was preferable if the incidence of intraoperative loss of vitreous could be low-

ered. The next evolutionary step beyond the Smith Indian method was offered by Stanculeanu<sup>48</sup> of Bucharest. Experience with this method was reported by WL Simpson<sup>49</sup> at the 1912 Academy meeting. Using smooth, curved capsule forceps, the anterior capsule was grasped, and movements were made from side to side and up and down until the zonular fibers gave way. The forceps then were opened and removed, and the lens was expressed by pressure with a spoon over the cornea slightly below the center, with slight counter pressure above the wound. If the capsule ruptured, the older method of nuclear expression was used.

During this era, it was in vogue not to remove the surgical bandage for several days after the procedure. The only useful purpose for occluding the eye was to prevent trauma, and by the 1916 Academy meeting, JW Millette<sup>50</sup> was a vocal proponent for not using binocular dressings and allowing quicker ambulation.

Knowledge of the management and consequences of vitreous loss was rather meager, as expressed at the 1920



**Figure 5.** Spectator's view. The lids are being held by the assistant, and the hook for expelling the lens is applied. This provides adequate exposure for the surgeon. (Reprinted with permission from Vail DT. Lantern demonstration of the unmodified Smith surgery for cataract. *15th Meeting of the Transactions of the American Academy of Ophthalmology and Otolaryngology* 1910; 72-97.)

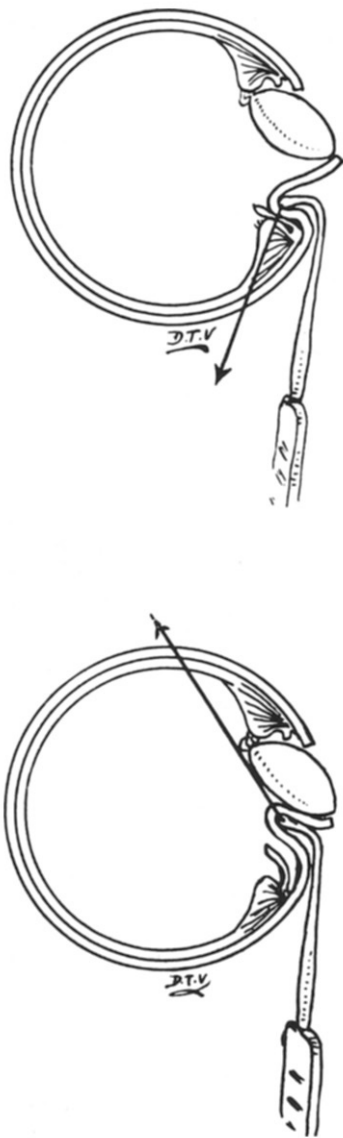


Figure 6. Top, this is a “tumbler.” This half-somersault of the lens occurs by making traction away from the incision by means of the hook caught on the ciliary ridge and pulling directly toward the patient’s feet and at the same time not making deep pressure. Bottom, the lens advances after it has severed its lower ligamentous attachments and is turning. The pressure is shifted to follow it up and is now no longer toward the patient’s feet, but toward the top of the head to keep all gaps between the lens and wound closed to prevent vitreous loss. (Reprinted with permission from Vail DT. Lantern demonstration of the unmodified Smith surgery for cataract. *Transactions of the American Academy of Ophthalmology and Otolaryngology* 1910;72-97.)

meeting of the Academy. H. Gifford<sup>51</sup> recommended terminating the surgery when vitreous loss was encountered before the lens was extracted. The surgery was eventually completed at a later date, after the incision had healed. He offered this as, “the best way out of a bad hole.” To do this today would be unthinkable.

Arnold Knapp,<sup>52</sup> the son of Herman Knapp, influenced many ophthalmologists at the 1928 Academy meeting to develop their skill in intracapsular surgery. While per-

forming capsulectomy with the blunt capsule forceps of Kalt, he noted that in many cases, before rupture of the capsule occurred, the lens became dislocated. This stimulated him to pursue the intracapsular surgery with a slight modification of the Stanculeanu technique.<sup>48</sup> He realized that there was no ideal method of cataract extraction and recommended that ICCE be performed only in selected cases.

During the discussion of Knapp’s paper, A. Green<sup>53</sup> stated that he induced paralysis of the orbicularis by an infraorbital injection of procaine hydrochloride (Novocain); this was fortified by instilling cocaine hydrochloride into the conjunctival sac. He continued that after the incision was made, a horizontal crease often appeared in the cornea, running from limbus to limbus, reflecting increased intraocular pressure. In these cases, the intracapsular method should be avoided.

At the 1924 Academy meeting, A. Greenwood<sup>54</sup> recommended that the term *cataract* should be avoided as much as possible with patients: “It strikes terror into the soul of some of the timid ones.” Cataract often implied impending blindness and a dreadful surgery with uncertain end results, so it is not surprising that many ophthalmologists recommended nonsurgical treatment to suppress the advancement of cataracts. These included dionin, sodium iodide, mercury cyanide, and ionization—all of which proved ineffective fell into disuse.

The surgical treatment of congenital cataract by complete discission was advocated primarily by Zeigler<sup>55</sup> in 1921. It was used mainly in children younger than 10 years of age. For older children, linear extraction was advocated.

As surgical techniques improved, a tide of enthusiasm for ICCE continued well into the 1930s, and it became the favored technique in the United States. This was supported by the two most obvious advantages of the method: 1) no need to wait for maturity of the cataract and 2) the avoidance of the then-serious problem of cataract.

Davis<sup>56</sup> advocated the ICCE method at the 1937 Academy meeting and outlined the suggested routine postoperative care as follows: The first dressing is done on the fourth day in cases in which complete iridectomy has been performed and after 48 hours in cases of simple extraction. Patients are kept in bed for 4 to 5 days, but a backrest is permitted after 48 hours. A soap suds enema is given on the fourth day. Sutures are removed on the seventh day unless spontaneously extruded. The eye that did not undergo surgery is uncovered on the fourth day after the

Table 1. Life Span per 100,000 Individuals in 1911

Age (yrs)	Number
80	13,290
85	5417
90	1319
95	89
100	1

# Explore Litigation Insights

Docket Alarm provides insights to develop a more informed litigation strategy and the peace of mind of knowing you're on top of things.

## Real-Time Litigation Alerts



Keep your litigation team up-to-date with **real-time alerts** and advanced team management tools built for the enterprise, all while greatly reducing PACER spend.

Our comprehensive service means we can handle Federal, State, and Administrative courts across the country.

## Advanced Docket Research



With over 230 million records, Docket Alarm's cloud-native docket research platform finds what other services can't. Coverage includes Federal, State, plus PTAB, TTAB, ITC and NLRB decisions, all in one place.

Identify arguments that have been successful in the past with full text, pinpoint searching. Link to case law cited within any court document via Fastcase.

## Analytics At Your Fingertips



Learn what happened the last time a particular judge, opposing counsel or company faced cases similar to yours.

Advanced out-of-the-box PTAB and TTAB analytics are always at your fingertips.

## API

Docket Alarm offers a powerful API (application programming interface) to developers that want to integrate case filings into their apps.

## LAW FIRMS

Build custom dashboards for your attorneys and clients with live data direct from the court.

Automate many repetitive legal tasks like conflict checks, document management, and marketing.

## FINANCIAL INSTITUTIONS

Litigation and bankruptcy checks for companies and debtors.

## E-DISCOVERY AND LEGAL VENDORS

Sync your system to PACER to automate legal marketing.