

Diclofenac-Associated Hepatotoxicity

Simon M. Helfgott, MD; Joanne Sandberg-Cook, RNC, MS; David Zakim, MD; Jeffrey Nestler, MD

Diclofenac sodium, a phenylacetic acid–derived nonsteroidal anti-inflammatory drug (NSAID) recently released in the United States, was associated with the development of significant hepatitis in seven patients, with one associated death. Signs and symptoms developed within several weeks of initiation of drug use and generally resolved 4 to 6 weeks following discontinuation of use of the drug. The only patient rechallenged with the drug developed a recurrence of her hepatic abnormalities. In one patient, fatal, fulminant hepatitis developed despite early withdrawal of the drug. Review of the European literature disclosed three additional fatalities associated with diclofenac therapy. It is unclear whether the incidence of hepatotoxicity is higher with this drug compared with other nonsteroidal anti-inflammatory drugs. Careful patient monitoring is advised, and prompt discontinuation of the drug is suggested when signs or symptoms of liver disease develop.

(*JAMA*. 1990;264:2660-2662)

DICLOFENAC sodium (Voltaren), a nonsteroidal anti-inflammatory drug (NSAID) that is a phenylacetic acid derivative, has recently been released for use in the United States, although it has been available in Europe since 1974. Borderline elevations of serum aminotransferase level have been described in approximately 15% of patients taking diclofenac,¹ yet signs and symptoms of liver disease rarely occur. We report

For editorial comment see p 2677.

the development of diclofenac-associated hepatitis in seven patients, including one patient with fatal fulminant massive hepatic necrosis (Table 1).

Report of Cases

CASE 1.—A 65-year-old housewife with a history of osteoarthritis and osteoporosis presented with a 1-month history of jaundice, elevations of aminotransferase level, and coagulopathy. The patient had been well except for worsening arthritic pain unresponsive to treatment with ibuprofen. Diclofenac sodium therapy, 75 mg twice daily, was started 2 months prior to admission, and use of ibuprofen was discontinued. Liver function studies yielded normal re-

sults 3 weeks after initiation of diclofenac therapy, but 3 weeks later the patient had sudden onset of nausea, vomiting, and fatigue. A serum alanine transpeptidase (ALT) concentration was 53 U/L and a serum aspartate transpeptidase (AST) concentration was 40 U/L (normal values: ALT, 0 to 45 U/L; AST, 0 to 45 U/L). The use of diclofenac was discontinued. Her only other medications at the time were long-term estrogen and progesterone hormone replacement therapy, which was stopped. Five days later the patient was noted to be jaundiced, with a bilirubin level of 291 $\mu\text{mol/L}$ (normal level, 2 to 18 $\mu\text{mol/L}$), an AST of 3740 U/L, and a prothrombin time of 17.9 seconds (normal prothrombin time, 9.0 to 12.5 seconds). Hepatitis A and B serologies and analysis of antimitochondrial antibody and antinuclear antibody yielded normal results. A computed tomographic scan of the abdomen revealed hepatomegaly without focal lesions or biliary duct obstruction. A brief tapering course of 60 mg of prednisone per day was started without improvement. The patient denied alcohol use, blood product transfusions, foreign travel, intravenous drug use, or known exposure to toxic agents. Medications included furosemide, 20 mg/d; famotidine, 40 mg/d; and prednisone, 30 mg/d.

On examination the patient was lethargic and jaundiced. The liver was not enlarged. There was some ascites and bilateral pitting edema. Marked asterixis was present. Bilirubin value was 616 $\mu\text{mol/L}$; AST, 177 U/L; ALT,

140 U/L; and prothrombin time, 15.8 seconds. Abdominal ultrasound examination revealed a small liver with patent hepatic veins and no biliary obstruction. On the seventh hospital day the patient suffered a cardiopulmonary arrest. She was resuscitated but continued to deteriorate and died 1 week later. At autopsy the liver was markedly reduced in size, weighing 800 g, with a yellow-green, wrinkled appearance. Microscopic examination revealed massive hepatocellular necrosis with evidence of bridging necrosis and marked intrahepatic cholestasis (Figure). There was a mild nonspecific inflammatory infiltrate in the portal triads and some regenerating nodules. Immunohistochemical stains for hepatitis B core and surface antigen were normal.

CASE 2.—A 46-year-old female nurse with a history of fibrositis started taking diclofenac sodium, 75 mg twice a day. Other medications included amitriptyline hydrochloride, 100 mg every night; ranitidine, 300 mg every night; nadolol, 40 mg/d; and furosemide, 40 mg/d. Findings from pretreatment liver function studies were normal. Four and one-half months later she developed mild anorexia and nausea. The ALT concentration measured 149 U/L and AST, 110 U/L. The use of diclofenac was discontinued, and her symptoms resolved. Results of liver function studies normalized over the next 8 weeks. Her musculoskeletal symptoms had worsened in the interval, and she restarted diclofenac sodium therapy at 50 mg twice daily. Six weeks later she developed nausea, anorexia, malaise, and right upper quadrant pain. On examination there was tenderness in the right upper quadrant and a slightly palpable, but not enlarged, liver. The ALT level measured 363 U/L and AST, 252 U/L. Hepatitis A and B serologies were normal. Use of diclofenac was discontinued, her symptoms resolved, and the results of the liver function studies normalized 5 weeks later.

CASE 3.—A 54-year-old housewife with rheumatoid arthritis, treated with biweekly parenteral gold salt injections, started a regimen of diclofenac sodium, 75 mg twice daily. Pretreatment liver function studies yielded nor-

From the Beth Israel and Brigham & Women's Hospitals and Harvard Medical School (Dr Helfgott), Boston, Mass; Braintree Hospital (Ms Sandberg-Cook), Braintree, Mass; and the New York Hospital and Cornell Medical College (Drs Nestler and Zakim), New York, NY.

Reprint requests to 85 Seymour St, Hartford, CT 06106 (Dr Nestler).

Table 1.—Clinical Characteristics of Patients With Diclofenac-Induced Hepatotoxicity (Present Series)*

Age, y	Sex	Diagnosis	Dose of Diclofenac Sodium	Onset of Hepatotoxicity, d	Symptoms	Peak Liver Function Studies		
						Aminotransferase: AST/ALT†	AP/Alb/Bili‡	Concomitant Drugs
65	F	Osteoarthritis	75 mg bid	42	Nausea	3740/2409	55/34/693	Estrogen, progesterone
46	F	Fibrositis	75 mg bid	139	Nausea, malaise, RUQ pain	363/252	186/40/17	Amitriptyline, furosemide, ranitidine, nadolol
54	F	Rheumatoid arthritis	75 mg bid	82	Acute RUQ pain, nausea, anorexia	389/327	360/30/50	Parenteral gold salts
55	F	Fibrositis	75 mg bid	131	Anorexia, nausea, weight loss	472/254	88/48/17	Trazodone, estrogen, progesterone
45	M	Osteoarthritis	75 mg bid	111	Asymptomatic	922/492	213/43/15	None
54	F	Osteoarthritis	75 mg bid	41	RUQ pain, nausea, anorexia	763/442	186/38/17	None
69	F	Osteoarthritis	25 mg tid	35	Nausea, abdominal pain	217/not done	225/35/99	None

*AST indicates aspartate transpeptidase; ALT, alanine transpeptidase; AP, alkaline phosphatase; Alb, albumin; Bili, bilirubin; bid, twice a day; tid, three times daily; and RUQ, right upper quadrant.

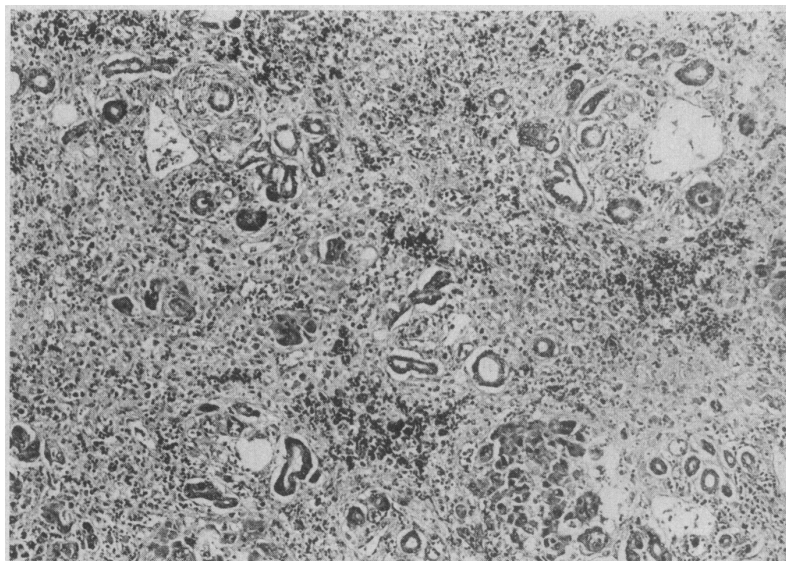
†AST and ALT are measured in units per liter.

‡AP is measured in units per liter; Alb, in grams per liter; and Bili, in micromoles per liter.

mal results. Ten weeks later she developed acute, severe right upper quadrant and epigastric pain that necessitated admission to a hospital. The ALT level measured 389 U/L; AST, 327 U/L; alkaline phosphatase, 360 U/L (normal level, 50 to 136 U/L); total bilirubin, 50 $\mu\text{mol/L}$; direct bilirubin, 39 $\mu\text{mol/L}$; and amylase, 41 U/L; hepatitis A and B serologies yielded normal results. An abdominal computed tomographic scan revealed mild gallbladder distention without an obstructive lesion; an ultrasound examination of the gallbladder displayed minimally dilated extrahepatic ducts (8 to 9 mm) without obstruction. Results of a radionuclide hepatic biliary and a double-contrast upper gastrointestinal tract series were normal except for a hiatus hernia. Diclofenac use was discontinued, and 5 weeks later the results of her liver function studies returned to normal.

CASE 4.—A 55-year-old waitress with a history of fibrositis started a regimen of diclofenac sodium, 75 mg twice a day. Results of pretreatment liver function studies were normal. Six months later she developed nausea, anorexia, and weight loss. Other medications included trazodone hydrochloride, 150 mg every night; conjugated estrogens, 0.625 mg/d with cyclic progesterone, 10 mg 10 days per month. The ALT concentration measured 472 U/L; AST, 254 U/L; and total bilirubin, 27 $\mu\text{mol/L}$. Hepatitis A and B serologies yielded normal results. Results of an upper gastrointestinal tract series and abdominal ultrasound examination were within normal limits. The use of diclofenac was discontinued, and 1 month later her symptoms resolved and the results of her liver function studies normalized.

CASE 5.—A 45-year-old male steelworker with osteoarthritis of the hip started a regimen of diclofenac sodium,



Low-power photomicrograph of collapsed hepatic parenchyma with nearly complete loss of hepatocytes and approximation of portal areas (case 1) (magnification $\times 100$).

75 mg twice a day. Whereas pretreatment liver function studies yielded normal results, 3½ months later the ALT level measured 922 U/L; AST, 492 U/L; alkaline phosphatase, 213 U/L; and total bilirubin, 15 $\mu\text{mol/L}$. Results of hepatitis serologies were normal. The patient denied any gastrointestinal symptoms. He admitted increasing his dose of diclofenac sodium intermittently to 225 mg/d, as well as drinking an average of 8 to 12 cans of beer per week. The use of diclofenac was stopped, and 6 weeks later the results of his liver function studies returned to normal.

CASE 6.—A 54-year-old female housekeeper with osteoarthritis of the knees started a regimen of diclofenac sodium, 75 mg twice a day. The results of pretreatment liver function studies

were normal. Six weeks later she developed an asymptomatic elevation of the ALT level to 248 U/L and AST to 148 U/L. Because her arthritis symptoms had improved with use of diclofenac, she continued to take the drug. Two months later she complained of anorexia, nausea, and abdominal pain. The ALT concentration measured 763 U/L and AST, 442 U/L. The results of hepatitis A and B serologies were normal. Diclofenac therapy was discontinued. Four weeks later her symptoms resolved and the results of her liver function studies normalized.

CASE 7.—A 69-year-old housewife with generalized osteoarthritis started taking 75 mg of diclofenac sodium per day, her only medication. Five weeks later she developed severe nausea,

Table 2.—Clinical Characteristics of Patients With Diclofenac-Induced Hepatotoxicity: European Literature Review*

Age, y	Sex	Dose of Diclofenac Sodium	Onset of Symptoms, d	Concomitant Drugs	Outcome	Reference
56	M	75 mg qd	47	Indomethacin	Death	7
68	F	50 mg bid	14, 7†	...	Normalized	8
70	F	75 mg bid	5	...	Normalized	8
52	M	Not available	120, 35†	...	Normalized	9
42	F	75 mg bid	7, 2†	...	Normalized	10
45	F	Not available	35	Glaufenine	Death	11
55	F	50 mg bid	21	Oxazepam, clomipramine, Noctadiol,‡ Atrium§	Death	12
60	F	75 mg bid	150	Nitrazepam, promethazine, amiloride, hydrochlorothiazide	Normalized	13
72	F	50 mg bid	107	Nadoxolol chlorhydrate	Normalized	14

*qd indicates every day; and bid, twice a day.

†Rechallenge with diclofenac.

‡Noctadiol is composed of amobarbital, secobarbital, and meprobamate.

§Atrium is composed of febarbamate, difebarbamate, and phenobarbital.

right upper quadrant pain, and jaundice. She denied alcohol intake. Liver function studies revealed a peak total bilirubin level of 99 $\mu\text{mol/L}$, an alkaline phosphatase level of 225 U/L, and an AST level of 217 U/L. Hepatitis A and B serologies yielded normal results. The results of an abdominal ultrasound examination and endoscopic retrograde cannulation of the pancreas and common bile duct were normal. Diclofenac use was discontinued, followed by resolution of symptoms and normalization of liver function.

Comment

Following NSAID therapy, hepatocellular and cholestatic liver disease have been reported, with both seen in association with phenylbutazone-induced hepatitis.² High doses of salicylates, notably in children, can induce a mild, reversible hepatocellular injury.³ Although propionic acid derivatives rarely cause hepatic injury, benoxaprofen was withdrawn from the market primarily because of a relatively high incidence of cholestatic jaundice.⁴ Diclofenac-induced hepatotoxicity most commonly results in an asymptomatic, mild, reversible elevation in the serum aminotransferase levels that occurs in up to 15% of patients using the drug.^{1,5} Fifty-one patients of 5700 developed marked rises (ie, at least 8 \times the upper limits of normal) in the aminotransferase levels, yet signs and symptoms of liver disease occurred in only three cases, and one patient developed jaundice.¹ A large, retrospective Danish study revealed a very low incidence of hepatotoxicity with diclofenac.⁶ Nevertheless, nine

case reports have documented severe hepatitis associated with diclofenac therapy,⁶⁻¹⁴ including three fatalities. These cases are summarized in Table 2.

Features common to the European cases and this series include a striking female preponderance (6:1), a mean age in the mid-50s, and an underlying diagnosis of osteoarthritis. These characteristics may reflect the population taking NSAIDs. The onset of hepatic symptoms usually occurred within several weeks of drug initiation. Discontinuation of the use of the drug did not always result in a return of normal liver function, as noted in our first case and three previously reported European cases.^{7,11,12} Concomitant drug use, including corticosteroids in our patient and other potential hepatotoxins in the European patients, may have contributed to their death. Two of our patients (cases 1 and 4) were using conjugated estrogens and one patient (case 5) admitted to regular alcohol consumption. Serologies for hepatitis types A and B were normal in all our patients. Although sporadic hepatitis C cannot be ruled out with absolute certainty, none of our patients had risk factors for this condition.

The mechanism of hepatotoxicity with diclofenac remains unclear. Reactive metabolites have been reported to play a role in benoxaprofen and other NSAID-induced hepatitis.¹⁵ In some cases a hypersensitivity reaction appeared to play a key role^{7,9}; however, none of our patients displayed the typical features of drug hypersensitivity, including fever, rash, or eosinophilia. The temporal relationship between diclofenac administration and the subsequent development of liver disease as well as recurrence of the illness with

drug rechallenge (case 2) implies a drug-disease association. Four of six patients restarted the use of NSAIDs, including naproxen, piroxicam, and flurbiprofen, without adverse effects.

These cases represent the first description of this complication in the United States since approval of this drug by the Food and Drug Administration. It is unclear whether this represents a higher incidence of hepatotoxicity than with other NSAIDs, but we would strongly encourage careful monitoring¹⁶ of all patients using this agent and prompt discontinuation of the drug therapy when signs or symptoms of liver disease develop.

We thank Richard Herrmann, MD, and Judith Feldman, MD, for kindly referring patients 1 and 7, respectively; Tom Goodwin, MD, for reviewing the histopathology; and Grace LeFort for expert secretarial assistance.

References

1. Package insert, Voltaren (diclofenac sodium). Ardsley, NY: Geigy Pharmaceuticals Division of Ciba-Geigy Corp; October 1988.
2. Fowler PD, Woolfe D, Alexander S. Phenylbutazone and hepatitis. *Rheumatol Rehab*. 1975;14:71-75.
3. Zimmerman HJ. Aspirin-induced hepatic injury. *Ann Intern Med*. 1974;80:103-105.
4. Fowler PD. Major toxic reactions associated with NSAIDs. In: Dudley Hart F, Klinenberg JR, eds. *Choosing NSAID Therapy*. Auckland, New Zealand: ADIS Press; 1985:41-57.
5. Ciccuolunghi SN. Report on a long-term tolerability study of up to two years with diclofenac sodium. *Scand J Rheumatol*. 1978;22:86-96.
6. Kromaann-Anderson H, Pedersen A. Reported adverse reactions to and consumption of nonsteroidal anti-inflammatory drugs in Denmark over a 17-year period. *Danish Med Bull*. 1988;35:187-192.
7. Breen E, McNicholl J, Cosgrove E, McCabe J, Stevens F. Fatal hepatitis associated with diclofenac. *Gut*. 1986;27:1390-1393.
8. Schapira D, Bassan L, Nahir A, Scharf A. Diclofenac-induced hepatotoxicity. *Postgrad Med J*. 1986;62:63-65.
9. Dunk A, Walt R, Jenkins W, Sherlock S. Diclofenac hepatitis. *BMJ*. 1982;289:1605-1606.
10. Masana P, Rojas G, Diego V, Leal S. Hepatitis acida y diclofenac sodico. *Rev Clin Esp*. 1986;179:476.
11. Babany G, Bernau J, Danaw G, Rueff B, Benhamou J. Fulminating hepatitis in a woman taking glafenine and diclofenac. *Gastroenterol Clin Biol*. 1985;9:185.
12. Lasgar G, Grippon P, Levy V. Acute fatal hepatitis during treatment with diclofenac. *Gastroenterol Clin Biol*. 1984;8:881-882.
13. Babany G, Passayre D, Benhamou J. Hepatitis caused by diclofenac. *Gastroenterol Clin Biol*. 1983;7:316.
14. Deshayes P, Leloet X, Bercoff E, Fouin-Fortinet H. Diclofenac hepatitis. *Presse Med*. 1984;13:1847.
15. Mitchell MC, Lietman PS. Evidence for the role of reactive metabolites in hepatotoxicity of benoxaprofen and other NSAIDs. *Hepatology*. 1983;3:808. Abstract.
16. Campbell PM, Wilske K. Drug monitoring. In: Weaver AL, ed. *Guidelines for Reviewers of Rheumatic Disease Care*. 2nd ed. Atlanta, Ga: Council of Rheumatologic Care of the American College of Rheumatology; 1989:23-24.