

See What's New

Heart Database

Right Atrium

Right Ventricle

Pulmonary Artery

Left Atrium

Left Ventricle

Aorta

Coronary Arteries

Cardiac Veins

External Images

Cardiac MRI

Comparative Imaging

3D Modeling

Anatomy Tutorial

Cardiac MRI Tutorial

Comparative Anatomy Tutorial

Conduction System Tutorial

Congenital Defects Tutorial

Coronary System Tutorial

Device Tutorial

Echocardiography Tutorial

Physiology Tutorial

Project Methodologies

Acknowledgements

References and Links

Atlas in the media

Surgery Department Home

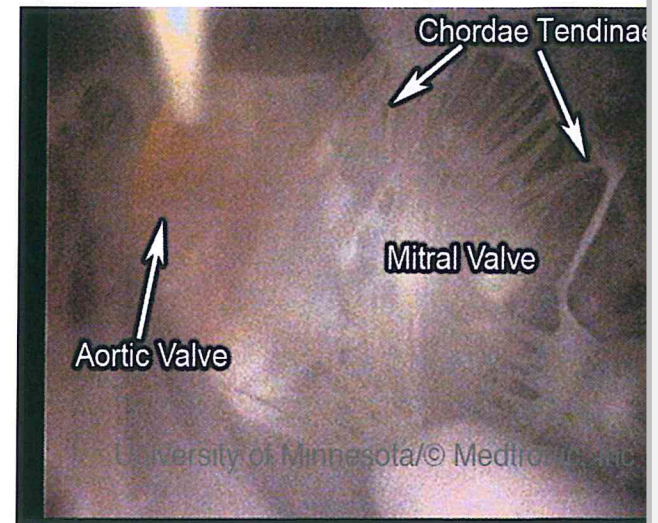
Principal Investigator:
Paul A. Iaizzo, Ph.D.

Email Us

Search Results for: mitral valve

Heart0073

View from left ventricular apex of mitral (right) and aortic (left) during working mode.



Viewing Labeled Image
Click for Movie

To download image, right-click
choose "Save As" or "Save

- © 2014 Regents of the University of Minnesota. All rights reserved.
- The University of Minnesota is an equal opportunity educator and employer
- Last modified on

<http://www.vhlab.umn.edu/atlas/search.cgi>

NORRED EXHIBIT 2349 - Page 1
Medtronic, Inc., Medtronic Vascular,
& Medtronic Corevalve, LLC
v. Troy R. Norred, MD
Case IPR2014-00395