

History of Percutaneous Aortic Valve Prosthesis

Henning Rud Andersen¹

¹Department of Cardiology, Skejby University Hospital, Aarhus, Denmark.

Abstract

This review describes the development of percutaneous transluminal catheter-mounted heart valves for permanent implantation. The time period from the first surgically implanted valve in 1952, through catheter-mounted valves inserted for temporal relief, until

the conception of the percutaneous transcatheter heart valve for permanent implantation is summarized. The process involved in the construction of the new valve is detailed in Figure 1, and the future of this new treatment modality is discussed.

Key Words:

Heart valve · Catheter · Percutaneous · Implantation

Herz 2009;34:343–6

DOI 10.1007/s00059-009-3251-4

Geschichte der perkutanen Aortenklappenimplantation

Zusammenfassung

Diese Übersicht beschreibt die Entwicklung perkutaner transluminaler kathetermontierter Herzklappen zur permanenten Implantation. Der Zeitraum von der ersten chirurgisch eingepflanzten Klappe 1952, die mittels kathetermontierter Klappen zur temporären Entlastung eingesetzt wurde, bis zum Konzept der

perkutanen Transkatheter-Herzklappe zur permanenten Implantation wird besprochen. Der mit der Konstruktion der neuen Klappe verbundene Prozess wird in Abbildung 1 detailliert dargestellt, und die Zukunft dieser neuen Behandlungsmodalität wird diskutiert.

Schlüsselwörter:

Herzklappe · Katheter · Perkutan · Implantation

Introduction

Implantation of an artificial heart valve as a treatment for valvular heart disease dates back to 1952, when Hufnagel performed the first implantation in a patient with severe aortic insufficiency [1]. The artificial heart valve was implanted in the descending thoracic aorta, significantly reducing severe left ventricular regurgitation and improving hemodynamic function [2]. This technique was used in a small series of operations for aortic regurgitation [3, 4], and follow-up reports 24 years later revealed satisfactory results in some of the patients [5]. The development of extracorporeal circulation made it possible for Harken et al. to perform the first subcoronary implantation in 1960 [6]. Since then, implantation of prosthetic heart valves has been an open-heart surgical procedure. If, however, permanent implantation of heart valves could be accomplished without thoracotomy, it would be highly attractive, as it would not only significantly reduce surgical time and trauma, but the procedure-associated morbidity of the patient would be smaller. In recent years, interventional cardiology has introduced percutaneous implantation of many different cardiac devices, but it was not until recently that percutaneous transluminal catheter-mounted heart valves were implanted into a human [7].

Catheter-Mounted Heart Valves for Temporary Treatment

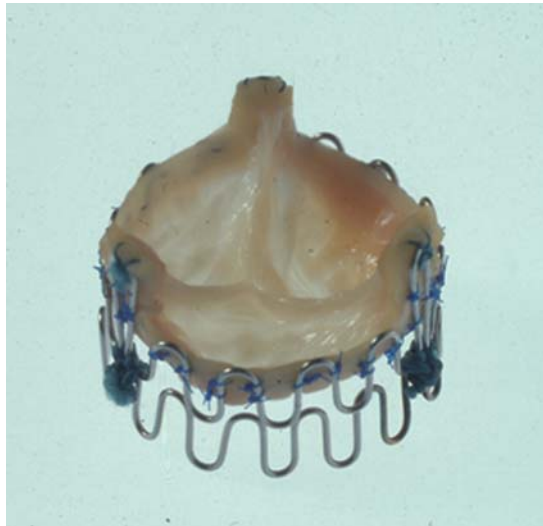
In 1965, Davies described a catheter-mounted valve for temporary relief of aortic insufficiency and tested it in dogs [8]. A cone-shaped valve in the form of a parachute with wires was mounted on the tip of a 5-F catheter. The catheter was inserted via the femoral artery into the descending aorta and the extending catheter was fixed to the skin of the leg. The valve collapsed during antegrade blood flow, and, during diastole, it unfolded due to retrograde blood flow and pressure gradient. The parachute wires prevented the valve from inverting during diastole. The catheter-mounted valve was designed for temporary relief of symptoms in patients with severe aortic insufficiency, and to render the patient fit for definitive surgery days or weeks later. The catheter was not designed for permanent implantation.

In 1971, Mouloupoulos et al. described three different catheter-mounted aortic valves for insertion in the ascending aorta [9]. The devices were tested in vitro in a mock circulation system, and in vivo in dogs. One of the valves had an umbrella design and two were based on a balloon system.

The umbrella-shaped polyurethane valve was 2–3 cm in length and 1–2 cm in diameter and mounted at the tip of a polyethylene catheter. The diameter of

Figure 1. Photograph of the Andersen stent valve built for percutaneous transluminal catheter implantation. The stent valve was constructed in 1989 and consisted of two folded metal rings and a porcine aortic valve mounted inside the stent.

Abbildung 1. Photographie der Andersen-Stentklappe zur perkutanen transluminalen Katheterimplantation. Die Stentklappe wurde 1989 konstruiert und bestand aus zwei gefalteten Metallringen und einer Schweineortenklappe, die innerhalb des Stents angebracht wurde.



the open umbrella was planned to be larger than that of the aorta. During systole, the forward flow closed the umbrella. During diastole, the backward flow opened the umbrella, which touched the aortic wall. The umbrella was designed to be long enough so the open valve would touch the aortic wall over a large area and would not be inverted by the diastolic pressure gradient. This therefore precluded the need for parachute wires to prevent inversion of the valve. The two balloon systems were designed with a spherical balloon 1 cm in diameter made of polyurethane and tied at the end of a 40 cm long polyethylene catheter. The balloons could be inflated during diastole and deflated during systole. When inflated, the balloon occluded the aorta in order to prevent diastolic backflow. When deflated, it collapsed in order to allow a free systolic flow. The catheters were connected to two different external pump systems which synchronized inflation and deflation in relation to diastole and systole. None of these three catheters was designed for permanent implantation.

5 years later, in 1976, Phillips et al. described a catheter-tip-mounted aortic valve for temporary treatment of aortic insufficiency and tested it in dogs [10]. This design employed a mixture of the concepts described by Davies [8] and Mouloupoulos et al. [9]. It was a catheter mounted with a polyurethane cusp designed to act as a temporarily inserted prosthetic aortic valve in the ascending aorta. The cusp should collapse during systole and unfold during diastole. It was mounted 1 cm from the end of a polyurethane catheter 4 mm in diameter and 60 cm in length. The cusp had an umbrella design, but also one parachute wire to prevent the valve from inverting during diastole. The extending catheter was fixed to the skin.

In 1977, Boretos & Poirier also described a catheter for temporary relief of aortic insufficiency [11].

This catheter was also designed for extending out of the patient to be fixed against the surface of the body. The valve was mounted at the tip of a catheter, shaped as a cone with a broad circular basis pointing in the direction of the left ventricle, and with the flexible valves of the cone extending downstream. It allowed central flow through the cone during systole and closure of the flexible valves during diastole, which was the result of both regurgitated flow and the diastolic pressure gradient.

Several years later, in 1992, Matsubara et al. described a balloon catheter with check valves for experimental relief of aortic regurgitation and tested it in a dog model [12]. A latex balloon was mounted near the end of a catheter and inflated to occlude the aorta. Holes on the proximal and distal sides of the balloon were connected to each other inside the catheter, allowing the passage of blood from the two distal holes to the two proximal holes during the systolic phase. Two latex valves were mounted on the two proximal holes of the catheter to prevent regurgitation during diastole.

The result of close to 30 years of design and testing of catheter-mounted valves for short-term insertion into the aorta designed for temporary relief of aortic insufficiency undoubtedly made experimental progress. However, despite the technical development these catheters never went into clinical use. None of these catheter-mounted valves was applicable for permanent implantation.

The Conception of a Percutaneous Transluminal Catheter-Mounted Heart Valve for Permanent Implantation

In February 1989, the idea of a percutaneous heart valve for permanent implantation was conceived by Andersen (Figure 1) [13]. The idea behind its conception was to develop a new technology and treatment to be used by interventional cardiologists in a cardiac catheterization laboratory. Andersen defined three requirements for the new technology. The implantation should be on a closed chest, a beating heart and a closed heart. Furthermore, no catheter should be left inside the heart or the vessel after implantation of the valve. The valve should be for permanent implantation. The first valve was implanted on May 1, 1989 in the descending thoracic aorta of a pig (Figure 2). The first subcoronary implantation was performed in November 1989 in a pig.

The New Concept for Implantation of Artificial Heart Valves

The idea was to mount a foldable biological cardiac valve inside a balloon-expandable metallic stent.

Implantation of such a device (stent + valve = the stent valve) would enable implantation of artificial heart valves by the transluminal catheter technique without using thoracotomy or extracorporeal circulation. We constructed and hand-built the stent valve, sheets and catheters. The metal stent was constructed from two 0.55-mm surgical stainless steel wires of the kind normally used to close the sternum after thoracotomy. Each wire was folded into 15 loops, 8 mm high each (Figure 1). Three of the loops were 14 mm high, designed for fixation of the commissural points of a porcine aortic valve. Each folded wire was bent into a circle (diameter, 22 mm) which was closed end-to-end by soldering. The two circles were then stacked upon each other and fixed together with sutures. The ability of the metal stent to be compressed manually around a 30-mm balloon was tested. Then, the ability of the balloon to expand the metal stent to 30 mm diameter, with the expanded stent having a sufficient stiffness to prevent recoil when it was implanted in vitro in an explanted pig aorta, was also tested. The choice of 0.55-mm surgical stainless wires was determined after several “trial and error” tests with different wire thickness, stiffness and number of loops. The foldable valve was a porcine aortic valve taken from a pig heart bought from a local butcher. The valve was carefully dissected and cleaned manually, mounted inside the stent and then fixed with sutures (Figure 1). The stent valve was neither sterilized nor heparinized, nor was it treated with any drug or chemical agent. Thus, the stent valve was viable only for short-term use (hours) to prove the concept of catheter-based implantation of artificial heart valves. The proof of concept was documented in pigs and in in vitro models [13, 14].

Progression of Development from 1989 until First Human Implantation in 2000

The new technology did not gain much attention for several years. It was obvious that much more refinement and testing were necessary before implantation in humans could even be considered. Thus, such development required engineering, research, refinement and investment which could only be done by a company who believed in the concept. The interest, however, from industry involved in interventional cardiology was minimal. Academic research groups around the world continued to investigate the technology. New biological valves were tested in animals [15–19], and mechanical valves, both cage-ball valves and disk valve prostheses, were also developed and tested [20, 21]. Then, in 2000, Bonhoeffer et al. performed the first human implantation in the pulmonary position [7]. This landmark achievement was followed by implantation in the aortic position in 2002 by Cribier et al. [22]. Afterwards, the interest in

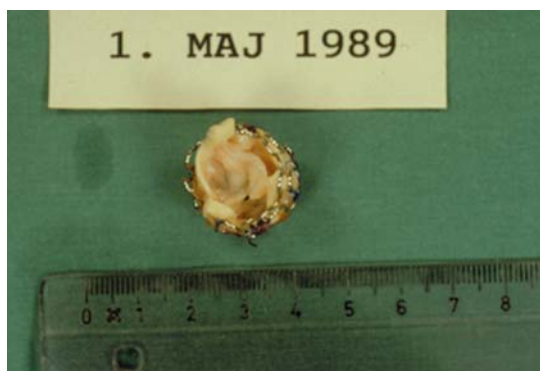

Figure 2. The first Andersen stent valve implanted on May 1, 1989.
Abbildung 2. Die erste Andersen-Stentklappe, implantiert am 01.05.1989.

this technology among cardiologists and industry skyrocketed.

The Future of Percutaneous Transluminal Catheter-Mounted Heart Valve Implantation

The first pulmonary implantation in 2000 and the first aortic implantations in 2002 used a balloon-expandable stent valve similar to the Andersen stent valve [13]. Later, self-expandable aortic valves were developed [23]. Within the last 2–3 years, implantation of both balloon- and self-expandable stent valves has become routine treatment in Europe for selected patients with aortic stenosis. The new treatment modality has already been used in several thousand patients. Initially, the implantations were done only from the femoral vein or the femoral artery [7, 22, 24]. Recently, a new transapical catheter technique for aortic valve implantation in humans has been developed and is now used very frequently [25, 26]. It allows treatment of patients with narrowed femoral arteries without the need for atrial septal puncture followed by antegrade implantation from the right atrium through the left atrium and the left ventricle – a difficult and complex procedure. New technical modifications of the initial concept are being developed, and in 2009 more than 20 companies around the world are involved in research and further development of the concept [27]. In addition, there have been recent mitral valve implantations that have been performed in animals (unpublished data). The percutaneous transluminal implantation technology is still very young and immature, but intense research and development will continue to bring it forward with high speed. This new technique has the potential to be the new major treatment breakthrough in interventional cardiology. Only time will tell.

Disclosure: The author declares that he has no financial or personal relations to other parties whose interests could have affected the content of this article in any way, either positively or negatively.

References

1. Hufnagel CA, Harvey WP. The surgical correction of aortic regurgitation. Preliminary report. Bull Georgetown Univ Med Center 1953;6:3-6.
2. Hufnagel CA. Basic concepts in the development of cardiovascular prostheses. Am J Surg 1979;137:285-300.
3. Hufnagel CA, Harvey WP, Rabil PJ, et al. Surgical correction of aortic insufficiency. Surgery 1954;35:673-83.
4. Conklin WS, Grismer JT, Aalpoel JA. Hufnagel valve surgery for aortic insufficiency. J Thorac Surg 1958;36:238-46.
5. Hufnagel CA, Gomes MN. Late follow-up of ball-valve prostheses in the descending thoracic aorta. J Thorac Cardiovasc Surg 1976;6:900-9.
6. Harken DE, Soroff HS, Taylor WJ, et al. Partial and complete prosthesis in aorta insufficiency. J Thorac Cardiovasc Surg 1960;40:744-62.
7. Bonhoeffer P, Boudjemline Y, Saliba Z, et al. Percutaneous replacement of pulmonary valve in a right-ventricular to pulmonary-artery prosthetic conduit with valve dysfunction. Lancet 2000;356:1403-5.
8. Davies H. Catheter-mounted valve for temporary relief of aortic insufficiency. Lancet 1965;1:250.
9. Mouloupoulos SD, Anthopoulos L, Stamatelopoulos S, et al. Catheter-mounted aortic valves. Ann Thorac Surg 1971;11:423-30.
10. Phillips SJ, Ciborski M, Freed PS, et al. A temporary catheter-tip aortic valve: hemodynamic effects on experimental acute aortic insufficiency. Ann Thorac Surg 1976;21:134-7.
11. Boretos JW, Poirier RA. Aortic heart valve catheter. United States Patent 1977 (No. 4,056,854).
12. Matsubara T, Yamazoe M, Tamura Y, et al. Balloon catheter with check valves for experimental relief of acute aortic regurgitation. Am Heart J 1992;124:1002-8.
13. Andersen HR, Knudsen LL, Hasenkam JM. Transluminal implantation of artificial heart valves. Description of a new expandable aortic valve and initial results with implantation by catheter technique in closed chest pigs. Eur Heart J 1992;13:704-8.
14. Knudsen LL, Andersen HR, Hasenkam JM. Catheter-implanted prosthetic heart valves. Transluminal catheter implantation of a new expandable artificial heart valve in the descending thoracic aorta in isolated vessels and closed chest pigs. Int J Artif Organs 1993;16:253-62.
15. Moazami N, Bessler M, Argenziano M, et al. Transluminal aortic valve placement. A feasibility study with a newly designed collapsible aortic valve. ASAIO J 1996;42:M381-5.
16. Bonhoeffer P, Boudjemline Y, Saliba Z, et al. Transcatheter implantation of a bovine valve in pulmonary position: a lamb study. Circulation 2000;102:813-6.
17. Boudjemline Y, Bonhoeffer P. Steps towards percutaneous aortic valve replacement. Circulation 2002;105:775-8.
18. Boudjemline Y, Bonhoeffer P. Percutaneous implantation of a valve in the descending aorta in lambs. Eur Heart J 2002;23:1045-9.
19. Lutter G, Kuklinski D, Berg G, et al. Percutaneous aortic valve replacement: an experimental study. I. Studies on implantation. J Thorac Cardiovasc Surg 2002;123:768-76.
20. Pavcnik D, Wright KC, Wallace S. Development and initial experimental evaluation of a prosthetic aortic valve for transcatheter placement: work in progress. Radiology 1992;183:151-4.
21. Sochman J, Peregrin JH, Pavcnik D, et al. Percutaneous transcatheter aortic disc valve prosthesis implantation: a feasibility study. Cardiovasc Intervent Radiol 2000;23:384-8.
22. Cribier A, Eltchaninoff H, Bash A, et al. Percutaneous transcatheter implantation of an aortic valve prosthesis for calcific aortic stenosis: first human case description. Circulation 2002;106:3006-8.
23. Grube E, Laborde JC, Zinkmann B, et al. First report on a human percutaneous transluminal implantation of a self-expanding valve prosthesis for interventional treatment of aortic valve stenosis. Cathet Cardiovasc Interv 2005;66:465-9.
24. Webb JG, Chandavimol M, Thompson CR, et al. Percutaneous aortic valve implantation retrograde from the femoral artery. Circulation 2006;113:842-50.
25. Webb JG, Munt B, Makkar R, et al. A percutaneous stent-mounted valve for treatment of aortic or pulmonary valve disease. Cathet Cardiovasc Interv 2004;63:89-93.
26. Lichtenstein SV, Cheung A, Ye J, et al. Transapical transcatheter aortic valve implantation in humans. Initial clinical experience. Circulation 2006;114:591-6.
27. Falk V, Schwammenthal EE, Kempfert J, et al. New anatomically oriented transapical aortic valve implantation. Ann Thorac Surg 2009;87:925-6.

Address for Correspondence

Henning Rud Andersen,
MD, PhD
Associate Professor of
Cardiology
Department of Cardiology
Skejby University Hospital
8200 Aarhus N
Denmark
Phone (+45) 89496111,
Fax -89496025
e-mail: henning.rud.
andersen@dadlnet.dk