

Date: Wed, 19 Apr 2000 11:06:15 -0500
From: ovidweb@tioga.lso.missouri.edu
To: hsl_ill@showme.missouri.edu
Subject: Document Order

Document Order
Date 04/19/00

Source Ovid

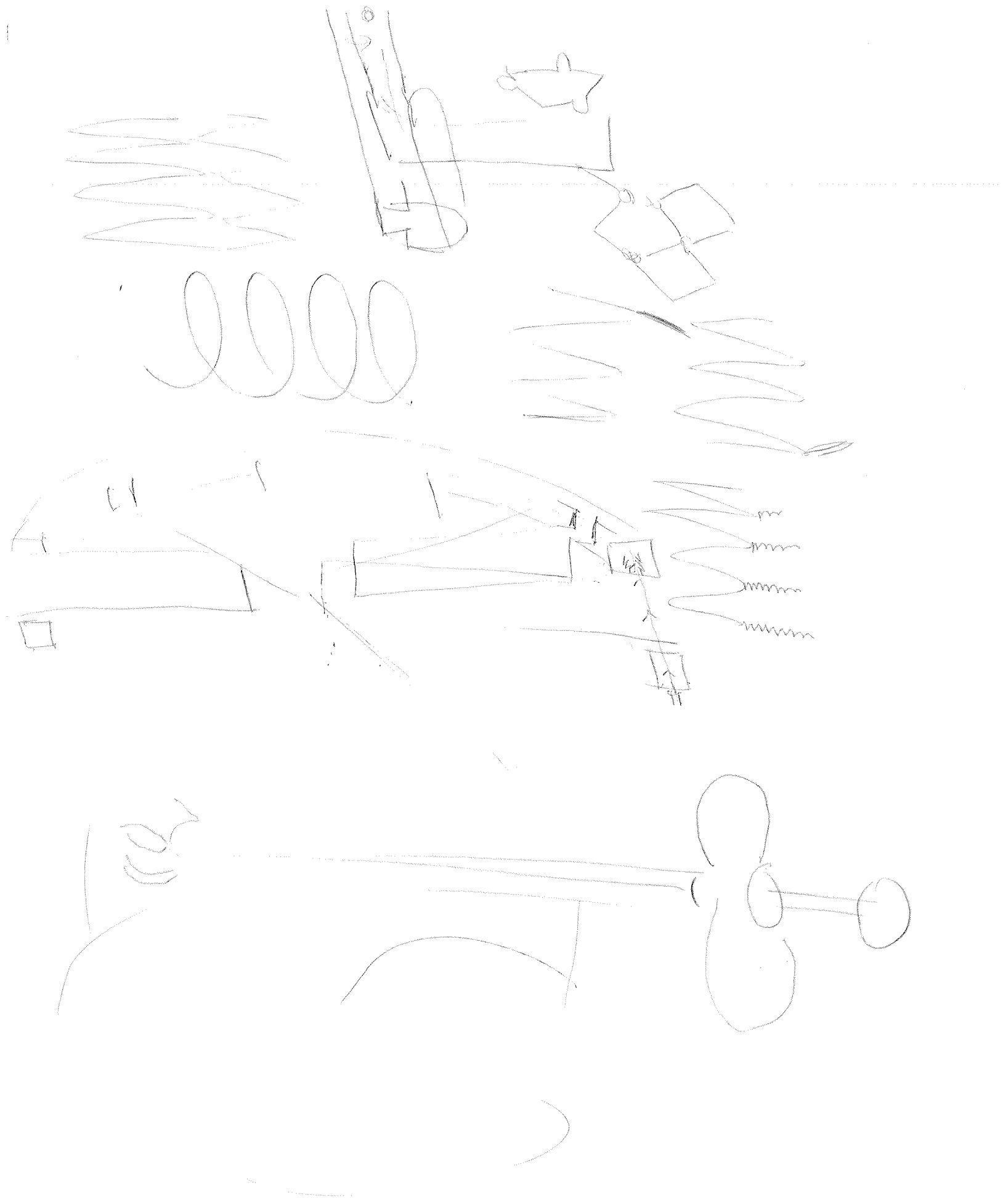
UI 95033723
Author Anderson RH
Journal ~~British Heart Journal~~
Title Balloon dilatation (valvoplasty) as first line treatment for severe stenosis of the aortic valve in early infancy: median term results and determinants of survival [letter; comment].
Volume 72
Issue 3
Page 300-1
ISSN 0007-0769
Year 1994 Sep
Local Msg Owned by MU HSL

Fullname Troy Norred MD
Campus Address
Local Address
Phone 882-7272
Fax
Email norred99@aol.com
Comments
Dept/Major Cardiology
Status Faculty
ID 440807683

Department Cardiology
Account Number c-3-40120-11
Delivery Mail

NORRED EXHIBIT 2207 - Page 1
Medtronic Inc. Medtronic Vascular Inc.

2-154



Imaging the dissected aorta

SIR,—I read with interest and sympathy Mr Treasure's editorial on imaging the dissected aorta.¹ I agree that it is a difficult to achieve a standard approach. I have found the following guidelines for acute dissection clinically reliable:

(a) Type B dissection is defined as dissection confined to the descending aorta—that is, any part of the aorta beyond the origin of the left subclavian artery.

(b) Type A dissection is any dissection that involves the ascending aorta, whether or not it also affects the descending aorta, and irrespective of the site of entry.

(c) Computed tomography (CT) is a reliable technique for the detection and assessment of type B dissections. It is certainly more reliable than angiography. This is because the flap in type B dissections is usually static and can be reliably imaged by CT, despite the fact that the true lumen may have regained a smooth, circular cross section.

(d) In type A dissection the flap in the ascending aorta is often mobile, giving a significant incidence of false negative CT examinations, but nevertheless . . .

(e) The ascending aorta is always dilated in type A dissection. If a dissection in the descending aorta is accompanied by an ascending aorta of normal size it is reasonable to exclude type A origin or extension of the false lumen.

In passing, I would like to endorse the efficacy of transoesophageal sonography in the diagnosis of traumatic aortic tear, as described by de Belder *et al.*² Indeed, I have yet to hear of a falsely negative study.

JB PARTRIDGE
Harefield Hospital,
Harefield,
Middlesex UB9 6JH

1 Treasure T. Imaging the dissected aorta. *Br Heart J* 1993;70:497-8.

2 de Belder A, Thomas M, Marrinan M. Traumatic rupture of the thoracic aorta diagnosed by transoesophageal echocardiography. *Br Heart J* 1993;70:393-4.

This letter was sent to the author, who replies as follows:

SIR,—Dr Partridge's guidelines indicate his keen interest in this problem and that he has considered it carefully. I will address his points item by item.

(a and b) In the original paper on which the Stanford classification is based¹ type B is defined as dissection that does not extend proximally to the subclavian artery. In a subsequent paper there was a subtle but important change in detail.² Type A includes any dissection that involves the ascending aorta, just as Dr Partridge writes, but type B includes all the rest, thus including some cases with arch involvement.^{1,2}

No classification is perfect but the virtue of the current version of the classification is that it defines a group (type A) in which a challenging but achievable operation on the ascending aorta protects the patient from three lethal consequences of dissection at this site:

- Rupture into the pericardium

associated with any residual uncorrected abnormality in the arch and descending aorta. Classification is an interesting discipline. In this instance type A is defined by inclusion of the particular characteristic—that is, involvement of the ascending aorta—and type B is defined by exclusion of this characteristic. (c, d, and e) His observations on the nuances of the interpretation of computed tomograms of the ascending and descending aorta are nicely observed and ring true.

Although I had no data or experience on which to base a comment, I was worried when de Belder *et al.* advocated transoesophageal echocardiography to diagnose a traumatic aortic tear.³ Dissection has length, so any cross sectional image will detect it. Traumatic aortic transection is a tear with an adjacent haematoma; it is not a propagating dissection. Because there are other sources of blood (rib and vertebral fractures) to cause the haematoma in trauma, it is visualisation of aortic wall discontinuity that is critical. High specificity, that is confidently excluding the diagnosis when it is absent, is required. We have argued elsewhere⁴ that the cross sectional image of CT cannot prove or exclude traumatic aortic dissection. In a critically injured patient this makes CT an unnecessary waste of time. The fact that transoesophageal echocardiography can be used at the bedside makes it attractive, provided a negative test is convincing and that any induced hypertension and local interference do not make the aorta go "pop".

TOM TREASURE
Cardiac Department,
St George's Hospital,
Blackshaw Road,
London SW17 0QT

1 Daily PO, Trueblood HW, Stinson EB, Wuerflein RD, Shumway NE. Management of acute aortic dissections. *Ann Thorac Surg* 1970;10:237-47.

2 Miller DC, Stinson EB, Oyer PE, Rossiter SJ, Reitz BA, Griep RB, Shumway NE. Operative treatment of aortic dissections. *J Thorac Cardiovasc Surg* 1979;78:365-82.

3 de Belder A, Thomas M, Marrinan M. Traumatic rupture of the thoracic aorta diagnosed by transoesophageal echocardiography. *Br Heart J* 1993;70:393-4.

4 Unsworth-White MJ, Buckenham T, Treasure T. Traumatic rupture of the thoracic aorta—computed tomography may be a dangerous waste of time. *Ann R Coll Surg Engl* (in press).

Anthracyclines and the heart

SIR,—I thank Dr Rhoden, Dr Hasleton, and Dr Brooks for an excellent review of anthracyclines and the heart.¹

I would like to point out an error. The evidence for doxorubicin-related cardiotoxicity involving myocardial adrenergic derangement comes from ¹²³I-meta-iodobenzyl-guanidine (MIBG) rather than from ¹²³I-methoxy-isobutyl isonitrile (MIBI).² These radiopharmaceuticals are quite dissimilar. MIBG shares similar uptake mechanisms into sympathetic nerve endings as noradrenaline. It is therefore ideally suited to imaging both the distribution of sympathetic nerve endings in the heart as well as neuroendocrine tumours such as pheochro-

the sympathetic nerve endings but roughly proportionally to myocardial blood flow. MIBI is therefore used to assess the patency of coronary arteries rather than the status of the sympathetic nervous system.³

PAUL THOMAS
Department of Nuclear Medicine,
John Hunter Hospital,
Locked Bag 1,
Newcastle Mail Centre,
NSW 2310,
Australia

We thank Dr Thomas for drawing attention to this error and we apologise to the authors of the review for introducing this mistake when the technical editor mistook the abbreviation MIBG for MIBI. Authors can help us to avoid such mistakes by spelling out all abbreviations and acronyms at the first mention—EDITOR

1 Rhoden W, Hasleton P, Brooks N. Anthracyclines and the heart. *Br Heart J* 1993;70:499-502.

2 Valdes-Olmos RA, Ten Bokkel-Huinuk WW, Greve JC, Hoefnagel CA. ¹²³I-MIBG and serial radionuclide angiography in doxorubicin-related cardiotoxicity. *Clin Nucl Med* 1992;17:163-7.

3 Dae M. Scintigraphic assessment of cardiac innervation using iodine-123 metaiodobenzylguanidine. In: Ernst E van der Wall, Sochor H, Righetti A, Niemyer MG, eds. What's new in cardiac imaging? Dordrecht: Kluwer Academic Publishers, 1992;377-85.

4 Gross MD, Shapiro B, Thrall JH. Adrenal scintigraphy. In: Gottschalk A, Hoffer PB, Potchen EJ, eds. Diagnostic nuclear medicine, Baltimore William and Wilkins, 1988;826-7.

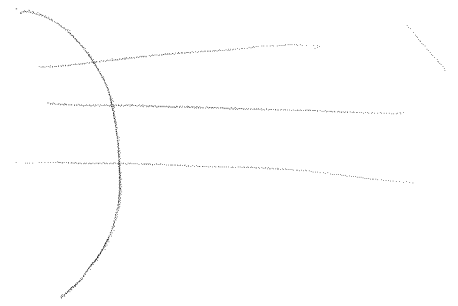
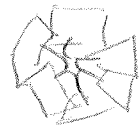

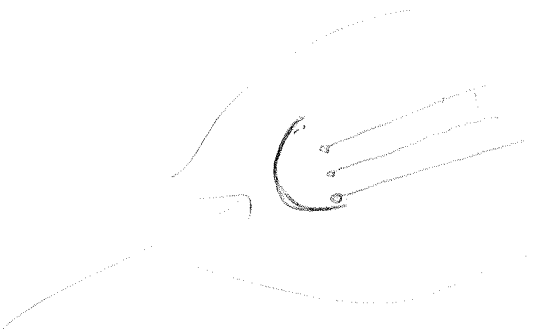
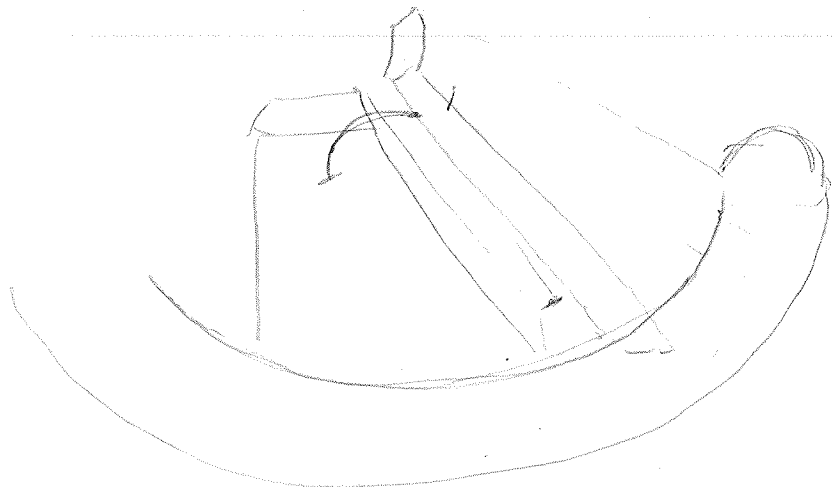
5 Rigo P, Larock M, Braat SH. Myocardial perfusion imaging with technetium-99m isonitriles: Attractive thallium substitutes? In: Ernst E van der Wall, *et al.* eds. What's new in cardiac imaging? Dordrecht: Kluwer Academic Publishers, 1992;69-85.

Balloon dilatation (valvoplasty) as first line treatment for severe stenosis of the aortic valve in early infancy: median term results and determinants of survival

SIR,—In their otherwise excellent article Bu'Lock and her colleagues¹ do not give any details of the morphology of the aortic valve itself, specifically the number of leaflets. This matter is of importance because in the so-called unicommissural and unicuspid variant of aortic valvar stenosis recent studies have shown that the leaflet tissue is attached within the aortic root in a circular rather than a semilunar fashion.² This arrangement would seem, on morphological grounds, to militate against successful balloon dilatation: but morphologists are constantly wary of predicting outcomes in life from their observations on cadaveric hearts. For this reason it would be invaluable to know whether Bu'Lock and her colleagues had information on the number of leaflets present in the valves dilated in their patients?

ROBERT H ANDERSON
Department of Paediatrics,
Royal Brompton National Heart and
Lung Institute, Dovehouse Street,
London SW3 6LY

1 Bu'Lock FA, Joffe HS, Jordan SC, Martin RP. Balloon dilatation (valvoplasty) as first line treatment for severe stenosis of the aortic valve in early infancy: median term results



This letter was shown to the authors, who reply as follows:

SIR,—We thank Professor Anderson for his pertinent reminder of the importance of morphological factors in congenital heart disease and their potential relevance to the treatment of patients with aortic stenosis. The reason that data on valve morphology were not included in our report is that we believe it is often difficult to be certain of leaflet morphology based solely on echocardiography in neonates with severe aortic stenosis. The poor correlation between echocardiographic predictions and observed morphology at the time of surgery was well described in the paper by Leung and Anderson.¹ In their study, echocardiographic examination of 20 infants with critical aortic stenosis identified 16 with bicuspid valves, four with tricuspid valves, and no unicuspid valves. This contrasts with the surgical findings in the same infants where six valves were described as unicuspid, 13 bicuspid, and 1 tricuspid.

In the patients we studied,² the aortic valve was considered to be bicuspid in six, tricuspid in five, and one may have had a unicuspid valve. Because few of these patients had visual inspection of the aortic valve (either surgically or at necropsy) we are unable to comment on the validity of the echocardiographic findings. There did not seem to be any correlation between echocardiographically determined valve morphology and outcome. The principal determinants of survival being left ventricular (rather than aortic valve) dimensions and presence and severity of associated lesions. The patient with the apparently unicuspid valve had an excellent response to balloon valvoplasty.

It does, however, seem logical to believe that aortic valve morphology may have an important influence on the degree of relief of valve obstruction obtained, on the propensity for early re-stenosis, and on the maintenance of longer term valve competence. Studies of the relation between valve morphology and the outcome of balloon dilatation might be of considerable interest. Precordial echocardiography may not be adequate for such cases, where transoesophageal echocardiography or intravascular ultrasound may be of additional value.

F A BU'LOCK
on behalf of
H S Joffe
S C Jordan
R P Martin
Bristol Royal Hospital
for Sick Children,
St Michael's Hill,
Bristol BS2 8BJ

1 Leung MP, McKay R, Smith A, Anderson RH, Arnold R. Critical aortic stenosis in early infancy. *J Thorac Cardiovasc Surg* 1991;101:526-35.

2 Bu'Lock FA, Joffe HS, Jordan SC, Martin RP. Balloon dilatation (valvoplasty) as first line treatment for severe stenosis of the aortic valve in early infancy: medium term results and determinants of survival. *Br Heart J* 1993;70:546-53.

Familial atrioventricular septal defect: possible genetic mechanism

SIR,—We read with interest the report of Kumar *et al* describing a family in which the mother and her two daughters by different fathers had atrioventricular septal defects not associated with trisomy 21.¹ They suggest that an autosomal dominant pattern of inheritance may be involved in this pedigree, although a multifactorial or cytoplasmic mechanism cannot be ruled out.

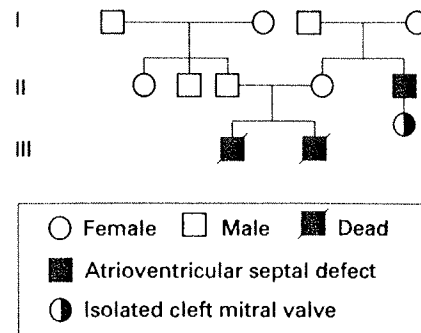
We recently described five families in which two or more members had isolated atrioventricular septal defect. Parent-to-son transmission of concordant cardiac defect was documented in four cases. The mother was affected in three cases and the father in one.²

Lately we found an additional example of atrioventricular septal defect in four members in two generations of the same family (figure). None of the family members showed phenotypic anomalies and all had a normal karyotype. They were examined by electrocardiography and echocardiography. A partial atrioventricular septal defect was diagnosed in one case (II 5) and a complete defect in two cases (III 1 and III 2). The daughter of a patient with atrioventricular septal defect had an isolated cleft of the mitral valve (III 3).

Anatomical differences between isolated mitral clefts and clefts associated with an atrioventricular septal defect have been described.³ The high frequency of isolated mitral cleft in families with atrioventricular septal defects,^{4,5} including our family, and its prevalence in patients with Down's syndrome (4/420 *v* 3/5200 in our experience), however, suggests that this malformation should be included in the spectrum of atrioventricular septal defects.

Monogenic autosomal dominant inheritance with incomplete penetrance could explain the atrioventricular septal defects in the families we studied and those reported by other workers. Normal parents of affected children could be obligate carriers of the gene involved in familial atrioventricular septal defects. The father-to-daughter transmission of cardiac malformation in two cases excludes cytoplasmic inheritance in these families. Moreover, atrioventricular septal defects in patients with and without Down's syndrome differ not only in terms of the prevalence of partial or complete forms^{6,7} but also in terms of the distribution of associated cardiac malformations.⁸ These anatomical differences and the absence of linkage in the molecular analysis of chromosome 21 in families with atrioventricular septal defect^{9,10} suggest that the gene or genes involved in the pathogenesis of atrioventricular septal defect in "normal" children are different from those in patients with Down's syndrome.

MARIA CRISTINA DIGILIO
BRUNO MARINO
ALDO GIANNOTTI
BRUNO DALLAPICCOLA
Paediatric Cardiology and Genetics,
Ospedale Bambino Gesù,
00165 Rome, Italy



Pedigree

- 1 Kumar A, Williams CA, Victorica BE. Familial atrioventricular septal defect: possible genetic mechanisms. *Br Heart J* 1994; 71:79-81.
- 2 Digilio MC, Marino B, Cicini MP, Giannotti A, Formigari R, Dallapiccola B. Risk of congenital heart defects in relatives of patients with atrioventricular canal. *Am J Dis Child* 1993;147:1295-7.
- 3 Smallhorn JF, DeLeval M, Stark J, Somerville J, Tylor JFN, Anderson RH, *et al*. Isolated anterior mitral cleft: two dimensional echocardiographic assessment and differentiation from "clefts" associated with atrioventricular septal defect. *Br Heart J* 1982;48:109-16.
- 4 Disegni E, Pierpont MEM, Bass JL, Kaplinky E. Two dimensional echocardiography in detection of endocardial cushion defect in families. *Am J Cardiol* 1985;55:1649-52.
- 5 Cousineau AJ, Lauer RM, Pierpont ME, Burns TL, Ardinger RH, *et al*. Linkage analysis of autosomal dominant atrioventricular canal defects: exclusion of chromosome 21. *Hum Genet* 1994;93:103-8.
- 6 Marino B, Vairo U, Como A, Nava S, Guccione P, Calabrò R, Marcellini C. Atrioventricular canal in Down's syndrome. *Am J Dis Child* 1990;144:1120-2.
- 7 Carmi R, Ferencz C, Boughman JA. Endocardial cushion defect: further studies of "Isolated" versus "syndromic" occurrence. *Am J Med Genet* 1992;43:569-75.
- 8 De Biase L, Di Ciommo L, Ballerini L, Bevilacqua M, Marcellini C, Marino B. Prevalence of left-sided obstruction lesion in patient with atrioventricular canal without Down's syndrome. *J Thorac Cardiovasc Surg* 1986;91:467-70.
- 9 Wilson L, Curtis A, Korenberg JR, Schipper RD, Allan L, Chenevix-Trench G, *et al*. A large, dominant pedigree of atrioventricular septal defect (AVSD): exclusion from the Down's syndrome critical region on chromosome 21. *Am J Hum Genet* 1994;53: 1262-8.
- 10 Melchionda S, Digilio MC, Marino B, Giannotti A, Mingarelli R, Dallapiccola B. Analisi di linkage con marcatori delle regioni 21q ed 8p in una famiglia con canale atrioventricolare. *G Ital Cardiol* 1993;23:7.

Explore Litigation Insights

Docket Alarm provides insights to develop a more informed litigation strategy and the peace of mind of knowing you're on top of things.

Real-Time Litigation Alerts



Keep your litigation team up-to-date with **real-time alerts** and advanced team management tools built for the enterprise, all while greatly reducing PACER spend.

Our comprehensive service means we can handle Federal, State, and Administrative courts across the country.

Advanced Docket Research



With over 230 million records, Docket Alarm's cloud-native docket research platform finds what other services can't. Coverage includes Federal, State, plus PTAB, TTAB, ITC and NLRB decisions, all in one place.

Identify arguments that have been successful in the past with full text, pinpoint searching. Link to case law cited within any court document via Fastcase.

Analytics At Your Fingertips



Learn what happened the last time a particular judge, opposing counsel or company faced cases similar to yours.

Advanced out-of-the-box PTAB and TTAB analytics are always at your fingertips.

API

Docket Alarm offers a powerful API (application programming interface) to developers that want to integrate case filings into their apps.

LAW FIRMS

Build custom dashboards for your attorneys and clients with live data direct from the court.

Automate many repetitive legal tasks like conflict checks, document management, and marketing.

FINANCIAL INSTITUTIONS

Litigation and bankruptcy checks for companies and debtors.

E-DISCOVERY AND LEGAL VENDORS

Sync your system to PACER to automate legal marketing.