

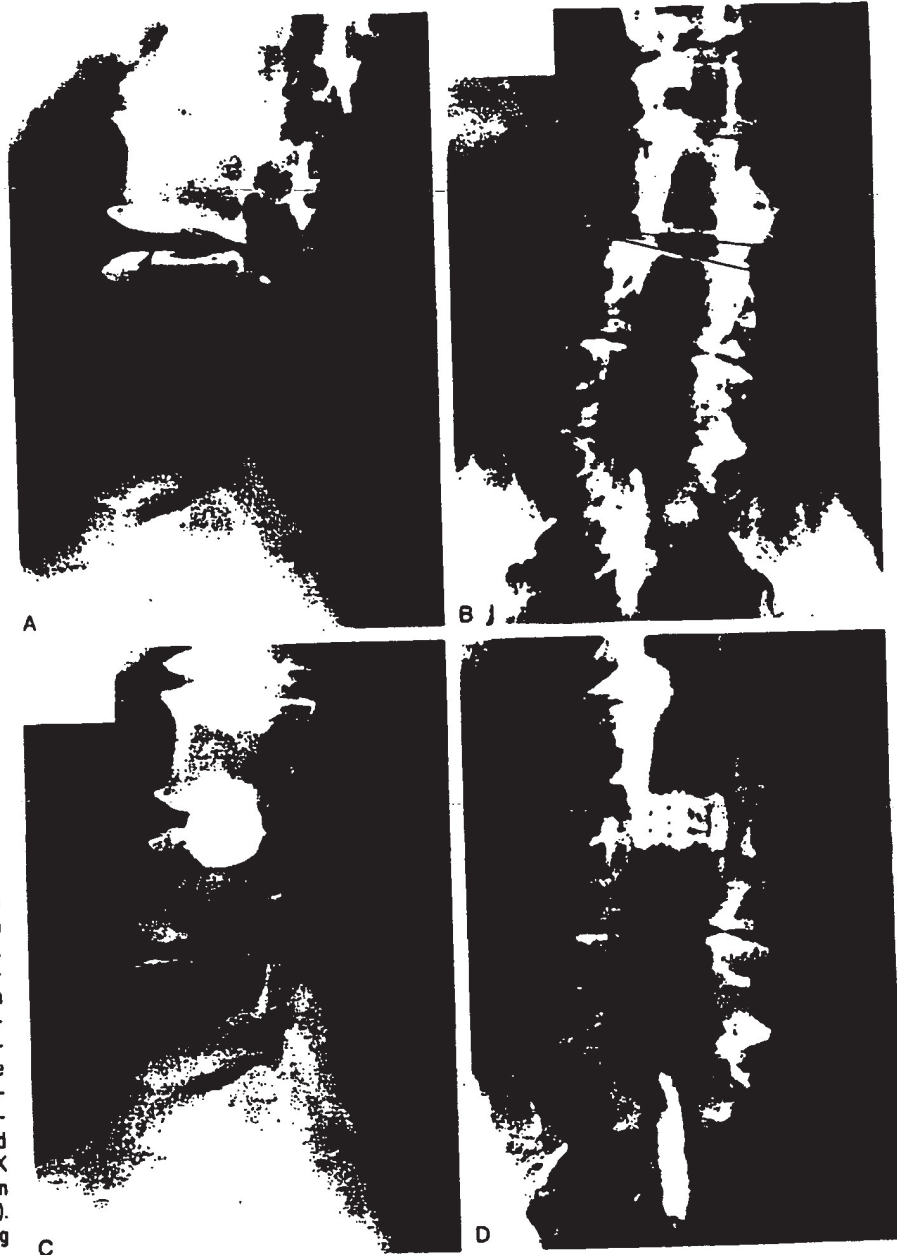

Figure 1. This 75-year-old man had back pain and right anterior thigh pain 2 years after he had undergone laminectomies from L3 to S1 with a posterolateral fusion from L4 to S1. The lateral (A) and anteroposterior (B) radiographs show "vacuum disk" sign at L3-L4 with lateral translation of the L3 vertebral body on L4. His characteristic pain was reproduced by an L3-L4 discogram performed by an independent radiologist. Lateral (C) and anteroposterior (D) radiographs were obtained after the procedure using the endoscopic retroperitoneal approach was performed and a transversely oriented BAK fusion cage was inserted (15 mm in diameter and 24 mm length). The patient's back and right leg pain resolved after surgery.

volving the lumbosacral plexus. Ten of the 13 patients in the degenerative category had undergone previous destabilizing laminectomy procedures elsewhere before referral to the authors' institutions. Flexion-extension lateral radiographs demonstrated more than 3.5 mm of translation, and anteroposterior radiographs showed 10 degrees or more of scoliotic disc space collapse with "vacuum disc sign." Positive discograms documented a provocative pain response at the unstable level (Figure 1). The one patient in the degenerative category who had not undergone previous destabilizing surgery had a massive L2-L3 central disc herniation with left quadriceps weakness.

The retroperitoneal approach proved to be very versatile in the range of vertebral levels addressed throughout the 18 cases. Four patients underwent procedures at L1-L2, seven patients at L3-L4, and two patients at L4-L5. There were four endoscopic decompressions and fusions at L2-L3. One patient with vertebral osteomyelitis underwent a decompressive procedure from L2 to L4.

Surgical Technique. The approach is a combination of video-assisted thoracoscopic and laparoscopic methods. The patient is put under general endotracheal anesthesia, then turned in the

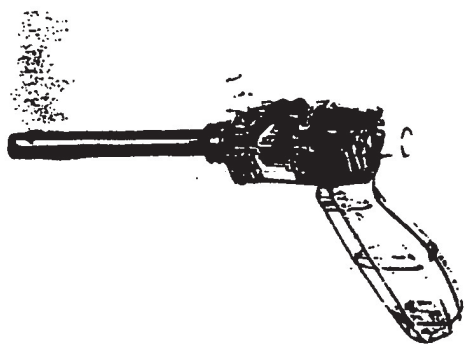


Figure 2. A view of a transparent optical trochar (Optiview, Ethicon Endosurgery, Cincinnati, OH) that was used in dissecting the retroperitoneal space. Notice the "winged keel cutting edges," which only will penetrate a fascial layer, such as the peritoneum, if the trochar is forcibly twisted backwards and forwards.

lateral decubitus position on a radiolucent, graphite, Jackson Maximum lateral access table (O.S.I. Corporation, Union City, CA) made specifically for the endoscopic approach, with side rails designed to accommodate robotic arms and to facilitate c-arm fluoroscopy. A 1-cm incision is made at the anterior portion of the 12th rib for approaching from L1 or L2. Below L2, a lateral c-arm fluoroscopic image is obtained, with a metal marker overlying the patient's skin in the midaxillary line. This method optimizes the placement of the working portal directly over the unstable disc or vertebral segment. The three techniques used to dissect the retroperitoneal space are: finger dissection, balloon insufflation, or the use of an optical, transparent, dissecting trochar called an Optiview (Ethicon Endosurgery, Cincinnati, OH; Figure 2).

The 10-mm laparoscope is inserted into the Optiview dissecting trochar and refocused once the trochar enters the subcutaneous tissue. The trochar has two "winged keel" cutting surfaces that will not penetrate a fascial layer such as the peritoneum unless the trochar is twisted. Therefore, the three abdominal muscular layers overlying the peritoneum are penetrated in sequence under direct visualization until the preperitoneal fat is encountered. The trochar is used to create a potential space that is superficial to the peritoneum until the laterally oriented fibers of the psoas major muscle are viewed. Usually, the genitofemoral nerve is visualized on the surface of the psoas muscle. At this juncture, a dissection balloon, such as that manufactured by Origin (Menlo Park, CA), can be filled with 1 liter of normal saline or air to dissect the retroperitoneal layer, more correctly referred to as the retrotransversalis fascia. Alternatively, carbon dioxide insufflation can be forced into the retroperitoneal cavity up to a pressure of 20 mm of mercury to create a working space to triangulate endoscopically.³⁰ Once the retroperitoneal space is enlarged, at least three portals are used—working portal, for pituitary rongeur; curettes; a high-powered burr; or Kerrison rongeurs. A second portal is necessary for the 10-mm laparoscope. A third portal is used for retraction of the psoas major muscle off of the spine in a posterior direction. The relatively avascular intervertebral discs are exposed first. Then, the respective midportions of the adjacent vertebral bodies are exposed, and the lumbar segmental vessels

are ligated and divided. Occasionally, a fourth 10-mm portal is used for suctioning in highly vascular cases requiring corpectomies for tumors or infections. Occasionally, for longer strut grafts or instrumentation, the 10-mm working portal is extended in size as much as 5 cm, and an endoscopically assisted, mini-laparotomy type of retroperitoneal exposure facilitates the corpectomy or spinal instrumentation. If the size of the working portal is extended, of course, the CO₂ insufflation is lost, and the working space in the retroperitoneum has to be maintained by using retractors. This technique is advantageous because the spinal decompression can be accomplished without airtight seals, and because standard thoracoscopic instruments can be used on the lumbar spine. In other words, throughout the remainder of the procedure, spine instruments of heterogeneous shaft diameters can be used, and airtight seals around trocars are not required.

Once the vertebral level is confirmed fluoroscopically, the transversalis fascia, perinephric fascia, and retroperitoneal contents are retracted anteriorly (Figure 3). Electrocautery is used to mark the intervertebral discs adjacent to the involved lesion. For example, for an L1 corpectomy, the L1-L2 and the T12-L1 intervertebral disc spaces are marked. A left-sided approach to the surgery is preferred to a right-sided approach, because it is easier to dissect the aorta off the spine than to dissect around the more friable inferior vena cava; this is particularly true in cases of pyogenic vertebral osteomyelitis or cases of neoplasm that occur after radiation therapy with retroperitoneal fibrosis. The psoas muscle is retracted posteriorly, and the ureter is retracted anteriorly.

If a corpectomy is being performed²¹ after the two adjacent discectomies, the surgeon must have access to three methods of hemostasis: 1) Endo-Avitene Microfibrillar Collagen (Alcon, Inc., Humacao, Puerto Rico), 2) Gelfoam (Upjohn Corp., Kalamazoo, MI) soaked in Thrombin (GenTrac Corp., Middletown, WI), and 3) bipolar endoscopic electrocautery. At this point, the segmental vessels are dissected from the underlying bone and elevated with a right-angled clamp. It is important to use two vascular clips or an endoloop on the high-pressure side of the vessels; the vessels are divided with endoshears. As a general rule, with any spine procedure the segmental vessels are ligated and divided in the anterior half of the vertebral body to allow collateral circulation to the neuroforamen and spinal cord to occur to its maximum potential. If the lesion is a tumor or infection, then a culture and a frozen section are obtained at this time in the procedure. A 45-degree, 4-mm-wide endoscopic Kerrison rongeur is used to resect the pedicle. Starting cephalad, the instrument is pointed caudad to protect the exiting spinal roots. Either Kaneda (Acromed Corp., Cleveland, OH) heavy-duty rongeurs or a high-powered, 5-mm burr, such as the Zimmer (Wausau, IN) Ultra-power or Anspach with long extensions, can be used to hollow out the vertebral body. Curettes and small 2-3-mm Kerrison rongeurs are used to complete the corpectomy. It is important to decompress the spinal canal all the way across to the base of the opposite pedicle. Decompression is accomplished only when the opposite pedicle is palpated or visualized. An autogenous iliac strut graft is tamped into place, filling the anterior portion of the corpectomy defect.

Alternatively, if the patient only requires a discectomy or one-level fusion, an anterior interbody fusion can be accomplished endoscopically. The disc space height is restored by using a distraction plug placed from the side. Optimally, two

distra-
and o-
ble-h-
posit-
terior
plug-
tusive
tube
and t
the d
inter
bone
pack
rogr
thru

cor-
taft
plis
BAL
adv
Ar-
sol-
adi
sol
rec
ex-
tu

T
w
ti
a
e
v

distraction plugs are tamped into the disc space: one anteriorly and one posteriorly. At this point, either a single-barrel or double-barrel drill tube is placed over the distraction plugs. The position of the distraction plugs is monitored with anteroposterior and lateral fluoroscopy. The center of the distraction plugs will correspond with the center of the BAK interbody fusion cages or endoscopic bone dowels.¹ The double-barrel tube is tamped into place to engage its teeth into the superior and inferior vertebral bodies to maintain the normal height of the disc space during the reaming and tapping of holes into the intervertebral endplates. The BAK fusion cage or laparoscopic bone dowels, which are composed of femoral allograft, are packed with autogenous iliac graft. The morselized iliac autograft can be harvested with minimally invasive techniques through a 12-mm incision by using a disposable T-shaped awl.

After surgery, the patient is placed in a warm and form corset (interbody fusion) or a thoracolumbar sacral orthosis (after a corpectomy), until radiographic fusion is accomplished. Intraoperatively, it is important to countersink the BAK fusion cages or laparoscopic bone dowel. The authors advocate packing additional bone graft superficial to the cage. At 3–6 months after surgery, arthrodesis can be confirmed if solid trabecular bone is observed to bridge one vertebrae to the adjacent level; this is the most reliable radiographic sign of a solid arthrodesis. Three-dimensional, computed-tomography reconstruction images of the bone within the cages and flexion-extension lateral radiographs also can provide useful information.

■ Results

The mean length of the postoperative follow-up period was 24.3 months (range, 12–40 months). Fourteen patients underwent left-sided retroperitoneal approaches, and, in four patients, the pathology was addressed more easily on the right side. There were four patients in whom a single incision was made of 5 centimeters or less. Fourteen patients had either three or four portals measuring approximately 12 mm in length. These fourteen patients had CO₂ insufflation to assist the retrotransversalis dissection. The patients with one incision of 5 centimeters or less had lesions compatible with infection or tumor, and the use of CO₂ insufflation was avoided to prevent pressurizing the tumor cells or bacteria systemically into the patient's bloodstream.^{9,10,11,15}

Fusions were performed in 15 of 18 cases by using structural bone graft and/or interbody fusion cages. A 38-year-old radiologist's wife with a neurofibroma arising from the lumbosacral plexus adjacent to the left common iliac vein did not demonstrate preoperative or intraoperative instability; therefore, a fusion procedure was not indicated.

Ten patients underwent fusion surgery with custom BAK interbody fusion cages. The long axes of the cages were in the transverse direction (Figure 4).⁴ In each case, the cages were packed with autogenous iliac bone graft harvested using a minimally invasive, T-shaped trochar, that was 10 mm in diameter. Four patients underwent placement of laparoscopic bone dowels fashioned from

femoral allograft. The long axes of the implants were positioned in a transverse direction.

There were no cases of implant migration or pseudoarthrosis. There were no cases of a radiolucent interface between the implant and the vertebral body. There were no cases of subsidence more than 1 mm, and there was trabecular bony bridging across the adjacent vertebrae laterally by 6 months after surgery.

One additional patient did not undergo an endoscopic stabilization procedure. He was a 47-year-old man with an unstable burst fracture who had undergone left anterior Kaneda instrumentation at the referring institution 3 months earlier. He had had an incomplete neurologic deficit; a preoperative computed tomography scan had demonstrated continued right-sided cauda equina compression. A right-sided endoscopic decompression was performed at the authors' institution, and additional stabilization was not required.

For all 18 cases, the mean duration of the surgical procedure, including the harvesting of iliac crest bone autograft, was 115.2 minutes (range, 60–260 minutes). The mean estimated blood loss, which, at the authors' institutions, is determined by the attending anesthesiologist, was 205 cc (range, 25–1000 cc). The mean length of hospital stay was 2.9 days (range, outpatient procedure to 5 days).

Complications

There were three patients with postoperative complications. Case 2 was a 71-year-old man on renal dialysis who presented with sepsis. Endoscopic, retroperitoneal, L3–L4 discectomy; debridement; and fusion were performed to culture and manage an L3–L4 pyogenic osteomyelitis. Six weeks after surgery, after treatment with intravenous antibiotics, the patient underwent posterior segmental stabilization with Texas Scottish Rite Hospital implants from L1–L5 for more definitive stabilization and fusion. The single-level, anterior, interbody, endoscopic fusion was not believed to be adequate to prevent long-term lumbar kyphosis and instability.

The second complication occurred intraoperatively in Case 3, when a laparoscopic bone dowel partially fractured at the point of attachment of the driver into the central drilling peg in the femoral cortical allograft. The fractured piece of allograft was extremely small (approximately 0.5 cm × 0.5 cm × 0.5 cm), and the patient's spinal stability was not jeopardized. There were no long-term sequelae, and the patient had a solid arthrodesis, which was facilitated by morselized iliac autograft placed in the central chamber of all laparoscopic bone dowels.

The third complication occurred in a 69-year-old man who underwent transverse BAK cage insertion for post-laminectomy instability at L3–L4. The patient developed a hematoma in the psoas muscle at L3–L4 after surgery. This resulted in a temporary genitofemoral nerve palsy, which resolved spontaneously within 3 months.

■ Discussion

Retroperitoneal lumbar fusion and stabilization offers several advantages over conventional anterior transperitoneal laparoscopic approaches of the lumbar spine.⁸ Retroperitoneal approaches obviate the risk of small bowel obstruction or postoperative intraperitoneal adhesions.^{16,17} Additionally, there should be a reduced risk of retrograde ejaculation, because the autonomic plexus is not dissected, in contrast to preliminary reports of transperitoneal laparoscopic approaches.^{13,22,30} The patient is in the lateral decubitus position, which facilitates exposure of the lumbar spine, as gravity helps retract the abdominal contents anteriorly. With the straight, lateral position, as opposed to the supine Trendelenburg position required for transperitoneal laparoscopy, it is easier to get orthogonal to the disc space and spine with laterally directed placement of interbody threaded fusion cages. The surgeon can use two longer cages in the transverse axis, with a larger-diameter cage anterior and a smaller-diameter cage posterior, thus "customizing" or "dialing in" the optimal degree of intervertebral lordosis (Figure 5). The same effect of altering the sagittal plane alignment was achieved in the majority of patients in this study by using distraction plugs of different diameters to adjust the degree of lordosis even before reaming the cage diameter. Two longer cages placed laterally via the retroperitoneal approach should be biomechanically more stable, because the surface area of the vertebral body cage contact area is greater than that achieved when using a transperitoneal approach. In addition, the anterior longitudinal ligament and posterior longitudinal ligament are not violated with the lateral retroperitoneal approach. With the transperitoneal approach, if the surgeon reams, taps, or drills too deeply, the spinal canal contents are at risk. With the lateral retroperitoneal approach, however, the orthopedic drilling, reaming, tapping, and cage insertion are directed toward the contralateral psoas muscle instead of the neurologic structures.^{8,22}

In the report of the laparoscopic BAK study¹³ submitted to the Food and Drug Administration, the incidence of iatrogenic intraoperative disc herniation in patients undergoing surgery at one level was 2.8% (6 of 215 patients) and that in patients undergoing transperitoneal, two-level BAK was 12% (3 of 25 patients). Overall, for BAK implants inserted via a straight anterior-to-

posterior direction, the incidence of reoperation for iatrogenic penetration or for pushing intervertebral disc material into the spinal canal was 2.3%. Furthermore, lateral retroperitoneal procedures obviate the need to dissect and mobilize the common iliac vein and artery, as is necessary with transperitoneal exposure of the L4-L5 intervertebral disc. The authors have found that it is easier to make the long axis of two retroperitoneal cages or bone dowels parallel via a shotgun or double-barrel trochar than via a transperitoneal independent trochar.


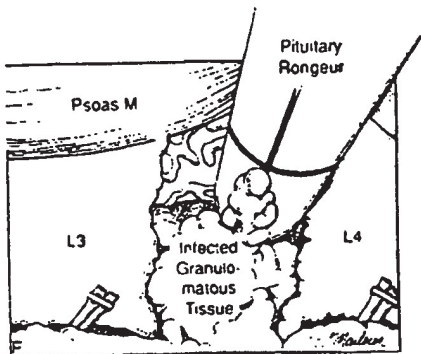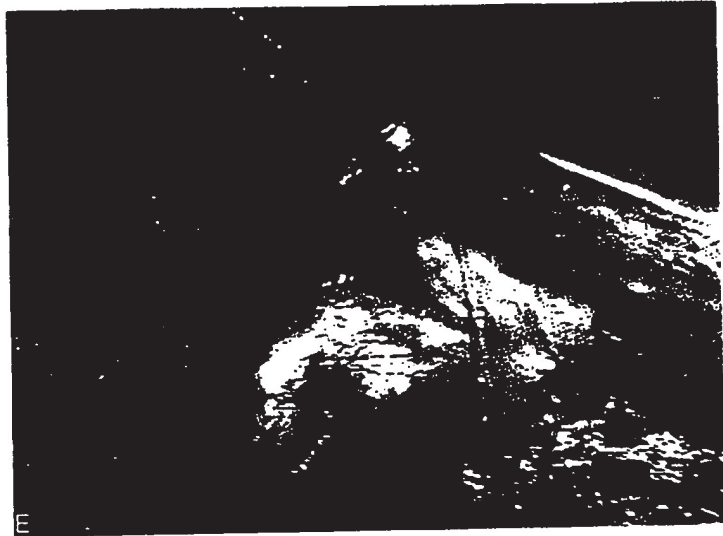
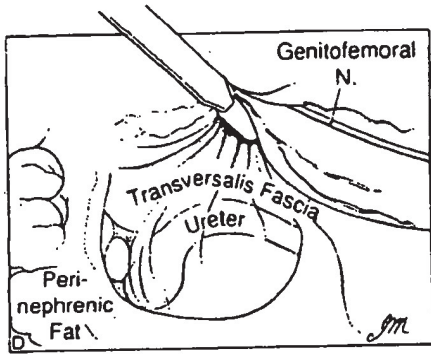
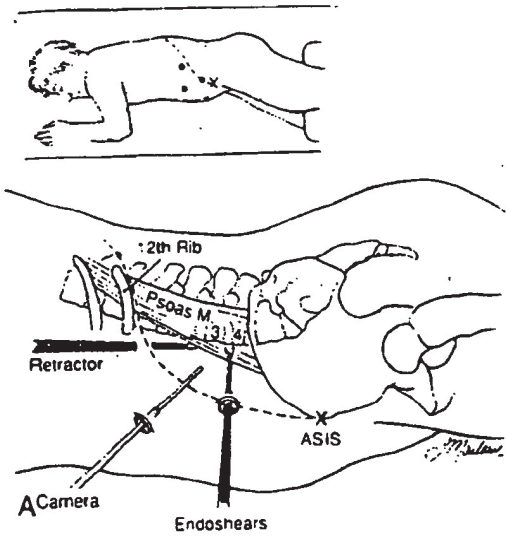
Mayer¹⁸ reported on 20 patients who underwent retroperitoneal, microsurgical, anterior lumbar interbody fusion between January 1, 1995 and January 31, 1996. In this procedure, an extensive quadrilateral retraction frame was used, but anterior stabilization implants were not. All patients had undergone an additional posterior pedicle screw instrumentation procedure 1-2 weeks earlier.

Boden et al² described a video-assisted, lateral, intertransverse-process arthrodesis in a rabbit and a non-human primate model. This was a posterior approach, which did not involve spinal stabilization.

Ordway et al²⁷ compared the biomechanical characteristics of a transversely oriented carbon-fiber cage with those of an anteriorly oriented cage in the bovine lumbar spine and found that, in most cases, the differences were not statistically significant. In addition, Ordway et al compared two anteriorly oriented cages with just one transversely oriented cage, which is a biased comparison. However, the carbon fiber cage has been studied extensively at the current authors' laboratory as well³; it is basically an unreamed spacer that is not screwed into place. The BAK system is inherently more stable than the carbon fiber cage because it uses preinsertional distraction via distraction plugs, which results in better ligamentotaxis. The BAK involves a tap that cuts threads into the two adjacent vertebral end plates, and the BAK reduces the strain and micromotion on the bone graft contained within the cage more successfully than does the rectangular carbon-fiber design.¹⁴

There are several potential disadvantages of the minimally invasive, retroperitoneal approach. Particularly at L4-L5, it may be necessary to remove part of the iliac crest or place the docking portal through the iliac wing to be orthogonal to the L4-L5 disc space.^{22,30} In addition, a large mass of psoas muscle containing lumbosacral

Figure 3. A, Schematic diagram showing the orientation for the retroperitoneal approach. The "X" marks the anterosuperior iliac spine, and the three portals are shown by black dots. B, Initial lateral radiograph of a 76-year-old, dialysis-dependent man with biopsy-confirmed osteomyelitis at L3-L4. Initially, he was treated at another institution with intravenous antibiotics and a thoracolumbosacral orthosis. When he arrived at the authors' institution, he was in septic shock. C, A sagittal magnetic resonance image revealing vertebral collapse with an associated retropulsed vertebral body fragment and thecal sac compression. D, A schematic diagram depicting the laparoscopic view through the transversalis fascia as the L3-L4 intervertebral disk is exposed. E, A laparoscopic view of the retroperitoneal space. The black arrows demonstrate the interval used to reach the vertebral body. The psoas major (P) is posterior, and the ureter (U) is anterior. Perinephric fat (K) is dissected bluntly to expose the interval. F, A schematic diagram showing debridement of the infected granulomatous tissue with the anterior thecal sac exposed between the L3 and L4 vertebral bodies posterior to the pituitary rongeur. G, A laparoscopic photograph showing a pituitary rongeur debriding the infected L3-L4 intervertebral disc.



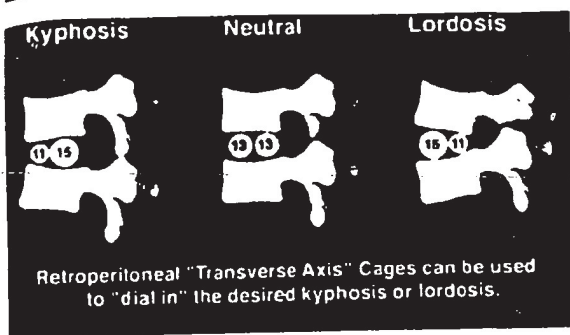


Figure 5. A schematic diagram illustrating how differential sizing of transversely oriented distraction plugs, interbody bone dowels, or fusion cages can "dial in" or adjust the desired amount of lumbar kyphosis or lordosis through a minimally invasive retroperitoneal approach.

undergone anterior transperitoneal laparoscopic L4–L5 fusion, when the greater omentum became adherent to the posterior peritoneum.

Tiusanen et al²⁴ reported an incidence of retrograde ejaculation of 5.9% as a complication of anterior interbody fusions and found that it occurred only after transabdominal procedures. In the report of the first series of 240 laparoscopic BAK interbody fusions and stabilizations¹³ submitted to the Food and Drug Administration, there were 12 cases (5%) of retrograde ejaculation that occurred as a complication of laparoscopic procedures. Although the numbers are too small to analyze statistically, there probably is a higher incidence of this complication at L5–S1 exposure than at L4–L5 exposure; it has been described to occur after anterior fusions to L4 and with periaortic lymph node dissection. Retroperitoneal exposure, either endoscopic or conventional, is associated with a lower incidence of this postoperative complication.^{18,30}

It is difficult to compare the morbidity of traditional *versus* minimally invasive, endoscopic, anterior, retroperitoneal approaches in the orthopaedic literature directly, because the length of hospital stay, operative time, and length of time out of work have not been reported. However, there are three studies of traditional, retroperitoneal, anterior decompressions of the spine in which the current authors have participated and reported: those of McAfee et al²⁰ with 70 patients, McAfee¹⁹ with 185 patients, and McAfee and Zdeblick²³ with 23 patients. Overall, it is the authors' impression that the incidence of complications and morbidity is much lower for endoscopic procedures; in particular, associated medical perioperative complications are reduced, including urinary tract infections, post-operative atelectasis, and pneumonia. However, further experience is clearly necessary to confirm this impression. The authors currently are participating in a prospective, multicenter trial by the National Institute of Health to investigate further the com-

plication rates of conventional *versus* minimally invasive techniques.

In summary, in this report of 18 cases of minimally invasive, lateral retroperitoneal, lumbar procedures, the main advantages were:

- 1) the length of stay was less than that associated with larger muscle-splitting "open approaches,"
- 2) the need for mobilization of the great vessels was reduced compared with that of transperitoneal laparoscopic approaches,
- 3) the procedure allowed for two larger cages to be inserted parallel to one another in a transverse direction, horizontal, rather than perpendicular, to the spinal canal.
- 4) by varying the diameter of the retroperitoneally placed interbody fusion cages, interbody allograft bone dowels, or distraction plugs, customization of the amount of lumbar lordosis was possible without increasing the risk of implant dislodgement or pseudoarthrosis.

Eighteen cases is not a large series, but the results are favorable compared with preliminary results of alternative techniques.

References

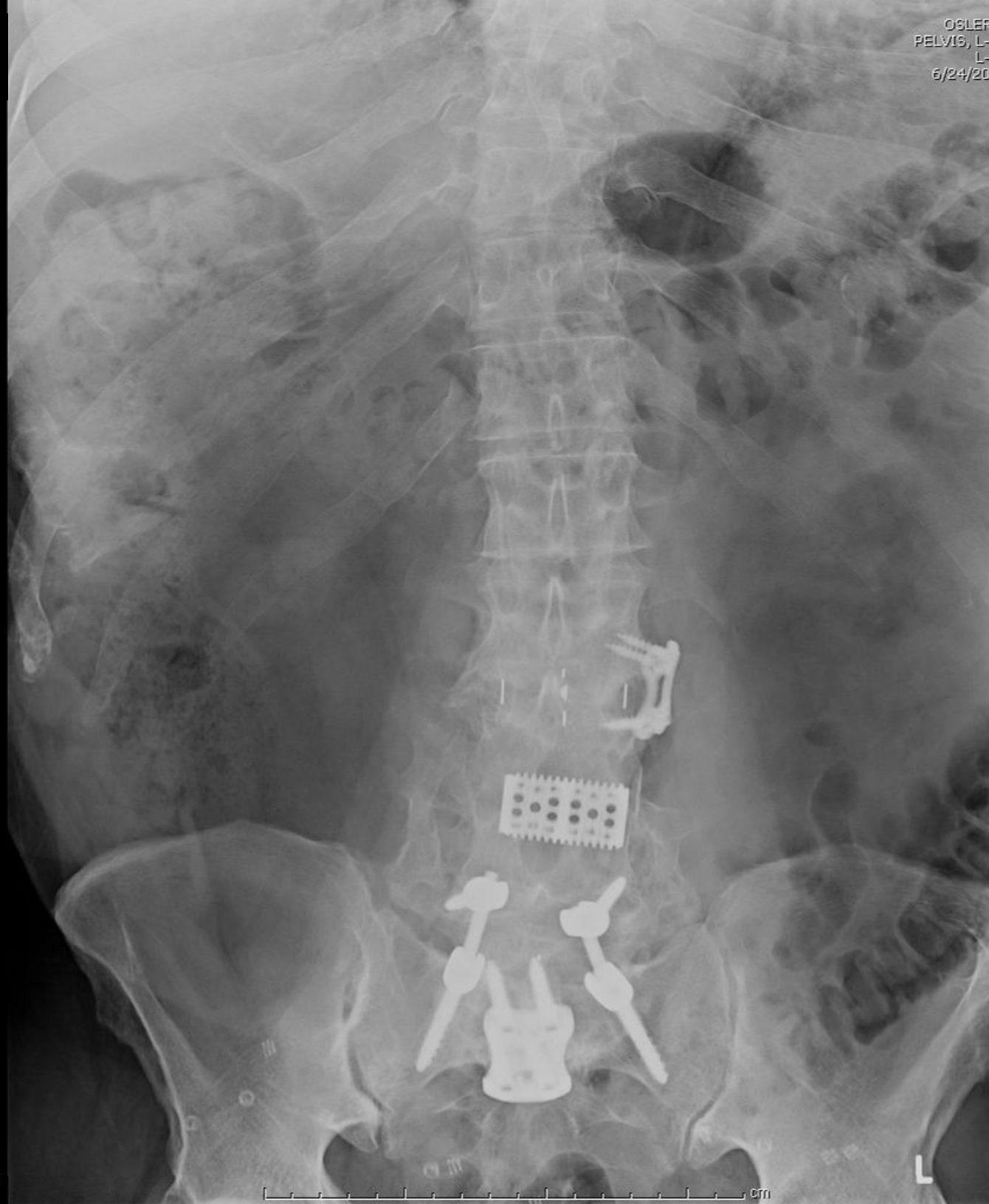1. Bagby G. Arthrodesis by the distraction-compression methods using a stainless steel implant. *Orthopaedics* 1988;11:931-4.
2. Boden SD, Moskovitz PA, Morone MA, Toeibitaby Y. Video-assisted lateral intertransverse process arthrodesis: Validation of a non-minimally invasive lumbar spinal fusion technique in the rabbit and non-human primate (Rhesus) models. *Spine* 1996;21:2689-97.
3. Brantigan JW, McAfee PC, Cunningham BW, Wang H, Orbegoso CM. Interbody lumbar fusion using a carbon fiber cage implant versus allograft bone: An investigational study in the spanish goat. *Spine* 1994;19:1436-44.
4. Brodke DS, Dick JC, Kunz DN, McCabe R, Zdeblick TA. Posterior lumbar interbody fusion: A biomechanical comparison including a new threaded cage. *Spine* 1997;22:26-31.
5. Cook TA, Dehn TC. Port-site metastases in patients undergoing laparoscopy for gastrointestinal malignancy. *Br J Surg* 1996;83:1419-20.
6. Gaur DD. Laparoscopic operative retroperitoneoscopy: Use of a new device. *J Urol* 1992;148:1137-9.
7. Geis WP, Kim HC, Brennan EJ, McAfee PC, Wang Y. Robotic arm enhancement to accommodate improved efficiency and decreased resource utilization in complex minimally invasive surgical procedures. In: Sieberg H, Weghorst S, Morgan K, eds. *Health Care in the Information Age*. Cincinnati, OH: IOS Press and Ohmsha, 1966:471-81.
8. Goldstein JA, Parker LM, McAfee PC. Minimally invasive endoscopic surgery of the lumbar spine. *Operative Techniques in Orthopaedics* 1997;7:27-35.
9. Hewett PJ, Thomas WM, King G, Eaton M. Intraperitoneal cell movement during abdominal carbon dioxide insufflation and laparoscopy: An In Vivo Model. *Journal of Diseases of the Colon and Rectum*. 1996;39(Suppl):S62-6.

10. Jacobi CA, Ordemann J, Bohm B, et al. The influence of laparotomy and laparoscopy on tumor growth in a rat model. *Journal of Surgical Endoscopy* 1997;11:618-21.
11. Jacobi CA, Ordemann J, Bohm B, et al. Does laparoscopy increase bacteremia and endotoxemia in a peritonitis model? *J Surg Endosc* 1997;11:235-8.
12. Jacobs M, Verdeja JC, Goldstein HS. Minimally invasive colon resection (laparoscopic colectomy). *Surg Laparosc Endosc* 1991;1:144-50.
13. Jansen R. FDA Submission. 240 BAK Laparoscopic Procedure. Personal Communication. January 17, 1997.
14. Kanayana M, Cunningham BW, Haggerty CJ, Kaneda K, McAfee PC. An in vitro biomechanical analysis on the stability and stress-shielding effect of interbody fusion implants. Presented at the annual meeting of the Scoliosis Research Society, St. Louis, MO, September 25, 1997.
15. Kruitwagen RF, Swinkels BM, Keyser KG, Doesburg WH, Schijf CP. Incidence and effect on survival of abdominal wall metastases at trocar or puncture sites following laparoscopy or paracentesis in women with ovarian cancer. *J Gynecol Oncol* 1996;60:233-7.
16. Lajer H, Widecrantz S, Heisterberg L. Hernias in trocar ports following abdominal laparoscopy: A Review. *Acta Obstet Gynecol Scand* 1997;76:389-93.
17. Levran SG, Bieber EJ, Barnes RB. Anterior abdominal wall adhesions after laparotomy or laparoscopy. *J Am Assoc Gynecol Laparosc* 1997;4:353-6.
18. Mayer MH. Mini ALIF: A new microsurgical technique for minimally invasive anterior lumbar interbody fusion. *Spine* 1997;6:691-700.
19. McAfee PC. Complications of anterior approaches to the thoracolumbar spine: Emphasis on Kaneda instrumentation. *Clin Orthop* 1994;306:110-9.
20. McAfee PC, Bohlman HH, Yuan HA. Anterior decompression of traumatic thoracolumbar fractures with incomplete neurological deficit using a retroperitoneal approach. *J Bone Joint Surg [Am]* 1985;67:89-104.
21. McAfee PC, Regan JR, Fedder IL, Mack MJ, Geis WP. Anterior thoracic corpectomy for spinal cord decompression performed endoscopically. *Surg Laparosc Endosc* 1995;5:339-48.
22. McAfee PC, Regan JR, Zdeblick T, et al. The incidence of complications in endoscopic anterior thoracolumbar spinal reconstructive surgery: A prospective multicenter study comprising the first 100 consecutive cases. *Spine* 1995;20:1624-32.
23. McAfee PC, Zdeblick TA. Tumors of the thoracic and lumbar spine: Surgical treatment via the anterior approach. *J Spinal Disord* 1989;2:145-54.
24. McDougall EM, Clayman RV, Fadden DT. Retroperitoneoscopy: The Washington University Medical School experience. *Urology* 1994;43:446-56.
25. Obenchain TG, Cloyd D. Outpatient laparoscopic lumbar discectomy: Description of technique and review of first twenty-one cases. *Surgical Technology International* 1994;2:415-8.
26. Obenchain TG. Laparoscopic lumbar discectomy: Case report. *J Laparoendoscopic Surgery* 1991;1:145-9.
27. Ordway NR, Vamvanij V, Zhao J, Seehan HA, Yuan HA, Mann KA. Effect of cage orientation and posterior instrumentation on the initial stability of the bovine lumbar spine following interbody fusion. Presented at the annual meeting of the International Society for Study of the Lumbar Spine, Singapore, June 6, 1997.
28. Pier A, Gotz F, Bacher C. Laparoscopic appendectomy in 625 cases: From innovation to routine. *Surg Laparosc Endosc* 1991;1:8-13.
29. Reddick EJ, Olsen DE. Laparoscopic laser cholecystectomy: A comparison with mini-lap cholecystectomy. *Surg Endosc* 1989;3:131-3.
30. Regan JJ, McAfee PC, Mack MJ. Atlas of Endoscopic Spine Surgery. St. Louis, MO: Quality Medical Publishing, Inc., 1995.
31. Scott TR, Graham SM, Flowers JL, Bailey RW, Zucker KA. An analysis of 12,397 laparoscopic cholecystectomies. *Surg Laparosc Endosc* 1992;2:191-8.
32. Southern Surgeon's Club. A prospective analysis of 1518 laparoscopic cholecystectomies. *New Engl J Med* 1991;325:1073-8.
33. Talamini MA, Gadacz TR. Equipment and instruction. In: Zucker KA, ed. *Surgical Laparoscopy Update*. St. Louis, Missouri, Quality Medical Publishing, 1993:3-85.
34. Tiisanen H, Seitsalo S, Osterman K, Soini J. Retrograde ejaculation after anterior interbody lumbar fusion. *Eur Spine J* 1995;4:339-42.

Address reprint requests to

Paul C. McAfee, MD
 The Scoliosis and Spine Center
 7505 Osler Drive, Suite 104
 Baltimore, Maryland 21204

APPENDIX K



S: 156
Z: 0.48
C: 512
W: 1024

APPENDIX L



FIELD ANNOUNCEMENT

From the desk of Gavin Fabian Office: (858)-909-1993



Date: October 29, 2008

60mm CoRoent XL® Implants Now Available!




CoRoent XL Responds to Meet Growing Surgical Requirements

As XLIF® has rapidly expanded to a wider surgeon and patient population, so has the need for additional implant sizes. After listening to the most experienced and expert XLIF surgeons, it has become evident that longer implants are sometimes needed to achieve full ring coverage on exceptionally large patients. In NuVasive® fashion, we have quickly responded to this surgical need and are now delivering a full set of standard and lordotic 60mm implants.

CoRoent XL Just Got Even Bigger!!!

Now offering 60mm long implants, CoRoent XL has the longest size offering on the market. With a full range of 40 to 60mm implants, enable your surgeon to achieve complete end to end ring coverage on even the largest XLIF patients. There is almost nothing that compares when considering size, strength, and performance. In fact, when we compared the CoRoent XL 60mm implant to even a stretched Hummer, the implant won. See for yourself!!

PLAINTIFF'S EXHIBIT
CASE NO. 08CV 01512
EXHIBIT NO. PX1901

	Stretch Hummer	CoRoent XL 60mm Implant
		
Impressively Long	X	X
Market-leading Strength and Support	X	X
Large Apertures for Bony Through-Growth		X
Marker Rods for Optimal Visualization		X
Exceptionally Good Looking	X	X

To order, please contact Customer Service today at:
7475 Lusk Blvd. • San Diego, CA 92121
phone: 800-475-9131 • fax: 800-475-9134

©2008 NuVasive, Inc. All Rights Reserved. Patents Pending.

www.nuvasive.com
For Educational Purposes Only – Do Not Copy – Do Not Circulate



FIELD ANNOUNCEMENT

From the desk of Gavin Fabian Office: (858)-909-1993



What is inside the CoRoent® XL 60mm implant tray?

The CoRoent XL 60mm implant tray will include **standard** and **lordotic** 60mm implants. **Important, there will be no trials, inserters, T-Handles, or any other instruments in this implant tray.** As a result, it will be absolutely necessary that you order the CoRoent XL implant tray as well. Look below to find images of the actual 60mm implant tray (closed and open).



Contents of the CoRoent XL 60mm Implant Tray		
Angles	Heights	Qty
Standard and Lordotic	8 - 16mm	2 of each size

How can I get a set for an upcoming case?

Call or email customer service and request the CoRoent XL 60mm implant tray. Remember, you must order the CoRoent XL tray for any case you have the 60mm implant tray. Otherwise, you will not have the required instrumentation for the case.

CoRoent XL 60mm Implant Tray (CRXL60) without the CoRoent XL Tray (CORXLL) = NO CASE!!!

Note: Please use your best judgment and order this tray when it is truly needed. Be diligent in speaking with the surgeon and examining x-rays prior to the case to determine if the 60mm tray is required. This will ensure the sales force has access to the 60mm implants when they are necessary.

Go Big,

Gavin Fabian,
Associate Product Manager, Thoracolumbar Interbody
gfabian@nuvasive.com

To order, please contact Customer Service today at:
7475 Lusk Blvd. • San Diego, CA 92121
phone: 800-475-9131 • fax: 800-475-9134

©2008 NuVasive, Inc. All Rights Reserved. Patents Pending.

www.nuvasive.com
For Educational Purposes Only – Do Not Copy – Do Not Circulate