

## **Cataracts in the Royal College of Surgeons Rat: Evidence for Initiation by Lipid Peroxidation Products**

J. S. ZIGLER, JR. AND H. H. HESS

*Laboratory of Vision Research, National Eye Institute, National Institutes of Health,  
Bethesda, MD 20205, U.S.A.*

*(Received 25 September 1984 and accepted 6 March 1985, New York)*

The Royal College of Surgeons (RCS) rat has been extensively studied as a model system for inherited retinal degeneration. As in a number of human retinal degenerative diseases, posterior subcapsular cataracts (PSC) are associated with the retinal changes. It has been hypothesized recently that such cataracts may be initiated by toxic products generated by the peroxidation of polyunsaturated lipid components from degenerating photoreceptor outer segments. In the present study, the possibility that such a mechanism might be responsible for cataract initiation in the RCS rat has been investigated.

The degeneration of the rod outer segments (ROS) occurs rapidly in these animals, beginning a few weeks after birth. Due to the failure of the retinal pigmented epithelium to phagocytize normally, ROS degeneration is accompanied by an accumulation of debris in the eye. During the brief period of maximal debris accumulation there is a marked increase in lipid peroxidation products in the vitreous. Cataract formation is correlated temporally with these events, becoming evident immediately following the time during which peroxidation products are present in the vitreous. In addition, the primary damage detected in the RCS lenses is an increase in the passive permeability of the lens membranes. Similar lens damage has been found in studies in which normal rat lenses were exposed to degenerating ROS *in vitro*. These findings are consistent with the hypothesis that cataracts in the RCS rat may be initiated by toxic lipid peroxidation products.

*Key words:* Royal College of Surgeons (RCS) rat; retinal degeneration; posterior subcapsular cataract formation; lipid peroxidation; lens culture; rubidium efflux; microdissection; high-performance liquid chromatography (HPLC).

### **1. Introduction**

The association between posterior subcapsular cataracts (PSC) and retinal degenerative diseases such as retinitis pigmentosa (Heckenlively, 1982) and gyrate atrophy (Kaiser-Kupfer, Kuwabara, Uga, Takki and Valle, 1983) has long been recognized; however, the mechanism accounting for this association has not been established. Although the cataracts have been considered by some to be intrinsic expressions of the genes responsible for retinal degeneration, the weight of the evidence supports the hypothesis that they are the result of secondary effects (Heckenlively, 1982). Berliner (1949) postulated that a 'toxic substance' released from the degenerating retinal tissue was responsible for the initiation of cataract development. Recently there have been two studies reported which suggest that such a 'toxic substance' might be a product(s) generated by peroxidation of the polyunsaturated lipid released from degenerating photoreceptor outer segments (Goosey, Tuan and Garcia, 1984; Zigler, Bodaness, Gery and Kinoshita, 1983). In both studies lens damage was correlated with lipid peroxidation. This hypothesis is consistent with the facts that the retinal photoreceptor cells have very high rates of oxygen consumption and that the outer segments of these cells, which are the primary site of degeneration in these diseases, have extremely high

Please address correspondence to J. Samuel Zigler, Jr, Bldg. 6, Rm. 235, National Institutes of Health, Bethesda, MD 20205, U.S.A.

levels of polyunsaturated lipid. Coupled with the marked tissue disruption occurring during the degenerative process, these factors would produce an ideal environment for lipid peroxidation.

To investigate this hypothesis further the cataracts present in the Royal College of Surgeons (RCS) rat were studied. Although this strain was initially developed as a cataract model (Bourne, Campbell and Pyke, 1938), it has been studied primarily as a model of retinal degeneration. Only in 1982 was it reported by Hess, Newsome, Knapka and Westney that RCS rats fed the standard NIH rat diet *all* developed bilateral PSC at 7–8 weeks of age, as detected by slit lamp examination. Consistent with earlier work (LaVail, Sidman and Gerhardt, 1975), it was found that only 23% of the rats had mature cataracts by 1 yr of age.

The timing of the appearance of the PSC is consistent with the hypothesis that the lens changes may be initiated by toxic products released from degenerating rod outer segments (ROS). Dowling and Sidman (1962) have reported an elegant histologic analysis of the course of the retinal changes in these animals. The first observable damage is seen at about 12 days of age in the outer segments; by 18 days the outer segment layer is twice normal thickness and includes much lamellar outer segment debris (LaVail and Battelle, 1975). At about 4 weeks of age this layer reaches its maximal thickness and inner segments and photoreceptor nuclei begin to degenerate. By 40 days both the inner and outer segments are gone and the debris layer is narrowing and becoming less lamellar with a more homogeneous appearance. This layer of debris, which accumulates due to the inability of the retinal pigment epithelium to phagocytize normally (Herron, Riegel, Myers and Rubin, 1969; Mullen and LaVail, 1976), gradually disappears over a period of several months. Thus the initial appearance of cataractous changes in the lens (7–8 weeks) closely follows the period of maximal accumulation of outer segment debris. The possible relationship between these two events has been investigated by first determining whether lipid peroxidation is occurring in the RCS rat eye during degeneration of the ROS and, secondly, by comparing the condition of the lens in these animals with that of normal rat lenses exposed to lipid peroxidation products *in vitro*.

## 2. Materials and Methods

All animals used in the present study were pink-eyed, tan-hooded dystrophic and control RCS rats (*rdy/rdy*, *p/p* and *rdy<sup>+</sup>*, *p/p*, respectively). All rats were fed the standard NIH-07 natural ingredient rodent diet and were maintained in plastic cages under a 12-hr on/12-hr off light schedule.

For preparation of vitreous, animals were killed and the eyes enucleated and frozen on crushed dry ice. Each eye was then bisected into anterior and posterior portions and the anterior portion discarded. While still frozen, the portion of lens remaining with the posterior part of the globe was removed and the vitreous was then carefully peeled from the outer layers of the eye. Any adherent retina was removed from the colorless vitreous under a dissecting microscope. Thiobarbituric acid assays were performed on isolated vitreous by the method of Buege and Aust (1978). For fluorescence studies, measured volumes of vitreous from RCS and congenic control animals were solubilized in sodium dodecyl sulfate (SDS) at a final concentration of 0.1% SDS.

Lens incubation studies were performed in TC-199 medium lacking phenol red and modified to increase buffering capacity as follows: to 160 ml TC-199 (Hanks salts) was added 26 ml H<sub>2</sub>O, 108 mg glucose and 61.38 mg CaCl<sub>2</sub>·2H<sub>2</sub>O. After complete dissolution, 64 ml of a stock bicarbonate buffer (7.65 g NaHCO<sub>3</sub>, 0.368 g KHCO<sub>3</sub>, 0.743 g NaCl and 0.085 g KCl per liter) was added to bring the total volume to 250 ml. Following addition of 30 mM fructose

(1.35 g/250 ml medium), the osmolarity of the medium was determined and NaCl added to bring the final osmolarity to  $298 \pm 2$  mOsm. The medium was equilibrated with 95% air/5% CO<sub>2</sub> by bubbling and was filter-sterilized following addition of 0.3 ml penicillin-streptomycin (Difco) per 100 ml. This is a modification of a medium previously developed specifically for lens organ culture (Kinoshita, Merola and Tung, 1968).

Rubidium efflux experiments were performed by incubating RCS and control lenses individually for 16 hr in 2.0 ml medium containing tracer levels of <sup>86</sup>RbCl. Following this period, half of the lenses in each group were removed and the uptake of radioactive label was determined as previously described (Zigler et al., 1983). The remaining lenses were rinsed in medium without label, transferred to fresh medium (2.0 ml) lacking <sup>86</sup>Rb, and incubated for 5 additional hr. Each lens was subsequently harvested and the content of <sup>86</sup>Rb remaining in the lens was determined as above. Comparison of the label remaining in the lenses following the 5-hr leak-out period with that present after 16 hr uptake yielded the efflux data, which are reported for the dystrophic lenses as the percentage of the efflux from age-matched control lenses.

Lenses for microdissection were carefully removed from the globe by the posterior approach. The cataractous zones were clearly visible under a dissecting microscope. Such opaque areas and adjacent clear zones were dissected manually using a micro dissecting knife (Roboz Instrument Co. Inc., Washington, DC). Samples were homogenized in 0.25–0.5 ml 0.05 M Tris buffer, pH 7.1, containing 0.1 M KCl, 1 mM EDTA and 1 mM dithiothreitol. Following centrifugation at 100000 g for 30 min, aliquots of the supernatants were applied to a 60 cm TSK-3000 column fitted to an LKB high-performance liquid chromatography (HPLC) system. The sample was eluted at 0.5 ml min<sup>-1</sup> and was monitored at 280 nm. Protein determinations on insoluble protein were performed in 0.5% sodium dodecyl sulfate using the BCA protein assay (Pierce Chemical Company).

### 3. Results

To determine whether lipid peroxidation occurs in the RCS rat eye during outer segment degeneration, samples of vitreous were carefully dissected from RCS dystrophic and congenic control animals of various ages and tested for the presence of lipid peroxidation products. Table I gives the results of thiobarbituric acid (TBA) assays on these preparations. There was a definite burst of TBA reactivity at about 4 weeks of age in the dystrophic eyes coincident with the time of maximal accumulation of debris from the ROS. The presence of the dialdehydes, with which TBA reacts, is of short duration, with the levels returning to the control range within several weeks.

TABLE I

*TBA reactivity in the vitreous\**

Animals	Age	O.D. <sub>532</sub>
RCS dystrophic	2½ weeks	0.010
	4 weeks	0.057
	8 weeks	0.008
	6 months	0.003
RCS control	4 weeks	0.006
	6 months	0.003

\* Each value represents a determination made on a sample of pooled vitreous taken from six to eight eyes. Similar results were obtained from two additional, separately prepared sets of vitreous samples. Comparison of the mean values ( $\pm$ s.d.) for the 4-week dystrophic ( $0.055 \pm 0.013$ ) and 4-week control ( $0.008 \pm 0.002$ ) preparations from the three experiments by Student's *t*-test revealed that they were significantly different ( $P < 0.05$ ).

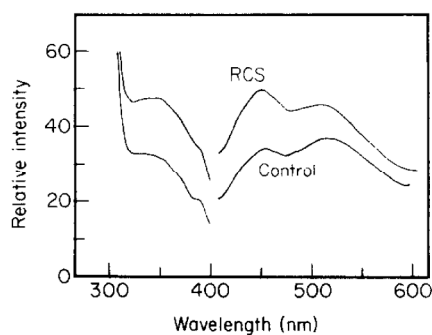


FIG. 1. Corrected fluorescence emission and excitation curves for RCS dystrophic and control vitreous isolated from animals approximately 7 months of age. Emission curves were obtained with excitation at 350 nm. The excitation spectra, shown at the left, were obtained with emission set at 450 nm. In both pairs of curves the dystrophic vitreous is the upper spectrum.

These highly reactive species would not be expected to persist for very long in the eye since they will react rapidly with any molecules containing amino groups. However, the products of the reaction of such aldehydes with amino groups are stable and give characteristic fluorescence emissions near 450 nm ( $E_x \approx 350$  nm) resulting from the iminopropene bonds formed (Chio and Tappel, 1969). Figure 1 demonstrates an increase in fluorescence emission in the 450 nm range in the vitreous of older RCS dystrophic rats relative to age-matched congenic controls.

Figure 2 is a photograph of the posterior surface of the lens from an RCS dystrophic rat at the age of about 8 weeks. The opacity is located at the posterior pole of the lens and has a 'sugar-grain' appearance. At this stage the opacity is immediately below the posterior capsule; however, in most of the lenses the opacity becomes 'internalized' within several weeks (Hess, Newsome, Knapka and Westney, 1983), with normal-appearing transparent fiber cells being laid down external to the opacity. Figure 3 is a similar view of another RCS rat lens at about 9 weeks of age in which new lens fibers can be seen covering most of the lesion. Note the formation of the sutures directly over the opacity. Figure 4 shows a lens from a 14-month-old RCS rat in which the opacity can be seen from the side as a discrete arc well inside the posterior capsule. The lens fibers both anterior and posterior to the opaque area are transparent.

Since previous studies by the present authors had demonstrated that peroxidation products, particularly aldehydes, damaged the membranes of organ-cultured rat lenses making them abnormally permeable to  $^{86}\text{Rb}$ , lenses were removed from RCS rats at different ages and their rubidium efflux rates were compared with those of age-matched congenic controls. Data are reported in Fig. 5 as percentage of control, with the 100% line representing the values for age-matched control lenses. The dystrophic animals first showed abnormally high efflux rates at about 40 days, shortly after the time of greatest debris accumulation in the retina. The efflux rate continued to rise until about 60 days of age when it began to decrease, returning to normal levels by about 3 months of age. This fall in efflux corresponds to the time at which the PSC becomes 'internalized'. It was also observed that in some of the lenses the opacity did not become internalized. When those lenses were selected from animals of 3-4 months of age, the rubidium efflux rates were found still to be elevated (Fig. 5).

The nature of the PSC produced in the RCS rat, particularly its highly reproducible occurrence and its discrete localization, make it an ideal subject for study by the microdissection technique (Horwitz, Neuhaus and Dockstader, 1981). Such studies

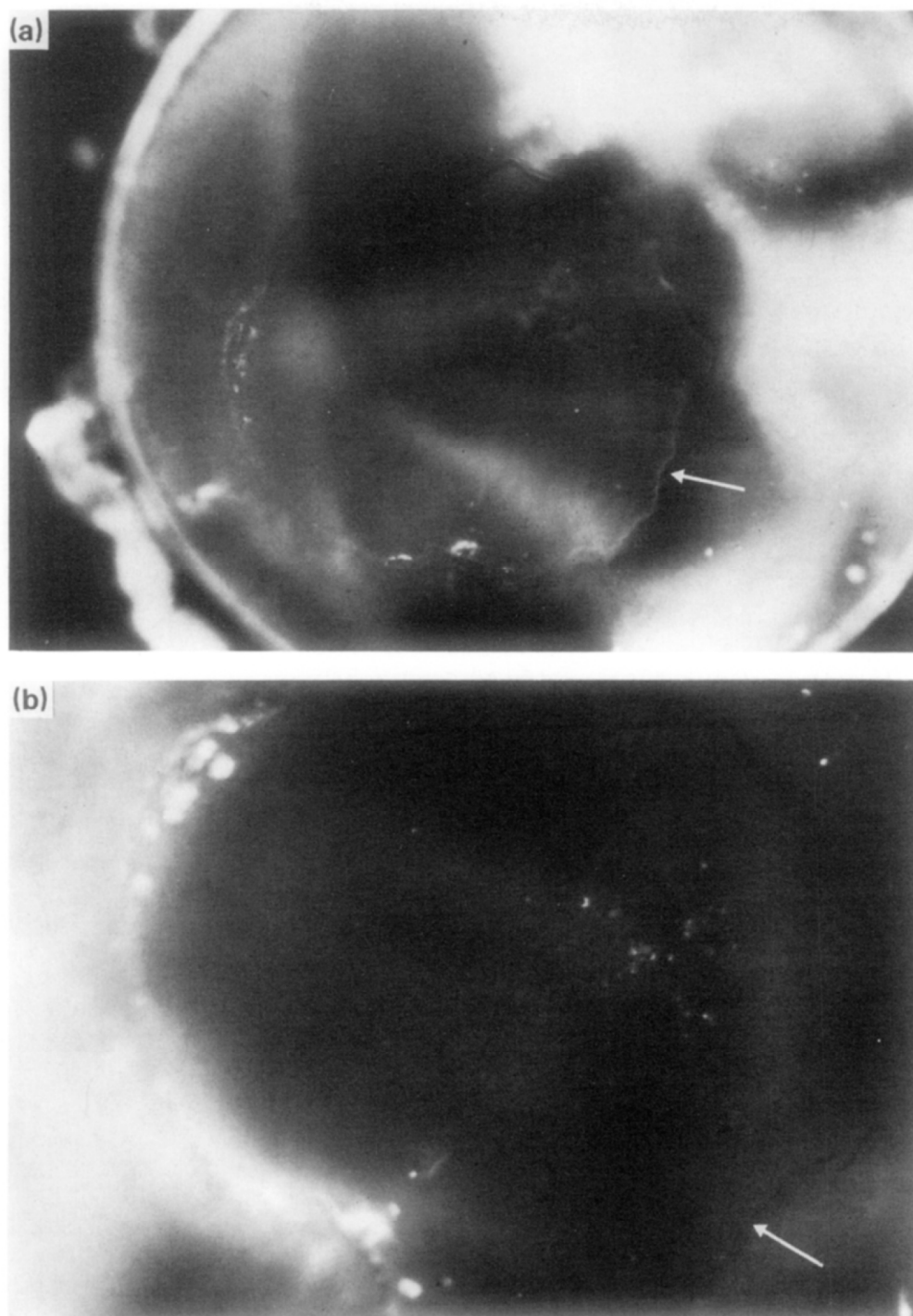


FIG. 2. Posterior subcapsular cataract (PSC) in pink-eyed, tan-hooded RCS rat at 8 weeks of age. Photograph of posterior aspect of dissected lens immersed in saline, taken with Zeiss stereomicroscope SR with darkfield/brightfield stand and MC-63 photomicrographic camera system. Note the boundary of the initial lesion (arrow) and the 'sugar-grain' appearance of some areas. (Microscope magnification in (a)  $\times 32$ . (b)  $\times 50$ .)

# Explore Litigation Insights

Docket Alarm provides insights to develop a more informed litigation strategy and the peace of mind of knowing you're on top of things.

## Real-Time Litigation Alerts



Keep your litigation team up-to-date with **real-time alerts** and advanced team management tools built for the enterprise, all while greatly reducing PACER spend.

Our comprehensive service means we can handle Federal, State, and Administrative courts across the country.

## Advanced Docket Research



With over 230 million records, Docket Alarm's cloud-native docket research platform finds what other services can't. Coverage includes Federal, State, plus PTAB, TTAB, ITC and NLRB decisions, all in one place.

Identify arguments that have been successful in the past with full text, pinpoint searching. Link to case law cited within any court document via Fastcase.

## Analytics At Your Fingertips



Learn what happened the last time a particular judge, opposing counsel or company faced cases similar to yours.

Advanced out-of-the-box PTAB and TTAB analytics are always at your fingertips.

## API

Docket Alarm offers a powerful API (application programming interface) to developers that want to integrate case filings into their apps.

## LAW FIRMS

Build custom dashboards for your attorneys and clients with live data direct from the court.

Automate many repetitive legal tasks like conflict checks, document management, and marketing.

## FINANCIAL INSTITUTIONS

Litigation and bankruptcy checks for companies and debtors.

## E-DISCOVERY AND LEGAL VENDORS

Sync your system to PACER to automate legal marketing.