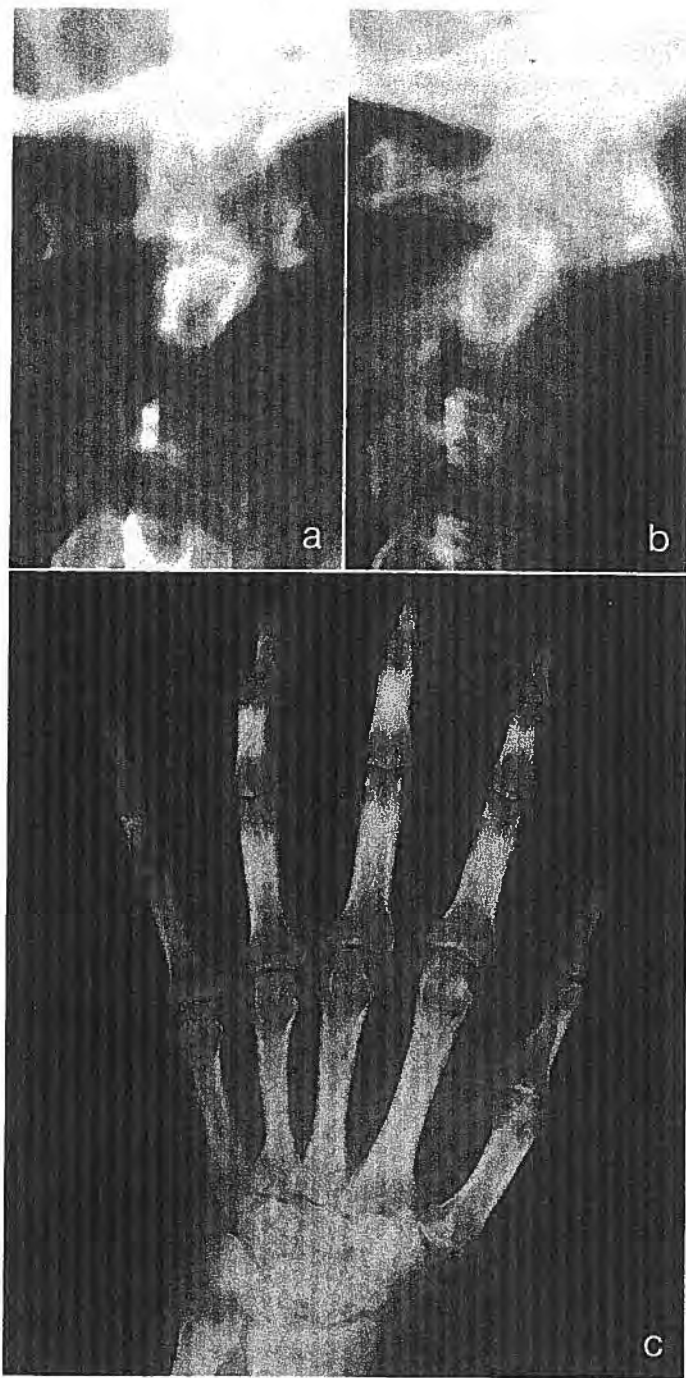

Figures 7.12 a-c. **a** A lateral radiograph of the upper cervical spine in a woman aged 30 years, showing erosive changes in the region of the odontoid peg due to rheumatoid disease. **b** A radiograph of the same area of the spine in flexion, showing instability between C1 and C2 due to rheumatoid joint disease at that level. **c** A radiograph of the bones of the wrist and hand of the same patient showing the changes of juxta-articular osteoporosis in all the digital joints due to rheumatoid arthritis

e) Infective Lesions

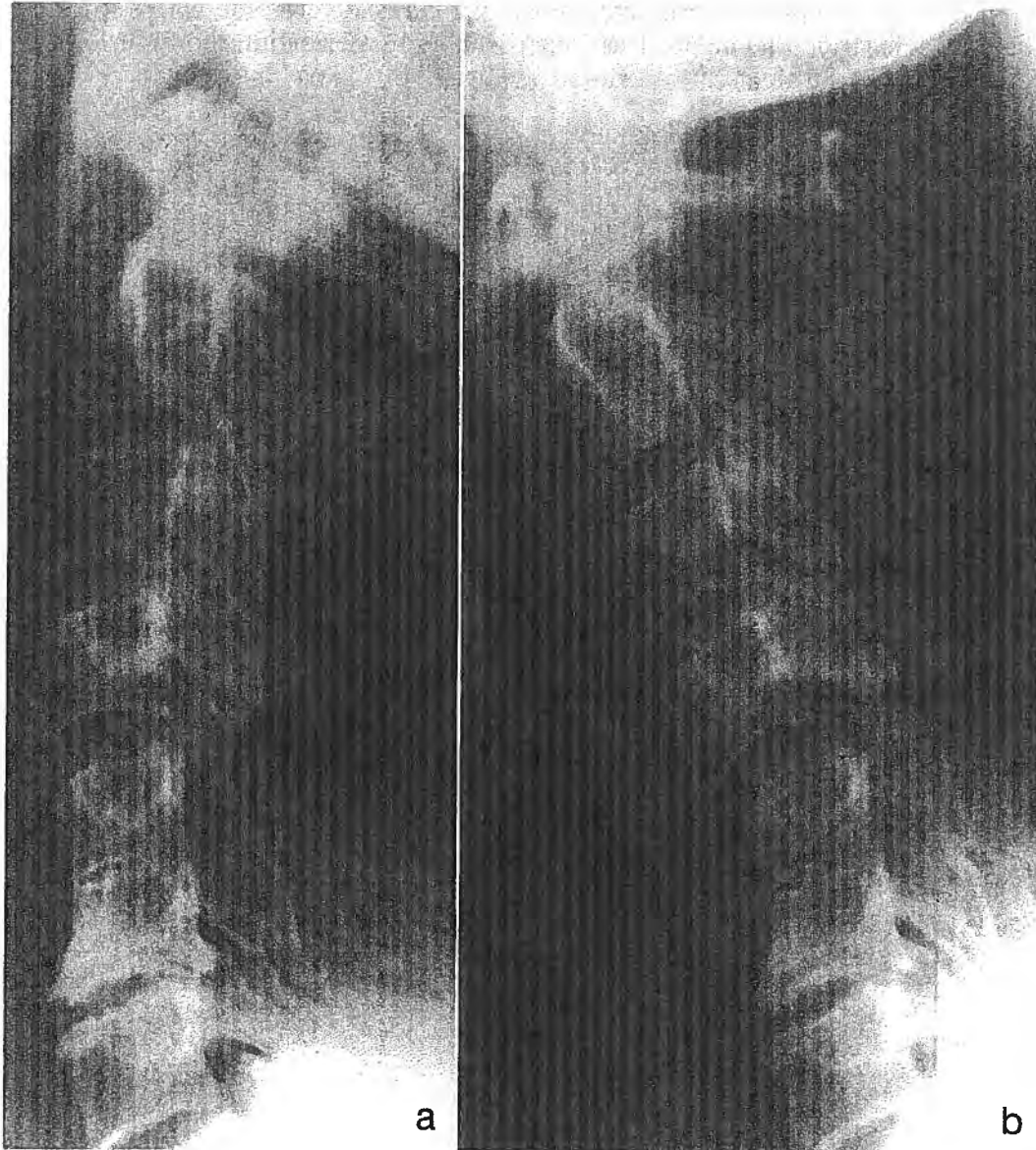
Acute haematogenous osteomyelitis affecting the cervical spine may lead to acute or chronic compression of the spinal cord due to associated epidural abscess formation or to pathological subluxation of the vertebrae. Patients presenting with quadriplegia need urgent investigation, appropriate surgical treatment being planned on the results of myelography or MRI. In the case illustrated in Chapter 8 (Figs. 8.4a–c), it was on the basis of the myelographic findings that the decision was taken to perform a decompression laminectomy to drain the epidural abscess. Subsequently, the associated spinal deformity was treated conservatively, using skull traction in extension. Spontaneous interbody fusion followed, union occurring without significant residual spinal deformity.

f) Tuberculous Infection

This may cause gross deformity in the neck. Trans-oral fusion of C1/2 involving the facet joints on both sides of the odontoid may be required (Fig. 7.13).

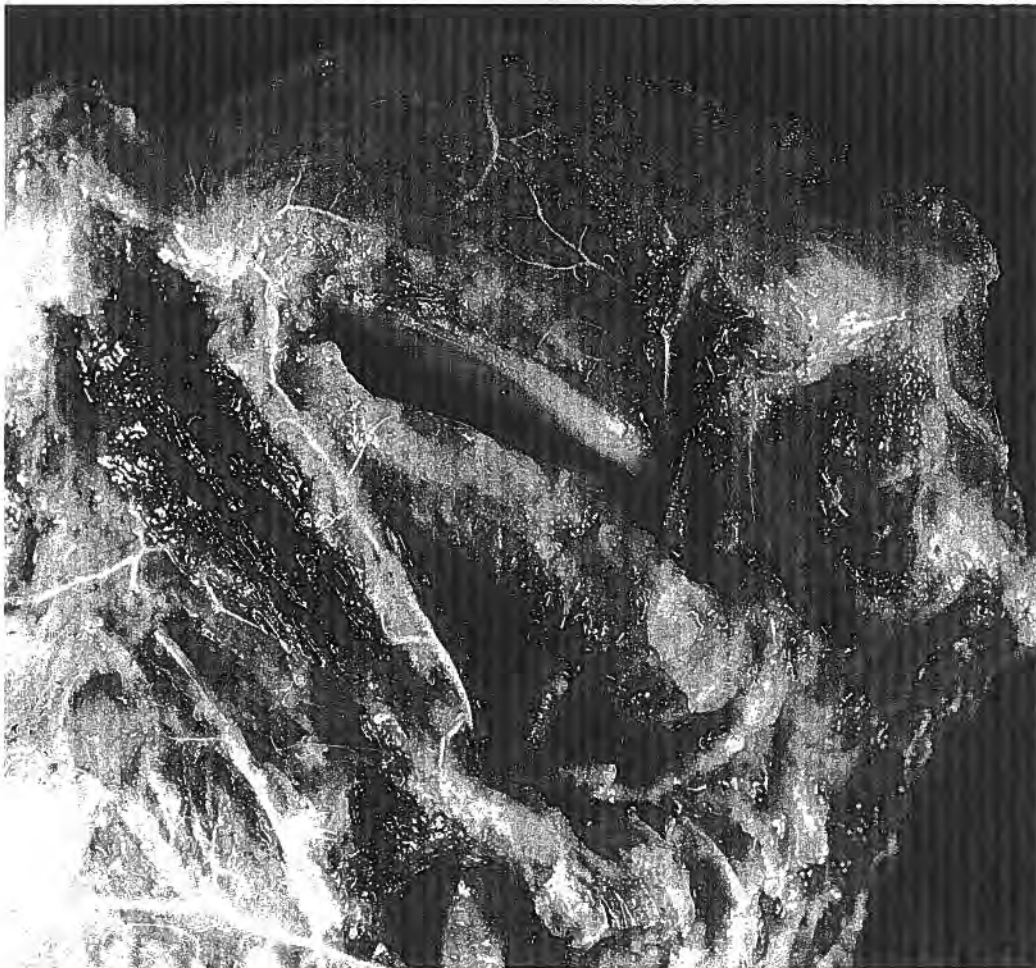

Figure 7.13



Figures 7.14a,b. **a** A lateral radiograph of the cervical spine of a patient aged 40 years. Note the congenital fusions between the bodies of C5 and C6. Advanced degenerative changes have occurred at the disc between C6 and C7 with large osteophytes projecting posteriorly into the spinal canal. The disc between C4 and C5 appears normal in this view. **b** A lateral radiograph of the same spine in flexion showing instability at the C4/5 level

Figure 7.13. A detailed view of the facet joint between C1 and C2 on the left side of the specimen illustrated in Fig. 7.1. Note the relationships of the vertebral artery to this joint from which the bulk of the capsule has been excised. In the operation of trans-oral fusion of C1 and C2, grafts are inserted into this joint space after removal of the articular cartilage and sub-chondral bone plates. The lateral capsule of the joint should be carefully preserved to avoid damaging the vertebral artery on the lateral aspect of the joint

More commonly, the disease affects lower cervical vertebrae where it is best treated by local debridement of carious tissue and anterior interbody fusion, see Chapter 8 (Figs. 8.12 a, b).

g) Congenital Abnormalities

Congenital fusion of cervical vertebral bodies is relatively common. Severe degenerative spondylosis is usually found in the adjacent vertebral segment below the fusion early in adult life. Occasionally vertebral instability will be found in the segment above or below the congenital fusion. Anterior cervical interbody fusions may be required for the treatment of either or both of these lesions (Figs. 7.14a, b).

7.3. Cervical Discography

The test is performed on the conscious patient with light sedation. The needles used for this investigation are smaller in calibre than those used in the lumbar spine (Fig. 7.15). They are usually inserted through the right side of the neck, anteriorly, by pushing the mid-line structures of the neck across to the left side with the

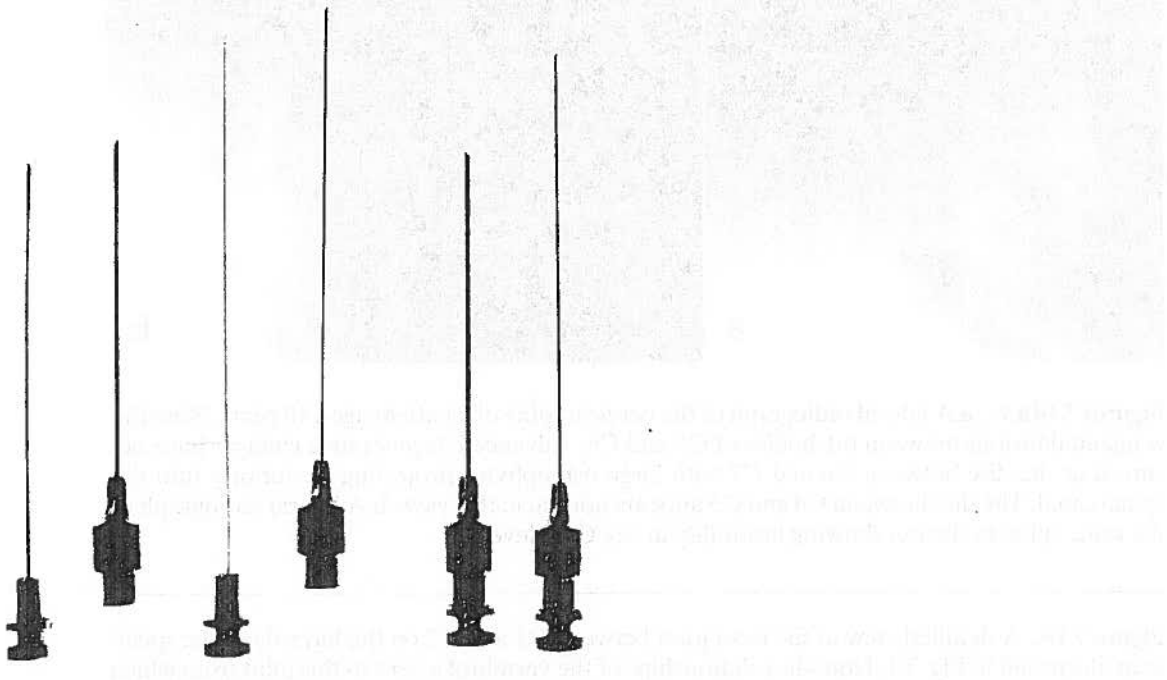


Figure 7.15. A photograph showing a gauge 25 “discogram needle” on the right of the picture with a gauge 22 “guide needle” alongside. On the left of the picture the stilettes are shown alongside their respective needles

operator's index finger. Control X-rays are taken in antero-posterior and lateral planes to ensure accurate placement of the tip of each "discogram needle" in the centre of the nuclear zones of the discs before dye is injected (see Chapter 2, pp. 66-69).

Spread of dye beyond the zone of the nucleus pulposus may occur into the unco-vertebral joint areas on both sides, while leakage backwards into the spinal canal (extra-theal) may indicate a posterior disc disruption. Spread of dye results from incompetence of annular fibres and is not necessarily an indication of disc prolapse.

The pain response provoked by injection of dye into the disc is not related to the volume injected or to the resultant increase in intra-discal pressure; rather, it is due to irritation, by the dye, of the sensitized pain fibres within the disrupted disc itself. Hence, the pattern of pain distribution is not strictly segmental and it does not follow the dermatomes in the upper limbs, as has been suggested by some writers. Use of cervical discography should be reserved for the investigation and demonstration of non-prolapsing disc disorders. By contrast, neither myelography nor C.T. scanning will help to identify the level of a disc with internal disruption. Those investigations find their proper application in the investigation of cases with disc pathology producing space-occupying lesions in the vertebral canal.

MRI, particularly with gadolinium enhancement, though useful, has not yet been found superior to discography in helping to confirm the diagnosis of post-traumatic internal disc disruption.


7.4. Technique of Anterior Cervical Interbody Fusions

a) Instruments

Dowel cutting instruments permit these operations to be performed accurately at each attempt. Their use in most cases is preferred to the use of chisels or osteotomes for this reason and for the added safety afforded, during the operation, by the safety devices built into the design of Crock cutters. Photographs of essential instruments are found in Figs. 7.16-20 with descriptive legends outlining details of their assembly and use.

b) Positioning

Patients are placed supine on the operating table. A small wedge-shaped pillow should be placed under the shoulders, with a rolled towel supporting the hollow of the neck, the occiput resting in a rubber ring. The patient's eyes should be protected and the anaesthetic tubes securely fixed to the patient's forehead (Fig. 7.21).



Figures 7.16 a, b



Figure 7.17



Figure 7.18

Figure 7.17. A photograph of two cervical retractors with smooth excavated ends designed to be held transversely across the anterior surfaces of the cervical intervertebral discs

Figure 7.18. A photograph of the self-retaining retractor designed by Cloward for use in anterior cervical fusions

Figures 7.16 a, b. **a** A photograph showing the Crock instruments used for dowel cutting in the operation of anterior cervical interbody fusion. On the right of the picture is a Hudson brace. Cutters of three sizes are shown. The starter centre pieces have been removed from each of these. On the right of the cutters is a pusher, which fits inside the cutters and can be used to eject the starter centre pieces or graft bone. On the left of the cutters a pusher is shown with a tubular segment of metal measuring 12.5 mm in depth. When this “dummy” is slotted into the cutter it acts as a guard, preventing the cutter from penetrating deeper than 12.5 mm into the cervical vertebral bodies. Dummies are provided in three sizes, 10 mm, 12.5 mm and 15 mm, for use according to the vertebral dimensions in individual cases. On the left of the photograph, two tooled gouges are shown, which will fit into the cuts made into adjacent vertebral bodies. Their use is illustrated in Figs. 7.28 a–c. Note that the cutters have circular rings marking their outer surfaces, at intervals of 5 mm. Instruments manufactured exclusively by Thomson and Shelton Instrumentation Company, 6119 Danbury Lane, Dallas, TX 75214, U.S.A. **b** A photograph of guide sleeve with two prongs which penetrate the disc – allowing the cutter to be inserted without snagging surrounding soft tissues

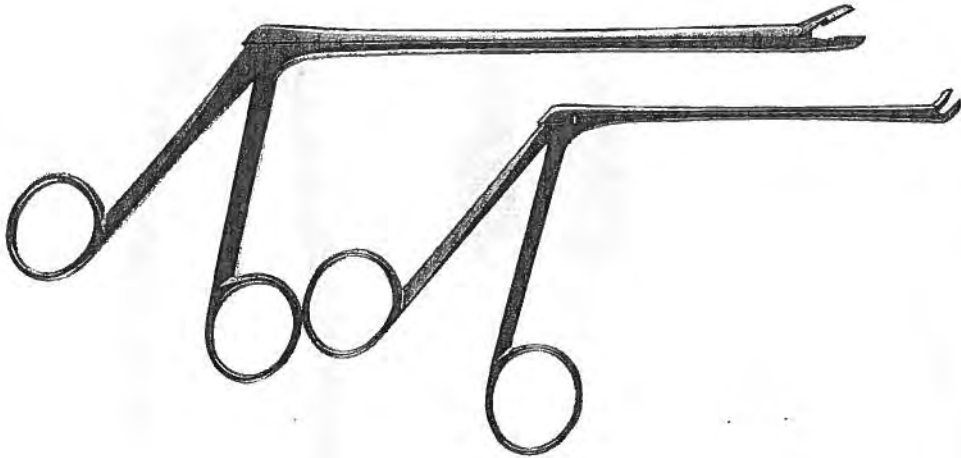


Figure 7.19. A photograph showing fine, straight and forward-angled pituitary rongeurs suitable for use during anterior cervical interbody fusion operations, for removing remnants of vertebral end-plates and disc tissue following curettage of the disc space




Figure 7.20. A photograph of a Bayonet forceps with a fine tip, essential for use in cervical spine operations

c) Incisions

A right-sided hemi-collar incision can be used for approaches to any of the cervical discs, from that between C2 and C3 vertebrae to the lowest in the cervical spine. The use of longitudinal incisions may result in unsightly scars, though they may be necessary in special cases requiring multi-level spinal fusions.

The platysma muscle is exposed by separating subcutaneous fat from its superficial surface before the muscle is split in the line of its fibres. The encircling layer of deep cervical fascia is then incised along the anterior border of the sterno-mastoid muscle, allowing access to the space between the carotid sheath laterally and the mid-line structures of the neck medially. Inserting the index finger into the space now created, the surgeon can palpate the front of the vertebral column. By moving the finger deliberately and carefully along the antero-lateral margin of the vertebrae, a plane of cleavage can usually be opened easily in the loose fascia between the carotid sheath and the mid-line structures of the neck over a distance sufficient to allow exposure of one, two or three of the cervical intervertebral discs.

Most cervical fusions are performed at the levels of C4/5, C5/6 or C6/7. Having cleared the space as indicated, retractors may then be inserted, orientated trans-

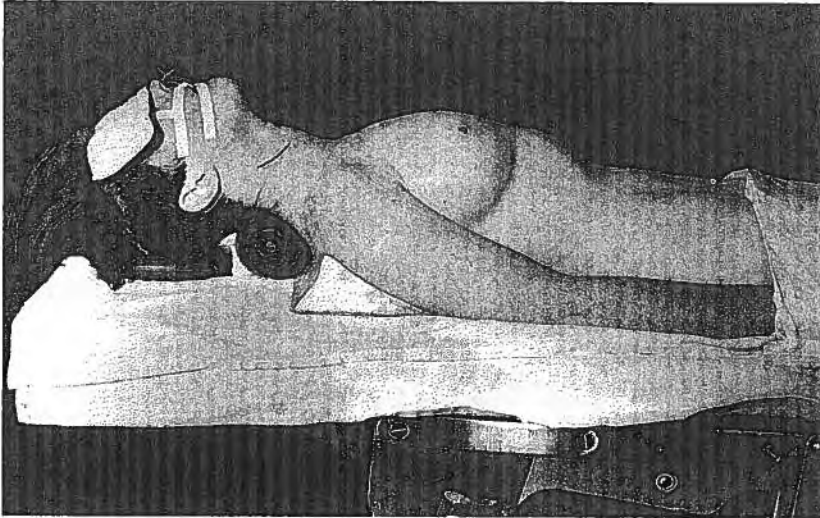


Figure 7.21. A photograph of a patient postured on the operating table for anterior cervical interbody fusion. Note the triangular-shaped pillow underneath the shoulders, the rolled towel (in black) under the neck, and the rubber ring on which the occiput rests. The endo-tracheal tube and the reinforced rubber airway adjacent to it are strapped to the patient's face. Note the pad covering the eyes, to prevent pressure on the orbits during surgery. Assistants have been known to press on the eyes during the operation. Irreparable ocular damage has been reported from this cause. Note also the outline of the hemi-collar incision extending from the anterior border of the sterno-mastoid muscle to just behind the mid-line. Through this incision two or three cervical discs can be exposed. For exposure of the disc between C2 and C3 vertebral bodies, the incision needs to be placed in the sub-mandibular region, care being taken to avoid damaging the mandibular branch of the facial nerve. Note that both arms are by the patient's side, to allow traction on the hands for lowering the shoulders while control X-rays are being taken during the operation

versely and applied to the anterior aspect of one of the intervertebral discs. Up to this point the only major anatomical structures encountered will have been those already mentioned. Only occasionally will it be found necessary to ligate and divide an anterior cervical vein or some un-named venous tributary of the internal jugular vein. The superior thyroid vessels may be seen, but it is rarely necessary to ligate and divide them.

The pre-vertebral fascia, that thin, filmy, opalescent membrane which sheaths the pre-vertebral muscles and the cervical column itself, is split longitudinally in the mid-line and the retractors re-positioned to give a clear view of the intervertebral discs and anterior aspects of the vertebral bodies. The medial edges of the right and left-sided longus colli muscles can be seen clearly and, using a fine bayonet forceps, the vessels related to the muscles at their attachments along the antero-lateral aspects of the vertebral bodies are coagulated with diathermy (Fig. 7.22). These muscular attachments are then separated from the vertebrae and discs, so that the cervical retractors may be replaced beneath their freed medial margins to expose the disc or discs to be removed. The risk of obstructing the carotid vessels during operation is thereby reduced, either with the use of the hand held retractors (Fig. 7.17) or with self retaining types (Fig. 7.18).

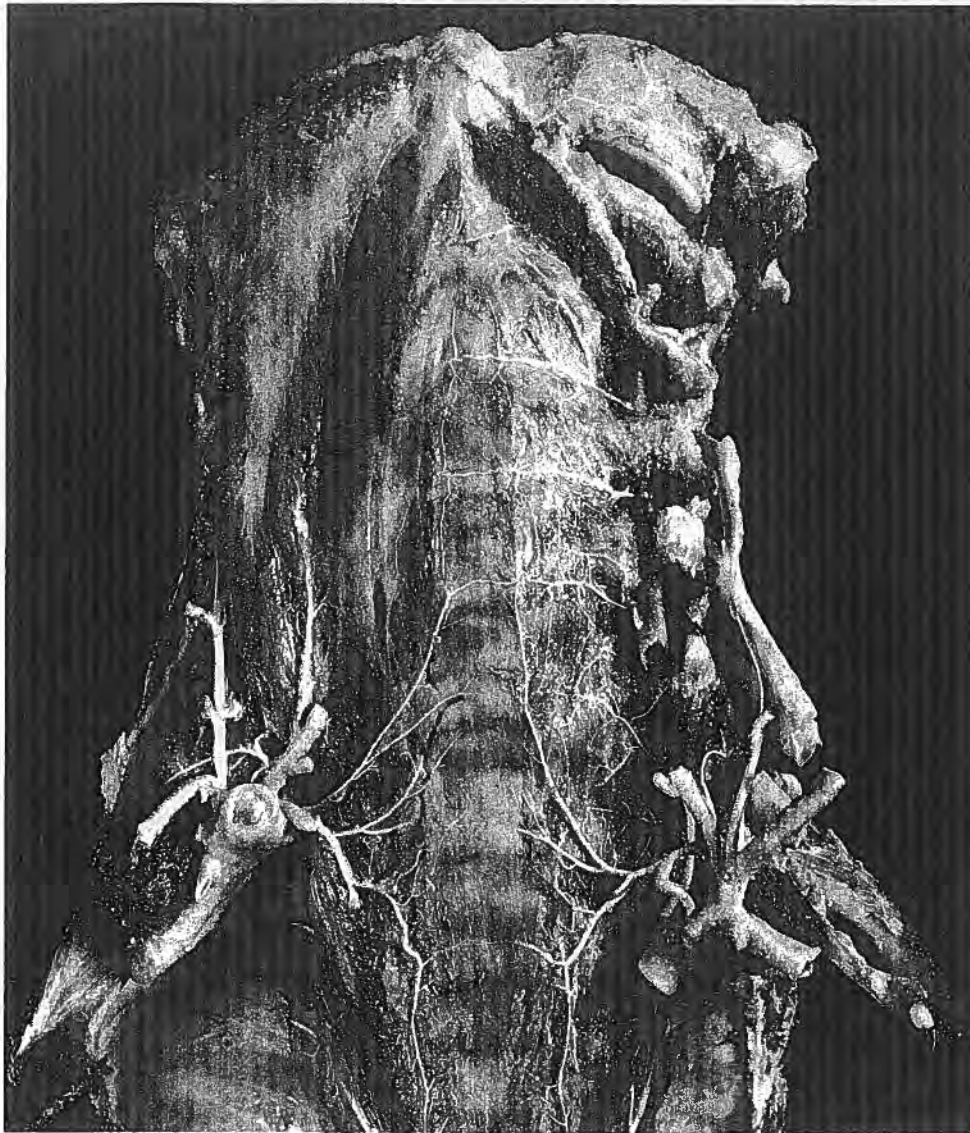


Figure 7.22. A photograph of a dissection of the anterior aspect of the cervical and upper thoracic spine of a female child aged 3 1/2 years, showing the origins and courses of arteries supplying the antero-lateral aspects of the vertebral bodies. The longus colli muscles have been removed from the left side of the specimen. The pre-vertebral fascia has also been removed but the anterior margin of the longus colli at its attachment to the antero-lateral aspects of the vertebral bodies on the right side is intact. Note the vertical chain of arterial anastomoses running along the margin of this muscular attachment, forming a parallel vascular channel with corresponding vessels on the left side of the vertebral column. (Dissected by Dr. H. Yoshizawa) [Reproduced from: Crock, H. V., Yoshizawa, H.: *The Blood Supply of the Vertebral Column and Spinal Cord in Man*. Wien-New York: Springer, 1977]

d) *The Thyroid Gland*

Before planning cervical discography and anterior cervical spine surgery in any patient, the surgeon should examine the patient's thyroid gland. On three occasions in twenty-five years of practice, I have had patients in whom thyroidectomy has been required before satisfactory access to the anterior aspect of the cervical vertebral column was possible.

e) *Control X-Rays to Identify Individual Intervertebral Discs*

The use of a disposable needle with a Z bend in it, inserted into the disc, is recommended before lateral X-rays are taken. The needle serves the dual purpose of identifying the disc level and allowing the precise measurement of its antero-posterior width. (Fig. 7.23 a-c). *Never remove the needle before the control X-ray has been exhibited in the operating room confirming the level of the disc to be removed.*

f) *Preparation of the Dowel Cavity*

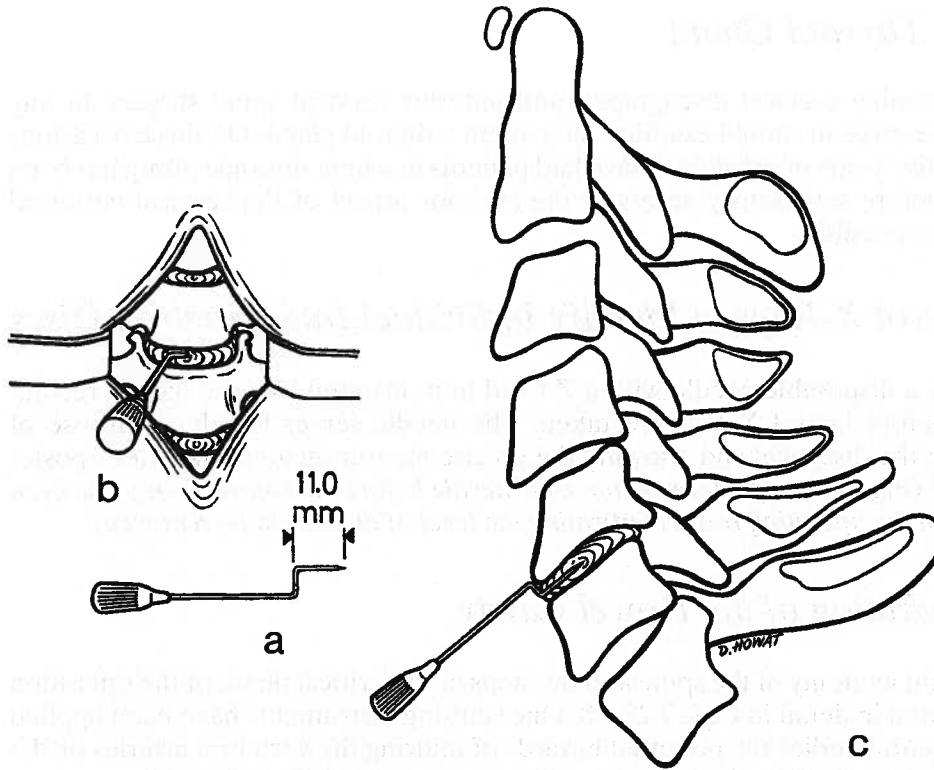
The relevant anatomy of the spine and the steps in this critical phase of the operation are illustrated in detail in Figs. 7.22-28. Once cutting instruments have been applied to the vertebral bodies the potential hazards of injuring the vertebral arteries or the neural structures in the spinal canal must be borne in mind (Figs. 7.1 a, b).

Having made the preliminary cut across the disc space, the starter centre piece is removed from the cutter. The surgeon then selects the "safety dummy" of predetermined size, by re-checking the antero-posterior measurements of the disc space and then personally assembles the cutter ready for use by inserting the "dummy", which is held in place by the "pusher device". Both the assistant surgeon and theatre sister should check the preparation of the cutter with the "dummy" and cross-check the disc space measurements before the surgeon re-inserts the cutter, after stage one, to commence the final preparation of the dowel cavity.

Errors made at this stage could lead to catastrophic accidents during the operation. The equipment illustrated in this chapter has been used by the author since 1962 without any instance of spinal cord or cervical nerve root injury occurring up to the present time (1991).

Having re-fitted the cutter into the preliminary circular slot cut during stage one (Fig. 7.25 a-c), it should be oscillated clockwise and counter-clockwise, avoiding any wobbling motion as the Hudson brace is being rotated. No force is to be exerted on the proximal end of the brace, other than that required to steady it with one hand, while the surgeon's other hand holds the off-set control bar through which the oscillating motion is transmitted to the cutter.

As the cutter advances slowly into the vertebral bodies and intervening disc tissue, the operator becomes aware of a grating sensation at its cutting end, from which an audible grating sound is emitted. The "dummy" inside the cutting cylinder will abut against the anterior surface of the disc and adjacent vertebral margins when the cutter has reached the depth that is determined by the length of the "dummy" (Fig. 7.26 a, b). Further penetration of the cutter into the vertebral bodies is thereby prevented. At this stage, the grating sensation ceases and the cutter spins smoothly



Figures 7.23a-c. a A drawing to illustrate the use of a bent needle recommended by the author for use during control X-rays in the neck. A disposable 19 gauge needle is prepared by bending it in the jaws of an artery forceps. A right-angle bend is made near the tip and the measurement between the tip and the first right-angle bend taken. Usually 11.0–12.5 mm is satisfactory, depending on the size of the patient. b A drawing to depict the front of a cervical intervertebral disc with the needle in place for control X-ray during operation. c A drawing of the cervical spine shown from the side depicting the use of the bent needle for control X-ray. The right angle bend prevents penetration of the needle into the cervical canal, a potential risk if a straight needle is inserted. It has the added advantage of allowing precise measurement of the intervertebral disc space on the control X-ray

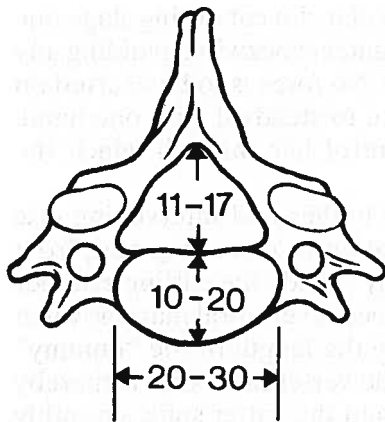
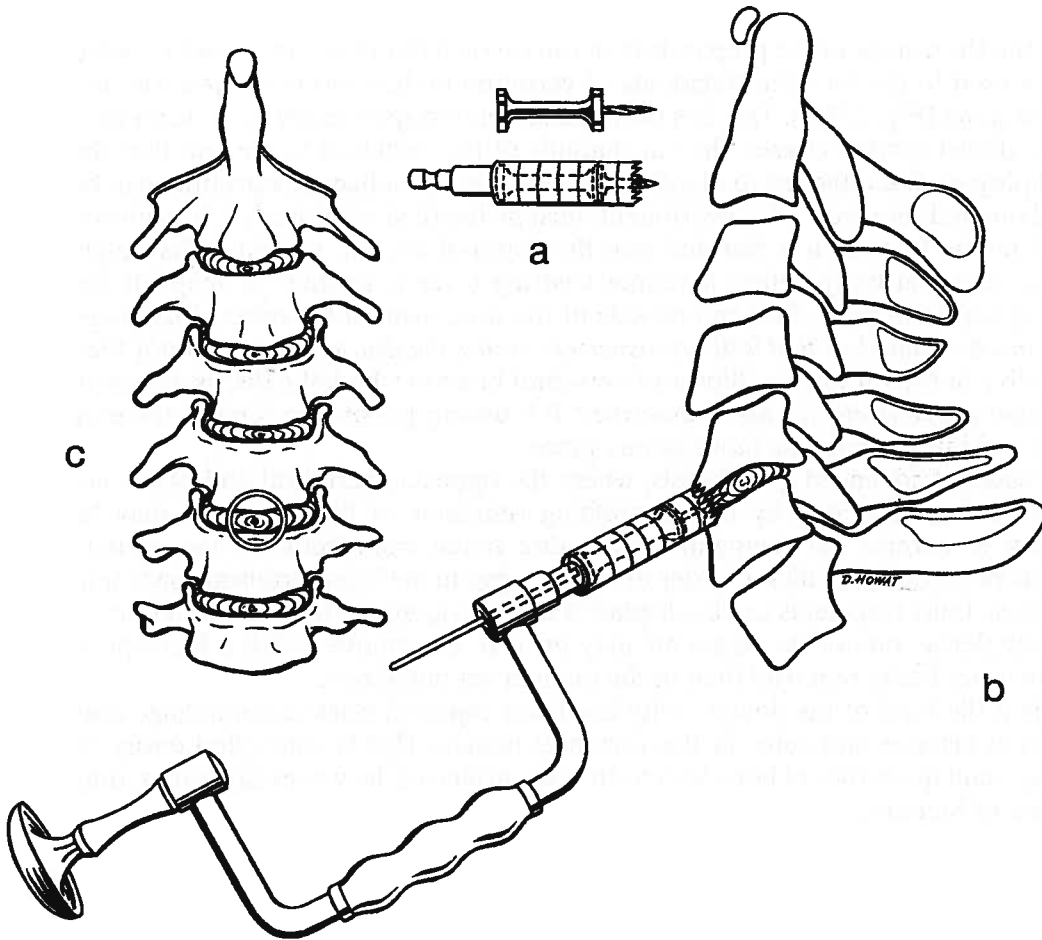


Figure 7.24. A drawing of a typical cervical vertebra with the ranges of measurements in millimeters of the transverse and antero-posterior diameters of the vertebral body and the antero-posterior diameter of the cervical canal



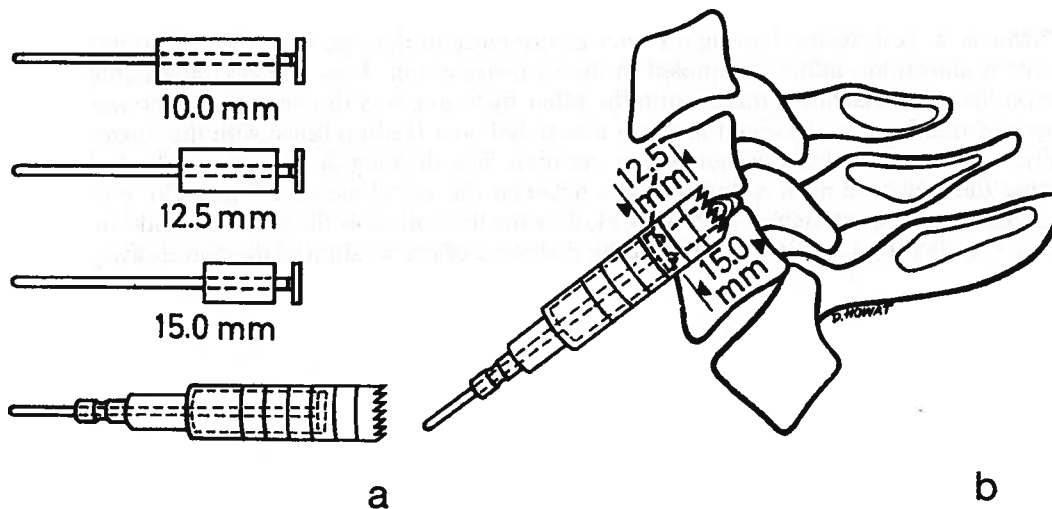
Figures 7.25 a-c. **a** A drawing showing a starter centre piece at the top. Below it, the starter centre piece is shown in outline, assembled in the zero-size cutter. Note the circumferential markings on the cutter, each separated from the other by 5 mm. **b** A drawing of the cervical spine, viewed from the side, showing the cutter assembled on a Hudson brace with the starter centre piece in position and the pusher within the tube. The drawing depicts the method of commencing the preparation of a dowel cavity between the vertebrae of C5 and C6. **c** A drawing of the cervical spine viewed from in front, showing the outline of the cut in the mid-line between the vertebral bodies of C5 and C6, at the first stage of preparation of the dowel cavity

and silently. For added safety, while the cutter is being oscillated, the surgeon may check the measurement of its advancement by counting the rings on its outer surface.

In the third stage of the preparation of the cervical dowel cavity a special tooled gouge is used to displace the fragments of vertebral bodies and intervertebral disc from the spine (Fig. 7.28 a). This has been manufactured specifically to fit accurately into the dowel cavity between the cut margins of the vertebral bodies, so that the central plug of disc attached to elliptical segments of the adjacent vertebrae can be levered out and removed. This instrument must be handled with caution, introduced without undue force as it is directed into the depth of the cut, so that it fits snugly into the vertebral body before a simple levering force is applied to snap off the ellipse of vertebral body, first on one side of the disc, then on the other. *The gouge should not be rotated so that it lies transversely across the disc space.* It will not then be effective in fracturing the ellipses of vertebral bone to which the disc is attached. *It is designed specifically for use as described.* It is usually possible to remove the plug of bone and intervening disc tissue in one piece.

In cases of advanced spondylosis, where the opposing vertebral end-plates are sclerotic, being separated by thin unyielding remnants of disc tissue, it may be necessary to curette the remnants of the disc tissue from between the arcuate segments of vertebral bodies in order to create a gap in the intervertebral space into which these bony fragments can be displaced with the gouge. If the vertebral bone is extremely dense, one of the segments may need to be removed with a high speed drill, the other being removed then in the manner set out above.

When the base of the dowel cavity has been exposed, brisk haemorrhage may occur from arteries and veins in the vertebral bodies. This is controlled easily by applying small quantities of bone wax to the cut surface of the vertebral bodies, only at the site of bleeding.



Figures 7.26 a, b

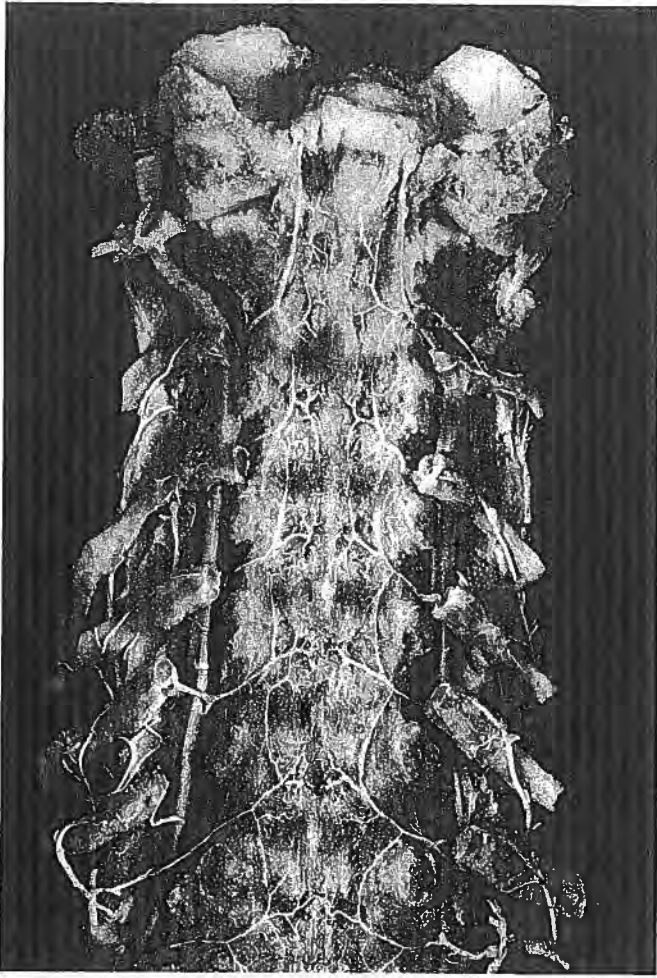
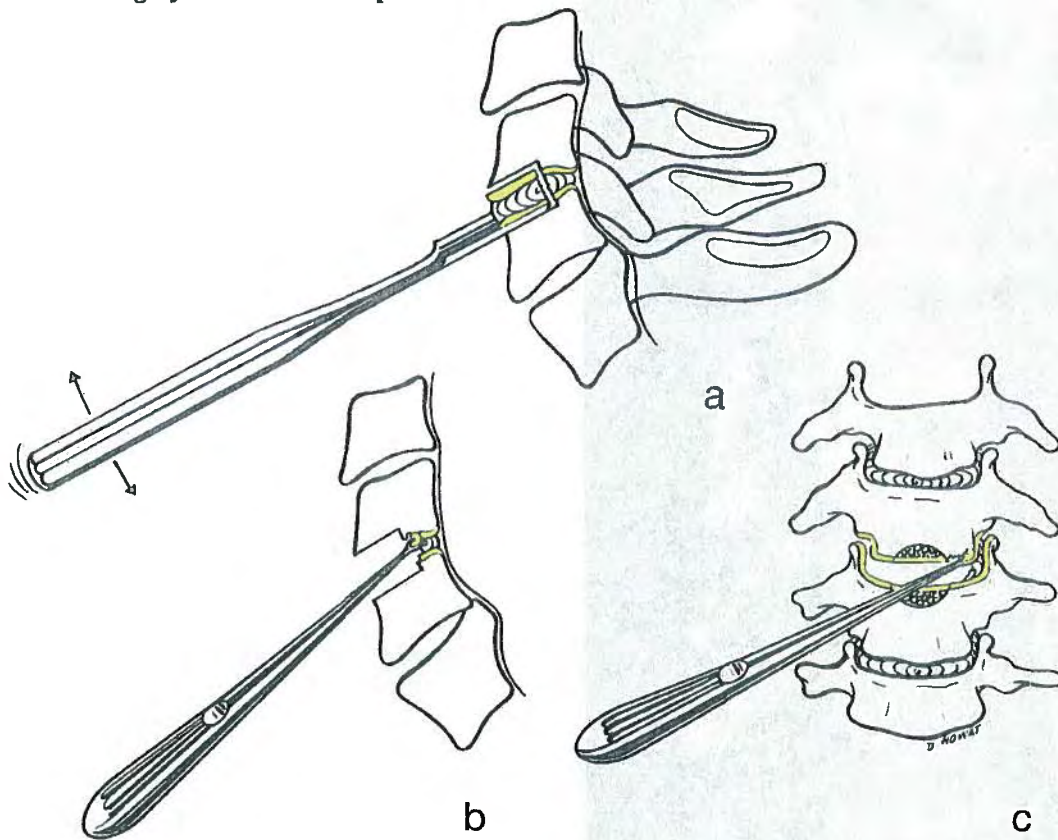


Figure 7.27. A photograph of a dissection of the posterior aspect of the cervical and upper thoracic spine of a male aged 34 years. The posterior aspects of the vertebral bodies have been exposed and portions of the posterior longitudinal ligament have been removed from a number of vertebral bodies in the lower part of the specimen. In the upper part of the specimen on both sides, the origins of the anterior spinal canal branches of the vertebral arteries can be seen. In the neck, these vessels form the familiar arcuate arterial pattern on the anterior surface of the spinal canal which is found along its length. The vessels contribute to the intra-osseous arterial supply of the vertebral bodies, anastomosing with branches from the vascular chains demonstrated in Fig. 7.22 on the anterior aspect of the vertebral column. In the operation of anterior cervical interbody fusion the blood supply of the vertebral body remains largely intact, ensuring rapid vascularization of grafts

Figures 7.26a,b. **a** A drawing to show the range of metal dummies available for insertion into the zero-size cutter, allowing the preparation of dowel cavities of pre-determined depth, depending on the depth of the disc space in individual patients. The depth of the space is checked at operation by control X-ray with the use of the bent needle as indicated in Figs. 7.23a,b,c. At the bottom of the drawing, note the dummy assembled inside the cutters. **b** A drawing to depict the cutter in use, demonstrating the mechanism of safety protection provided by the 12.5 mm dummy which has been inserted after removal of the starter centre piece. Note also that the surgeon is able to count the rings on the outer side of the cutter, providing a double safety factor. (See pp 243 for a detailed description of the technique for cutting the dowel cavity)



Figures 7.28a–c. **a** A drawing to show the method of use of the tooled gouge for removal of the plug of the vertebral bodies and disc following the use of the cutter as depicted in Figs. 7.26a,b. **b** A drawing to illustrate the use of a fine curette (2 mm cup) for removal of the vertebral end-plate remnants shown in yellow, after the plug of disc tissue sandwiched between vertebral end-plate margins has been displaced with the gouge and removed with a straight pituitary rongeur. **c** A drawing depicting the use of the fine curette (2 mm cup) showing the prepared dowel cavity from in front with the curette removing remnants of vertebral end-plate cartilage and disc tissue in the region of the left-sided unco-vertebral joint. It is possible to remove virtually all disc tissue and vertebral end-plate remnants in this manner

The fourth and final stage of preparation of the intervertebral space now commences, leading up to the actual impaction of the bone graft. Vertebral end-plate cartilage remnants are removed with a fine curette (1 or 2 mm cup), disc remnants attached, as illustrated in Figs. 7.28b,c. Care is taken to avoid damaging the vertebral arteries (Figs. 7.1 a, b).

Longitudinal traction applied to the skull by the anaesthetist will result in opening up of the intervertebral space, allowing the surgeon to see the posterior longitudinal ligament in the depths of the dowel cavity. Through visible defects in this ligament in cases of sequestration of disc fragments into the cervical spinal canal, it is possible to remove the displaced disc tissue from the canal.

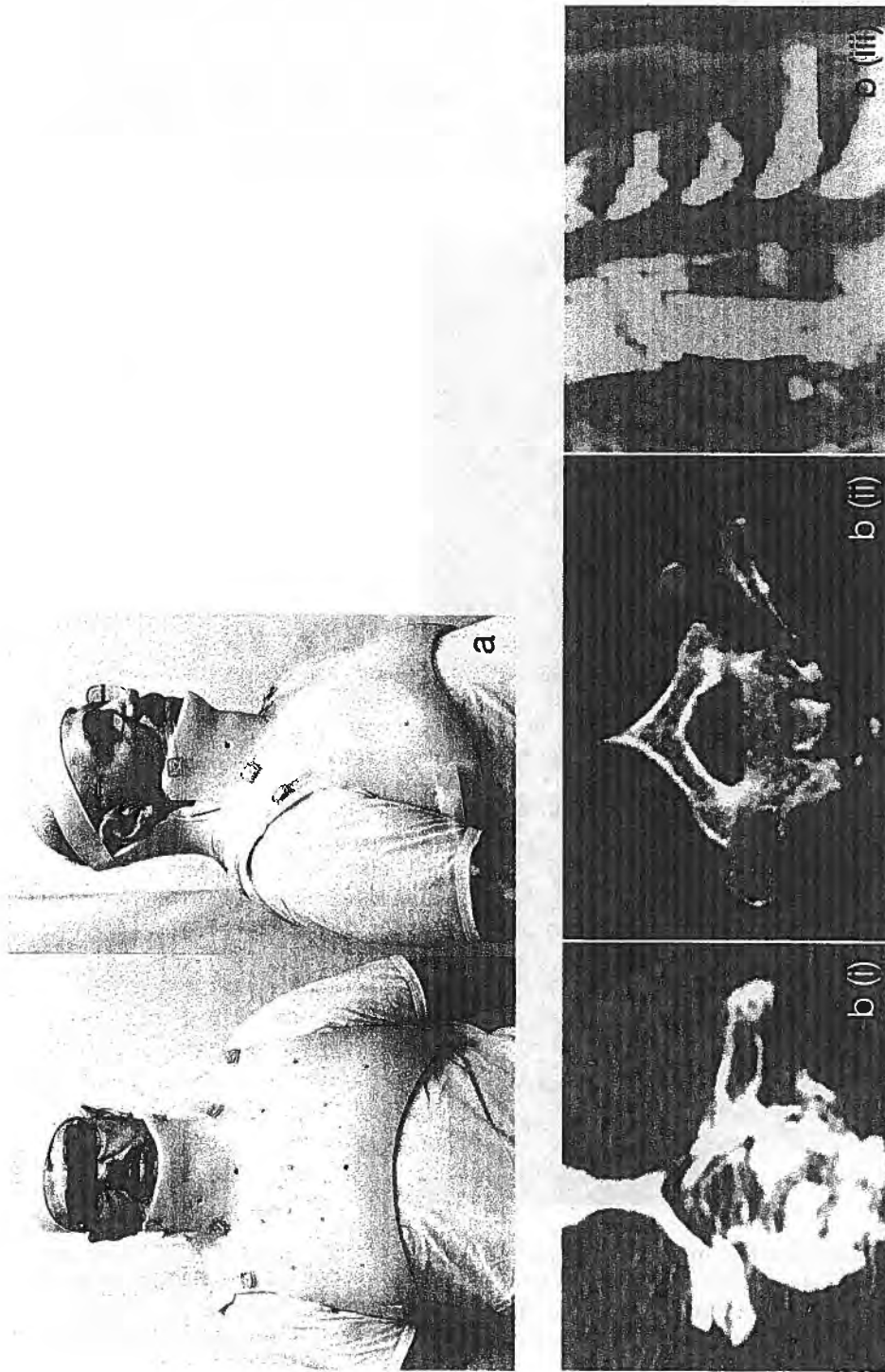
Excision of osteophytic bars of bone from the anterior aspect of the cervical spinal canal may be required in cases of cervical myelopathy. Depending on the

transverse width of the disc, two overlapping dowel cavities may be cut, allowing a wider exposure for this delicate, and potentially dangerous, task.

The use of a high-speed drill with rounded diamond-tipped burrs is essential and facilities for good lighting, suction, irrigation and magnification are required. A small piece of plastic catheter should be fixed to the tip of the sucker to prevent it being damaged by the drill burr. Two or three vertebral levels are often involved and the decision needs to be made either to decompress and fuse individual levels or to excise intervening vertebral bodies and insert a strut graft (Fig. 7.29). In either case, the use of autogenous grafts cut from the iliac crest can be recommended. Fibular strut grafts are used by some authors but they are slow to vascularize.

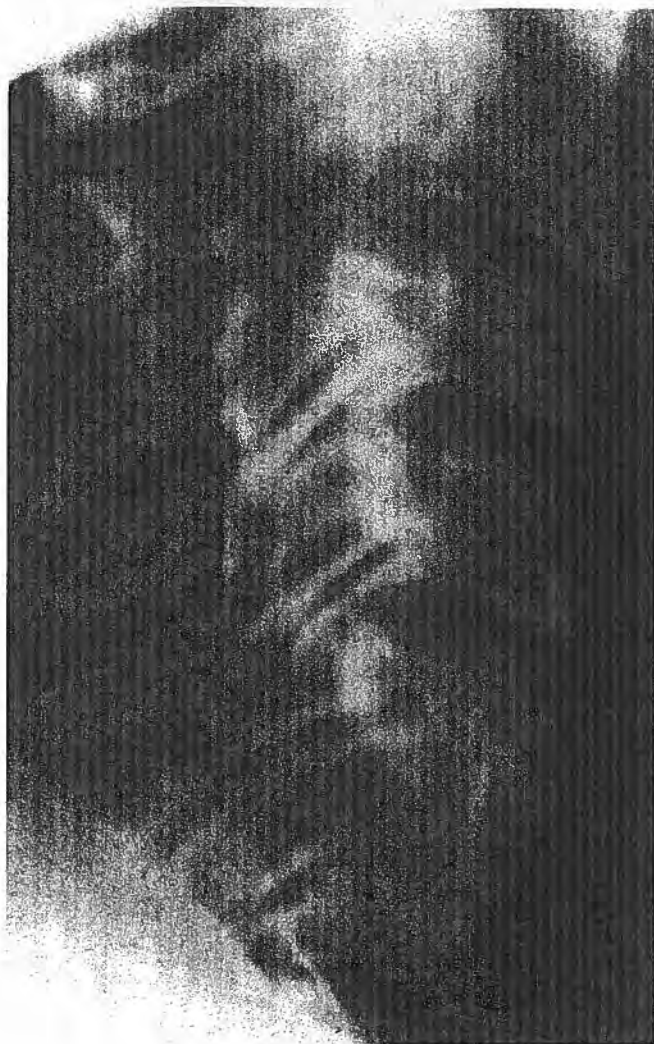

Figure 7.29. A lateral radiograph of the spine of the patient whose pre-operative films are illustrated in Figs. 7.4a,b. This patient had clinical evidence of cervical myelopathy with a spastic gait and weak upper extremities. Note the positioning of the interbody graft which is already incorporating. Note also that the large osteophyte has been excised completely from the front of the cervical vertebral column



Figures 7.30 a, b. a Photographs of a 62 year old man showing the type of custom-made plastic thoraco-cervico-cranial corset suitable for use after decompression and anterior cervical interbody fusions at multiple levels. b (i) An axial CT radiulogram of this man's spine following inadequate surgery, with *bone cement* supplementing grafted bone. He presented with quadriparesis. (ii) Centre – a post-operative axial CT scan showing the upper end of the autogenous cortico-cancellous graft cut from his iliac crest – six weeks after revision surgery. (iii) A mid-sagittal reconstruction showing the strut graft in situ, with adequate decompression of the anterior wall of the cervical spinal canal. Reviewed one year after this operation, his quadriparesis had recovered fully

The vertebral osteophytes which project into the cervical canal are often surprisingly hard and thick. They can be drilled to egg-shell thinness before being removed from the dural surface with fine angled curettes. Occasionally ossified remnants of the posterior longitudinal ligament are adherent to the dura. They should not be removed for fear of producing dural injury and CSF leakage, problems not easily dealt with in this location. Recovery of neurological function in many of these cases is often gratifying though, in severely disabled patients, degrees of recovery vary and may be delayed for upwards of two years after operation.

Internal fixation is rarely indicated when strut grafts are used. However, special corsets or braces should be fitted (Figs. 7.30-32).

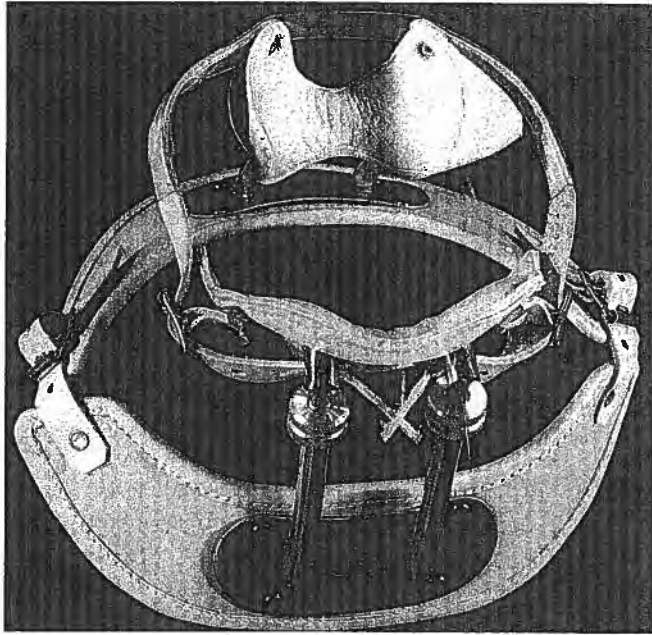


Figure 7.31




Figure 7.32

Figure 7.31. A photograph of an adjustable cervical collar of the Zimmer type, which can provide effective immobilization following multi-level cervical fusions and which may be used later in C1/2 fusions following removal of halo jackets or Minerva jackets

Figure 7.32. A photograph of a SOMI brace which provides an adjustable occipital support and an adjustable mental support fitted to a sternal plate. It is suspended over the shoulder and fixed firmly to the trunk with adjustable straps. On cine-radiography this has been shown to be one of the most effective devices for immobilizing the cervical spine. However, there are problems with its management as it tends to ride up when the patient lies in bed.

g) Graft Preparation

i) Autogenous Grafts

Autogenous grafts should be cut from the anterior third of the iliac crest. If only a single graft is required, this may be cut through a small vertical skin incision placed 2 or 3 cm behind the anterior superior iliac spine, splitting the fibres of tensor fascia lata in the line of the skin cut. The cutting cylinder must be one size larger than that used to prepare the dowel cavity in the neck.

Alternatively, using a short incision along the line of the inner margin of the anterior third of the iliac crest, a limited sub-periosteal exposure of the inner table of the iliac crest can be made, the cutter then being inserted to cut a bone plug extending from the inner to outer table of the ilium.

When more than one graft is required, the skin incision should run parallel to the iliac crest about 1 cm below it. The fascia lata is cut 1 cm below its upper attachment to the iliac crest and the muscles of the outer table of the ilium stripped down sufficiently to allow easy access for removal of the desired number of grafts. During wound closure, a suction drain tube should be inserted. The sutures should be placed deeply into the muscle mass from within-out, allowing the fibres of the tensor fascia lata muscle to be pulled up towards its former site of attachment on the outer wall of the iliac crest. If the sutures approximate only the fascial coverings near the margins of the incision, a noticeably ugly defect results in the zone of attachment of the tensor fascia lata below the iliac crest.

For rare indications, long strut grafts may be required to bridge multiple vertebral levels, where, for example, a cervical kyphotic deformity is being corrected (Fig. 7.11), or after excision of vertebral bodies for tumour or infection. Fibular grafts have been advocated for use in such circumstances. In my view, it is preferable to use long grafts cut from the ilium, to include both cortical surfaces, with cancellous bone between. These grafts will vascularize more rapidly than fibular grafts, the latter being useful only in exceptional circumstances.

ii) Bone Graft Substitutes

Ceramic dowels constructed of a "cancellous core" (pore size in excess of 100 μ) capped on either end by dense "cortical" ceramic plates, have been used successfully in man¹ (Figs. 7.33, 7.34).

Titanium mesh implants have given rise to serious problems due to collapse, extrusion and fragmentation in some cases. They cannot therefore be confidently recommended for use in vertebral interbody fusion operations either in the neck or other areas of the spine (Figs. 7.35, 7.36).

Figure 7.33. A detailed lateral radiograph showing a "cortico-cancellous" ceramic dowel 6 months after insertion.

Figure 7.34. An axial CT image showing a "cortico-cancellous" ceramic dowel covered anteriorly by a thin operculum of bone, well incorporated in the vertebral body

¹ Manufactured by Kyocera Corporation, Kyoto, Japan.

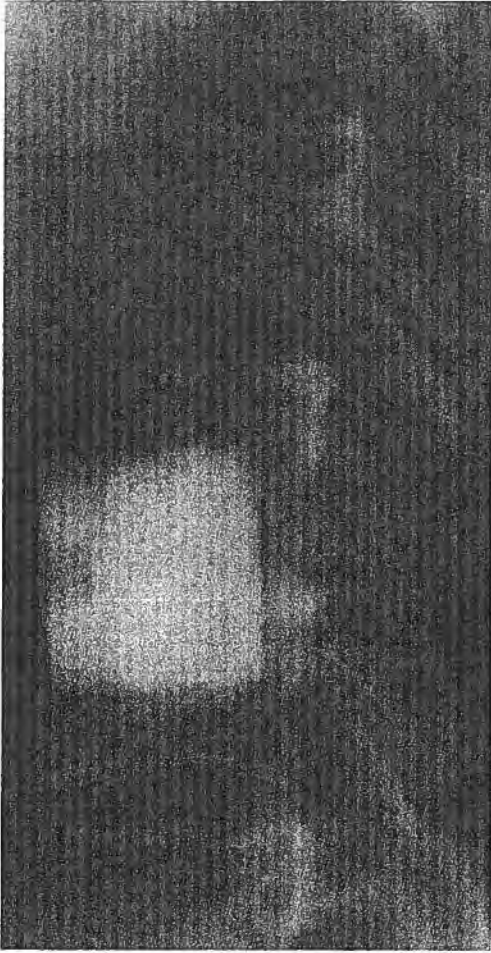


Figure 7.33

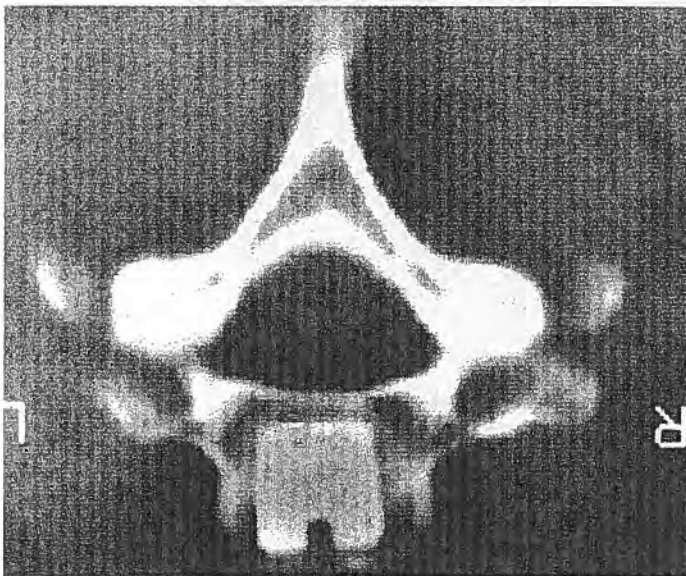
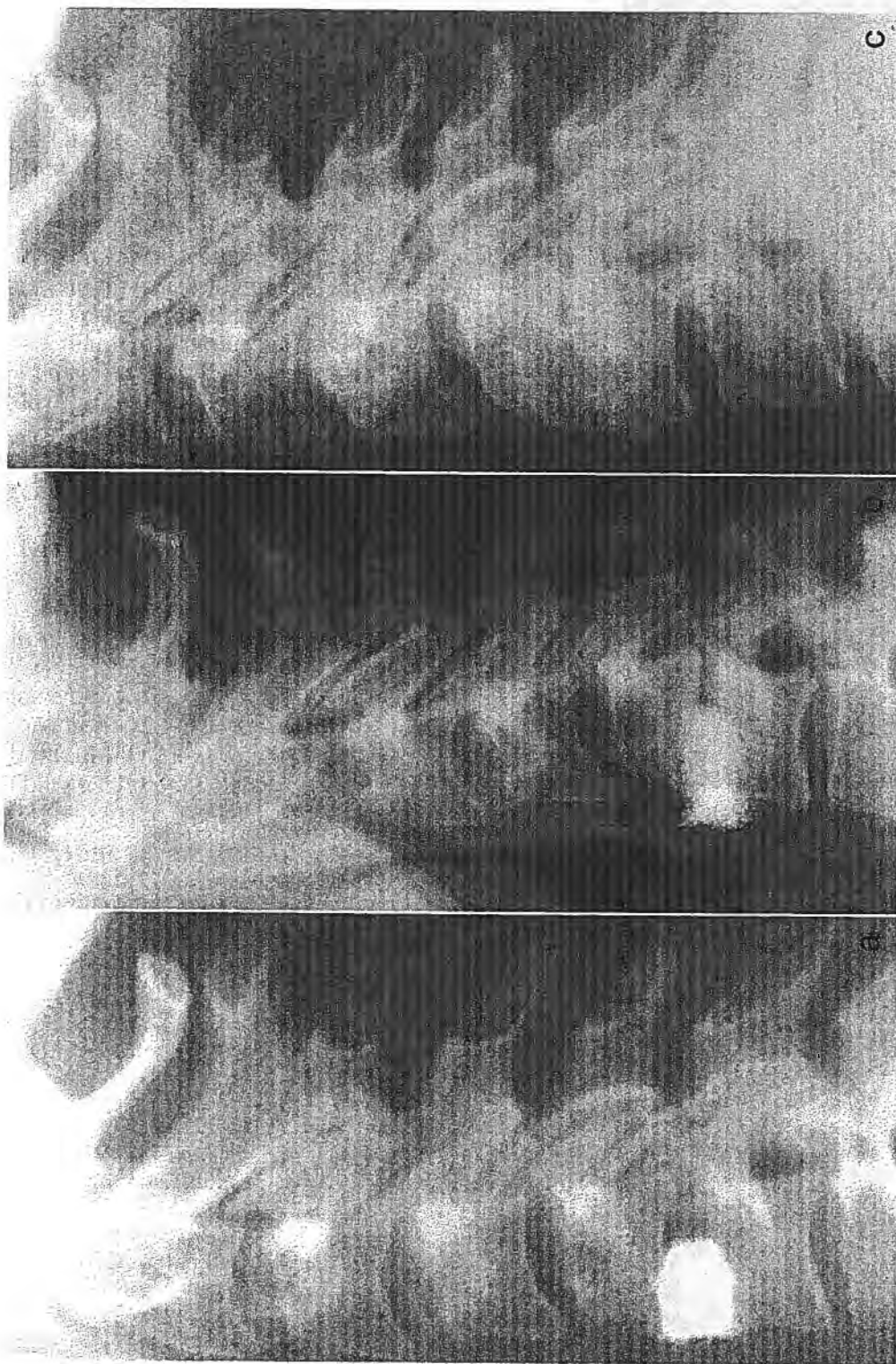


Figure 7.34



Figures 7.35 a-c

h) Graft Impaction

The final critical manoeuvres required to seat the graft in the dowel cavity are illustrated in Figs. 7.37a–d. Before insertion of the graft, the surgeon must always measure the depth of the dowel cavity and the depth of the graft. Great force is never required during their impaction. Soft tissues should be carefully retracted from the margins of the cavity and the neck should be gently elongated by traction applied to the skull before the graft is inserted.

i) Wound Closure

After the grafts have been inserted, a careful inspection should be made of the anterior aspect of the vertebrae; any bleeding points should be coagulated, especially along the medial margins of the longus colli muscles.

The neck wound may be closed, without drainage, except after multi-level fusions or in rare circumstances after associated thyroid surgery.


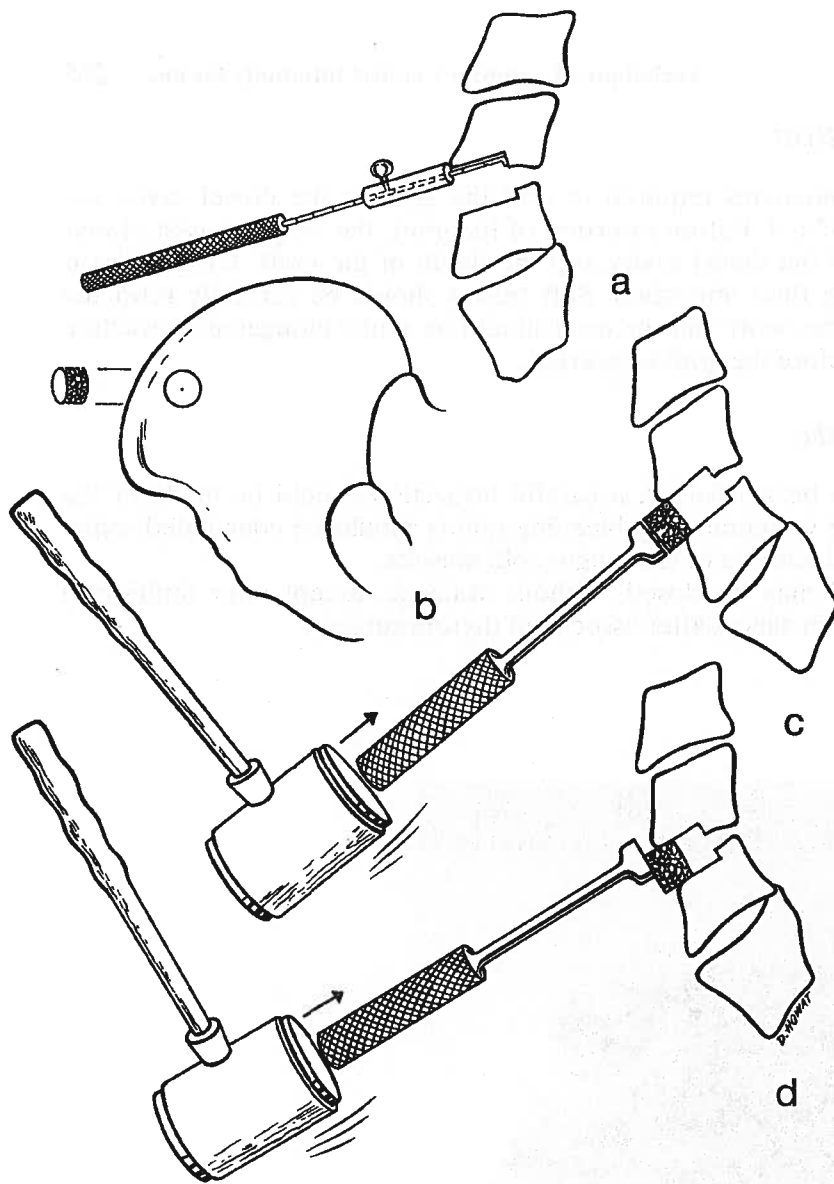


Figure 7.36. A photograph of the fragmented titanium mesh graft removed from the cervical spine of the patient whose X-rays are shown in Figs. 35a–c. Soft tissues stained an intense black colour were mingled with the titanium strands

Figures 7.35a–c. **a** A lateral X-ray of the cervical spine of a female patient aged 42 years showing a titanium mesh implant approximately 3 months after insertion. **b** Six months after insertion, the implant has collapsed and partially extruded anteriorly. The patient's symptoms of neck pain and brachial neuralgia had recurred. **c** A lateral X-ray of the same patient's cervical spine following removal of the titanium mesh implant, showing successful interbody fusion with an autogenous bone graft



Figures 7.37 a-d. **a** A drawing of the cervical spine, viewed from the side, showing a prepared dowel cavity between two vertebral bodies with a depth gauge inserted to measure the depth of the cavity before the graft is inserted. **b** A drawing of the pelvic crest to show the site of removal of a plug of bone which is cut from the inner to the outer table. The measurement of this graft between the two cortical surfaces varies, depending on the size of the patient's pelvis. Grafts should be trimmed so that the anterior and posterior margins are parallel. The depth of the anterior iliac crest between the inner and outer cortical tables varies between 5 and 15 mm. In patients in whom the pelvis is thin (3-5 mm between outer and inner cortices), it may be necessary to cut grafts vertically downwards from the top of the crest, by the method used in lumbar interbody fusions. **c** A drawing to show the initial stages of impaction of the graft, the measurement of which has been checked carefully with the measurement of the prepared dowel cavity. At this stage the anaesthetist is asked to elongate the neck by applying traction under the angles of the mandible. **d** Final seating of the graft is sometimes necessary if the anterior margin is not flush with the anterior vertebral margins after use of the initial impactor which has a central nipple on it, as illustrated in (c) above. The manoeuvre shown is performed with a plain-ended impactor and it is *important to note the impactor is placed half-way across the graft and half-way across the adjacent vertebral body so that when a blow is struck with the hammer it is impossible to drive the graft too deeply into the dowel cavity, the impactor coming to rest on the anterior vertebral margin*. Accurate seating of the graft is essential if the complications of graft rotation or post-operative prolapse are to be avoided

j) Post-Operative Management

Patients complain of little pain after this operation, in contrast to those who have had cervical laminectomies.

Nursed with the head raised on two or three pillows, they should have collars fitted in the operating room (Fig. 7.38, 7.39). Patients are more comfortable when they wear an appropriate neck support after cervical fusion.

Dysphagia is common in the first few days after surgery; restriction of the intake of solid foods is advisable, but special measures in management are rarely required. During an anterior cervical interbody fusion at the C2/3 level, in one case, a small pharyngeal laceration occurred. This was sutured. Nothing was given to the patient by mouth for three days, intravenous fluid replacement being administered during that time, with prophylactic chemotherapy and no ill-effects resulted.

Within twenty-four hours of operation, patients should be encouraged to get out of bed and to walk short distances. Their stay in hospital averages 5 days.

Travel by car should be avoided for six weeks and then allowed only in vehicles fitted with head rests. Until the graft or grafts have incorporated with the vertebrae, a collar should be worn at all times when travelling.




Figure 7.38. A photograph of a light plastic collar of adjustable height suitable for use in the post-operative period after single level anterior fusion operations. This type of collar is also suitable for use in the conservative management of patients with neck pain after neck injuries, or for the treatment of recurring symptoms of neck pain and occipital headache due to cervical spondylosis

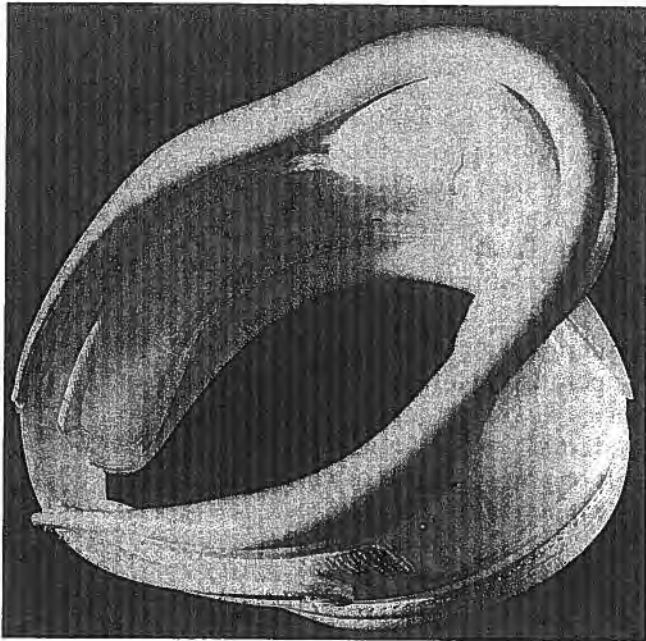


Figure 7.39. A photograph of an adjustable plastic cervical collar with supporting chin piece suitable for use after multi-level cervical fusions

7.5. Radiological Changes After Interbody Fusion

Autogenous grafts, even when they fill less than 50% of the dowel cavity into which they have been impacted, will fuse imperceptibly with the adjacent vertebral bodies and within a few years the whole of the vertebral interspace will ossify and consolidate. The capacity for remoulding of protruding graft margins and for *resorption of immature osteophytes* surrounding the vertebral margins is remarkable once interbody fusion has occurred. Lateral tomography is still the best method of assessing union of cervical interbody grafts (Figs. 7.40–42)

MRI now provides the most reliable information on changes in the dural sac and its contents in cases of cervical spinal canal stenosis with myelopathy, both before and after operation (Figs. 43 a,b), while CT images, using “bone windows” with axial slices and sagittal reconstructions are best for measuring the dimensions of the canal.

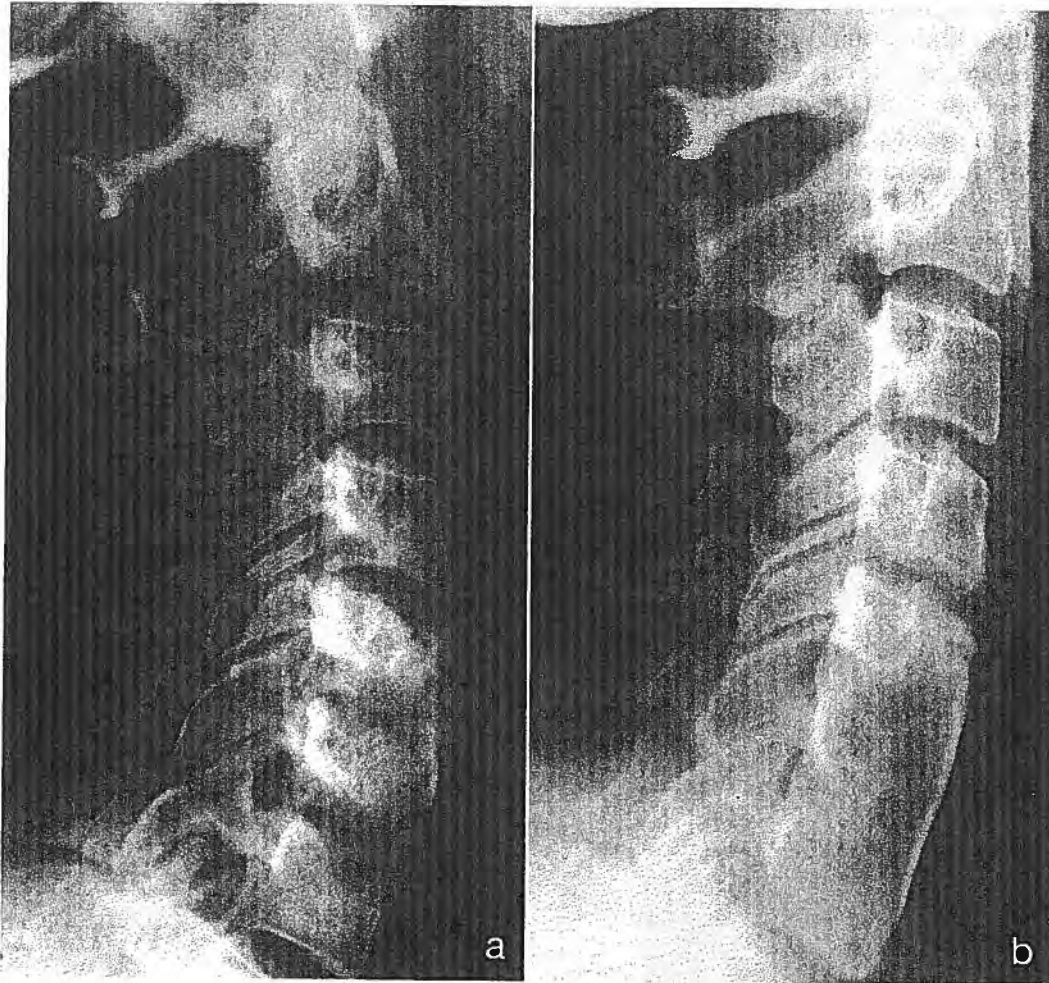
Union with this method can be expected in about 96% of cases. Mal-union with kyphosis may occur, if the shape of the grafts at the time of operation was unsatisfactory because of the size and contour of the pelvis at the donor site. In such cases, X-rays should be taken at intervals of one, two and four weeks post-operatively. If the

grafts rotate during that time, with resultant kyphotic deformity of the neck, the patient should be re-admitted to hospital and nursed with the head in traction and the neck in extension for several weeks. An orthosis of the type illustrated in (Fig. 7.30a) should be fitted thereafter, with the neck held in the corrected position, checked by lateral X-rays taken with the collar applied. Alternatively a Minerva jacket can be made more cheaply (Fig. 7.44).

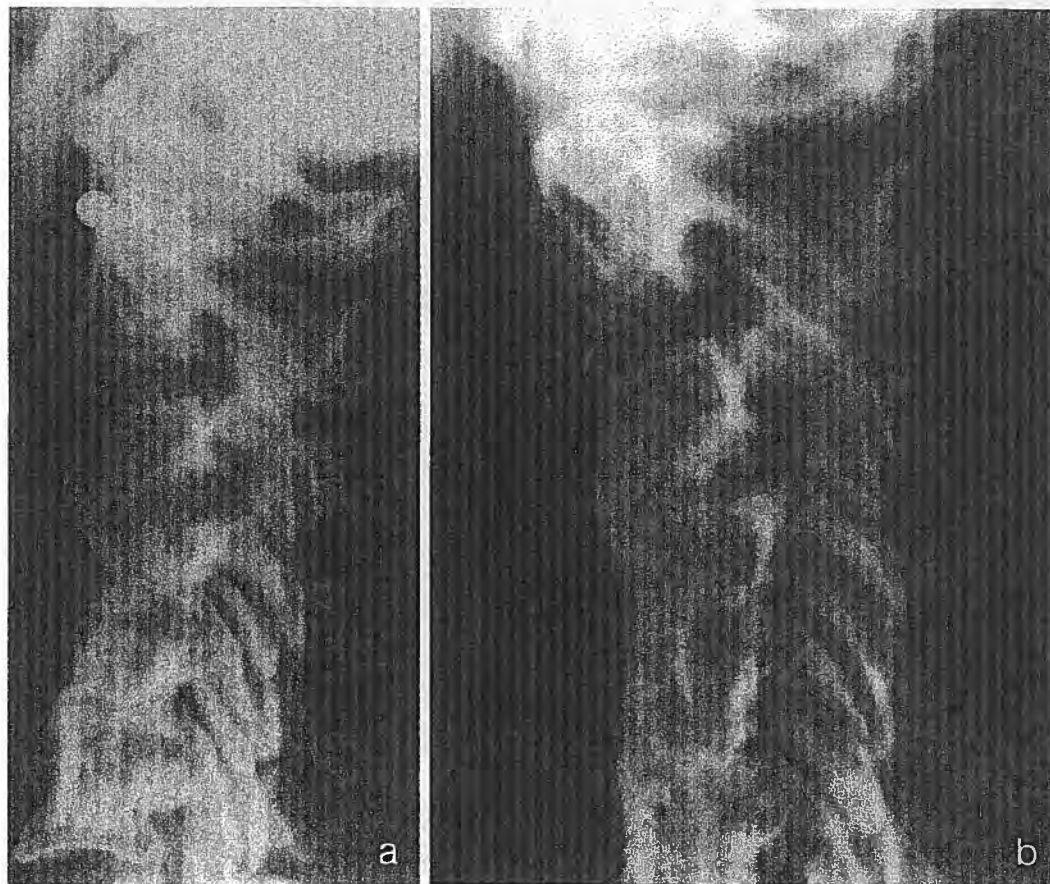
In general, collars should be worn for two or three months, until union of the grafts has occurred. Instruction in the use of gentle mobilizing neck exercises should be given at that time. Should restriction of neck movements persist beyond six months after fusion, the neck may be gently manipulated with gentle longitudinal traction and rotatory motions to right and left, under a short-acting general anaesthetic.

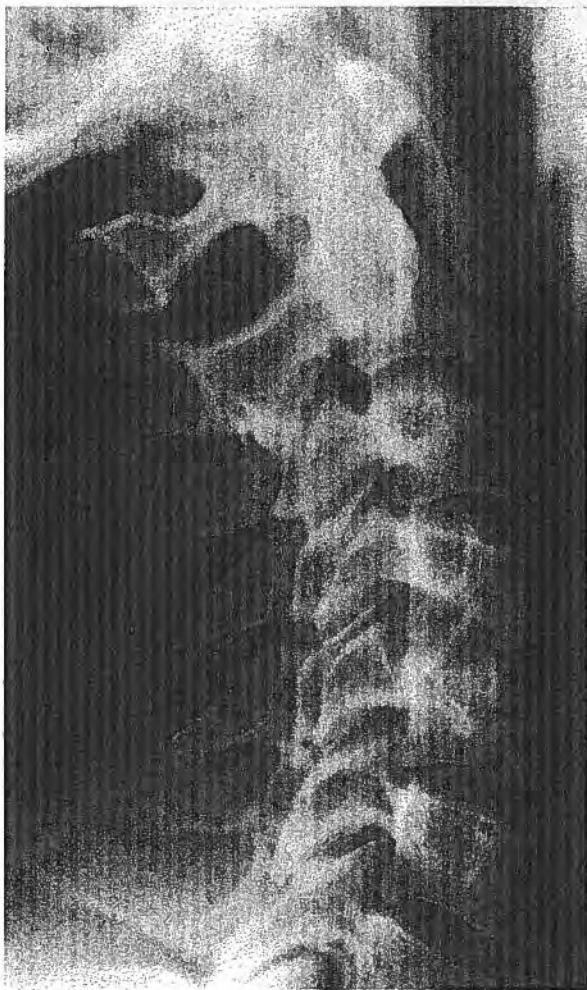

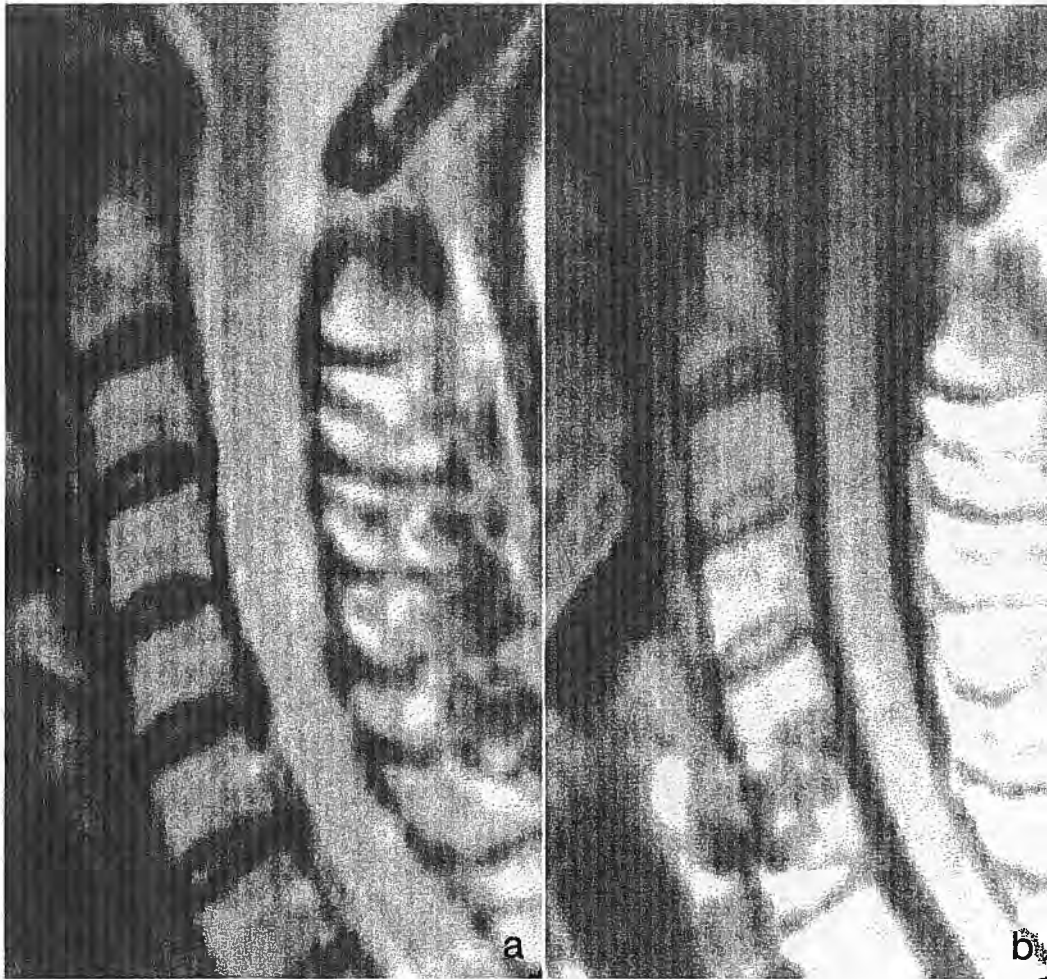
Figure 7.40. A lateral radiograph of the cervical spine of a man aged 24 years taken five months after an anterior cervical fusion performed at the C4/5 level for post-traumatic internal disc disruption. The fusion is solid and union has occurred without spinal deformity



Figures 7.41a,b. **a** A lateral radiograph of the cervical spine of a man aged 34 showing the appearance at three months following anterior interbody fusions at C5/6 and C6/7. Early incorporation of the grafts in satisfactory position is evident. The indication for the operation in this case was to control intractable neck pain and headache with some referred shoulder pain following post-traumatic internal disc disruption demonstrated by discography. **b** A radiograph of the same spine taken five years later showing complete remodelling of the fused segments between the vertebral bodies at C5/6 and C6/7



Figures 7.42 a, b. **a** A lateral radiograph of the cervical spine of a female aged 46 years taken 3 months after operation showing interbody grafts at C3/4, C4/5 and C5/6. This patient presented with symptoms and signs of cervical myelopathy. The lower two grafts have united in good position with the vertebral bodies. The graft at C3/4 has tilted and its upper anterior cortical edge is prominent in the retropharyngeal space. **b** A lateral radiograph of the same person's cervical spine 18 months after operation. Note the remoulding of the graft at C3/4



Figures 7.43 a,b. **a** A sagittal T2 weighted sequence MRI of a female aged 42 years presenting with signs of cervical myelopathy, with lower limb spasticity, showing constriction of the cervical canal at C5/6. **b** An MRI of the same patient one year after anterior cervical canal decompression, using a diamond tipped high speed drill. Sound interbody fusion has occurred and the normal dimensions of the spinal canal have been restored at the C5/6 level

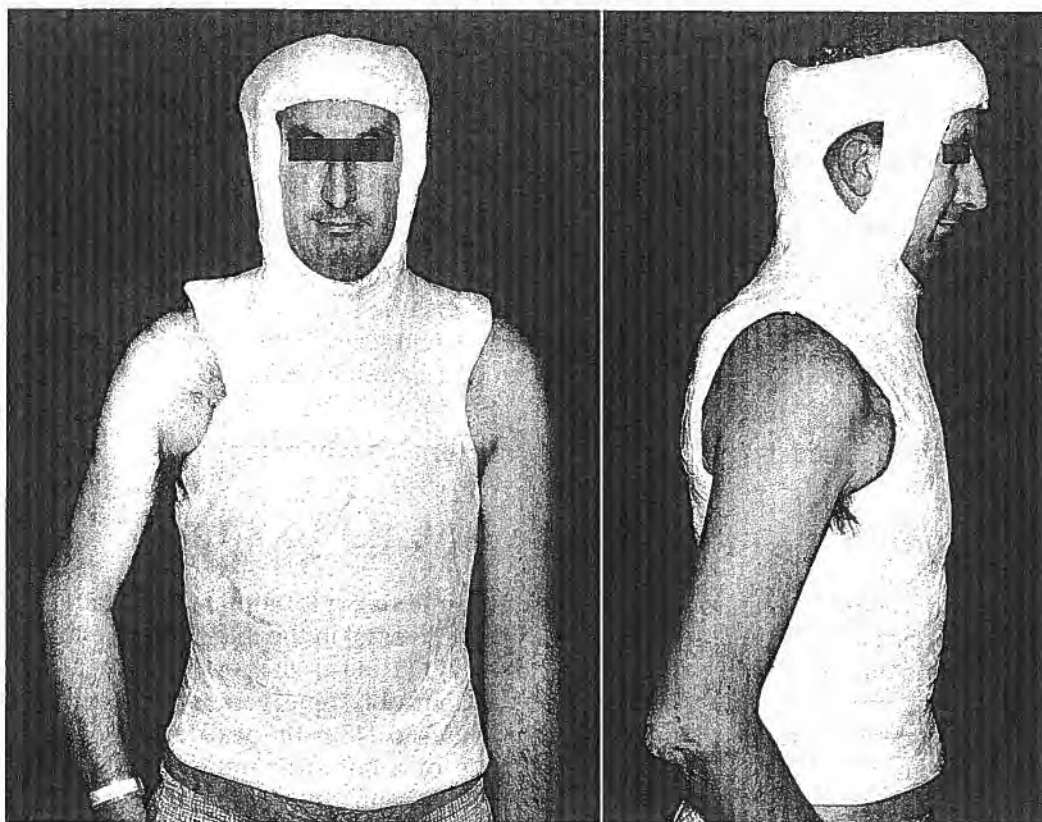


Figure 7.44. A photograph showing a patient viewed from in front and from the side, fitted with a Minerva jacket for immobilization of the upper cervical spine following occipito-cervical fusion. Although variations of halojackets are available, this useful method of spinal immobilization is illustrated for the benefit of surgeons who do not have access to more expensive commercially available braces such as the halo with thoracic jacket and pillar supports. Before the Minerva jacket is fitted, the patient should be placed on a tilting bed so that he is used to standing in a vertical position, and then the jacket can be put on when he is able to stand without dizziness for periods in excess of 30 minutes

7.6. Complications

The list of potential complications following anterior cervical interbody fusion operations includes:

1. Quadriplegia.
2. Unilateral blindness produced by the pressure of an assistant's hand resting on the globe.
3. Vascular catastrophe involving the vertebral or carotid arteries.
4. Severe venous haemorrhage following damage to the jugular vein.
5. Oesophageal laceration.
6. Horner's syndrome.

Reviewing my own experience with the use of this operation during the past thirty years, I have had to deal with a range of minor problems and with only a few serious complications.

a) Minor

These have included dysphagia and transient Horner's syndrome.

b) Major

In one case, a large haematoma in the neck required re-exploration for evacuation of the blood clot and coagulation of a small bleeding vessel in the margin of the longus colli muscle on one side.

In one case, the lady was very thin, and troublesome venous haemorrhage occurred when a small un-named vein was avulsed from the wall of the internal jugular vein. This was controlled with the use of a 6/0 atraumatic vascular stitch inserted into the medial wall of the internal jugular vein at the site of avulsion of the venule. This incident is mentioned because there is an important lesson to be learned from it. Anterior approaches to the cervical spine can be very difficult and time-consuming in heavily built patients with short thick necks. In very thin patients, however, it is often possible to complete an anterior cervical interbody fusion at a single disc level within one hour. *The case just cited shows that caution and vigilance must be exercised at all times.* A surgeon can never afford to approach this particular operation lightly, as problems may arise unexpectedly in any patient.

In one case, already referred to in the text above, a small pharyngeal laceration occurred.

Graft rotation with resultant acute cervical kyphosis has required surgical treatment in only four cases. However, unrecognized mal-union, with minor degrees of cervical kyphosis has been identified on X-rays taken three or four months after operation in a small number of cases.

Infection of neck wounds, with vertebral osteomyelitis occurred in six patients. One patient was diabetic, two others were heavy smokers with bronchitis, in the fourth, infection arose apparently spontaneously early after operation, while the fifth and sixth followed trans-oral C2-3 fusions.

These cases all resulted from infections with staphylococcus aureus organisms. All required drainage of pre-vertebral abscesses. Use of chemotherapeutic agents was determined on the results of sensitivity tests following culture of the organisms. Chemotherapy was used for at least three months, and in two of these patients its use was continued for one year after operation. Recurrent septicaemic episodes occurred in both when the use of Cloxacillin was discontinued after three months. Each of these patients recovered without disability – see Chapter 10.

Finally, I have had experience with the management of one referred case of quadriplegia resulting from neglect in treatment of a chronic wound infection in the neck. This patient presented with a small discharging sinus in the line of the neck incision which had been made at the time of anterior cervical fusion four months earlier. He was unable to stand or walk and had also severe paresis of both upper limbs. Lateral X-rays revealed a large pre-vertebral abscess, with a severe kyphotic deformity at the site of bone grafting.

The abscess was drained under general anaesthesia. Long-term chemotherapy was administered. The patient was nursed with skull traction with his neck extended over a rolled towel. See Chapter 8, p. 278 for further details. The quadriplegia recovered and spontaneous interbody fusion followed, with correction of the kyphotic deformity. Supplementary bone grafting was not required.

7.7. Results of Operation

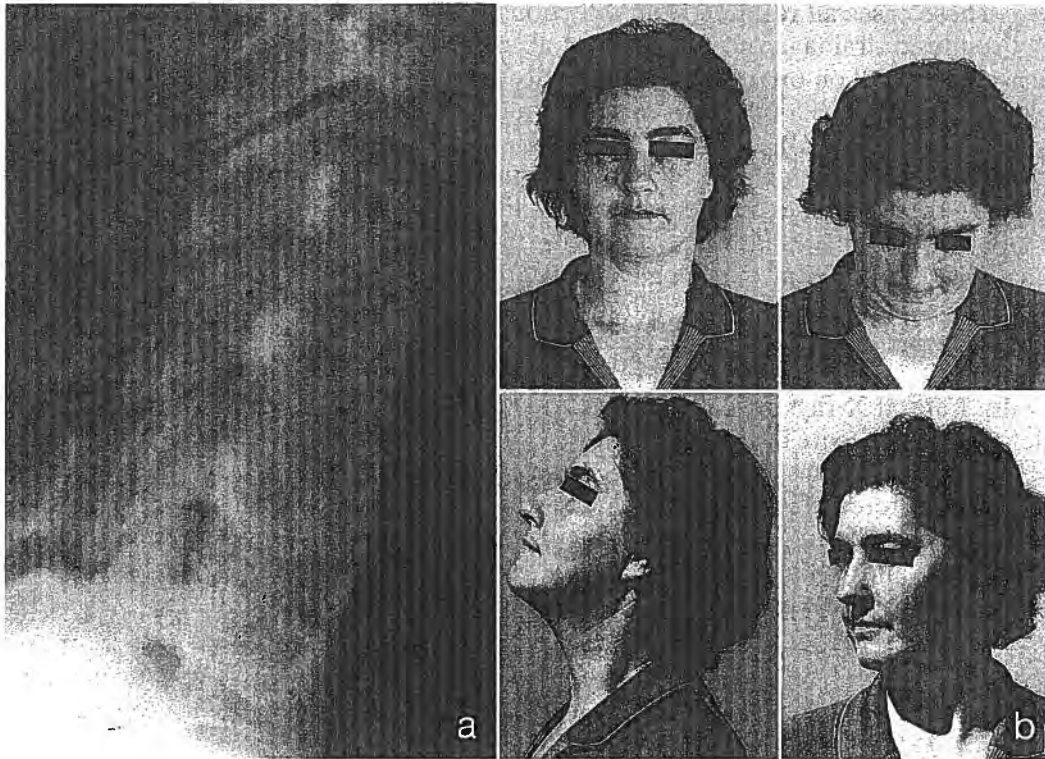Technically, excellent results can be achieved using this technique for anterior cervical interbody fusion. Non-union of grafts may occur in about 4% of patients.

Return to work is usual between four to six months following operation. I believe that it is unwise to persuade patients to return to work within one or two weeks of this operation – a claim made by some of its proponents – but foreign to my experience.

Neck motion is slightly restricted after multi-level fusion (Figs. 7.45 a, b), though normally full after single level grafting.

7.8. Posterior Cervical Spinal Fusion

The indications for these procedures have been set out above. Details of surgical technique will not be discussed as they involve simple manoeuvres which are in common use. However, radiographs showing the appearance of conditions requiring these procedures, with post-operative X-rays are found in Figs. 7.2 a, b, together with photographs of suitable braces and a Minerva jacket which may be used post-operatively (Figs. 7.30–32, 7.39, 7.40) if facilities are not available for obtaining expensive orthoses.



Figures 7.45a,b. **a** A lateral radiograph of the cervical spine of a woman aged 46 showing a three-level anterior cervical fusion between the bodies of C4/5, C5/6 and C6/7 taken five years after operation for the relief of intractable neck pain and occipital headache with some referred arm pain, in the absence of neurological signs. This patient had post-traumatic multi-level disc disruption following a high speed rear-end collision which had inflicted a whiplash mechanism of injury on her cervical spine. **b** Four photographs of the patient whose X-ray showing multi-level cervical fusion is reproduced alongside, to demonstrate the ranges of motion of the neck after a fusion of this extent. Flexion and extension movements and the range of lateral rotation are all restricted. However, the functional result is regarded as satisfactory by the patient who has remained symptom-free for 15 years since this operation

Figure 7.46. A photograph to show the arrangements for posturing the patient on an operating table for posterior approaches to the cervical spine. When the patient is in the prone position for operations on the cervical spine, precautions must be taken to ensure that the anaesthetic tubes and airways are securely fastened, with all their linkage points strapped to prevent accidental separation during the surgery. When the patient is in this position, the skin of the neck is often lax. Strapping should be applied across the hairline transversely and fixed to the head support. Further strapping is then attached across the vertex of the skull running from the transverse strapping to the front of the headrest. In addition, long strips of strapping should be applied just lateral to the spinous process of C7 on both sides, running down the back to the buttocks. This will ensure that the skin of the neck is tightly stretched, making the incision and its subsequent closure much easier. Note also the inclination of the table. If the head is raised any further, then the potential risk of air embolism is increased

7.9. Cervical Laminectomy

a) Positioning (Fig. 7.46)

The prone position, using a neurosurgical headrest, provides satisfactory conditions for operation.

b) Exposure

The techniques used in this approach to the laminae are identical to those described for exposure of the lumbar spine, except that the scale and mobility of the bones is different, the cervical spine being small and very mobile. Smaller instruments are therefore required for use in this area.

The knowledge of applied anatomy assumes great importance because disastrous complications may occur as a result of uncontrolled haemorrhage, particularly in approaches to the occipito-cervical junction. Damage to the vertebral arteries may lead to catastrophic neurological complications following the resultant interference with cerebral circulation. In addition the sub-occipital veins are very large with

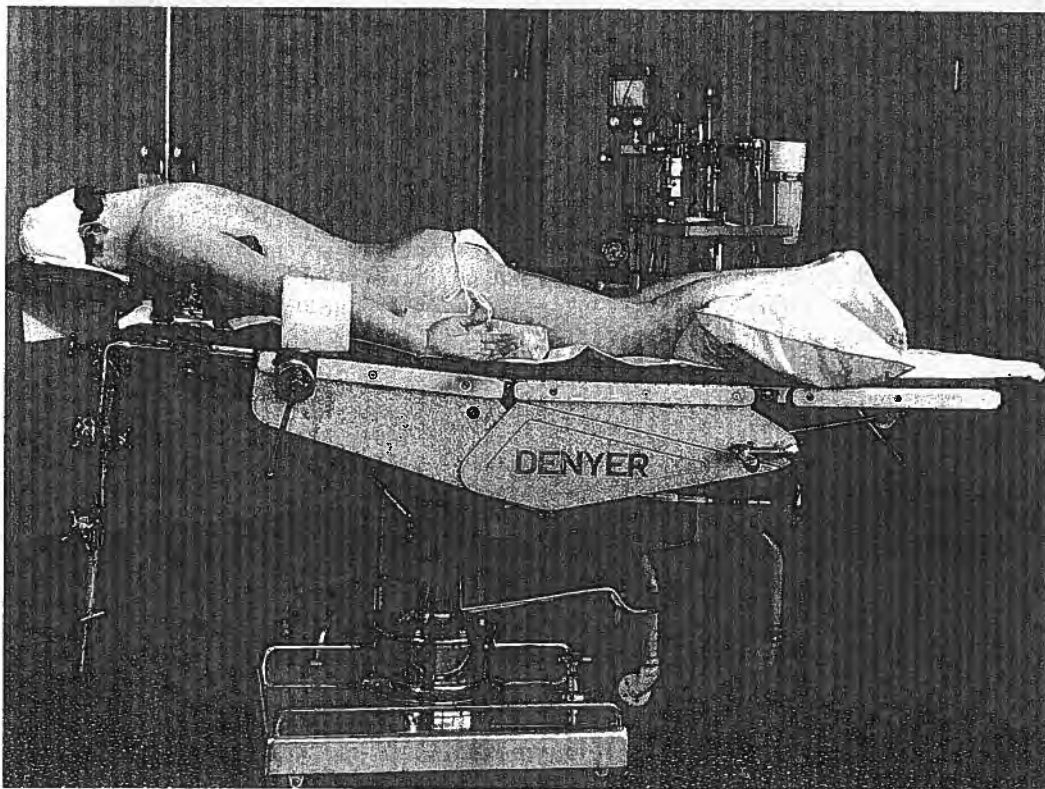


Figure 7.46

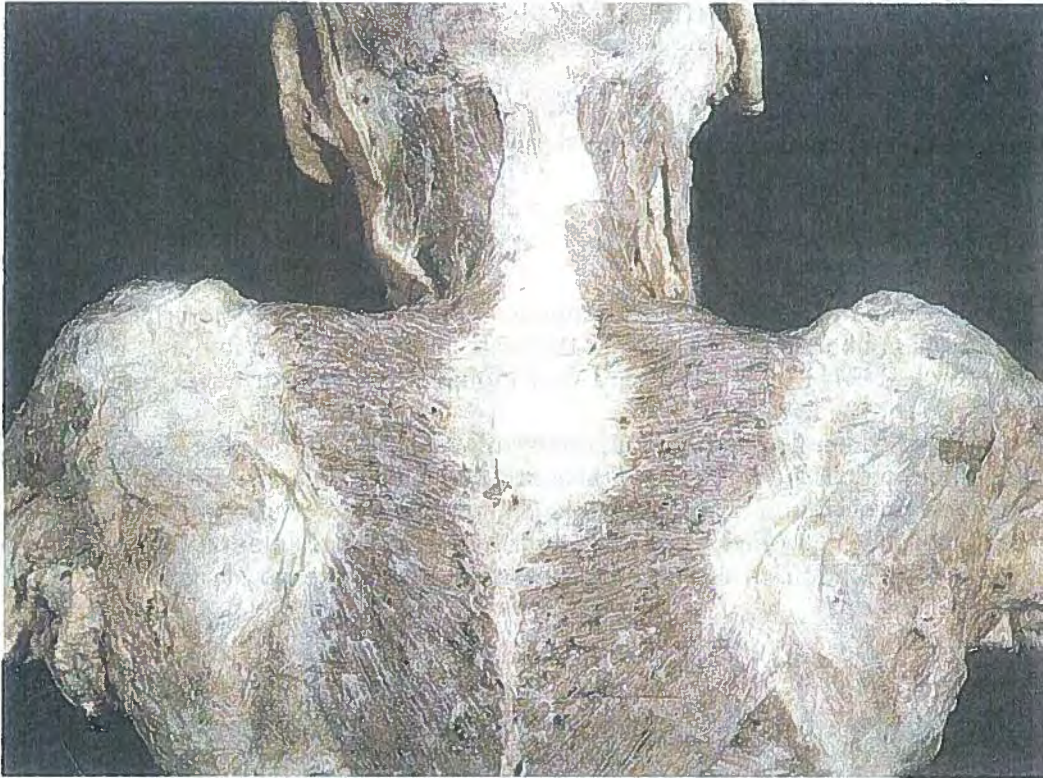

Figure 7.47. A photograph of a dissection of the posterior muscles of the neck and of the upper part of the trapezii. Note the central diamond shaped area of glistening white aponeurotic fibres from which the middle part of the trapezii arise on either side, the muscle fibres passing horizontally laterally. The investing layer of deep cervical fascia covers the trapezii and the splenius capitis muscles on both sides. On the left side of the specimen it has been largely removed while on the right side it has been left in situ covering the upper portion of the trapezius muscle to the level of its attachment to the skull. Note the large vascular channels which perforate the trapezius aponeurosis around its margins

delicate walls. If breached under certain conditions, air embolism becomes a potential hazard.

When internal fixation devices are to be used in the neck, a sound working knowledge of the applied anatomy of cervical osteology is essential. Developments in this area of instrumentation have led to the introduction of excellent devices for interlaminar fixation such as the Halifax interlaminar clamp (Figs. 7.47–50).

The use of sub-laminar wires should only be considered when the dimensions of the cervical spinal canal are within normal limits. When the C1/C2 vertebrae are fixed with trans-articular screws, the graft between the laminae is best held in place with sub-laminar braided nylon threads rather than with sub-laminar wires (Figs. 7.9a,b).

Inter-segmental stabilization can also be obtained using plates and screws. In the anatomical position, the cervical facet joints from C2 distally lie in the coronal

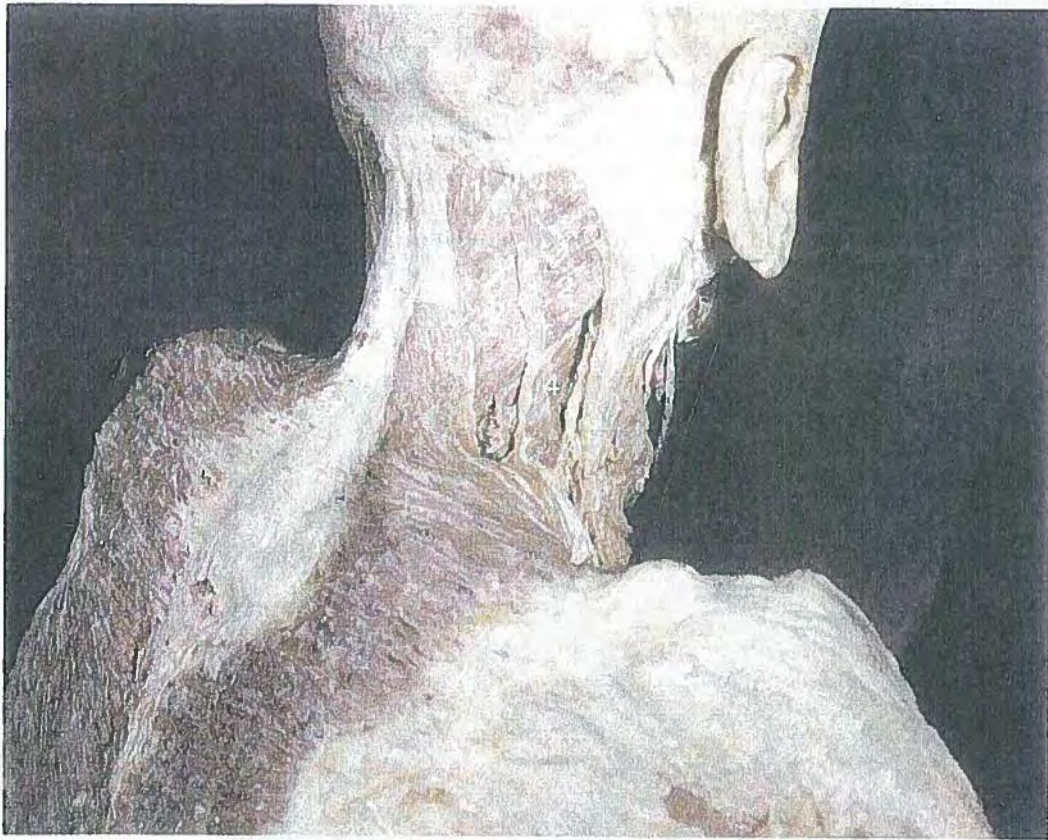

Figure 7.48. A photograph of the same specimen viewed from the right side. The encircling layer of deep cervical fascia has been removed along with a section of the trapezius muscle, to show the underlying muscles from left to right 1 the semispinalis capitis, 2 the splenius capitis, 3 the lateral edge of the trapezius and 4 the longissimus capitis

plane. Screws should be placed above and below the level of the facet joint in the sagittal plane and angled 10 degrees laterally (Fig. 7.7).

Having identified the lamina or laminae to be removed, the spinous processes should be excised. Then, using a Leksell-type rongeur, with thin cutting blades, the inferior surface of the superior lamina at the interspace can be removed piece-meal, while the thin ligamentum flavum is still intact. Having enlarged the inter-laminar space, the ligamentum flavum can be reflected and excised, after passing a small moistened patty beneath it, propelled gently laterally on the tip of the curved end of a Watson-Cheyne dissector. This done, on both sides of the canal, preparation is then made to perform foraminotomies. The soft tissues and veins are separated carefully from the remnants of the roof of the spinal canal, one side at a time. The pedicles can be identified using the curved tip of the Watson-Cheyne probe. Venous

bleeding should not obstruct the surgeon's view, unless the manoeuvres just described have been carried out carelessly or too quickly.

Using a forward-angled 45 degree rongeur with a 1 or 2 mm cup, it is then possible to open the roof of the intervertebral foramen, protecting the dura and nerve root sleeve with a patty on the end of a fine sucker. When this has been done, the regional veins will distend remarkably if a stenosis in the region has been relieved. Some brisk venous haemorrhage may then occur. This is best controlled by the application of small fragments of gelfoam (or its equivalent) packed lightly in place with an overlying moist patty. The use of coagulating currents, through low voltage diathermy machines, is still widespread. However, I have not found it neces-

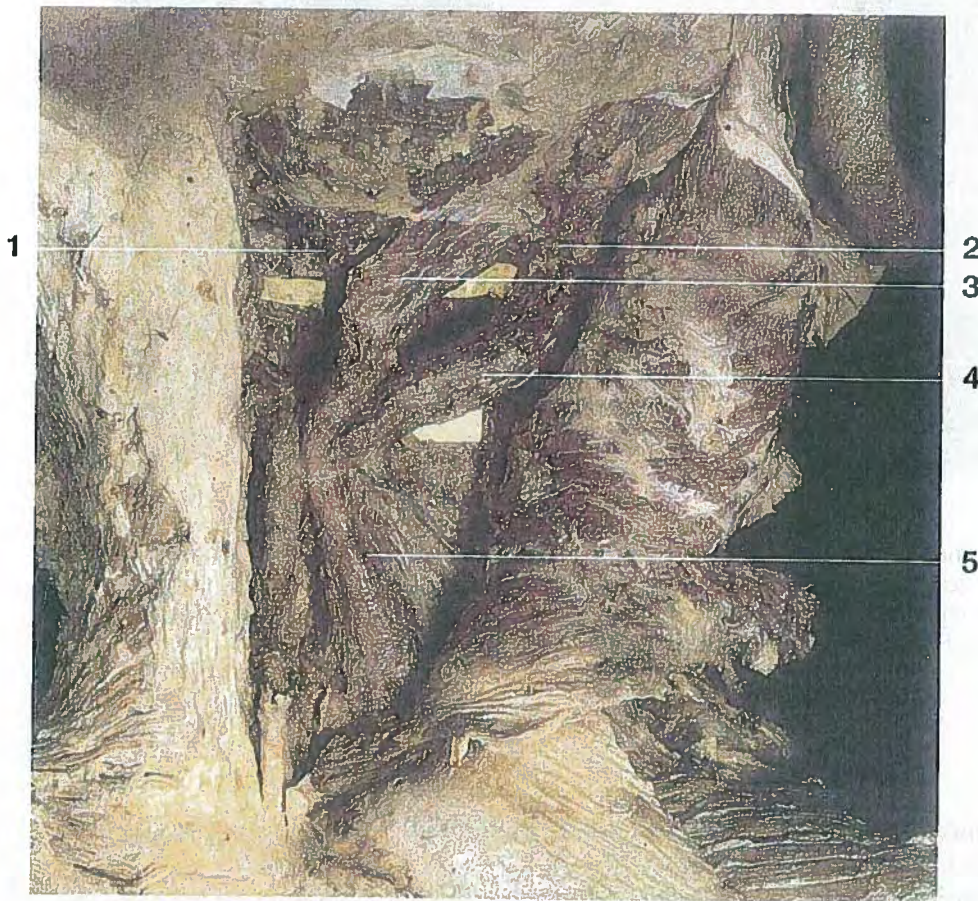

Figure 7.49. A photograph of the same specimen dissected to display the sub-occipital muscles. The upper yellow marker lies beneath the rectus capitis posterior major on the posterior arch of the atlas. The lower triangular shaped marker is placed on the lamina of C2. Lying between the margins of these individual muscles, large sub-occipital veins are found in life. The deep sub-occipital muscles are labelled below: 1 Rectus capitis posterior minor, 2 Obliquus capitis superior, 3 Rectus capitis posterior major, 4 Obliquus capitis inferior, 5 Multifidus cervicis. (Dissected by Doctors H. Nakamura and H. V. Crock and reproduced by kind permission of the President and Council of the Royal College of Surgeons of England. These dissections were prepared in the Anatomy Department with the permission of Professor S. Sinatamby)

sary to resort to this method of haemorrhage control, which I believe to be potentially dangerous if used at multiple levels in the cervical spine. There may be a significant risk of damaging the fine segmental arteries which join the anterior median longitudinal arterial channel of the cervical spinal cord if diathermy is used to excess in the region of the intervertebral foramina within the cervical canal (Crock and Yoshizawa, 1977).

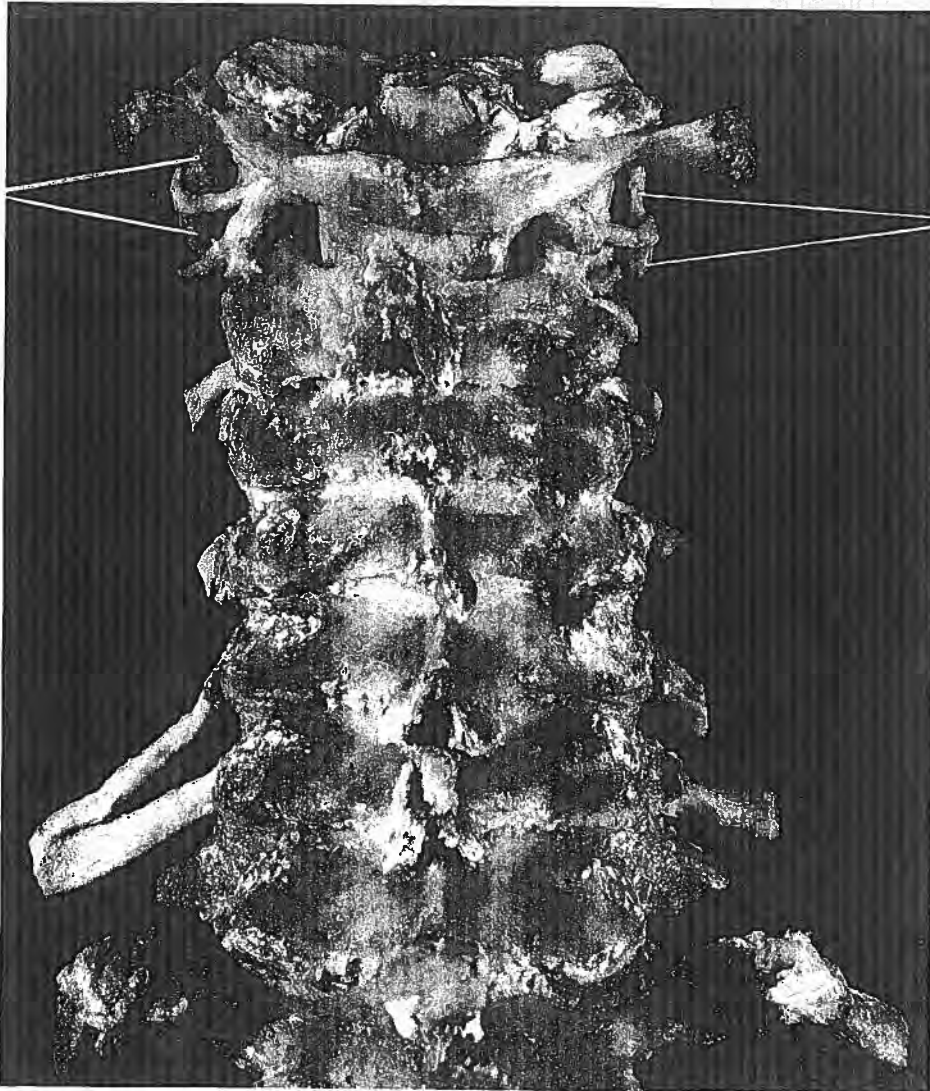


Figure 7.50. A photograph of a dissection of the cervical spine viewed from behind. All the soft tissues have been removed except the ligamenta flava, the dural sac and the emerging nerve roots. At the level of C1 and C2, note the relationships of the emerging nerve roots to the vertebral arteries on both sides (white arrows). The facet joints from C2 distally can be seen orientated in the coronal plain. In the cervical spine the interlaminar spaces are very narrow at all levels and only a few millimetres of ligamentum flavum can be seen in the normal state. (Dissected by Dr. M. C. Crock)

On completion of the "laminectomy" and foraminotomies, the partes inter-articulares of the laminae being preserved, along with the bulk of the facet joints, the wound should be closed with suction drainage. Before this is done, haemorrhage should be controlled, using haemostatic agents in the cervical canal as described, and diathermy in the muscle layer.

Facets should be preserved, except in cases of trauma, when facetectomy may be required to allow reduction of a fracture-dislocation. Localized inter-laminar posterior cervical fusion should be performed then, using either laminar clamps or screws inserted into the lateral masses.

In patients with multi-level cervical canal stenosis, due either to cervical spondylosis, or to ossification of the posterior longitudinal ligament (OPLL), various forms of laminoplasty have been in use in Japan for more than ten years. The method described by Hirabayashi *et al.* (1989) involves the use of a high speed drill to create parallel channels at the junctions of the laminae with the lateral masses, over the desired number of vertebral segments to be decompressed. The dissection enters the epidural space on one side, allowing the laminal segments to be elevated, thus enlarging the cervical spinal canal.

c) Post-Operative Care

Patients complain of severe pain after posterior cervical spinal operations. Adequate analgesia should therefore be ordered.

The use of soft collars for short periods can be recommended after decompressions of the cervical canal.

8

Spinal Infections

8.1. Acute Vertebral Osteomyelitis

a) Introduction

In clinical practice, acute inflammatory lesions of the spine are relatively uncommon. For this reason alone, diagnosis of vertebral osteomyelitis is often delayed, so that patients may not receive specific treatment for the disease until they present with major complications.

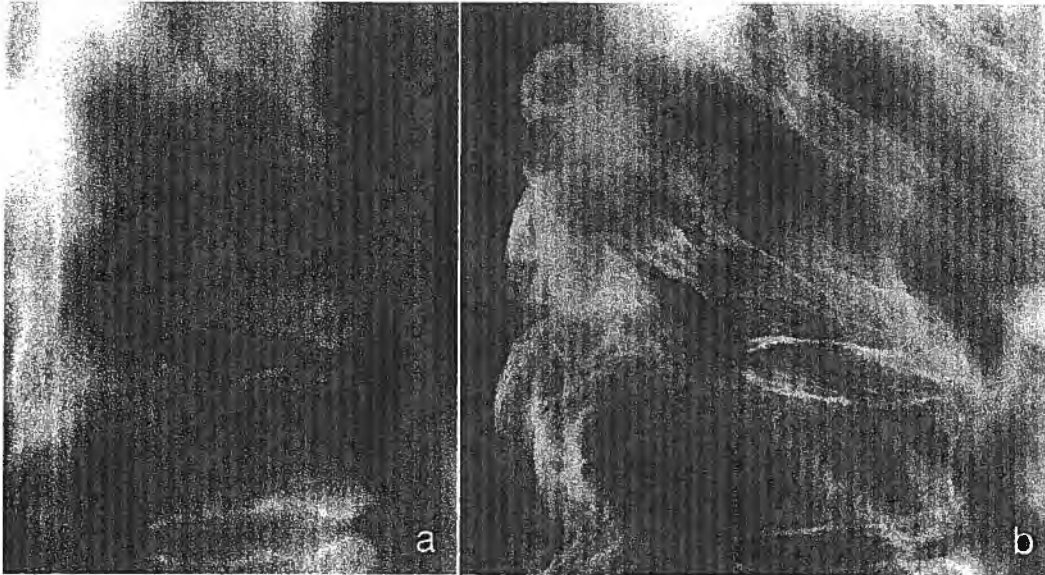
The virtues of specialist hospitals are often hailed but cogent arguments favour the retention of specialist units in large general hospitals, where orthopaedic surgeons and neurosurgeons can be consulted readily about the surgical problems relevant to bone disease, not the least important of which are infective lesions of the spine.

Most referred cases of vertebral osteomyelitis will come from physicians. Vertebral infections follow repeated episodes of bacteraemia or septicaemia which may occur in many debilitating medical diseases such as pneumonia, chronic bronchitis and diabetes mellitus (Figs. 8.1a,b). One of the most elusive causes of pyrexia of unknown origin is sub-acute bacterial endocarditis. Acute vertebral osteomyelitis may complicate the course of this disease before the underlying pathology of the cardiac valvular disease is recognized and even before positive blood cultures have been obtained.

Some cases will be referred from general surgical wards, having been admitted with abdominal pain and fever (Fig. 8.2).

A third significant source of referred cases in general hospitals is from the urology department. Following urethral or bladder surgery, some patients will present with spinal pain due to vertebral osteomyelitis following gram-negative septicemia.

Some general hospitals in particular localities in large cities often admit many drug addicts and alcoholics, in whom complaints of severe spinal pain should raise the suspicion of underlying vertebral infection. A wide range of organisms, including fungi, may be identified either in blood cultures or from needle biopsy specimens in the drug-addicted patient.



Figures 8.1a,b. **a** A lateral tomogram of the mid-thoracic spine of a woman aged 66 who had been under treatment for chronic bronchitis for three months prior to her presentation with back pain and paraplegia. Gross destruction of the vertebral body of T7 is noted with pathological fracture-dislocation. **b** A lateral X-ray of the same area taken four years after conservative treatment of this lesion with long-term chemotherapy. Considerable remoulding of the vertebrae at the site of the dislocation had occurred and the paraplegia had recovered in part

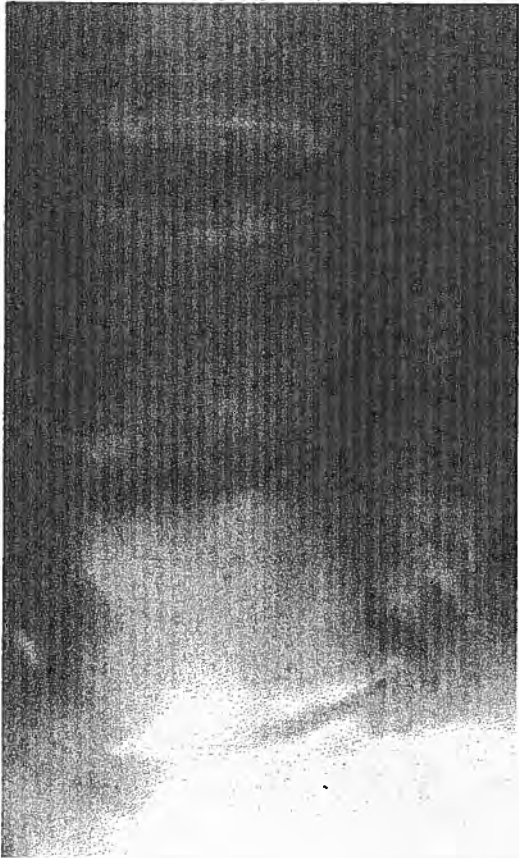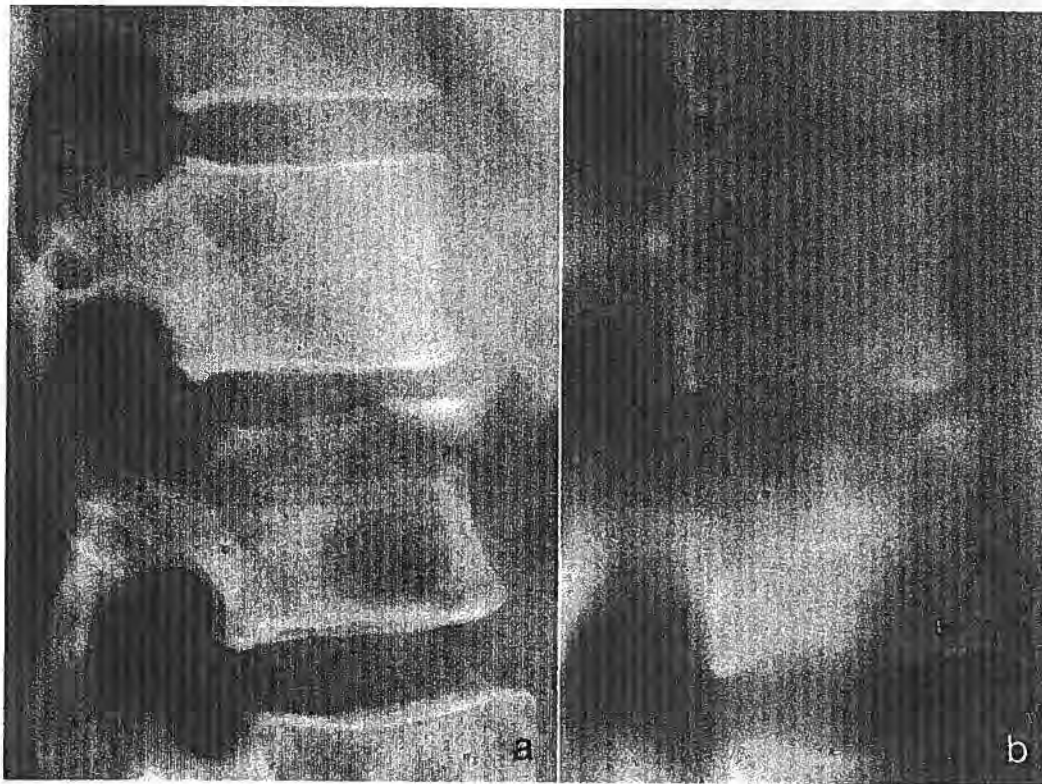


Figure 8.2. A lateral tomogram of the lower lumbar spine of a woman aged 59. Note the changes in the upper half of the body of the 5th lumbar vertebra in the region of the vertebral end-plate, with erosion and narrowing of the intervertebral disc space. The patient presented with acute abdominal pain, overshadowing back pain. The lesion was due to an acute osteomyelitis of the body of L5 complicating bronchitis.

276 Spinal Infections

Organisms lodge in the complex vascular bed, in the region of the vertebral end-plates, in children and adults (Crock and Yoshizawa, 1977). The pathological changes induced vary enormously depending on the bacteriological characteristics of different organisms.

Although the radiological appearances may be similar, in the case of staphylococcal infections chondrolytic activity destroys cartilage and disc tissue, whereas in tuberculous disease these tissues are not destroyed. The loss of disc height shown on X-rays in cases of spinal tuberculosis is due to osteitis with pathological fracture, the disc tissue simply collapsing into the adjacent carious vertebral bodies (Figs. 8.3 a, b).



Figures 8.3a,b. **a** A lateral radiograph of the lumbar spine of a 32 year old lady who presented with a history of low back pain and weight loss. She had not complained of pain in the region of this lesion. The film is centred on the disc between T12 and L1 at the thoraco-lumbar junction. Note the narrowing of the disc space. **b** A lateral tomogram of the same area of the spine. Note the extensive erosive changes in the upper vertebral end-plate of the lower vertebra at the level of the narrowed disc space. This lesion was tuberculous and, at operation, intact disc tissue was found within the cavities of the lower vertebral body

b) *Clinical Findings*

The sudden onset of excruciating spinal pain in a febrile patient, should immediately arouse the suspicion of the diagnosis of vertebral osteomyelitis. Physical signs include:

- marked local tenderness in the spine;
- paraspinal spasm and rigidity, or psoas spasm causing fixed flexion deformity of the hip;
- local spinal deformity;
- rapidly advancing neurological deficits in cases with spinal epidural abscesses (Figs. 8.4 a-c).

c) *Investigations*

Full blood examination should be carried out urgently, and repeated samples of blood taken for bacteriological cultures, both aerobic and anaerobic. The diagnosis of spondylodiscitis is still made with difficulty. In a recent study the mean duration of symptoms before recognition was 6.4 month, Zilkens *et al.* (1991). These workers found estimations of the ESR, CRP and Neopterin (a marker of activated macrophages) very useful in helping to identify vertebral infections.

Other cultures may be taken from infected skin lesions, sputum, urine or faeces, depending on their predicted relevance on clinical grounds.

The significance of the results of many of these tests is that they may form the basis for decisions in the differential diagnosis between infections, acute and chronic, and neoplastic diseases. In addition, the critical choice of appropriate chemotherapeutic agents will depend on some of them.

d) *Radiological Examinations*

i) Plain X-Ray

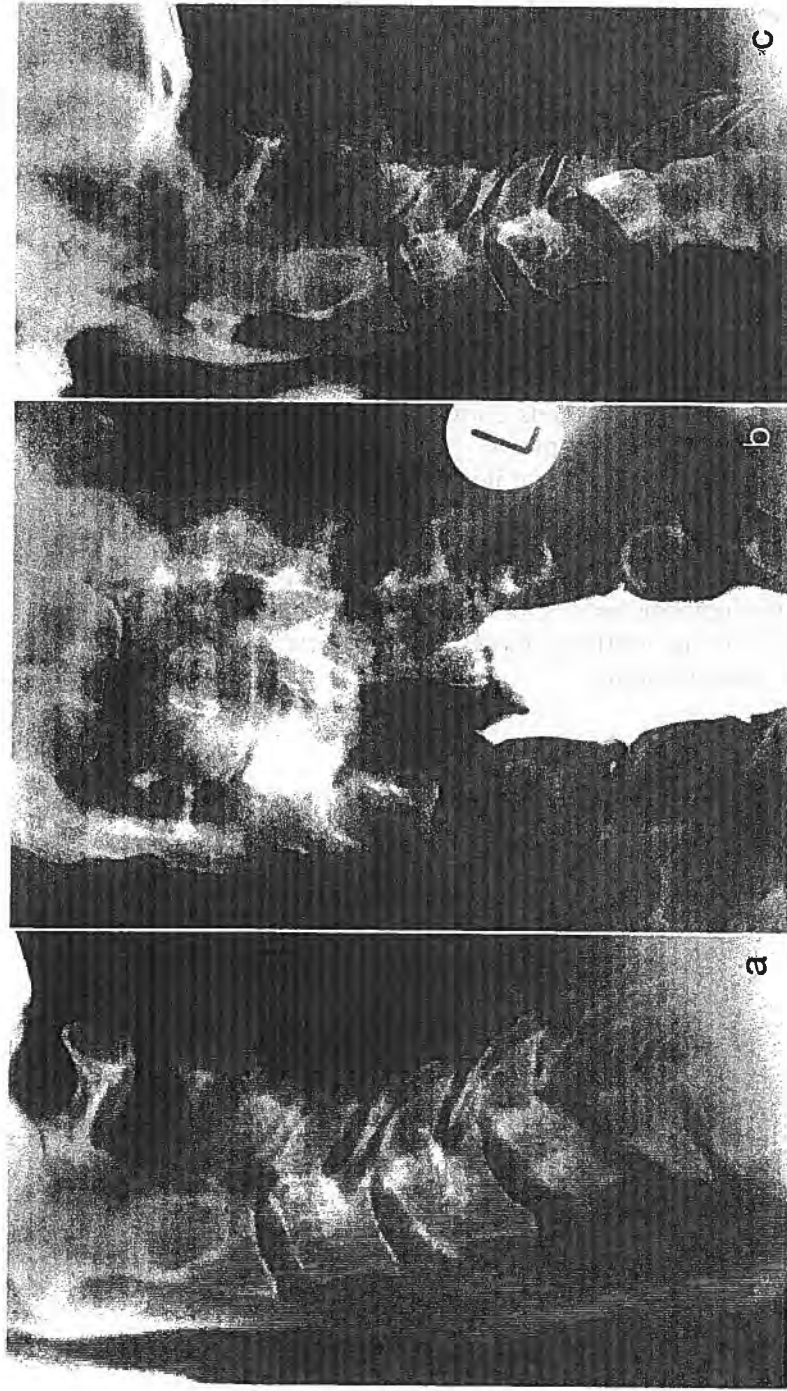
Plain X-rays and tomograms will demonstrate a variety of changes in the bones and soft tissues, pointing to their likely inflammatory basis.

ii) Computerized Axial Tomography

C.T. scanning has been of inestimable value in demonstrating the relationships between pathological changes in the vertebrae and in the related soft tissue structures. Paravertebral and spinal epidural abscesses may be mapped accurately using this technique.

iii) Myelography

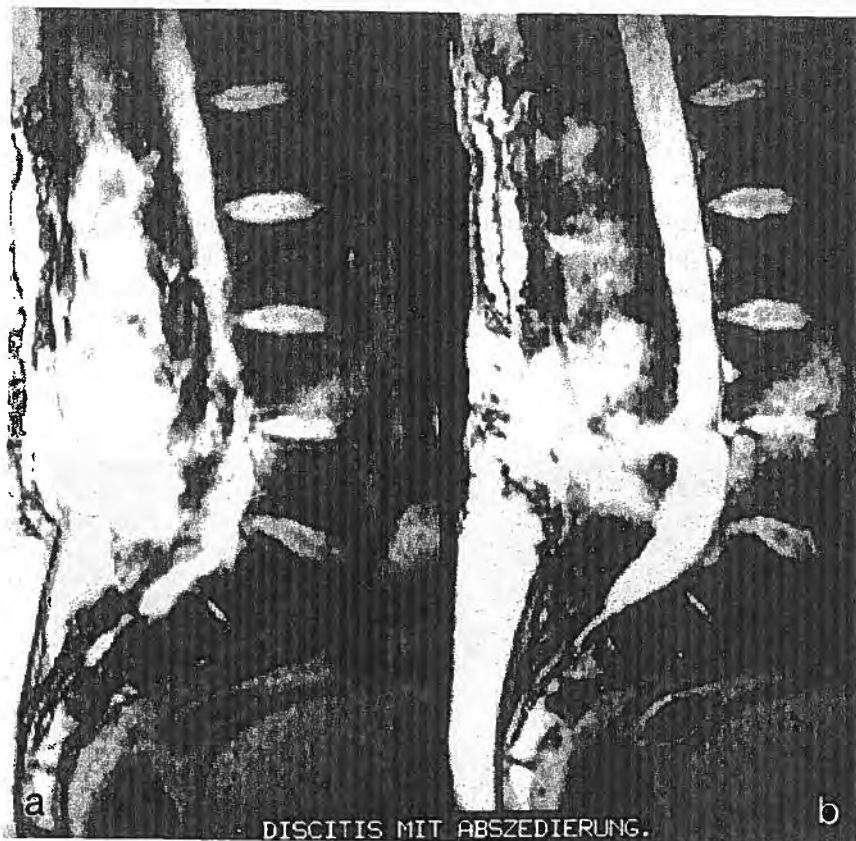
Myelography may be essential to identify the level of obstruction in the spinal canal caused by vertebral collapse or epidural abscess.



Figures 8.4 a-c. **a** A lateral radiograph of the cervical spine of an alcoholic male patient aged 54 years who presented with severe neck pain of sub-acute onset. Note the extensive changes in the vertebral bodies of C5 and C6 with vertebral end-plate erosion in the adjacent vertebral margins of these vertebrae; the disc space is also reduced in height. Note in particular the wide separation of the gas shadow in the pharynx and oesophagus from the anterior aspects of the cervical vertebral bodies, indicating the presence of a pre-vertebral abscess. This patient became quadriplegic within 48 hours of presentation. (By courtesy of Mr B. J. Dooley and Mr J. K. Henderson.) **b** An antero-posterior radiograph of the spine of the same patient showing complete obstruction to the flow of a Myodil column upwards at the level of C6 and C7. **c** A lateral radiograph of the spine of the same patient taken 15 months after operation. The spinal canal was decompressed from behind and a large epidural abscess aspirated. Treatment then consisted of splinting the neck in traction with hyperextension; chemotherapy was administered for twelve months. Note the restoration of the normal relationships between the pharynx and oesophagus and the anterior surfaces of the vertebral bodies

iv) MRI

MRI with gadolinium enhancement has become extremely useful in diagnosing inflammatory lesions of the spine, though it is not always possible to distinguish between neoplastic and inflammatory tissues with this examination (Figs. 8.5 a, b).



Figures 8.5a,b. MR images with gadolinium enhancement showing extensive abscess formation involving the paraspinal muscles, epidural space and vertebral bodies following infection at an operation site

e) Needle Biopsy

The use of needles or small trephines inserted into vertebrae under X-ray or CT control represents one of the most significant advances in management of patients with neoplastic or inflammatory lesions. In parts of Asia, where infective lesions of bone are still common, the use of this method to obtain samples both for histological and bacteriological examination has proved the accuracy of diagnosis in many cases of non-tuberculous spinal infections which would have been classified previously as tuberculous (Chari, 1979).

f) Bed Rest and Chemotherapy

i) Conservative Treatment

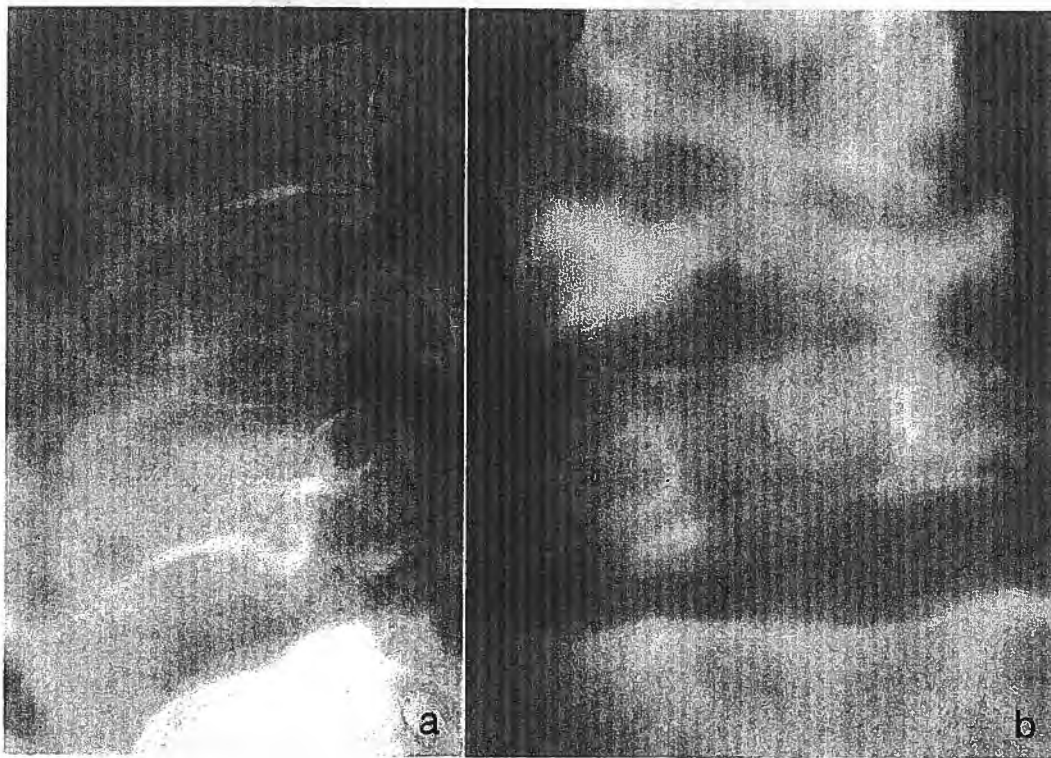
Many patients will respond satisfactorily to conservative treatment. Spontaneous spinal fusion often follows healing of lesions in staphylococcal osteomyelitis.

Problems arising in cases of osteomyelitis due to staphylococcal infections vary with the virulence and sensitivity of the particular organisms. The use of chemotherapy continuously for more than six months may be necessary in patients who have developed multiple bone lesions complicating septicemia (Figs. 8.6 a, b).

ii) Drainage of Abscesses

Emergency surgery is required for decompression of the spinal canal in cases developing tetraplegia or paraplegia due to the formation of epidural abscesses.

Occasionally drainage of psoas abscesses may be required, even in cases of non-tuberculous infections (Figs. 8.6a, b).



Figures 8.6a,b. **a** A lateral radiograph of the lower lumbar spine of a boy aged 14 years. Extensive destruction of the vertebral body of L4 is noted. This lesion developed in the spine twelve months after he had been treated for acute osteomyelitis affecting his upper tibia. **b** An antero-posterior tomogram. A large para-vertebral abscess required extra peritoneal drainage. Staphylococcus aureus organisms were cultured and found to be Penicillin sensitive

Surgical treatment of this type is recommended early in the management of vertebral osteomyelitis in drug addicts, because of the high resistance of organisms in these cases to chemotherapy alone (Hartman, 1978).

Even after extensive destruction of vertebral bodies due to staphylococcal infection, spontaneous spinal fusion usually occurs. Supplementary bone graft operations should not be required, providing sharp contrast with the requirements in the surgical management of Pott's disease.

8.2. Tuberculous Disease of the Spine

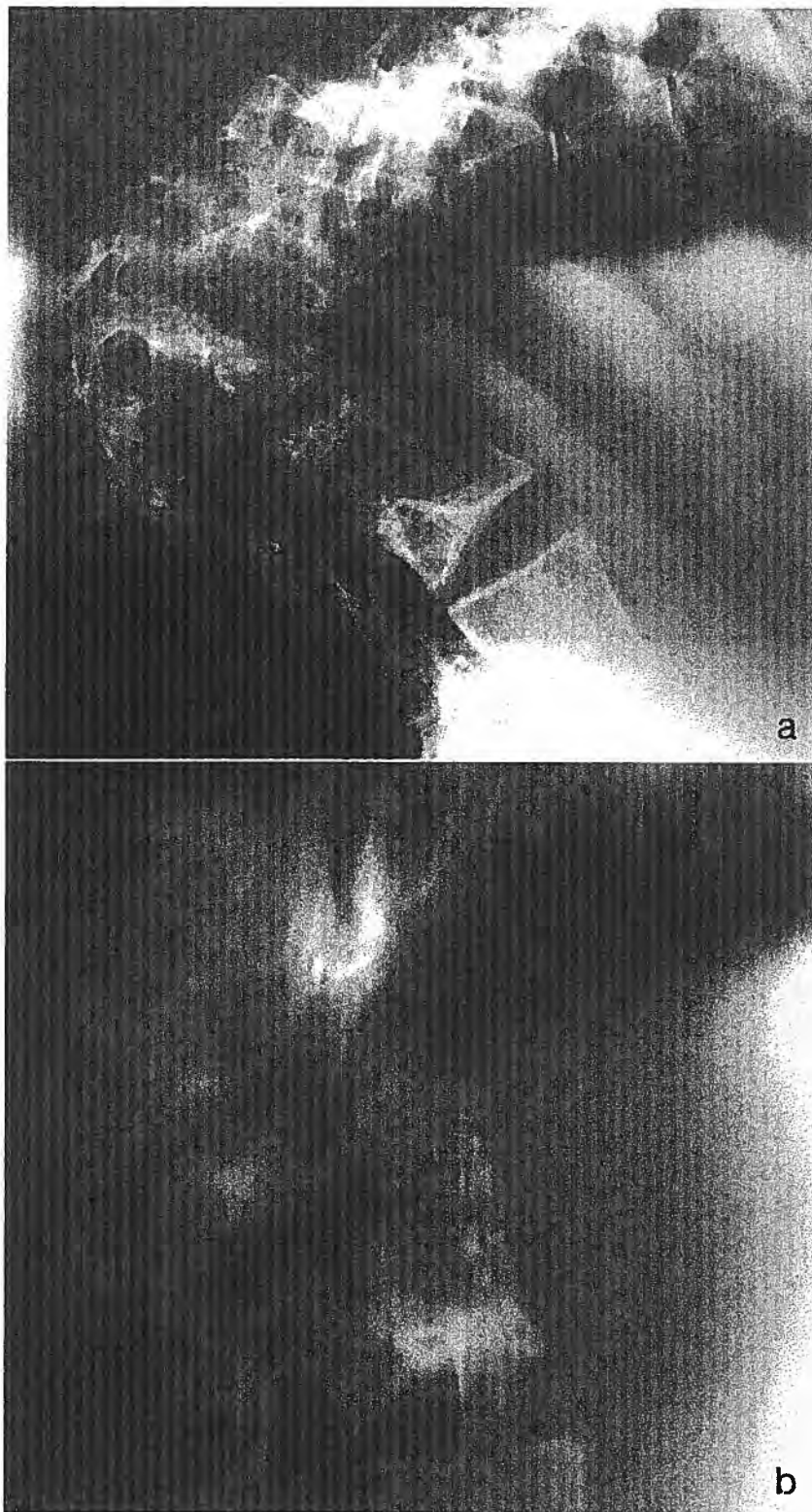
The surgical treatment of tuberculosis of the spine has attracted widespread interest in the past twenty years. During that time, the most authoritative accounts of the various surgical procedures which may be required in dealing with the spinal complications of this disease have come from the East, especially from Hong Kong (Hodgson, 1956).

Tuberculosis is now re-emerging in Western communities.

The illustrations in this chapter have been chosen simply to draw attention to some of the outstanding features of this disease as it affects the spine (Figs. 8.7-10).

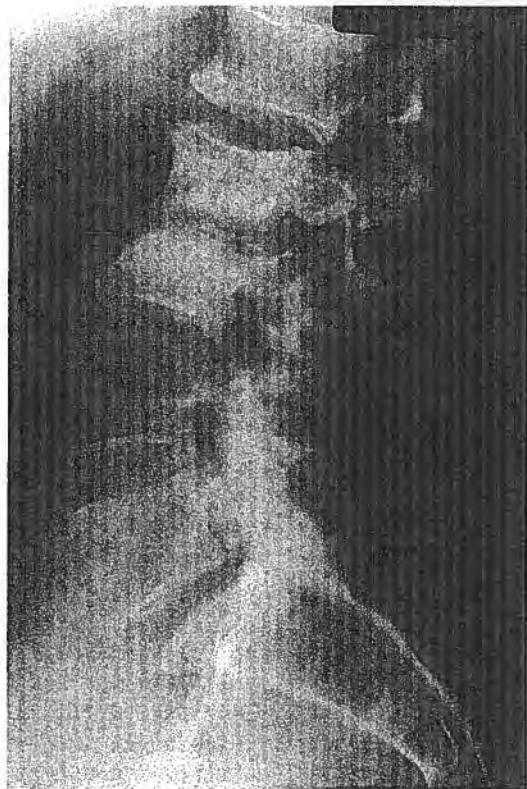

Figure 8.7. A lateral radiograph of the lumbar spine of a man aged 54 who presented with severe low back pain. Note the loss of disc space with erosive changes in the adjacent vertebral bodies at the level of the disc between L2 and L3. The body of L4 is somewhat osteoporotic. In the antero-posterior view the classic deformity of the psoas shadows indicated the presence of bilateral psoas abscesses. This is an example of relatively localized tuberculous disease with minimal spinal deformity at the time of presentation

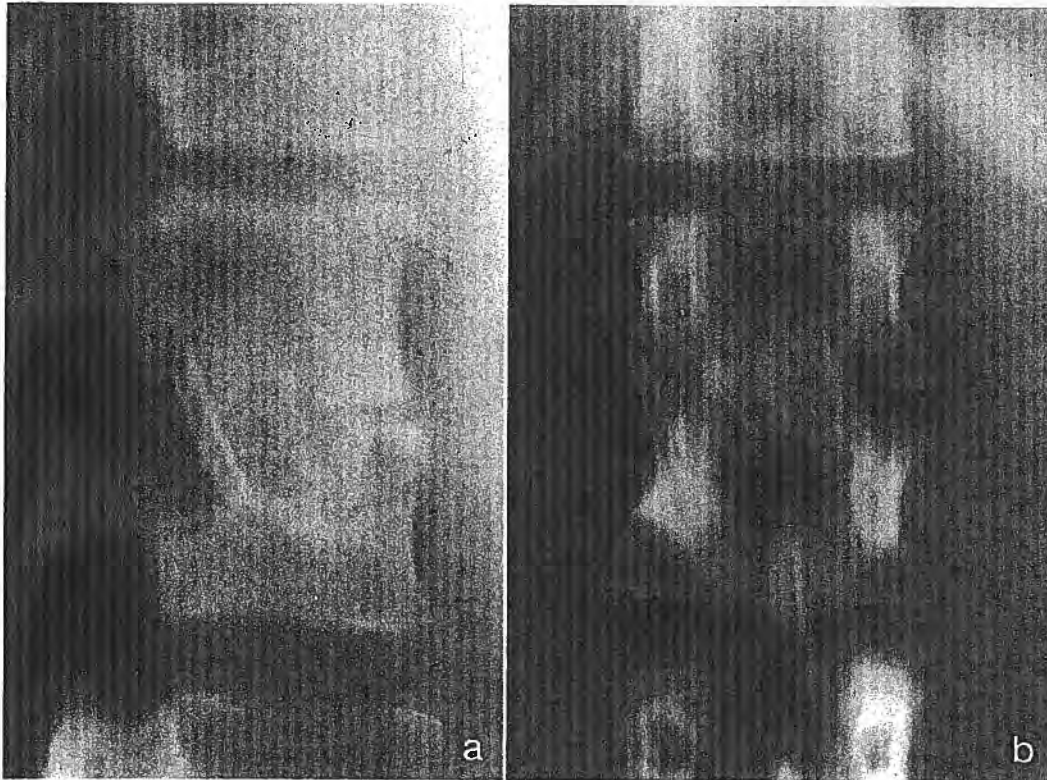


Figures 8.8a, b

Publication of these records may serve a useful purpose for those readers whose experience of this disease has been limited, reminding them of the magnitude of the problems which may occur in spinal tuberculosis.

Surgical treatment has been dominated by the use of interbody fusion operations, performed through anterior approaches at every level of the vertebral column, allowing debridement of carious debris and necrotic bone fragments before the insertion of strut grafts (Fig. 8.14).

Correction of kyphotic deformities of the spine due to Pott's disease has been undertaken with considerable success in a limited number of special centres in the world.



Figures 8.9a,b. **a** A lateral tomogram taken four months after operation showing the incorporation of grafts inserted for the treatment of tuberculous disease in the patient whose pre-operative films are illustrated in Figs. 8.3a,b. Note the fragment of rib graft adjacent to the spinal canal. **b** An antero-posterior tomogram of the same spine showing sound interbody fusion with no lateral deformity of the spine

Figures 8.8a,b. **a** A lateral radiograph of the thoraco-lumbar junction of the spine of a man aged 24 years who presented with complaints of spinal pain and increasing weakness of the lower extremities. **b** A lateral tomogram of the same area of this patient's spine following debridement and bone grafting of the bone of the area for active Pott's disease. No attempt was made to correct the deformity. The patient was managed post-operatively in a plaster bed and anti-tuberculous chemotherapy administered

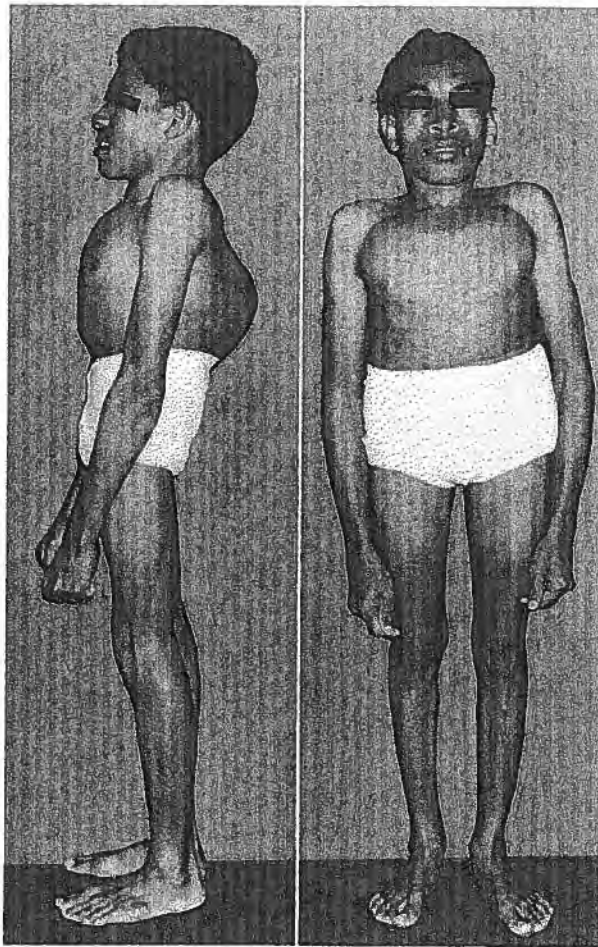
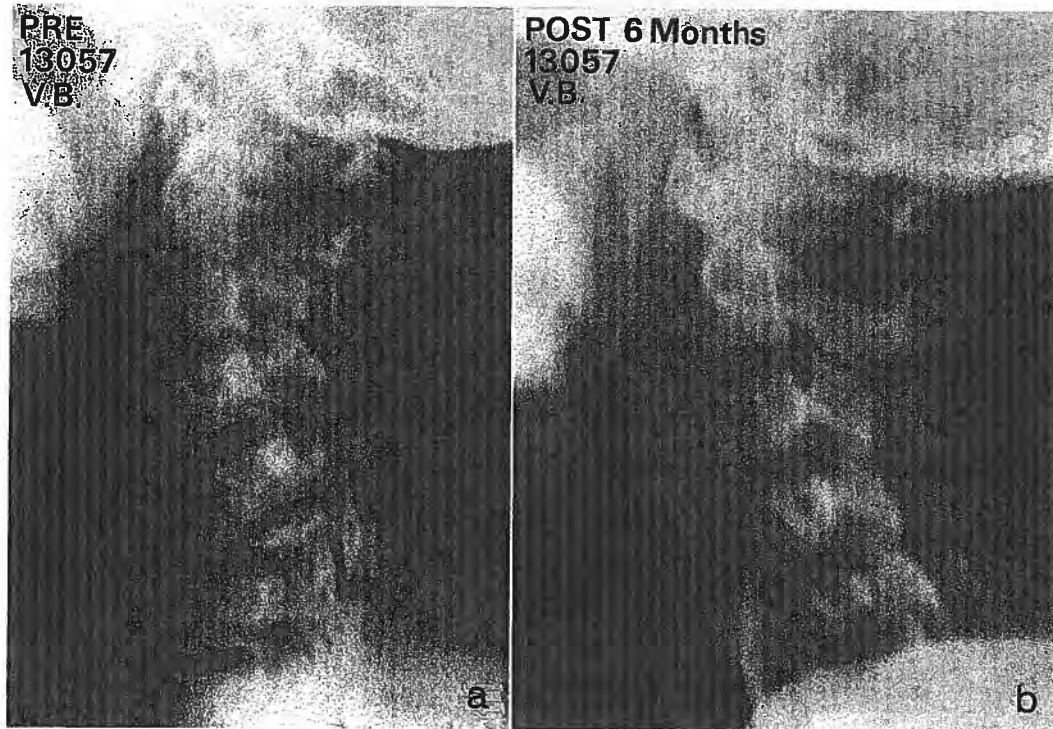


Figure 8.10. Lateral and anterior photographs showing the gross deformity of the spine resulting from Pott's disease at the thoraco-lumbar junction. The X-rays of this patient are shown in Figs. 8.8 a, b, 8.9a, b



Figures 8.11 a,b. **a** A lateral radiograph of the cervical spine showing gross vertebral destruction at C6 with subluxation of the spine complicating tuberculous infection. **b** A lateral radiograph of the same spine six months after operative treatment for debridement and anterior interbody fusion. Note the correction of the deformity and the presence of a unifying interbody fusion

A surgeon who has had no special experience in the management of post-infective kyphoses should avoid "trying his hand" on such cases. Should he be obliged to operate on a patient with a gross spinal kyphosis, with active tuberculous disease and clinical evidence of spinal cord dysfunction, he should treat the case by anterior decompression and anterior interbody fusion, making no attempt to correct the deformity. The patient should be nursed in a plaster bed for three months after surgery (Fig. 8.12).

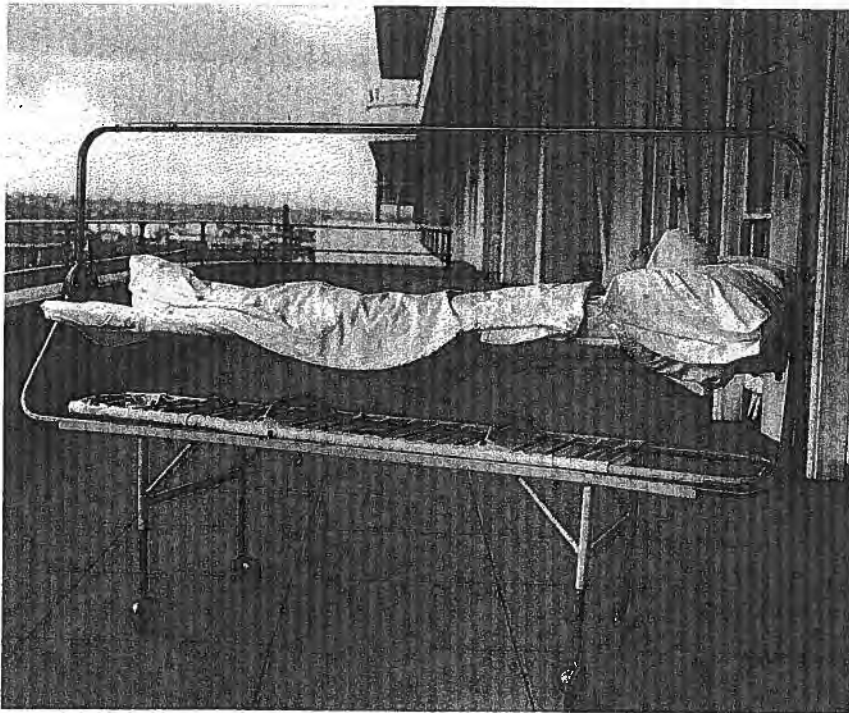


Figure 8.12. A photograph of a Stryker rotor bed suitable for nursing patients following spinal surgery for infective or neoplastic lesions

8.3. Post-Operative Infections

Some of the surgical aspects of the management of post-operative infections following spinal operations are discussed in Chapters 7 and 9.

Fortunately, serious infections are uncommon. Surgeons, therefore, have a natural tendency to hope that wound infections may subside with the use of chemotherapy alone. They may be reluctant to explore the wound early after the onset of infections.

Clinically, distinction should be drawn between superficial and deep wound infections. In patients with a thick layer of subcutaneous fat between skin and lumbo-dorsal fascia, fat necrosis and infections in the haematoma between the skin

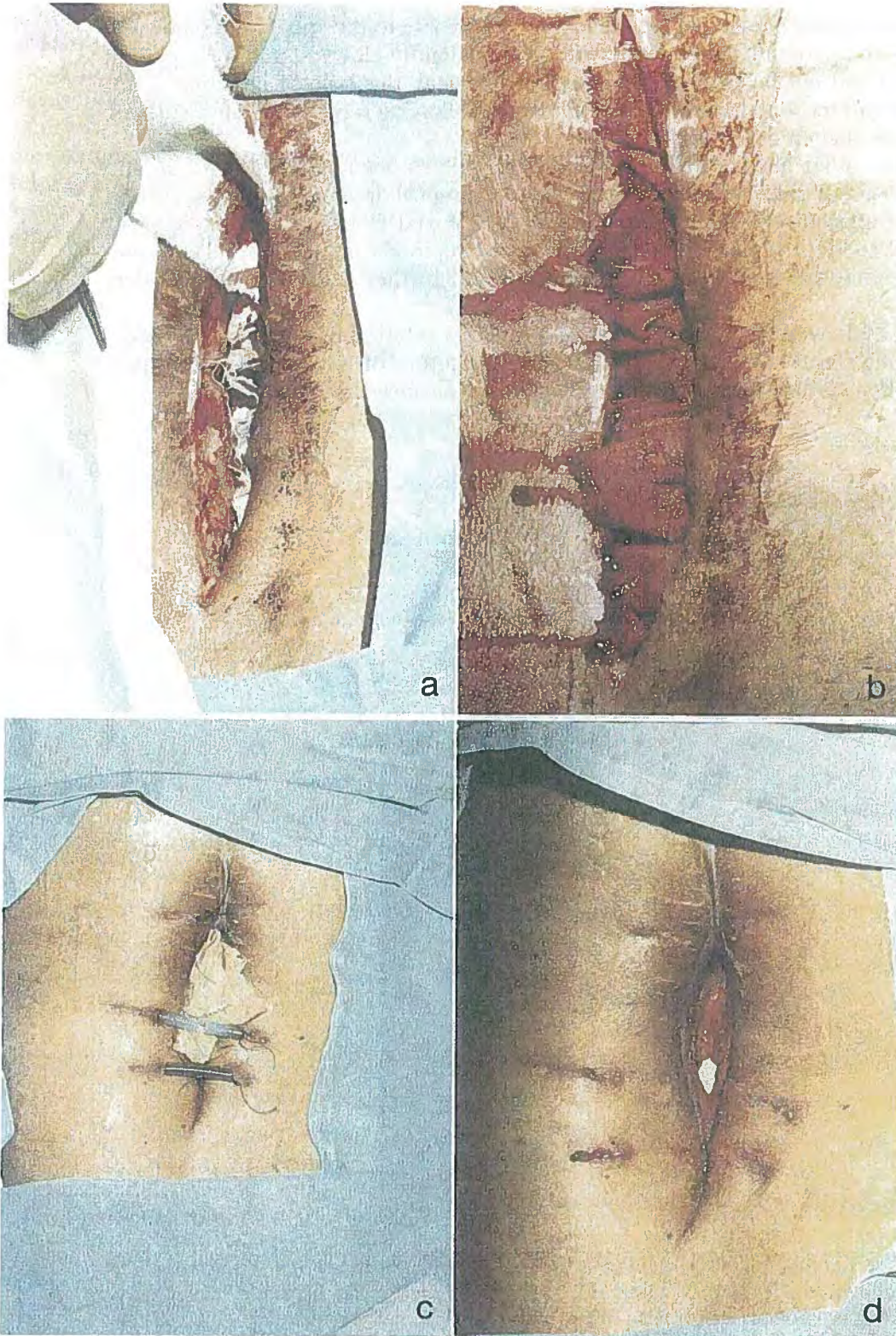
and the underlying paraspinal muscle layer will give rise to the appearance shown in Fig. 8.13. The patient's temperature will be only slightly elevated and local pain in the wound will not be severe. Although slow to heal, this type of infection is not serious. It will respond to limited local drainage, following removal of a few sutures, and the use of chemotherapy.

On the other hand, with deep infections, patients become febrile and ill, and they complain of extremely severe pain. Prompt surgical drainage should be carried out under anaesthesia. All sutures should be removed from the skin and deeper structures, so that the vertebral column can be re-explored. Infected blood clots and free pus should be aspirated, and material sent for further detailed bacteriological tests.

The whole wound should be washed out with a solution of hydrogen peroxide. Dry packing should then be inserted. Secondary suture of the wound can be performed when cultures from the granulating wound surfaces have become sterile.

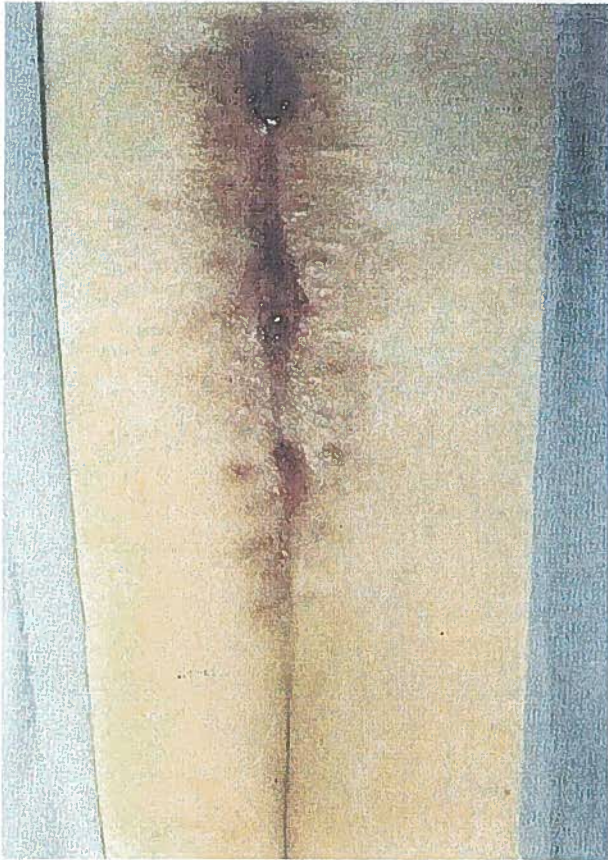

Figure 8.13. A photograph of the incision used for lumbar laminectomy in a young woman in whom the subcutaneous fat layer between skin and lumbo-dorsal fascia measured 9cms. Serous fluid containing fat droplets leaked from the wound. The incision was re-opened in the mid-line but extensive dissection was not necessary, the problem being confined to the subcutaneous layers of tissue superficial to the lumbo-dorsal fascia, as is usual in this type of wound infection



Figures 8.14a-d

If deep infections, either in the neck or elsewhere in the spine, are treated promptly in this way, the dreaded complications of vertebral osteomyelitis, epidural abscess formation, or even meningitis should not develop (Figs. 8.14 a-d).

Patients who present with persistent severe spinal pain (with or without small discharging sinuses) some months after treatment for post-operative wound infections, will require very careful re-assessment. In this group, chronic osteomyelitis and chronic spinal epidural abscesses may be discovered resulting in crippling and prolonged illness (Fig. 8.15).

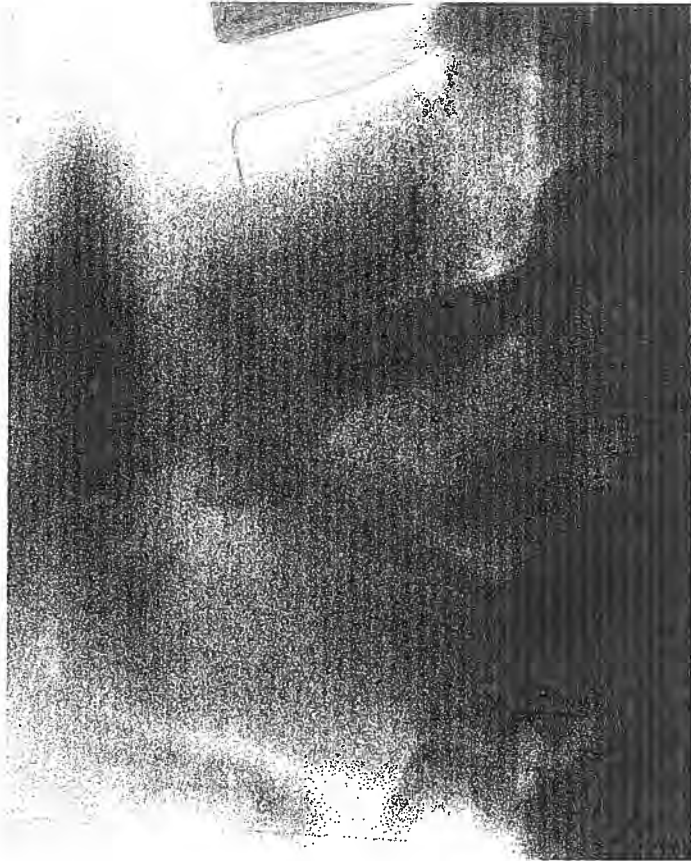

Figure 8.15. A lateral tomogram of the mid-lumbar spine of a woman aged 58 years. Note the gross destruction of two adjacent vertebral bodies and the resultant marked kyphotic deformity. This patient developed an epidural abscess and vertebral osteomyelitis following infection of a laminectomy wound

Figures 8.14a-d. Photographs illustrating progressive stages in the management of chronic osteomyelitis of the spine following posterior bone grafting for spondylolisthesis 15 years earlier. This patient had had a discharging sinus in his back with intractable back pain for many years. **a** The problem was treated by radical excision of the graft and packing of the cavity with calico. **b** The appearance of the wound three days after the operation for graft excision. **c** The appearance of the wound at the time of secondary suture when cultures from the granulating surfaces were sterile. **d** The appearance of the wound following removal of the tension sutures after secondary suture. Note the dural tissue in the base of the wound. The wound healed completely and epithelialized four weeks after this photograph was taken. The patient was treated with appropriate chemotherapeutic agents for more than one year

9

The Management of Failed Spinal Operations

9.1. Introduction

Waddell *et al.* (1980), painted a gloomy picture of the outcome for patients who have had multiple back operations. Little wonder that patients with persisting serious spinal problems are often given dire warnings about further operations, not only from non-medical sources but even from some specialist surgeons. There are certainly daunting problems in their management. These patients are often debilitated and demoralized. Family breakdown, financial stress, drug dependency and frank persecution by insurers, examining doctors and employers constitute some of their difficulties – leaving aside the question of the actual physical causes of their persisting disability.

This is one of the most challenging fields of spinal surgery and there is no place in it for a surgeon who is sceptical or suspicious of his patient or whose attitudes are in any way defeatist.

9.2. Investigation

The cornerstone of management is to investigate these problems with great care and with compassion, before recommending further surgery. The surgeon must establish a good working relationship with the patient's general practitioner and physical therapist and call upon the expertise of other specialists with declared interests in this type of work when indicated.

Before outlining a simple system for the analysis of failures after spinal operations, some general comments should be made on the subject of investigations.

Clinical neurological examination may be unrewarding in assessing the level or severity of nerve root or cauda equina lesions in patients who have had previous spinal surgery. This is especially true in those who have had multiple operations.

Radiological examinations which may be essential in helping to establish diagnoses and to plan further surgery in particular cases include:

- a) Motion studies of the spine. Instability may require spinal fusion.
- b) Oblique views of the facet joints and intervertebral foramina. Unrecognized foraminal stenosis may require decompression.
- c) Antero-posterior and lateral tomograms in any case of failure following spinal fusion or canal exploration. Irregular laminal remnants or re-formed bone in scar tissue may require revision of canal decompression.
- d) Repeat myelography to demonstrate space-occupying lesions or arachnoiditis.
- e) Discography to plan the extent of spinal fusion.
- f) Computerized tomography, especially if reconstructed scans in three planes can be obtained. Offers a wide range of diagnostic information but does not necessarily supersede the use of a-e.
- g) MRI, especially with gadolinium enhancement, is probably the best investigation for demonstrating unrecognized disc lesions, epidural scarring or chronic inflammatory disorders.

The analysis of individual cases of failed spinal operations may be facilitated by using the following classification:

1. **Outright Failure**
This group comprises patients who show no improvement or who become worse after the first operation.
2. **Temporary Relief**
These patients may be free of symptoms for months or years after operation.
3. **Failures in Spondylolisthesis**
These patients are considered separately because of special features of the pathological anatomy in this condition (see Chapter 5 and p. 305).
4. **Infection**

9.3. *Outright Failure*

Failure is usually related to wrong diagnosis. Some pain and discomfort are to be expected after any spinal operation. Pain protracted over weeks may follow some operations in which adherent root sleeves have been tediously separated from disc tissue, yet a successful outcome can be predicted. Such special circumstances excluded, patients in this group can usually be identified soon after operation. They complain of pain which is more severe than is normally expected. Those with infections will have elevated temperatures and altered blood counts.

The questions to be determined are simply these:

- Is the failure due to an unrecognized condition?
- Is it due to wrong diagnosis of the spinal lesion?
- Or finally, has it followed some technical failure?

a) Unrecognized Conditions

Investigations should begin as soon as possible, but several months may elapse before the correct diagnosis can be established. For example, a carcinoma involving the apex of the lung may be the cause of neck pain and brachial neuralgia persisting after anterior cervical fusion. Operation for lumbar spondylolisthesis may fail because the true cause of pain is a secondary prostatic carcinoma of the vertebra.

Rarely, infection after a spinal operation may be caused by tuberculosis or gonorrhoea.

Primary tumours in the spinal canal are relatively rare. They are usually diagnosed before operation by clinical examination and by myelography. However, in cases of failure, the possibility that such lesions may be the cause of continuing symptoms should be considered. Even MRI may fail to define some lesions such as intradural neurilemmomas unless gadolinium enhancement is used.

b) Error in Diagnosis of the Spinal Condition

Three questions must be answered:

1. What was the primary diagnosis?
2. What were the operative findings?
3. What was the nature of the operation?

Stenoses of the spinal canal or of a nerve root canal must be excluded as underlying causes of failure. The possibility that the symptoms are those of "claudication" of the cauda equina must be borne in mind. Under such circumstances, myelography with CT or MRI should be used to help clarify the diagnosis.

c) Technical Errors

i) In Operations for Disc Prolapse

Persistence of severe pain after operation is unusual if the diagnosis of disc prolapse has been confirmed at the time of surgery. If a considerable amount of fragmented and desiccated disc material has been removed, it is likely that a further fragment has been displaced beneath the root sleeve after operation, or that a migrating sequestered fragment has not been removed.

If a pre-operative diagnosis of disc prolapse was made but no disc prolapse was found at operation, it is likely that the intervertebral space at the wrong level has been explored (Fig. 9.1). Removal of a disc prolapse or of sequestered disc fragments occurring at the site of isolated disc resorption usually leads to failure unless bilateral foraminal and nerve root canal decompressions are performed at the same time. More commonly this diagnosis is simply overlooked and operation is performed at an adjacent level on the basis of a minor disc "bulge" seen on a myelogram (Figs. 9.2, 1.2).

Most failures in this group occur when no disc prolapse has been found at operation yet one or two discs have been incised in the attempt to locate a "prolapse". These patients are often subjected to further myelography even on two or three occasions and subsequently have further unsuccessful explorations of their spinal canals (Fig. 9.3 a-c).

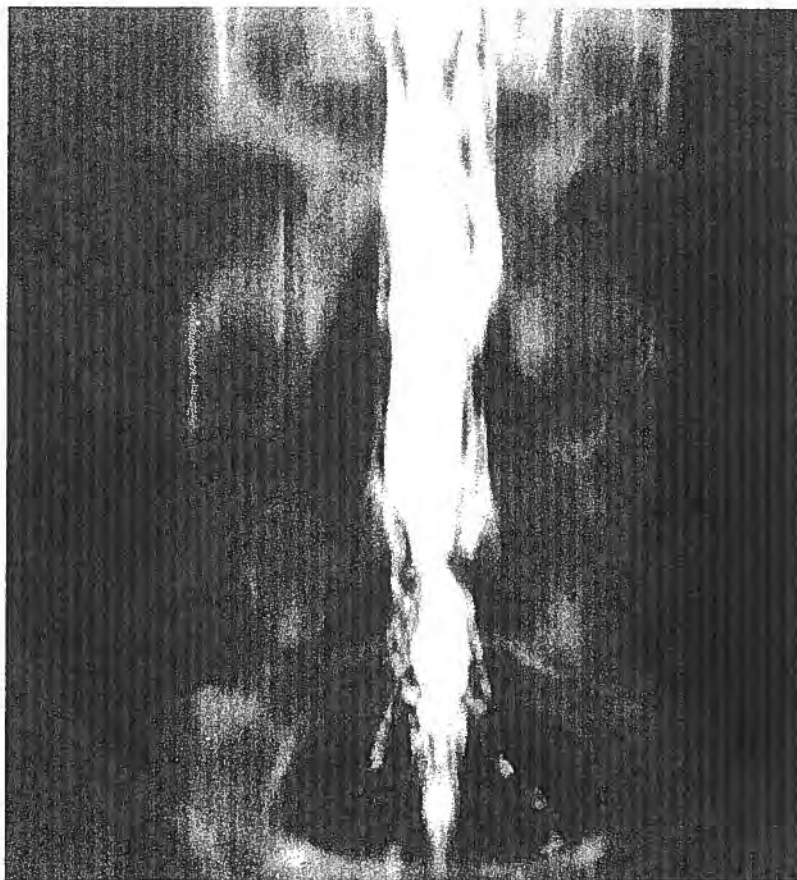

Figure 9.1. An antero-posterior tomograph of the lower lumbar spine in a patient aged 37 years, said to have undergone laminectomy for removal of a left-sided lumbo-sacral disc prolapse. Part of the upper margin of the lamina of the 4th lumbar vertebra has been removed, so that the space between the 3rd and 4th vertebrae was probably explored. The outline of the myodil shows that there is bilateral stenosis of root canals at the L4/5 level. This patient's symptoms were relieved by further decompression of the spinal canal, involving removal of the central segment of the arch of the 4th lumbar lamina, combined with bilateral nerve root canal decompression at that level

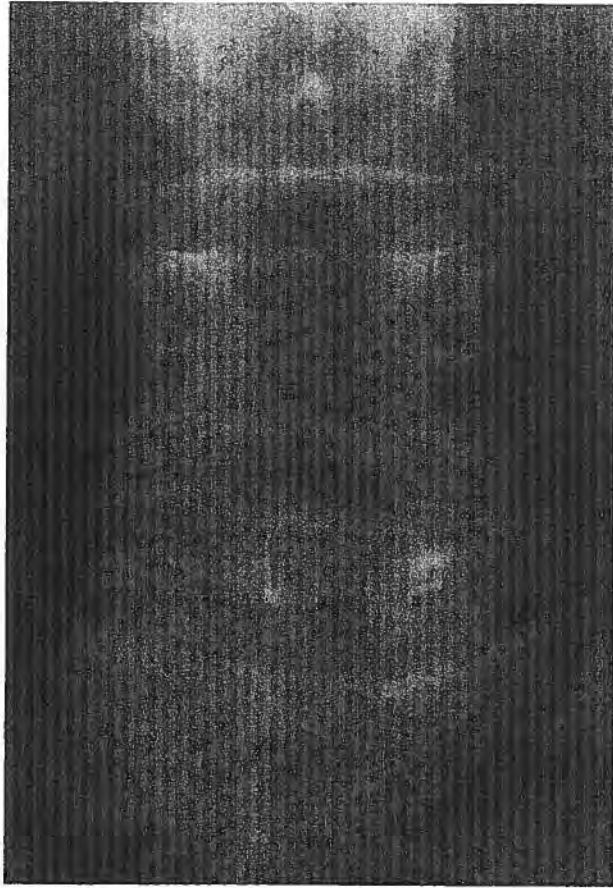
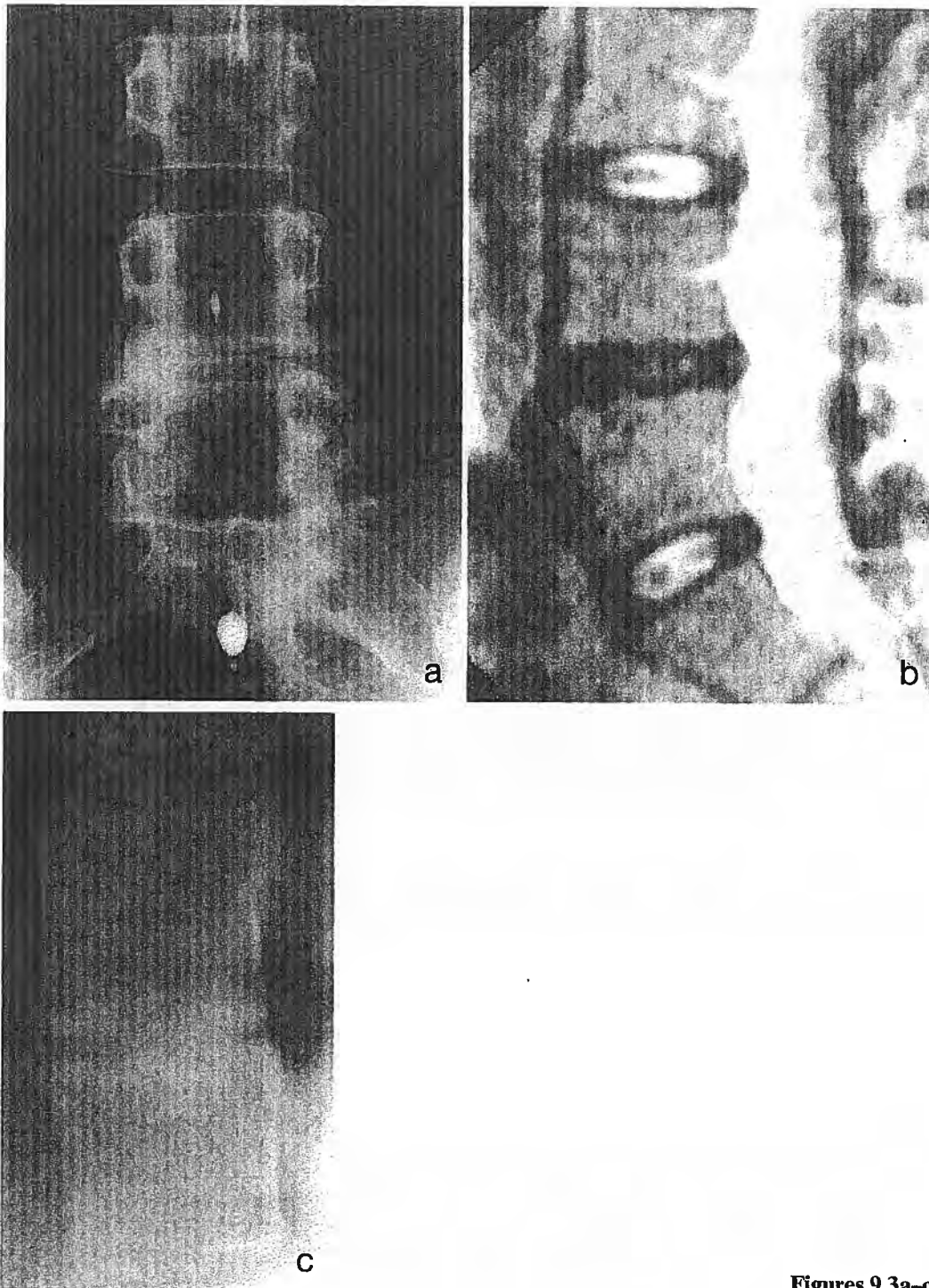


Figure 9.2. An antero-posterior radiograph of the lumbar spine of an 82 year old man showing the extent of decompression of the lumbar spinal canal at the L4/5 level where no disc prolapse was found. The lesion was at L5/S1 in the form of a well-established isolated disc resorption which responded very satisfactorily to bilateral foraminal and nerve root canal decompressions subsequently (see Fig. 1.2 which shows a lateral radiograph of this patient's spine)



Figures 9.3a-c

ii) In Operations for Internal Disc Disruption

If this diagnosis has been established by discography and disc excision and interbody fusion has been done, early failure may indicate that the wrong level has been fused. In the neck particularly, levels should always be identified by radiographs taken during operation. The injection of methylene blue at the time of discography is an unreliable method of identifying the level of an affected disc. Even in the lumbar spine, levels may be wrongly identified, especially if there are segmentation anomalies.

9.4. Temporary Relief

In this group initial relief of pain after operation may last for weeks or months before the recurrence of disabling pain. The largest number of cases fall into this category.

a) Failure After Operation for Disc Prolapse

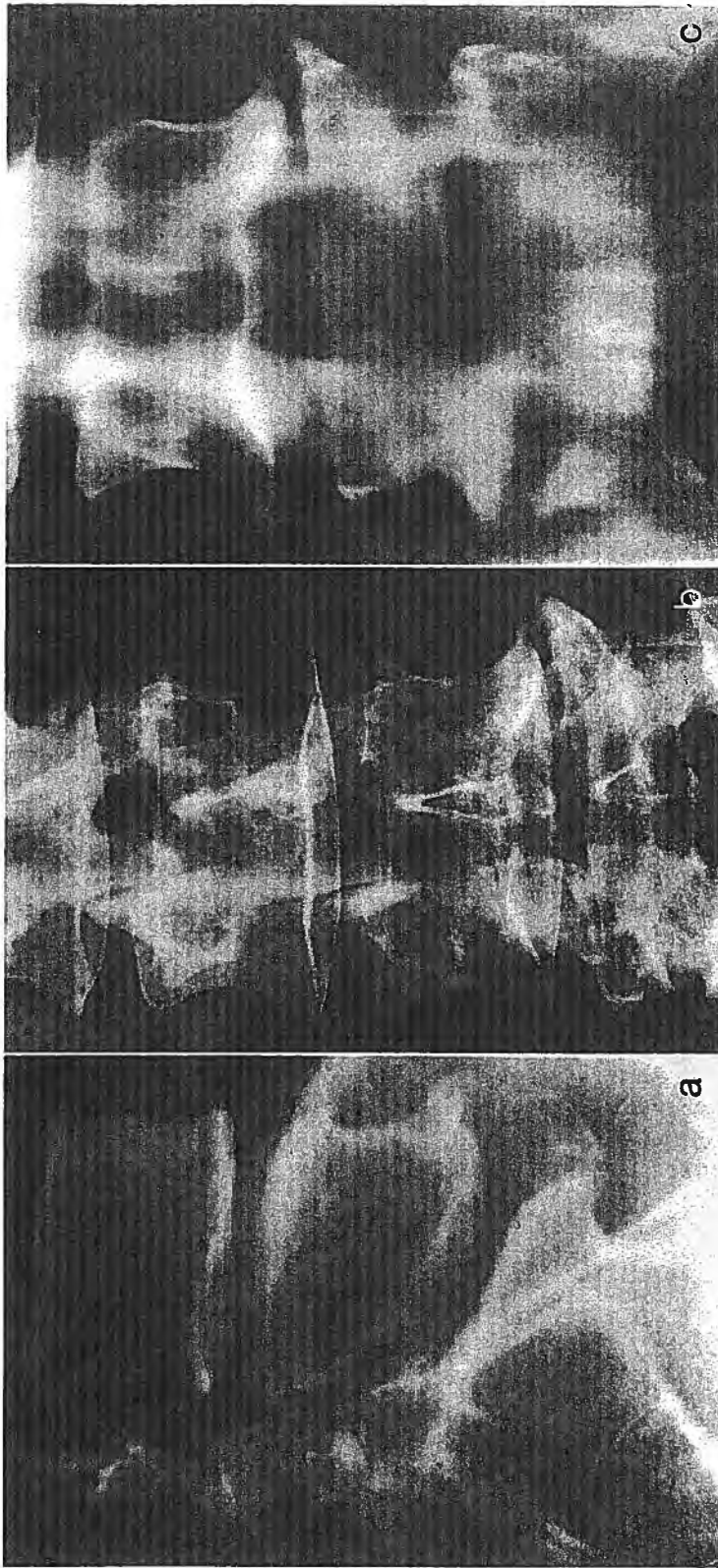
Recurrence of pain is usually caused by further prolapse at the level operated on, especially if a large volume of disc material was removed at the original operation, or by a fresh prolapse at another level.

Recurrent but contra-lateral sciatica occurs after asymmetrical settling of the vertebrae when several grams of disc material have been removed at the initial operation. Radiographs show collapse of one side of the intervertebral space. Recurrence of pain is caused by a fresh prolapse of disc material or by stenosis of the nerve root canal following its deformation due to the reduction in height of the intervertebral disc space.

The commonest cause of late recurrence of symptoms after initial successful excision of a disc prolapse is stenosis of the spinal and nerve root canals, secondary to degenerative changes (Figs. 9.4 a-c). Ectopic ossification or calcification in the remnants of ligamentum flavum may be found at the site of re-exploration in such cases.

Another cause of late recurrence, often associated with secondary canal stenosis but contributing to the overall problem, is the presence of a meningocele caused by damage to the dural sac at the time of the original operation.

Figures 9.3a-c. **a** An antero-posterior radiograph of the lumbar spine of a 27 year old female who had had two previous lumbar laminectomies involving excision of the L4 and L5 laminae and spinous processes. She presented with intractable pain and hysterical paraparesis. **b** A lateral sagittal MR image, T2 weighed sequence of this patient's spine showing isolated disc resorption at L4/5. **c** A post-operative tomogram showing sound interbody fusions at L4/5 in this patient's spine. Her gait returned to normal and she made a complete recovery




Figures 9.4 a-c. Degenerative changes 30 years after removal of an intervertebral disc prolapse at L4/5 level in a patient aged 61 years. Note the inter-laminar calcification in the antero-posterior view in **b**, **c**. A tomogram showing the extent of the decompression of the spinal canal and nerve root canals

b) Failure After Operation for Internal Disc Disruption

If interbody fusion has been performed for this lesion, early recurrence of severe symptoms within two or three months of operation may be due either to complications of the discography or to trouble arising at the site of grafting.

Severe pain occurring within six weeks of operation may be due to discitis in adjacent un-operated discs in which discograms had been performed. Erosion of the vertebral end-plates and bodies in the area of the nucleus pulposus occurs on either side of the disc, leading to gross narrowing of the intervertebral space at the level of the normal disc above or below the "fused disc". Histological examination of specimens removed at operation shows inflammatory changes with plasma cell infiltration. Cultures are sterile (see Chapter 2, Figs. 2.23, 2.48).

Non-union of grafts occurs in a few instances. These problems are discussed in detail on pp. 93, 96. The incidence of non-union of interbody grafts has been reduced in recent years following improvements in surgical technique reported by Crock (1976), by Crock (1982) and by Fujimaki, Crock and Bedbrook (1982). Grafts of cancellous bone were shown to have two disadvantages. They are prone to infiltration by disc remnants with subsequent non-union and graft resorption; secondly, even though union occurs, loss of intervertebral height may follow collapse of the cancellous graft and its settling into the vertebral bodies. Stenosis of the nerve root canal follows and may cause recurrence of pain in both lower limbs (Figs. 9.5 a, b).



Figures 9.5a, b. Lateral tomographs of the lumbo-sacral junction in a man aged 46 years. (A) is taken four months after operation, (B) is taken 18 months after operation. The graft has incorporated but secondary disc space collapse has occurred with resultant nerve root canal and intervertebral foraminal stenosis. The diagrams (A) and (B) alongside depict the evolution of the foraminal stenosis

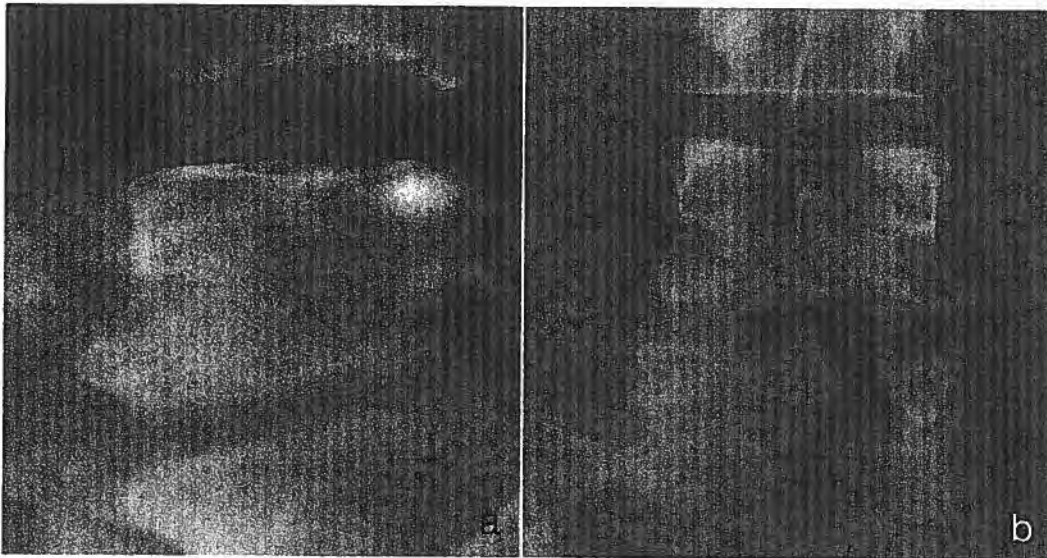
300 The Management of Failed Spinal Operations

Block or dowel grafts cut from the anterior half of the iliac crest provide grafts which are rapidly revascularized, usually maintain height and always resist infiltration by disc remnants (see Chapter 2, Figs. 2.26, 4-8).

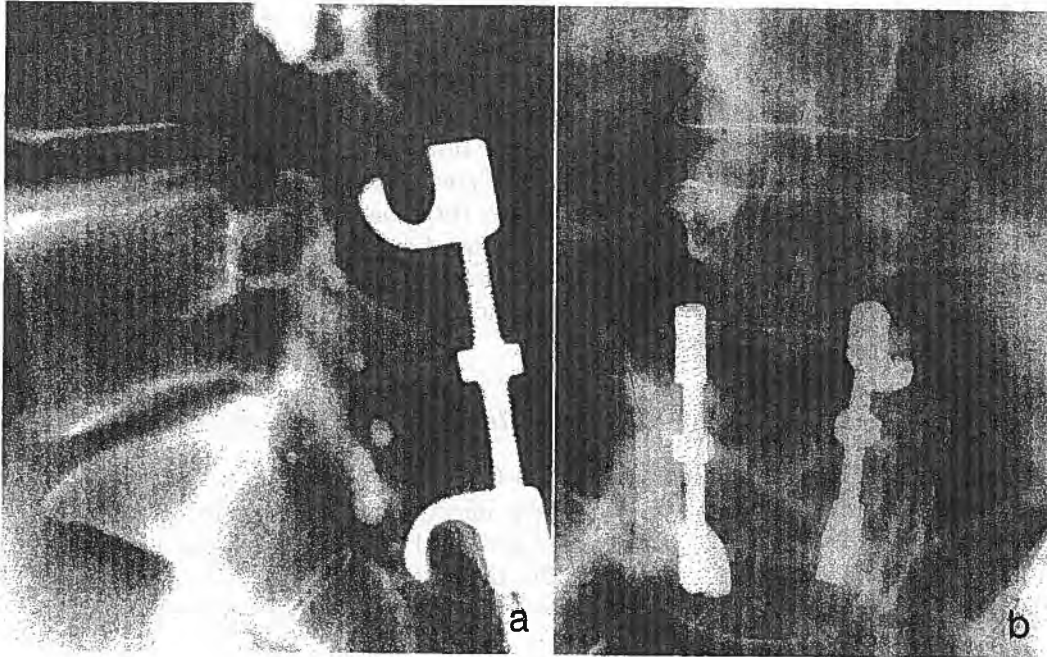
Following successful interbody fusions, the ligamentum flavum related to the fused segment will atrophy, adhering then to the dura and nerve root sleeves. With vertebral column movements above the fused segment, stretching of the dural root sleeves may occur and cause pain. Relief follows total laminectomy and excision of the ligamentum flavum over the area of the fused spinal segment or segments, leaving intact the facet joints between the fused and mobile segments of the column. In the cervical spine, the relevant root canals should also be decompressed, using a very fine forward-angled rongeur.

c) Failure After Operation for Isolated Disc Resorption

This condition has been discussed in detail in Chapter 1. Acquired disc resorption may follow partial disc excision or intradiscal injections of chymopapain. In such cases symptoms usually recur or persist after a second exploration of the disc space with hemi-laminectomy and removal of more disc material (Figs. 9.6 a,b). The appropriate surgical treatment of bilateral nerve root canal decompression is discussed



Figures 9.6 a,b. **a** A lateral radiograph of the lower lumbar spine of a woman aged 37 years with persistent pain in the back and lower limbs. Note the narrowing of the lumbo-sacral intervertebral disc space, with minimal osteophyte formation and marked sclerosis of the adjacent vertebral body. **b** The antero-posterior radiograph shows the amount of residual lamina bone after two previous operations. This patient's problem was due to acquired disc space narrowing following intervertebral disc surgery, with resultant bilateral nerve root canal stenosis. The second operation had been inadequate, the remnants of the central portion of the 5th lumbar lamina should have been removed, and bilateral nerve root canal decompression performed as described in Chapter 1, pp 30-35, 127-138



Figures 9.7a,b. **a** A lateral radiograph of the lower lumbar spine. Isolated disc resorption is noted at the lumbo-sacral junction with a degree of retrolisthesis of L5 on S1 and a positive Knott's sign. The L4/5 disc space is normal. Knott's rods have been inserted beneath the lamina of L4 above and into the sacrum below. **b** An antero-posterior radiograph of the same spine. Note the bilateral Knott rods and the segments of graft, some of which extend upwards to lie against the left side of the spinous process of L3. The pathology in this case was present only at the L5/S1 level. In this patient, two other normal spinal segments have been operated upon unnecessarily. Supplementary treatment in this case involved removal of the Knott rods, excision of the unwanted bone at L3/4 and L4/5, and bilateral nerve root canal decompression at L5/S1 level

in detail on pp. 30, 127–138. If the true significance of the pathology of isolated disc resorption is not appreciated, the patient may be subjected to further major surgery, involving adjacent normal segments of the spine (Figs. 9.7a and 1.2).

9.5. *Surgical Techniques for Re-Exploring the Spinal Canal*

a) Preparation

These procedures are often time-consuming and may be associated with considerable blood loss. Blood transfusion facilities must be available. Adequate supplies of bone wax, gelfoam or equivalent haemostatic agents should be ready for use.

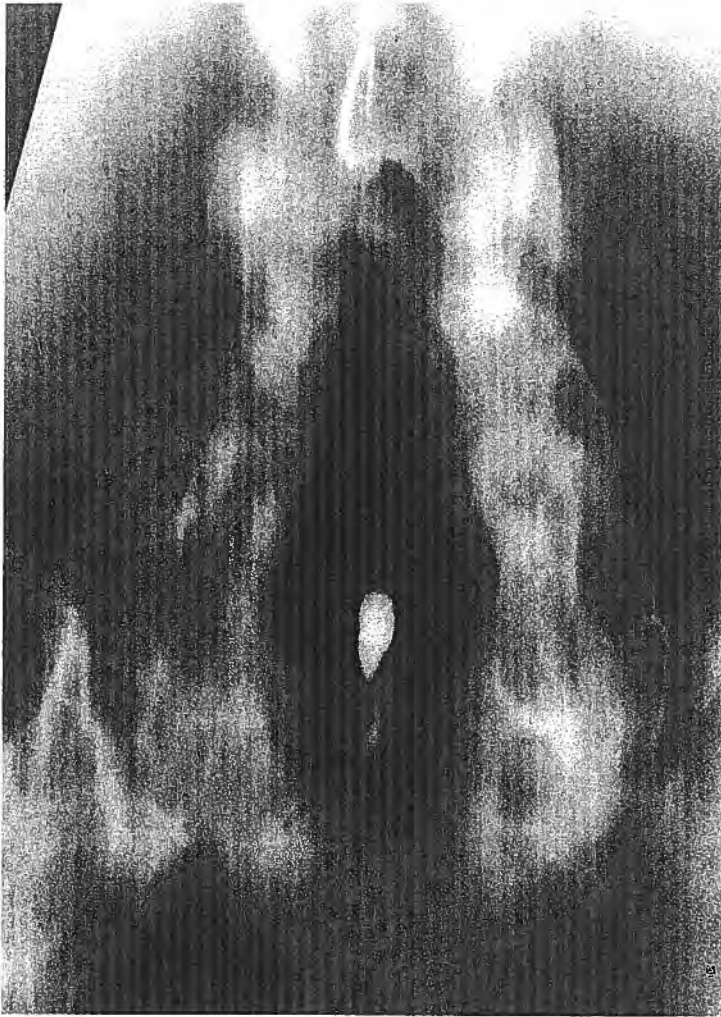

Figure 9.8. An antero-posterior tomogram of the lower lumbar spine of a man aged 52 years who complained of recurrent back and leg pain following two previous spinal operations, including spinal canal decompression and postero-lateral inter-transverse-alar fusion. Note the reformation of the laminal remnant near the top of the picture on the right side at the upper extremity of the previous exploration

b) Radiology

Radiographs of the patient's spine should be displayed on a viewing box in the theatre. The most valuable information for the operation of re-exploring the spinal canal is usually provided in antero-posterior views, including tomograms which show the anatomy of the roof of the spinal canal or its remnants most clearly (Fig. 9.8).

c) Positioning

Positioning on the operating table is important and use of the prone position on a suitable frame is recommended.

d) Instruments

Opening of the dural sac may be indicated if arachnoiditis of the cauda equina is recognized during operation. Dural tears may occur accidentally in the course of dissection, especially at the junction of previously operated and non-operated areas. If the dural sac and nerve root sheaths are tethered to the floor of the spinal canal by dense adhesions, it may be necessary to open the dural sac to gain access for removal of prolapsed disc fragments. On rare occasions meningocoeles may be encountered unexpectedly. An adequate array of instruments, including a fine sucker, long handled fine toothed forceps, long handled fine needle holder and long fine "atraumatic sutures" on fine needles (4.0 or 6.0 sizes) should therefore be readily available so that any of these problems may be dealt with promptly during the operation.

Dense laminal bone is likely to be encountered in some cases. A high-speed drill with diamond-tipped burr should be available for use. Debris dispersed in a fine spray from the tip of the drill may be the source of spread of the HIV virus. *Theatre staff should nowadays wear suitable protective masks for the face and eyes to avoid contamination.*

e) Exposure

A mid-line incision should be used. Bony landmarks at the extremities of the incision should be palpated with the aim of exposing intact spinous processes and laminae above and below the area to be re-explored.

f) Orientation

When the incision has been made over the desired length of the spine, the soft tissues are separated from the sides of the intact spinous processes at each end of the wound. The paraspinal muscles should be separated carefully from the lateral aspects of the spinous processes and the posterior surfaces of the laminae, leaving the periosteum intact and avoiding any disturbance of the capsules of the facet joints. At the upper end of the incision the intact lamina and its inferior facets should be clearly defined, as should the posterior surface of the sacrum below, to the level of its superior laminal edge. Self-retaining retractors should then be inserted before any effort is made to expose the actual area to be re-explored.

The surgeon must re-assess the patient's X-rays at this stage, to be certain of the location of laminal remnants in the dense scar tissue which has usually formed between the paraspinal muscles and the roof of the spinal canal following previous surgery.

Using a sharp scalpel, an oblique incision is made into this scar tissue, starting in the mid-line at the upper extremity of the wound on one side, the direction and depth of the cut being gauged by the orientation of the cleared lamina and its

inferior facet joint, laterally and inferiorly to the level of the next joint. The extent of muscle damage resulting from the previous surgical procedure or procedures will be variable. Where it has been slight, there will be a clearly defined fatty layer between the anterior surface of the paraspinal muscles and the bony canal. Through this soft tissue the surgeon can easily palpate the facet joint with the tip of his/her index finger, thereby determining the plane of dissection. In cases where very dense scar tissue has invaded the paraspinal muscles at the site to be re-explored – a likely finding after multiple explorations – identification of the lateral edge of the pars interarticularis of the lamina and its inferior facet joint is difficult. The site of the pars interarticularis below the normal facet joint at the upper end of the incision can be identified either by removing the extra-synovial fat pad from this facet joint or by locating the main stem of the posterior branch of the lumbar artery which is a constant lateral relation of the pars interarticularis. Using either or both of these guidelines, one can determine the direction of the incision which will lead safely to the exposure of the outer edge of the lamina and its related facet joint. Depending on the findings in particular cases, one may proceed to expose the entire area to be re-explored on one side between the sacrum below and the normal spinous process and lamina above, then repeat the procedure on the opposite side. Where there have been multiple previous operations, it is often wiser to make limited exposures, one level at a time, on the right and left sides alternately, moving the self-retaining retractors progressively as required.

If a meningocele is present, it will be identified early. Cerebrospinal fluid will fill the wound when the scalpel is used to cut obliquely into the scarred tissue after preliminary exposure of the normal bony segments of the canal, as described above. The inexperienced surgeon will be shaken by the appearance of C.S.F. so early in the operation. The meningocele should be identified as such and thereafter ignored until the formal exposure of the roof of the spinal canal or its remnants has been completed.

Once the lateral bony margins of the laminae and the facet joints have been exposed on both sides, the self-retaining retractors are positioned definitively.

g) Timing of Retractor Application

The time of their application should be noted because re-exploration operations may last more than two hours. The retractors should be removed at intervals of 45-60 minutes for 5 minutes, to restore circulation in the paraspinal muscles. During these rest periods the wound may be irrigated with Ringer's solution.

At this stage of the procedure, a bulky mass of scar tissue of variable depth remains in the mid-line between the lumbar spinous process above and the back of the sacrum below. Its relationship to the underlying dura will vary depending on the amount of laminal bone remaining or reformed after the previous operation or operations. The surgeon should now strip all soft tissues from the outer surface of each lamina or laminal remnants, referring once again to the patient's X-rays. Identification of laminal levels can be very difficult, particularly in cases with anomalies at the lumbo-sacral junction or in spondylolisthesis with the higher grades of slip of the vertebral body (Figs. 9.9, 9.10) so that it may be necessary to take control X-rays in the operating theatre in such cases. This done, the bulky mid-line scar tissue can be excised or thinned down to the level of the bony canal, at each level between

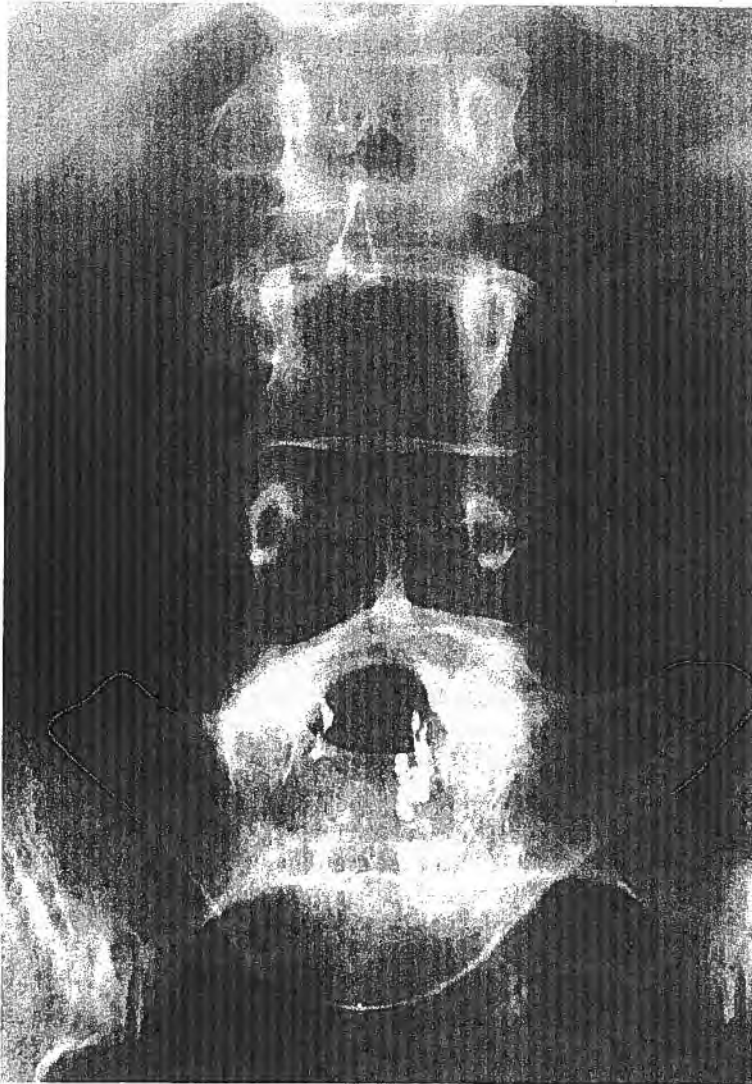
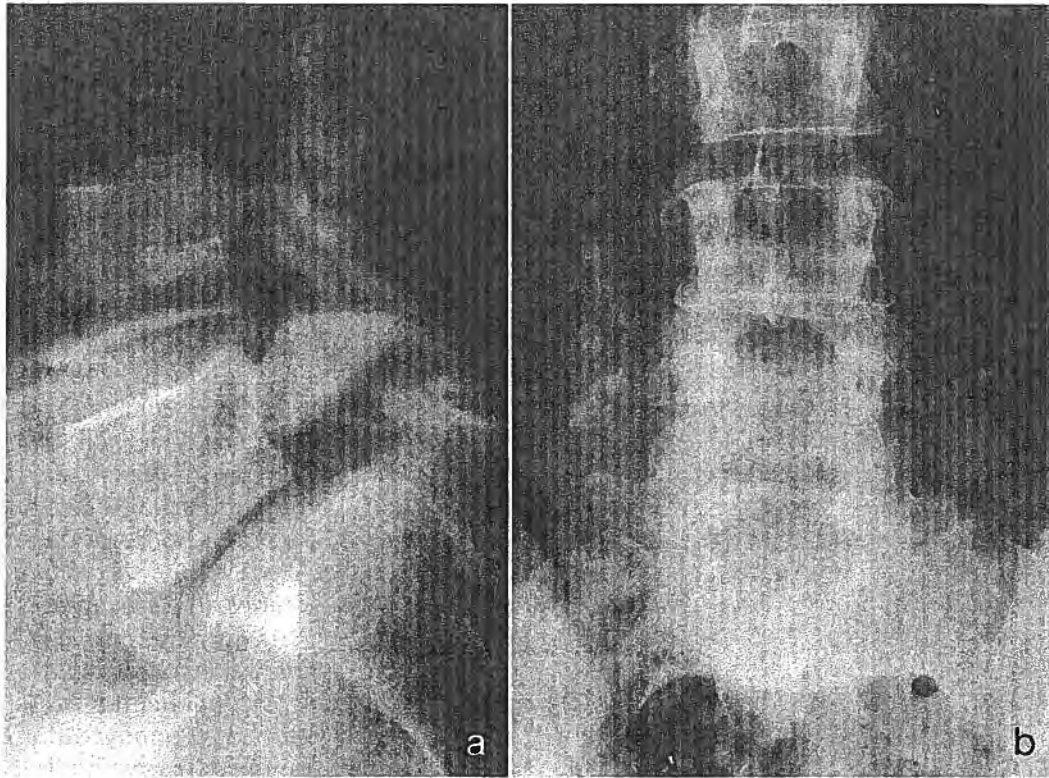


Figure 9.9. An antero-posterior radiograph of the lumbar spine of a woman aged 53, with spondyloptosis of L5. Note the classical radiological sign of "Napoleon's Hat". At operation, identification of vertebral levels can be difficult in such cases. Despite two operations aimed at decompressing the lumbar canal and nerve roots related to the spondyloptosis, the lamina of L5 remains intact. However, the laminae of L2 and L3 have been removed, along with some of their related facets



Figures 9.10a,b. **a** A lateral radiograph of the lumbar spine of a 39 year old woman showing grade I spondylolytic spondylolisthesis with disc resorption at L5/S1. **b** An antero-posterior radiograph following operation which had aimed to produce lumbar canal decompression and inter-transverse-alar fusions. Scattered bony fragments unrelated to the spinous processes of L3 and L4 are seen on the right side. On the left side scattered fragments of graft bone are seen in the region of the transverse processes of L3 and L4, no bone graft material being visible at the L5/S1 interspace. A central portion of the lamina of L4 has been removed and a small portion of the lamina of L5, leaving a gaping defect in the spinal canal with ragged margins

the sacrum and the normal lamina and spinous process above, using either a large rongeur with sharp cutting edges or a sharp scalpel. *Forceful use of periosteal elevators should be avoided as scar tissue of the density frequently encountered in these cases can only be dissected with sharp instruments.*

h) Re-Opening the Spinal Canal

If the upper end of the sacral lamina is in the field of operation, the canal can be re-entered easily in the mid-line, even if the dural sac is covered with densely adherent scar tissue. This can be done by thinning the lamina in the mid-line and then stripping the scar tissue carefully away from its upper edge with a pointed probe (such as the Watson-Cheyne probe). Alternatively, when the bone is very thin, a small gouge directed proximally from a few millimetres distal to the free edge of the lamina can be used. A small plug of laminal bone is turned out, allowing the

insertion of a blunt-ended probe into the canal. The dura is pushed away and a 2 or 3 mm sized cup of a 45 degree forward-angled rongeur then inserted to open the roof of the sacral canal, a few millimetres distal to its upper free edge, from the mid-line outward on both sides to the level of the medial margins of each S1 pedicle. Dural tearing may occur at this stage. It can be avoided by careful handling of the fragments of sacral bone created by the use of the angled rongeur. These fragments should not be pulled on forcibly. They are best left attached to the scar tissue, to be dissected free from it by sharp dissection after the canal has been exposed to the level of each S1 pedicle.

Should it be decided to commence the dissection for entry into the spinal canal at the upper end of the operation field, it may be easily done by removing the normal ligamentum flavum from the spinal segment immediately adjacent to the area to be re-explored. The central portion of the lamina on the inferior side of this vertebral interspace is then removed, using the same techniques described in dealing with the removal of the sacral laminal bone at its site of attachment to the scar tissue overlying the dura. Further dissection distally follows, using the landmarks of facet joints, medial pedicular margins and partes interarticulares, obtaining exposure one side at a time, with the careful technique outlined above.

Scar formation between the dura and nerve root sleeves and the paraspinal muscles is prevented by normal ligamentum flavum. This fact should be remembered when re-exploring a spinal interspace, which may have been opened previously on one side only as it may be put to good use, allowing safe entry into the spinal canal without risk of injuring the dural sac.

Regrettably, notes made at the time of the original surgery are rarely available to a surgeon when he is re-exploring a patient's spine. The identification of a segment of normal ligamentum flavum often assumes great importance. Although the outer surface of this ligamentum may be covered with dense white scar tissue arising from the deep surface of the paraspinal muscles, its presence can be determined most easily by removing the extra-synovial fat pad from the adjacent facet joint, and then defining its characteristic yellow colour, where it attaches to the medial edge of the superior facet at the interspace. Once its presence has been confirmed, the white scar tissue can be cut away, defining its full extent, before incising this ligamentum flavum to gain access to the spinal canal.

In the course of the dissection just described, root canal stenosis or foraminal stenosis can be identified and relieved easily (see pp. 30, 127-138). Once the lateral margins of the dural sac and the regional nerve root sleeves have been exposed on both sides over the whole area being re-explored, the surgeon is then in a position to assess the dural contents by digital palpation. If they are normal, the question of separating all the scar tissue from the dura should be addressed. It is not necessary to remove it entirely, but if scar tissue is left attached, it should be thin and should not contain any remnants of bony spicules. Bone left in scar tissue is likely to grow and it may lead to further canal stenosis after a few years, especially if a hemi-lamina is left nearby (Figs. 9.8).

With the canal thoroughly decompressed and any problems of root canal or foraminal stenosis already resolved, the regional intervertebral discs should be inspected, using digital palpation and probing with the Watson-Cheyne instrument. A nerve root may be bound to a recurrent disc prolapse by dense scar tissue. The use of an operating loop may be necessary to enable the separation of the root sleeve from prolapsed disc tissue, minimizing the risk of nerve injury. If recurrent disc

prolapse is found, curettage of the intervertebral disc space may be indicated. The risk of penetration of the abdominal cavity may be high in these circumstances so that realization of this hazard should be uppermost in the surgeon's mind (see Chapter 3, Fig. 3.3 a).

i) Dural and Epidural Problems

i) Meningocoeles

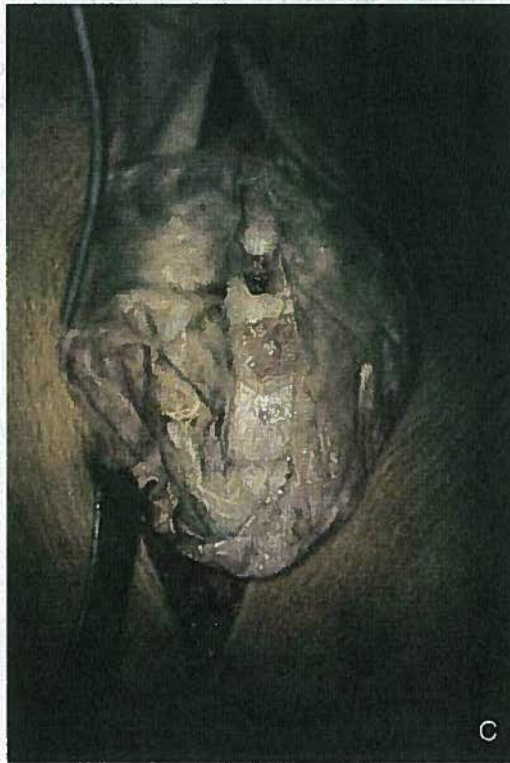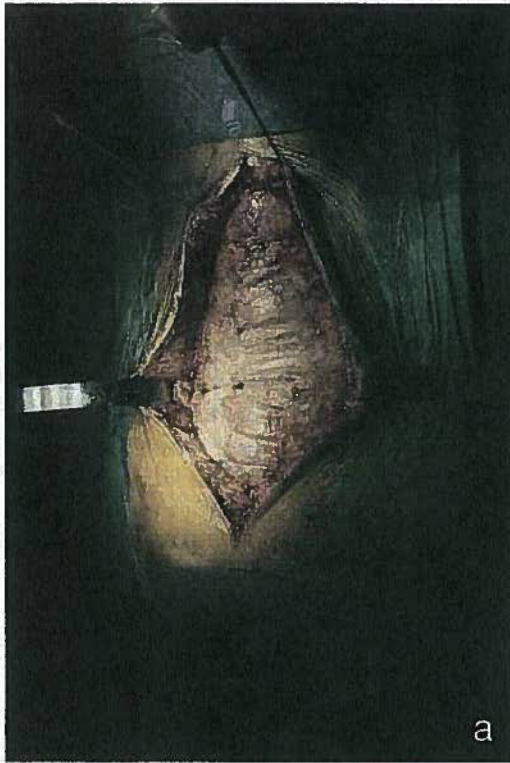
These lesions are uncommon. They are often only recognized at operation and may be found early in the course of a re-exploration operation. When the spinal canal has been opened as described above, a meningocele sac may then be dealt with quickly. It will usually have a single ostium which can be closed with a fine atraumatic suture after the bulk of the wall of the cystic cavity surrounding it has been separated from the dural sac and excised. In large long-standing meningoceles, closure may require the use of tissue patches fixed to the ostium with biological adhesives such as Tisseel (Figs. 9.11 a-c).

With attention to the details of dissecting technique outlined above, the creation of dural tears can usually be avoided. They may occur inevitably in some patients in whom the dura is abnormally thin. In such patients multiple tears sometimes occur and closure of the dural defects becomes impracticable. The closure of the wound at the completion of the operation then becomes critical. Several layers of sutures should be used in the muscle and fascial layers rendering the wound watertight. Appropriate chemotherapy should be administered post-operatively until the surgical wound has healed, Penicillins and Sulphonamides being used together when applicable.

Small dural tears should be identified and closed with fine "atraumatic sutures", the area of the tear being kept dry with a fine low-pressure sucker and protective patty. Care should be taken to avoid trapping nerve root filaments in the sutures as they are passed through the dural margins.

The management of the dura in cases of arachnoiditis of the cauda equina is discussed on pp. 206, 213. The technique of transdural disc fragment excision is found on p. 141.

Figures 9.11a-c. **a** A photograph of a large meningocele extending from the back of the sacrum to the level of T12 spinous process. This sac contained about 2 litres of cerebrospinal fluid. It was subcutaneous and filled within a few minutes of the patient standing. This meningocele had formed after dural injury ten years previously. **b** A photograph of the sac opened showing a single ostium in its base. The tip of the probe is pointing to a spinous process which has been eroded by the pressure of fluid over a period of ten years. **c** A photograph showing a patch of tissue cut from the wall of the sac applied to the ostium with Tisseel. The ostium could not be closed with sutures. The wall of the meningeal sac had been separated from all the surrounding soft tissues and its redundant tissue folded over the spinous processes and sutured in place, reinforcing the tissue patch which had been used to seal to the ostium



Figures 9.11 a-c

ii) Unrecognized Epidural Infection

Rarely, during re-exploration of the lumbar canal, previously unrecognized epidural or vertebral body infections may be found. The history of a superficial wound infection, followed by persistent spinal pain, out of proportion to what might have been expected post-operatively, should raise the possibility of this diagnosis. The planned operation of canal decompression should proceed, and intravenous chemotherapy should be commenced. Special care should be taken to avoid dural injury though the dura in such cases is often thickened. The epidural abscess should be sucked out and its extent defined. If possible, pus in the intervertebral disc space should be aspirated and sent immediately for bacteriological examination.

The decision for primary or secondary wound closure should be resolved on the assessment of the extent and severity of the infection. It is better to pack the wound open with dry gauze where a large abscess cavity has been discovered, particularly if the vertebral bodies are infected. Secondary closure of the wound may be performed when cultures taken from the granulating surfaces become sterile (Chapter 8, Figs. 8.13, 8.14). Such wounds, even if they are extensive, will heal by secondary intention in 6–8 weeks. The first few post-operative weeks will be spent in hospital and thereafter daily wound care can be managed at home by visiting nurses.

j) *Re-Exploration of the Spine Following Spinal Fusion Operations*

The principal indications for these operations are for the treatment of the following complications:

- a) Non-union.
- b) Graft overgrowth.
- c) Development of secondary stenosis.
- d) Disc or facet joint lesions above or below fused spinal segments.
- e) Fusion at the wrong level.
- f) Infection.
- g) Spondylosis acquisita.
- h) Ligamentum flavum atrophy.

i) Non-Union of Spinal Grafts

The multiplicity of methods of spinal fusion underlines the fact that it is difficult to produce union of the grafts with the vertebral column. The success rate of the lengthy spinal fusions used with Harrington's or Luecke's rods in scoliotics has not been matched when applied to the treatment of degenerative disorders or spondylolisthesis in the lumbar spine.

Non-union of the various spinal grafts used in the lumbar area can be diagnosed usually with plain X-rays, motion X-rays or tomograms. Discography may have a special place in the assessment of persisting pain after posterior spinal fusion with pseudarthrosis, as advocated by MacNab (1977, p. 195), though MRI may provide

sufficient evidence of the state of adjacent discs. Myelography may also be useful to demonstrate acquired canal stenosis.

Attempts at re-grafting in failed posterior fusions frequently fail. This problem may be managed most effectively in the majority of cases by a supplementary anterior interbody fusion.

Conversely, where an anterior interbody graft has failed, supplementary posterior inter-transverse grafting will often succeed, fusion of the anterior graft occurring *pari-passu* with the union of the posterior graft.

Particular problems may be encountered when attempting to repeat an anterior lumbar interbody grafting operation when no other method is applicable. The first is the identification of the vertebral interspace which will be obscured by extensive scarring. Facilities must be available for obtaining good quality radiographs in the operating room. The second problem of adherence of the great vessels to the vertebral column is always anticipated, so that a proper range of instruments and sutures should be available to deal with injuries to the great veins or their branches which may be inflicted on them inadvertently during dissection. Lumbar interbody fusion operations are usually performed through left-sided abdominal incisions. In the special circumstances of attempting to re-graft in the case of failure, the risks of ureteric injury or of damage to the left common iliac artery or vein are high. It may be safer to expose the lower lumbar vertebrae through a right-sided extra-peritoneal approach. Without doubt, attempted re-fusion of a failed anterior lumbar interbody graft should only be undertaken by a surgeon with special training in the use of these techniques of spinal fusion. Even equipped with the necessary training and with the help of skilled assistants, it may prove technically impossible to perform a re-fusion by this method. The patient should be informed in advance of the potential problems, including the possibility that the operation may need to be abandoned without completion of the re-grafting.

Non-union of cervical anterior interbody fusions is uncommon. Re-grafting is usually easy, though identification of the site of the pseudarthrosis can be difficult. Special care is needed when inserting the instruments to cut a new graft bed to ensure proper siting of the dowel cavity between the vertebral bodies, both in the longitudinal and transverse planes. In these cases it is potentially easy to expose and so to damage the vertebral artery and its *venae comitantes* if the cutter has been inserted too far laterally. The outlines of the inner margins of the *longus colli* muscles are usually obscured by the scar tissue formed following the previous surgery, so that the safety factor normally provided by the identification of these landmarks is lost. Damage to the vertebral artery and subsequent efforts to control the ensuing haemorrhage from it may lead to quadriparesis (Figs. 9.12a-c), or to cerebro-vascular accidents.

ii) Graft Overgrowth After Posterior Spinal Fusion

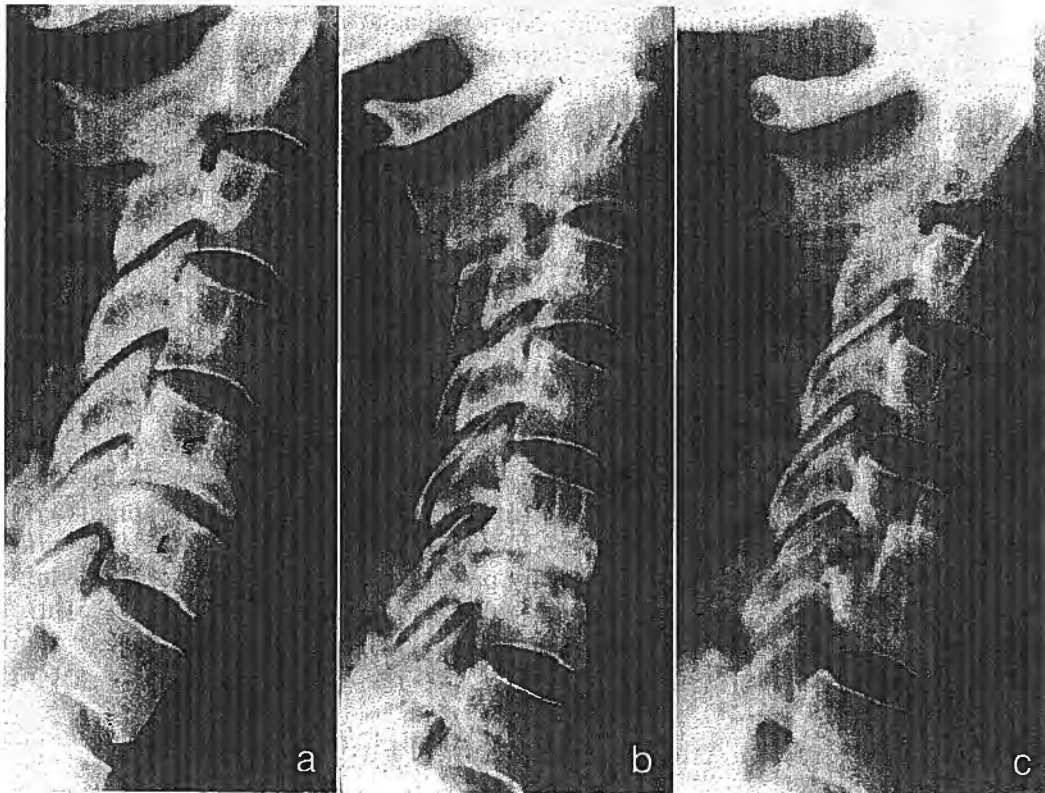
Attention was drawn to this particular complication by Crock in 1976. It may occur following the use of techniques for posterior spinal fusions involving the use of fragments of cortico-cancellous bone. While every effort should be made to place the bone chips accurately at the time of performing inter-transverse, postero-lateral or Hibb's type posterior fusions, the movement of some of the graft fragments beyond the desired area of fusion may occur and these bony fragments may continue to grow. An extreme example of this problem was seen in an elderly lady who had

312 The Management of Failed Spinal Operations

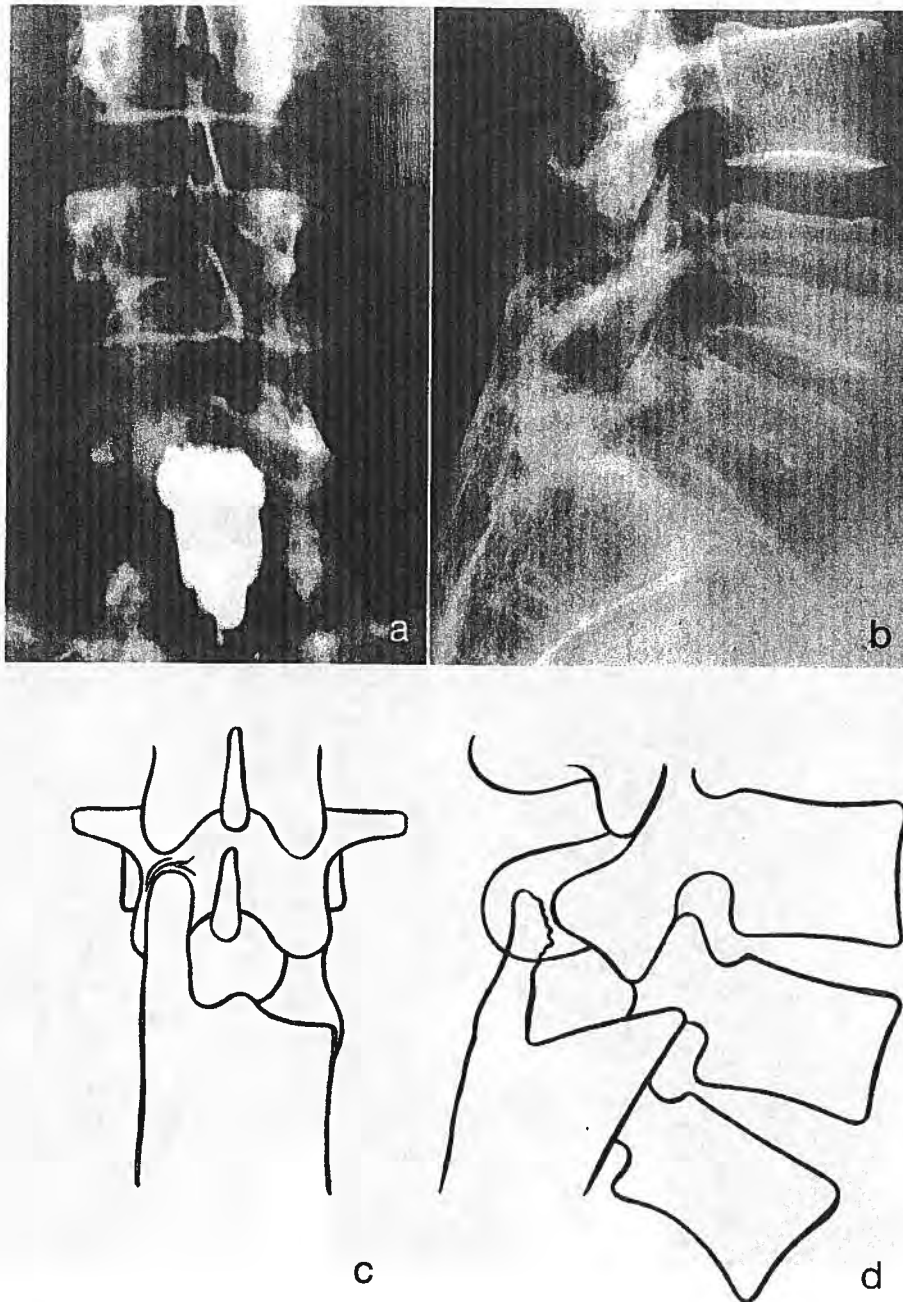
had multiple spinal operations performed for a lumbo-sacral disc lesion. A dense spicule of bone had extended to the level of the facet joints at L1/2 on one side where the point of this "unwanted graft" impinged upon the facet joint capsule causing chronic pain. Examples of this unwanted overgrowth of graft are shown in Figs. 9.13 a–d. Gratifying relief of intractable back pain can be obtained in these cases by simply excising the "unwanted bone", leaving the main body of the graft intact.

iii) Development of Secondary Stenosis Beneath the Graft

Hypertrophy of posterior fusions has been reported and may lead to secondary lumbar canal stenosis after many years. The complication is not common. Currently it is best assessed either by the use of MRI or by CT radiculography.



Figures 9.12a–c. Lateral radiographs of the cervical spine of a man aged 39 years. **a** Shows an isolated spondylitic degenerative change between the vertebral bodies of C5 and C6, the cause of intractable neck pain, occipital headache and brachial neuralgia. **b** Is a lateral radiograph taken nine months after interbody fusion performed by the Cloward method, showing non-union of the graft with some kyphotic deformity. **c** A lateral radiograph taken six months after replacement of the graft using the technique described in Chapter 7, p. 237



Figures 9.13a-d. **a** and **b** Antero-posterior and lateral radiographs of a posterior spinal fusion for spondylolisthesis in a woman aged 48 years. The prolongation of a bar of grafted bone can be seen on the left side overlying the lamina of L3 with reactive bone formation near the adjacent facet. **c** and **d** Explanatory drawings of the radiographs. **c** Shows solid fusion between the posterior elements of L4 and S2, with upward extension of the “unwanted graft”

314 The Management of Failed Spinal Operations

Relief of this form of stenosis can be difficult technically because the graft may measure many centimetres in depth. Usually it is possible to relieve the stenosis without interfering with the stability of the graft. This is done by removing the central segment of the graft and exposing the dural sac beneath it, being guided by the principles of re-exploration of the spine which have been outlined above.

iv) Disc or Facet Joint Lesions Above or Below the Fused Spinal Segment

Disc prolapse above a fused spinal segment occurs in a few cases. It usually occurs some years after the fusion and its identification is easy on clinical grounds. MRI or CT radiculography scanning are useful investigations when the diagnosis is suspected.

Acute nucleus pulposus calcification may be seen in discs adjacent to a previously fused spinal segment (Chapter 4).

Secondary degenerative arthritic changes may affect the facet joints above and below fused spinal segments, leading to secondary root canal stenosis or even spinal canal stenosis. Limited root canal decompression operations are usually effective in relieving symptoms.

v) Fusion at the Wrong Level

Surgeons dread this problem which may occur either when anterior interbody or posterior fusion methods are used at any level in the vertebral column. Readers are referred again to the sections of this book dealing with the operative technique of anterior interbody fusion operations, Chapters 2 and 7 (Figs. 9.7, 9.9, 9.10 a, b).

vi) Infections

Fortunately, infection after most spinal fusions is uncommon, though it is usually chronic and often difficult to control. Its incidence after the combined use of grafting with internal fixation is, regrettably, high, averaging 4 to 5% of cases.

Early post-operative death from gas gangrene has been reported following inter-transverse-alar fusion.

Chronically infected posterior grafts can be treated successfully by open drainage and the use of long-term chemotherapy; that is, by the same methods which are usually effective in controlling chronic osteomyelitis in long bones.

Infection after anterior interbody grafting operations is rare but serious. Epidural abscess formation is likely and may lead to cervical cord compression or cauda equina compression. Urgent radical drainage is required, with special measures in the neck to prevent the development of secondary kyphotic deformities. Skull traction may be required for some weeks or some form of halo applied, fitted to a thoracic jacket.

If the infection is due to staphylococcal organisms, long-term chemotherapy for at least 6 months is recommended (Fig. 9.14).

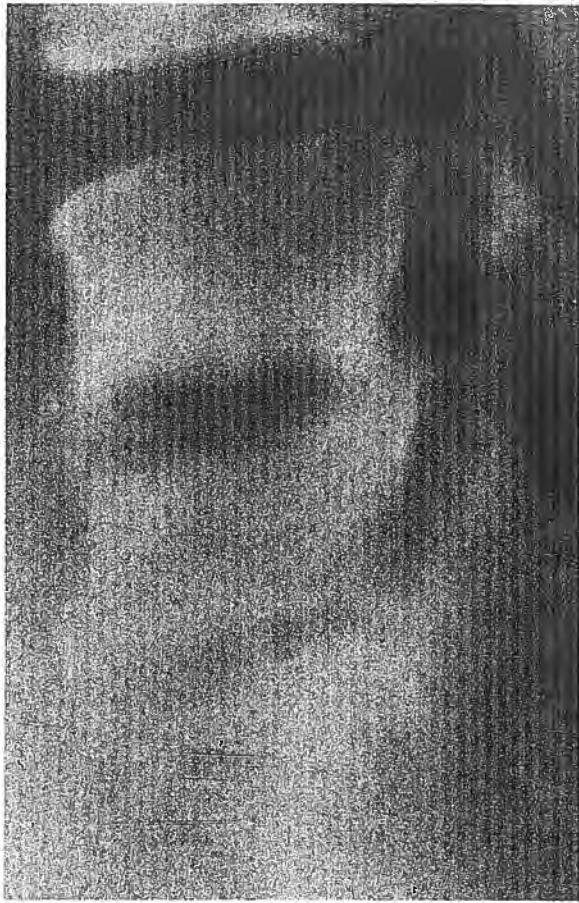

Figure 9.14. A lateral tomogram of the lower lumbar spine of a man aged 45 years. This film was taken more than twelve months after interbody fusions had been performed at L4/5 and L5/S1 levels, following which staphylococcal infection of the spine had occurred, leading to the development of an epidural abscess and to infection of the laminae and spinous processes at both levels. The infection was due to a staphylococcus aureus sensitive to Cloxacillin. The patient was treated by surgical drainage of the paravertebral abscess through the left loin and subsequently by extensive laminectomy for removal of infected laminal bone and for further drainage of an epidural abscess. Long-term chemotherapy was required over the course of 18 months and fibrous union followed

316 The Management of Failed Spinal Operations

vii) Spondylolysis Acquisita

This is a well-recognized though uncommon complication of posterior spinal fusion, though as MacNab has pointed out (1977, p. 216) it does not complicate intertransverse fusions in which the pars interarticularis of the proximal vertebral segment in the spinal fusion is supported by the graft.

Assuming that the disc at the level of the spondylolytic defect is intact, it may be satisfactory to perform a localized foraminal decompression, even on one side only.

viii) Ligamentum Flavum Atrophy

Atrophy of the ligamentum flavum occurs following interbody fusion operations, both in the lumbar and cervical regions. In some cases, this may lead to dural root sleeve tethering, so that, with normal movements at the first mobile segment above the fusion, the nerve roots at the level of the fusion may be stretched because the ligamentum flavum adheres to them. In the lumbar region, total laminectomy with excision of the ligamentum flavum over the area of the fused segment of the spine, leaving intact the facet joints at the level of the first mobile segment above the fusion, has been found satisfactory. It may also be applied to the management of persisting problems of neck and arm pain following successful anterior cervical fusion.

ix) Synchronous Combined Anterior and Posterior Spinal Fusion, with Internal Fixation

This massive operation has been advocated, in recent years, for the primary treatment of multi-level lumbar disc degeneration and as a salvage procedure following failure of other operations. Good results have been claimed by O'Brien and Kozak (1990) and by Selby and Henderson (1991). Despite its intended purpose even this procedure has failed, sometimes with catastrophic results.

Multi-level degenerative disease of the spine often responds tolerably well to conservative treatment. If surgery is required for its treatment in the lumbar spine, the less radical operation of bilateral foraminal and nerve root canal decompressions, with preservation of the laminal arches, spinous processes and their related ligaments will often give acceptable results (Fig. 9.15).

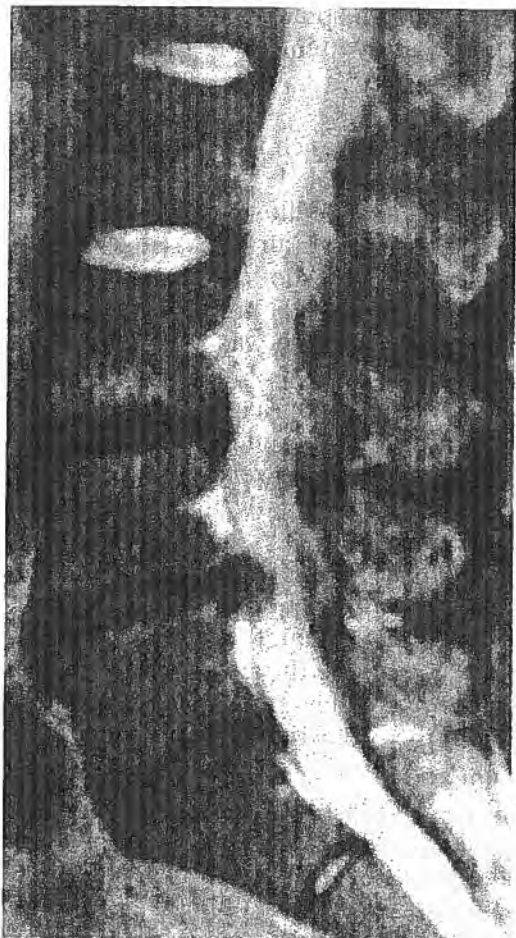


Figure 9.15. A mid-sagittal MR image, T2 weighted sequence, from the lumbar spine of a 24 year old man who presented with recurring episodes of back pain and lumbar scoliosis. He was a sedentary worker. Despite the appearance of a large filling defect related to the dural sac at the L4/5 level, he had no neurological signs on examination. His symptoms subsided with conservative treatment and surgery was not necessary

9.6. Summary

The surgical techniques used in re-exploring the lumbar spine have been described in considerable detail in this chapter. In concluding, attention is focussed on a number of important points:

1. Pay particular attention to the muscles of the back which will be further damaged by the re-exploration operation.
Release self-retaining retractors every 45 minutes to allow the muscle blood supply to flow for 5 minutes before proceeding with the surgery.
2. Do not leave jagged remnants of laminal bone in the roof of the spinal canal. Preserve the pars interarticularis, leaving smooth laminal margins adjacent to the dural sac. Coat these bony surfaces either with bone wax or with haemostatic agents at the conclusion of the operation.
Do not leave bony spicules in scar tissue overlying the dura.
3. Pay particular attention to haemostasis during the operation. Avoid electrocoagulation of vessels in the spinal canal as far as possible, relying rather on the use of haemostatic agents such as gelfoam, packed lightly in the paradural gutters at the end of the operation.
4. Use closed suction drainage post-operatively, except in cases where leakage of cerebrospinal fluid may be anticipated.
5. Before embarking on re-explorations of the spinal canal, the surgeon must be familiar with techniques for opening and closing the dural sac or nerve root sheaths. He or she must be aware of the potential danger of cauda equina injury and avoid the use of a strong sucker without the protection of a cotton patty on the sucker tip.
In treating cauda equina arachnoiditis (p. 213) or in circumstances where multiple rents have occurred in abnormally thin dura in the course of the operation, closure of the dura may not be indicated. Special care must then be exercised in closing the wounds and the patient should be given chemotherapy prophylactically.

9.7. Post-Operative Care

Pain control is often particularly difficult in these patients so that special management with continuous intravenous infusions of Pethidine or Omnopon may be required for a few days. Anticoagulant therapy is advised, particularly after lengthy operations.

Mobilization should start soon after operation and in due course a cautious rehabilitation programme should commence. Warm pool therapy is often useful, though if this is not available, then walking progressive distances is to be recommended. Any vigorous muscular exercise is to be avoided.

Light surgical corsets are often helpful for short-term use.

Medical Aspects in the Management of Spinal Surgical Patients

Bryan P. Galbally, M.B.B.S., F.R.A.C.P.

Surgical procedures on the spinal cord and spinal canal structures are the fifth most commonly performed operations, after biopsies, caesarean section, repair of lacerations in obstetrical patients, hysterectomy, and more common than cholecystectomy, oophorectomy, open reduction of fractures and appendicectomy (National Center for Health Statistics, U.S.A., 1987).

Patients who undergo spinal surgery are usually adults whose pain has been chronic and sometimes disabling. Only a minority of them will suffer acute symptoms requiring spinal surgery on an emergency basis. The majority will have suffered from spinal pain for many months or years and undergone various forms of treatment comprising bed-rest, traction, injections, physical therapy, including chiropractic and osteopathy, acupuncture and varieties of complementary medicine such as homeopathy, naturopathy, aromatherapy, reflexology, herbal medicine, faith healing and special diets, eg macrobiotics; many will have used large doses of different kinds of medication: analgesics, pain-killers, anxiolytics, hypnotics, anti-depressants, and non-steroidal anti-inflammatory drugs. It is in the review and assessment of these drugs which are so often taken in combination and in large dosage by patients with chronic spinal pain that the physician has an essential and major role to play in their management. The immediate and beneficial results of spinal surgery may allow drastic modification of the medication regime over several weeks but a number of patients presenting for operation are drug dependant and require special care to moderate the addiction before surgery.

The first 24–48 hours after general anaesthesia, when the patient is receiving intravenous analgesia (usually morphine, pethidine or omnopon) provides the best opportunity to withdraw drugs of dependency. Following the cessation of administration of intravenous narcotics, appropriate drugs are prescribed in moderation, e.g. Voltarol (diclofenac) per rectum, Tylex (codeine and paracetamol), and Aspav (aspirin and papaveretum) orally. The range and dosage of drugs regularly consumed by some patients is often excessive as illustrated in the records of three cases listed in Table 1.

320 Medical Aspects in the Management of Spinal Surgical Patients

Table 1. Examples of pre-operative daily medication intake in 3 patients at the time of their admission to hospital for repeat spinal surgery

Case 1		Case 2*		Case 3	
Diazepam	50 mg	Diazepam	10 mg	Lorazepam	6 mg
Triazolam	0.375 mg	Nitrazepam	15 mg	Triazolam	1 mg
Thyroxine	150 mcg	Promethazine	20 mg	Paracetamol	4 g
Benzhexol	15 mg	Paracetamol	4 g		
Cyclobenzaprine	30 mg	Aspirin	600 mg		
Metoprolol	300 mg	Dihydrocodeine tartate	300 mg		
Nifedipine	30 mg	Diphenoxylate +	5 mg		
Glyceril trinitrate transdermal patch	5 mg	Atropine	50 mcg		
Beclamethasone aerosol	600 mcg	Ranitidine	300 mg		
Aspirin	300 mg	Hyoscine butylbromide	40 mg		
Codeine phosphate	120 mg	Nabumetone	1 g		
Paracetamol	3 g	Frusemide	80 mg		
Dextropropoxyphene	100 mg	Potassium chloride	1.2 g		
Amitriptyline	200 mg				
Clofibrate	1 g				
Sucralfate	3 g				
Ranitidine	450 mg				
Frusemide	120 mg				
Potassium chloride	3 g				
Diphenoxylate +	5 mg				
Atropine	50 mcg				

* Case 2 developed acute hepatic failure with coma post-operatively on a previous occasion.

All three cases were discharged from hospital following definitive spinal surgery with a markedly reduced intake of drugs.

The patient presenting for spinal surgery may be receiving medication for concomitant pathological conditions: these regimes will require attention and review prior to general anaesthesia and surgery. Conditions such as hypertension, diabetes mellitus, asthma, allergy and hypersensitivity may require further specific investigation and management before operation.

Pre-operative review must include psychological assessment as well as physical examination including dental inspection and other special tests: chest radiography, electrocardiography, haematology, serology and biochemistry profiles. A raised erythrocyte sedimentation rate as a single abnormal finding in an otherwise healthy patient may point to underlying pathology. As an example, an ESR of 40 mm in these circumstances was found to be caused by a uterine infection due to a retained loop which had been in place for several years.

Chronic spinal pain which is severe enough to be disabling is almost always accompanied by psychological disturbances. Many patients have obsessional neuroses and depression reflecting the inevitable stress imposed on the patient's own psyche and the deterioration in lifestyle of the spouse or close family members; these effects may reach others in the near-environment perhaps the family physician, the

physiotherapist or osteopath, neighbours and friends, the family nanny or other domestic staff. The result is a network of tangled interpersonal relationships the common thread of which is the patient's response, the ability to cope or otherwise, with chronic disabling spinal pain. The dynamics of the patient's closer interpersonal relationships usually require scrutiny as part of the psychological evaluation. Psychotherapy and/or psychotropic drugs may be indicated.

Practice in North America strongly supports the notion of several days hospitalisation prior to surgery for physical therapy, group therapy and instruction in pre- and post-operative procedures, operative procedures and medico-legal consequences. This approach is not widely accepted in other Western countries. Europeans are less enthusiastic about and certainly less responsive to group therapy and are generally less preoccupied with clinical minutiae and the potential for medico-legal action.

Admission to hospital should be at least one day prior to surgery. However, information must be obtained at least one month earlier with regard to the intake of drugs, in particular certain psychotropics such as monoamine oxidase inhibitors, the contraceptive pill or hormone replacement therapy. These drugs pose threats such as subarachnoid haemorrhage with general anaesthesia and intravenous narcosis or post-operatively of thrombo-embolic manifestations. Also, the intake of alcohol, nicotine and other lifestyle drugs should be restricted to reduce the risks of general anaesthesia.

Unhurried counselling on the major aspects of the patient's individual spinal surgery should be given on admission. Patient care is more satisfactory when the patient has time to become familiar with the hospital environment and with the staff who will be in attendance post-operatively. At this time, the use of special equipment such as the vertical tilting bed, the intravenous infusion pump, the chair with spring-loaded seat, elastic stockings, to enhance venous drainage, and orthoses for use in the neck or other areas of the spine where indicated, may be explained.

However, some patients who have a concomitant illness or a history of complex drug intake may require to be admitted several days prior to surgery. In this time, their general physical condition may be improved, specific treatment given and drug control initiated. Most spinal surgical patients have the opportunity to achieve recovery when their pain is reduced or eliminated and their dependency situation removed as a consequence.

Previously unrecognized concomitant disease discovered following admission to hospital is not uncommon and is cause for concern for the physician: various anaemias (commonly sickle-cell and iron deficiency), carcinomas (lung, bladder and colon), disorders of biochemistry (commonly hyperlipidaemia), hormone secreting tumours (acromegaly and pheochromocytoma), tuberculosis, neurological disorders, urethral stricture, sexually transmitted diseases including human immunodeficiency viral infection. Testing for HIV antibodies is desirable in all patients undergoing surgery and requires sensitive counselling both before and after the test. The patient should always be reassured of the strict confidentiality of the test and its result and offered the option of not being informed of the result itself.

Early post-operative complications with spinal surgery relate to malfunction of the gut. Nausea is common with intravenous narcotic medication and a short-lived ileus commonly follows anterior approaches to the thoracic or lumbar spine. Occasionally a more severe ileus occurs requiring naso-gastric drainage, intravenous dextrose and electrolytes and if prolonged, complete parenteral nutrition. If a cen-

322 Medical Aspects in the Management of Spinal Surgical Patients

tral venous line is used it should be changed at intervals not exceeding 48 hours. Intensive care is most likely to be required in surgery of the upper cervical spine – here a patient nurse ratio of 1:1 will replace ordinary ward nursing care. Post-operative pain relief is achieved with an intravenous adjustable infusion pump delivering a fixed rate of a suitable narcotic, usually morphine, pethidine or omnopon. Close supervision of the intravenous pump is mandatory noting the patient's respiratory rate and blood pressure at frequent intervals.

Early mobilisation on the day of, or the day after, surgery is facilitated by the use of a vertical tilting bed which places the patient upright and allows him or her to walk freely from the footboard.

Respiratory care, mobilisation and early rehabilitation are supervised by the physical therapist who exercises the patient each day, both morning and afternoon.

Apart from early mobilisation, the risk of post-operative thrombo-embolic manifestations is reduced by the use of heparin injected subcutaneously each day (e.g. Clexane 40 mg, commenced 12 hours prior to surgery) for a week to ten days, and the wearing of above-knee elastic stockings to enhance venous drainage from the lower limbs for at least six weeks after surgery.

A short-lived rise in temperature due to a metabolic response is the norm after spinal surgery. In the presence of significant wound infection on the other hand, the temperature is persistently elevated, the pulse rapid, pain is severe and the patient looks ill.

The management of spinal surgical patients rests on the efforts of a dedicated team under the leadership of the spinal surgeon. Its members include assistant surgeons, fellows-in-training, nurses, physiotherapists and technicians specially trained in the care of patients undergoing spinal surgery together with a physician or physicians who are committed to the aspects of patient care which are briefly outlined above.

References

- Adkins, E. W. O.: Lumbo-sacral arthrodesis after laminectomy. *J. Bone Joint Surg.* 37B, 208–223 (1955).
- Albee, F. H.: Transplantation of a portion of tibia into the spine for Pott's disease. *JAMA* 57, 885–886 (1911).
- American Academy of Orthopaedic Surgeons Symposium on the Spine, p. 289. St. Louis: C. V. Mosby. 1969.
- Armstrong, J. R.: Lumbar disc lesions. Edinburgh: E. and S. Livingstone. 1965.
- Aronson, H. A., Dunmore, R. H.: Herniated upper lumbar disc. *J. Bone Joint Surg.* 45A, 311–317 (1963).
- Arseni, C., Nash, F.: Protrusion of thoracic intervertebral discs. *Acta Neurochir. (Wien)* 11, 3–33 (1963).
- Assheuer, J.: Neuroradiologist (Köln, Germany). Personal communication (1991).
- Beadle, O. A.: The intervertebral disc (Medical Research Council, Special Report Series 161), p. 79. London: His Majesty's Stationery Office. 1931.
- Beals, R. K., Hickman, N. W.: Industrial injuries of the back and extremities. *J. Bone Joint Surg.* 54A, 1593–1611 (1972).
- Bickerstaff, E. R.: Neurological examination in clinical practice, 3rd ed. Oxford-London-Edinburgh-Melbourne: Blackwell. 1973.
- Blikra, G.: Intradural herniated lumbar disc. *J. Neurosurg.* 31, 676–679 (1969).
- Bobacko, W. P., Hirsch, C.: Autoimmune response to nucleus pulposus in the rabbit. *J. Bone Joint Surg.* 47B, 574–580 (1965).
- Bogduk, N., Macintosh, J. E.: The applied anatomy of the thoracolumbar fascia. *Spine* 9, 164–170 (1984).
- Bohlman, H. H., Cook, S. S.: One-stage decompression and posterolateral interbody fusion for lumbosacral spondyloptosis through a posterior approach. Report of two cases. *J. Bone Joint Surg.* 64A, 415–418 (1982).
- Bonneville, J. F. (ed.): Focus on Chemonucleolysis, pp. 1–152. Berlin-Heidelberg-New York-Tokyo: Springer. 1986.
- Brain, Lord R., Wilkinson, M.: Cervical spondylosis and other disorders of the cervical spine. London: W. Heinemann. 1967.
- Brav, E. A., Bruck, S., Fruchter, J. M.: A roentgenologic study of low back and sciatic pain. *AJR* 48, 39–46 (1942).
- Briggs, H., Krause, K.: The intervertebral foraminotomy for relief of sciatic pain. *J. Bone Joint Surg.* 27, 475–478 (1945).
- Brown, H. A., Pont, M. E.: Disease of lumbar discs: 10 years of surgical treatment. *J. Neurosurg.* 20, 410–417 (1963).
- Brown, M. D.: Intradiscal therapy, pp. 1–186. Chicago-London: Year Book Medical Publishers Inc. 1983.

324 References

- Brown, M. D.: The pathophysiology of disc disease. *Orthop. Clin. North Am.* 2, 359-370 (1971).
- Buck, J. E.: Direct repair of the bony defect in spondylolisthesis. In: *Operative Surgery*, 3rd ed., p. 419. London: Butterworths. 1979.
- Buck, J. E.: Direct repair of the defect in spondylolisthesis. *J. Bone Joint Surg.* 52B, 432-437 (1970).
- Burton, C. V., Heithoff, K. B., Kirkaldy-Willis, W., Ray, C. D.: Computed tomographic scanning and the lumbar spine, Part II: Clinical considerations. *Spine* 4, 356-368 (1979).
- Campbell, A. M. G., Phillips, D. G.: Cervical disk lesions with neurological disorder. *Brit. Med. J.* 2, 481-485 (1960).
- Carson, J., Gumpert, J., Jefferson, A.: Diagnosis and treatment of thoracic intervertebral disc protrusions. *J. Neurol. Neurosurg. Psychiatry* 34, 68-77 (1971).
- Chari, P. R. (Professor of Orthopaedic Surgery, Hyderabad, India): Personal communication, unpublished.
- Charnley, J.: Arthroplasty of the hip. A new operation. *Lancet* 1, 1129-1132 (1961).
- Chow, S. P., Leong, J. C. Y., Ma, A., Yau, A. C. B. C.: Anterior spinal fusion for deranged lumbar intervertebral disc. *Spine* 5, 452-458 (1980).
- Cloward, R. B.: Lumbar intervertebral disc surgery. *Surgery* 32, 852-857 (1952).
- Cloward, R. B.: The treatment of ruptured lumbar intervertebral discs by vertebral body fusion. *J. Neurosurg.* 10, 154-168 (1953).
- Cloward, R. B.: Multiple ruptured lumbar discs. *Ann. Surg.* 142, 190-195 (1955).
- Cloward, R. B.: The anterior approach for ruptured cervical discs. *J. Neurosurg.* 15, 602-617 (1958).
- Cloward, R. B.: Lesions of the intervertebral discs and their treatment by interbody fusion methods. *Clin. Orthop.* 27, 51-77 (1963).
- Cole, E. S.: Psychiatric aspects of compensable injury. *Med. J. Aust.* 1, 93-100 (1970).
- Collis, J. S.: Lumbar discography. Springfield, Ill.: Ch. C. Thomas. 1963.
- Coventry, M. B., Ghormley, R. K., Kernohan, J. W.: The intervertebral disc: its microscopic anatomy and pathology. *J. Bone Joint Surg.* 27, 105-112, 233-247 (1945).
- Critchley, E. M. R.: Lumbar spinal stenosis. (Leading article.) *Brit. Med. J.* 284, 1588-1589 (1982).
- Crock, H. V.: The arterial supply and venous drainage of the bones of the human knee joint. *Anat. Rec.* 144, 199-218 (1962).
- Crock, H. V.: Post-traumatic erosions of articular cartilage. *J. Bone Joint Surg.* 64B, 530-538 (1965).
- Crock, H. V.: The blood supply of the lower limb bones in man. Edinburgh-London: E. and S. Livingstone. 1967.
- Crock, H. V.: A reappraisal of intervertebral disc lesions. *Med. J. Aust.* 1, 983-989 (1970).
- Crock, H. V.: Isolated lumbar disc resorption as a cause of nerve root canal stenosis. *Clin. Orthop.* 115, 109-115 (1976).
- Crock, H. V.: Observations on the management of failed spinal operations. *J. Bone Joint Surg.* 58B, 193-199 (1976).
- Crock, H. V.: Traumatic disc injury. In: *Handbook of clinical neurology* (Vinken, P. J., Bruyn, G. W., eds.), pp. 481-511. Amsterdam: North-Holland. 1976.
- Crock, H. V.: Surgical management of lumbar disc prolapses. In: *Operative surgery*, 3rd ed., pp. 404-415. London: Butterworths. 1978.
- Crock, H. V.: Anterior lumbar interbody fusion, indications for its use and notes on surgical technique. *Clin. Orthop.* 165, 157-163 (1981).
- Crock, H. V.: Normal and pathological anatomy of the lumbar spinal nerve root canals. *J. Bone Joint Surg.* 63B, 487-490 (1981).
- Crock, H. V.: Traitement chirurgical de la calcification du nucleus pulposus du disque intervertébral dorsal et lombaire, chez l'adulte. *Revue de chirurgie orthopédique* 68, 171-177 (1982).
- Crock, H. V., Crock, M. C.: A technique for decompression of the lumbar spinal canal. *Neuro-Orthopaedics* 5, 96-99 (1988).

- Crock, H. V., Goldwasser, M.: The fine circulation related to the vertebral end-plates in adult dogs. *Spine* 9, 702-706 (1984).
- Crock, H. V., Yoshizawa, H.: The blood supply of the vertebral column and spinal cord in man. Wien-New York: Springer. 1977.
- Crock, H. V., Yoshizawa, H., Kame, S. K.: Observations on the venous drainage of the human vertebral body. *J. Bone Joint Surg.* 55B, 528-533 (1973).
- Crockard, H. A.: Anterior approaches to lesions of the upper cervical spine. *Clin. Neurosurg.* 34, 389-416 (1988).
- Cyriax, J.: The slipped disc. London: Gower Press. 1970.
- Dandy, W. E.: Concealed ruptured intervertebral discs: Plea for elimination of contrast media in diagnosis. *JAMA* 117, 821-823 (1941).
- DeBeyre, J., Delforges, P.: Arthrodeuse vertébrale intersomatique. *Rev. Chir. Orthop.* 45, 855-894 (1959).
- DePalma, A. F., Rothman, R. H.: The intervertebral disc. Philadelphia: W. B. Saunders. 1970.
- Dillane, J. B., Fry, J., Kalton, G.: Acute back syndrome - a study from general practice. *Brit. Med. J.* 2, 82-84 (1966).
- Donisch, E. W., Trapp, W.: The cartilage end plates of the human vertebral column (some considerations of postnatal development). *Anat. Rec.* 169, 705-716 (1971).
- Doppman, J. L., Di Chiro, G., Ommaya, A. K.: Selective arteriography of the spinal cord. St. Louis: W. H. Green. 1969.
- Dreyfus, P. B., Six, B., Dorfmann, H., De Sèze, S.: La hernie discale dorsale. *Sem. Hôp. Paris* 48, 3045-3052 (1972).
- Dwyer, A. F., Newton, N. C., Sherwood, A. A.: An anterior approach to scoliosis. A preliminary report. *Clin. Orthop.* 62, 192-202 (1969).
- Dyck, P.: Paraplegia following chemonucleolysis. A case report and discussion of neurotoxicity. *Spine* 10, 359-362 (1985).
- Dye, E. R.: Kinematics of the human body under crash conditions. *Clin. Orthop.* 8, 305-309 (1956).
- Ehni, G.: Effects of certain degenerative diseases of the spine, especially spondylosis and disk protrusion, on the neural contents, particularly in the lumbar region. *Mayo Clinic Proc.* 50, 327-338 (1975).
- Epstein, B.: The spine. New York-London: Lea and Febiger. 1969.
- Epstein, J. A., Epstein, B. S., Lavine, L.: Nerve root compression associated with narrowing of the lumbar spinal canal. *J. Neurol. Neurosurg. Psychiatry* 25, 165-176 (1962).
- Esses, S. I., Sachs, B. L.: Complications of pedicle screw fixation. Paper 64 delivered at the 25th Anniversary Meeting of the Scoliosis Research Society 1991, Minneapolis, Minnesota, USA.
- Farfan, H. F., Cossette, J. W., Robertson, G. H., Wells, R. V., Krause, H.: The effects of torsion on the lumbar intervertebral joints: the role of torsion in the production of disc degeneration. *J. Bone Joint Surg.* 52A, 468-497 (1970).
- Farfan, H. F., Huberdeau, R. M., Dubow, H. I.: Lumbar intervertebral disc degeneration. *J. Bone Joint Surg.* 54A, 492-510 (1972).
- Ferguson, A. B.: Roentgendiagnostic. Extremities and spine. New York: Hoeber. 1949.
- Fineschi, C.: Anatomical anomalies of the lumbar spinal roots. *Arch. Putti* 2, 222-236 (1952).
- Finneson, B. E.: Low back pain. Philadelphia: J. B. Lippincott. 1973.
- Flynn, J. C., Hoque, M. A.: Anterior fusion of the lumbar spine. *J. Bone Joint Surg.* 61A, 1143-1150 (1979).
- Fraser, R. D.: A wide muscle-splitting approach to the lumbosacral spine. *J. Bone Joint Surg.* 64B, 44-46 (1982).
- Frederickson, B. E., Baker, D., McHolick, W. J., Yuan, H. A., Lubicky, J. P.: The natural history of spondylolysis and spondylolisthesis. *J. Bone Joint Surg.* 66A, 699-707 (1984).

326 References

- Frederickson, B. E., Baker, D., Murtland, A., Yuan, H. A.: Paper presented at 5th Annual Meeting, North American Spine Society, Monterey, California, August 1990.
- Freebody, D., Bendall, R., Taylor, R. D.: Anterior transperitoneal lumbar fusion. *J. Bone Joint Surg.* 53B, 617-627 (1971).
- Frykholm, R.: Deformities of dural pouches and strictures of dural sheaths in the cervical region producing nerve root compression. A contribution to the aetiology and operative treatment of brachial neuralgia. *J. Neurosurg.* 4, 403-413 (1947).
- Fujimaki, A., Crock, H. V., Bedbrook, G. M.: The results of 150 anterior lumbar interbody fusion operations performed by two surgeons in Australia. *Clin. Orthop.* 165, 164-167 (1982).
- Ghosh P. (ed.): *The Biology of the intervertebral disc*, pp. 1-245. Boca Raton, Florida: CRC Press Inc. 1988. Anniversary meeting of the Scoliosis Research Society, Minneapolis, 1991.
- Gill, G. G., Manning, J. C., White, H. L.: Surgical treatment of spondylolisthesis without spine fusion. *J. Bone Joint Surg.* 37A, 493-518 (1955).
- Gimeno, A.: Arachnoid, neurenteric and other cysts. In: *Handbook of clinical neurology: congenital malformations of the spine and spinal cord* (Vinken, P. J., Bruyn, G. W., eds.), pp. 393-448. Amsterdam: North-Holland. 1978.
- Gonsette, R.: An experimental and clinical assessment of water-soluble contrast medium in neuro-radiology. A new medium Dimer - X. *Clin. Radiol.* 22, 44-56 (1971).
- Graf, H.: Graf stabilisation system. Lyon, France (1991).
- Graham, C. E.: Backache and sciatica. *Med. J. Aust.* 1, 5-8 (1974).
- Grollmus, J., Perkins, R. K., Russel, W.: Erythrocyte sedimentation rate as a possible indicator of early disc space infection. *Neurochirurgia (Stuttg.)* 17, 30-35 (1974).
- Gross, D.: Treatment of prolapsed lumbar intervertebral disk. *Folia Rheumatologica (Basel)* 2, 1-16 (1965).
- Gurdjian, E. S., Webster, J. E., Ostrowski, A. Z., Hardy, W. G., Lindner, D. W., Thomas, L. M.: Herniated lumbar intervertebral discs - an analysis of 1,176 operated cases. *J. Trauma* 1, 158-176 (1961).
- Hakelius, A., Nilsson, U., Pernow, B., Zetterquist, S.: The cold sciatic leg. *Acta Orthop. Scand.* 40, 614-623 (1969).
- Happey, F., Johnson, A. G., Naylor, A., Turner, R. L.: Preliminary observations concerning the fine structure of the intervertebral disc. *J. Bone Joint Surg.* 46B, 563-567 (1964).
- Hartman, J. T. (Dean, Faculty of Medicine, Texas Tech. University, Lubbock, Texas): Personal Communication, unpublished.
- Hasue, M., Ito, R.: Sacral nerve root cyst as a cause of low back pain and sciatica. *J. Jap. Orthop. Ass.* 46, 65-72 (1972).
- Hasue, M., Kunogi, J., Kikuchi, S.: Imaging methods of the dorsal root ganglion. Diagnostic aids in lumbar spine disease. A preliminary report. *Neuro-Orthopaedics* 8, 23-27 (1989).
- Helfet, A. J., Gruebel Lee, D. M.: *Disorders of the lumbar spine*. Philadelphia: J. B. Lippincott. 1978.
- Hijikata, S.: Practice of discography. In: *Diagnosis of orthopaedic diseases*. (Tsuji, H., Takahashi, H., eds), chapter 14, pp. 689-700. Tokyo: Kanehara Shuppan. 1982.
- Hijikata, S., Yamagishi, M., Nakayama, T., et al.: Percutaneous disectomy: a new treatment method for lumbar disc herniation. *J. Toden Hosp.* 5, 5 (1975).
- Hirabayashi, K., Satomi, K., Sasaki, T.: Ossification of the posterior longitudinal ligament in the cervical spine. In: *The cervical spine*. (Serb, H. H., Dunn, E. J., Eismont, F. J., et al., eds.), pp. 678-692. Philadelphia: Lippincott. 1989.
- Hirsch, C., Bobechko, W. P.: Auto-immune response to nucleus pulposus in the rabbit. *J. Bone Joint Surg.* 47B, 574-580 (1965).
- Hirsch, C., Zotterman, Y.: *Cervical pain*. Proc. Intern. Symp. Wenner-Gren Center, Stockholm, 1971. Oxford: Pergamon Press. 1972.

- Hodgson, A. R., Stock, F. E.: Anterior spinal fusion: a preliminary communication of the radical treatment of Pott's disease and Pott's paraplegia. *Brit. J. Surg.* 44, 266-275 (1956).
- Hooper, J.: Low back pain and manipulation. *Med. J. Aust.* 1, 549-551 (1973).
- Houdart, R., Djindjian, R., Hurth, M.: Chirurgie des angiomes de la moelle. *Neuro-Chirurgie* 15, Suppl. 1 (1969).
- Hudgins, W. R.: The predictive value of myelography in the diagnosis of ruptured lumbar discs. *J. Neurosurg.* 32, 152-162 (1970).
- Hult, L.: The Munk Fors investigation. *Acta Orthop. Scand. Suppl.* 16, 1-76 (1954).
- Inman, V. T., Saunders, J. B. DeCM: Anatomico-physiological aspects of injuries to the intervertebral disc. *J. Bone Joint Surg.* 29, 461-475 (1947).
- Jackson, R. K.: The long-term effects of wide laminectomy for lumbar disc excision. *J. Bone Joint Surg.* 53B, 609-616 (1971).
- Jayson, M.: The lumbar spine and back pain. London: Sector Publishing. 1976.
- Jenkins, D. H. R., Weeks, R. D., Yau, A. C. M. C., Du, R. R.: Manual of spinal surgery. London: Butterworths. 1981.
- Johnson, R. H.: Cerebro-spinal fluid. In: Scientific foundations of neurology, pp. 281-288. London: W. Heinemann. 1972.
- Jones, R. A. C., Thomson, J. L. G.: The narrow lumbar canal. *J. Bone Joint Surg.* 50B, 595-605 (1968).
- Kellgren, J. H.: Sciatica. *Lancet* 1, 561-564 (1941).
- Keyes, D. C., Compere, E. L.: The normal and pathological physiology of the nucleus pulposus of the intervertebral disc: an anatomical, clinical and experimental study. *J. Bone Joint Surg.* 14, 897-938 (1932).
- Kirkaldy-Willis, W. H., Paine, K. W. E., Cauchoix, J., McIvor, G.: Lumbar spinal stenosis. *Clin. Orthop.* 99, 30-50 (1974).
- Kirkaldy-Willis, W., Hill, R. J.: A more precise diagnosis for low back pain. *Spine* 4, 102-109 (1979).
- Knutsson, F.: The vacuum phenomenon in intervertebral discs. *Acta Radiol. (Stockh.)* 23, 173-179 (1942).
- Köhler, A., Zimmer, E. A.: Borderlands of the normal and early pathologic in skeletal roentgenology. New York-London: Grune and Stratton. 1968.
- Kramer, J.: Intervertebral disk diseases: causes, diagnosis, treatment and prophylaxis. Stuttgart: G. Thieme. 1981.
- Kudelka, P.: Laminectomy in lumbar disc syndrome. *Med. J. Aust.* 1, 1120-1122 (1968).
- Kulak, R. F., Schultz, A. B., Belytschko, T., Galante, J.: Biomechanical characteristics of vertebral motion segments and intervertebral disc. *Orthop. Clin. North Am.* 6, 121-133 (1975).
- Lancourt, J. E., Glenn, W. V., jr., Wiltse, L. L.: Multiplanar computerized tomography in the normal spine and in the diagnosis of spinal stenosis: a gross anatomic-computerized tomographic correlation. *Spine* 4, 379-390 (1979).
- Le Vay, D.: A survey of surgical management of lumbar disc prolapse in the United Kingdom and Eire. *Lancet* 1, 1211-1213 (1967).
- Lin, P. M., Gill, K.: Lumbar interbody fusion, pp. 1-271. Rockville, Maryland, Royal Tunbridge Wells: Aspen Publishers Inc. 1989.
- Lindblom, K.: Diagnostic puncture of intervertebral discs in sciatica. *Acta Orthop. Scand.* 17, 231-239 (1948).
- Lowther, D. A., Baxter, E.: Isolation of a chondroitin sulphate protein complex from bovine intervertebral discs. *Nature (Lond.)* 211, 595-597 (1966).
- Lowther, D. A. (Monash University, Melbourne): Personal communication, 1972.

328 References

- MacCartee, C. C., Griffin, P. P., Byrd, B. E.: Ruptured calcified thoracic disc in a child. *J. Bone Joint Surg.* 54A, 1272-1274 (1972).
- McKenzie, J. A., Williams, J. F.: The dynamic behaviour of the head and cervical spine during "whiplash". *J. Biomech.* 4, 477-490 (1971).
- Macnab, I.: Acceleration-extension injuries of the cervical spine. In: American Academy of Orthopaedic Surgeons Symposium on the Spine, p. 16. St. Louis: C. V. Mosby. 1969.
- Macnab, I.: Chemonucleolysis. *Clin. Neurosurg.* 20, 183-192 (1973).
- Macnab, I.: Backache. Baltimore: Williams & Wilkins. 1977.
- Macnab, I., McCulloch, J. A., Weiner, D. S., Hugo, E. P., Galway, R. D., Dall, D.: Chemonucleolysis. *Can. J. Surg.* 14, 280-289 (1971).
- Maroudras, A., Nachemson, A., Stockwell, R. A.: Factors involved in the nutrition of the adult human intervertebral disc. *J. Bone Joint Surg.* 55A, 658-659 (1973).
- Mathews, J. A.: Epidurography. In: Modern trends in orthopaedics, pp. 148-166. London: Butterworths. 1972.
- Matsubara, T., Karube, F., Terashima, I.: Atypical course observed following discography - cases of discitis and disappearing backache. *J. Orthop. Surg. (Tokyo)* 17, 124-130 (1966).
- Matsuda, H. M., Hirose, T., Shimazu, A., Yoshimura, M., Yamano, Y., Nakajima, K.: Electro-neurophysiological diagnosis by the approach from single nerve root unit in the degenerative spondylolisthesis. *Osaka City Med. J.* 23, 155-165 (1977).
- Matsuda, H., Hirose, T., Hashimoto, T., Shimazu, A., Yamano, Y., Nakajima, K.: Electro-diagnosis of compression of individual nerve roots of the cauda equina. *Intern. Orthop.* 2, 121-131 (1979).
- Mayer, H. M., Brock, M.: Percutaneous lumbar disectomy, pp. 1-218. Berlin-Heidelberg-New York: Springer. 1989.
- McCulloch, J. A.: Chemonucleolysis. *J. Bone Joint Surg.* 59B, 45-52 (1977).
- McCulloch, J. A., Macnab, I.: Sciatica and Chymopapain, pp. 1-225. Baltimore-London: Williams and Wilkins. 1983.
- McCulloch, J. A.: Principles of micro surgery for lumbar disc disease, pp. 1-307. New York: Raven Press. 1989.
- Med. J. Aust. (Editorial): Comments on: Backache and sciatica: a new breakthrough or a new controversy? *Med. J. Aust.* 1, 3 (1974).
- Mercer, R., Duthie, R. B.: Orthopaedic surgery, 6th ed. London: Edward Arnold. 1964.
- Miller, H.: Accident neurosis. *Brit. Med. J.* 1, 919-925 (1961).
- Mitchell, P. E. G., Hendry, N. G. C., Billewicz, W. Z.: The chemical background of intervertebral disc prolapse. *J. Bone Joint Surg.* 43B, 141-151 (1961).
- Mixter, W. J., Barr, J. S.: Rupture of the intervertebral disc with involvement of the spinal canal. *New Engl. J. Med.* 211, 210-215 (1934).
- Moll, J., Wright, T. V.: Measurement of spinal movement. In: The lumbar spine and back pain (Jayson, M., ed.), pp. 93-112. London: Sector Publishing. 1976.
- Morgan, F. P., King, T.: Primary vertebral instability as a cause of low back pain. *J. Bone Joint Surg.* 39B, 6-22 (1957).
- Murphey, F., Simmons, J. H. C., Brunson, B.: Surgical treatment of laterally ruptured cervical disc. Review of 648 cases, 1939-1972. *J. Neurosurg.* 38, 679-683 (1973).
- Murphey, M. G., Gado, M.: Anterior cervical disectomy without interbody bone graft. *J. Neurosurg.* 37, 71-74 (1972).
- Nachemson, A.: Mechanical stresses on lumbar disks. In: Current practice in orthopaedic surgery, pp. 208-224. St. Louis: C. V. Mosby. 1966.
- Nachemson, A.: Intradiscal measurements of pH in patients with lumbar rhizopathies. *Acta Orthop. Scand.* 40, 23-42 (1969).
- Nachemson, A. L.: The lumbar spine an orthopaedic challenge. *Spine* 1, 59-71 (1976).
- Nachemson, A.: Editorial comment. Lumbar discography - where are we today? *Spine* 14, 555-557 (1989).

- Nachemson, A., Morris, J. M.: In vivo measurements of intradiscal pressure. *J. Bone Joint Surg.* 46A, 1077-1092 (1964).
- Nashbold, B. S., Hrubec, Z.: Lumbar disc disease: a twenty year follow-up study. St. Louis: C. V. Mosby. 1971.
- Naylor, A.: The biophysiological and biochemical aspects of intervertebral disc herniation and degeneration. *Ann. Roy. Coll. Surg. Engl.* 31, 91-114 (1962).
- Naylor, A.: The late results of laminectomy for lumbar disc prolapse. *J. Bone Joint Surg.* 56B, 17-29 (1974).
- Naylor, A., Happey, F., Turner, R. L., Shentall, R. D., West, D. C., Richardson, C.: Enzymic and immunological activity in the intervertebral disc. *Orthop. Clin. North Am.* 6, 51-58 (1976).
- Newman, P. H.: Surgical treatment for derangement of the lumbar spine. *J. Bone Joint Surg.* 55B, 7-19 (1973).
- Nixon, J. E. (ed.): Spinal stenosis, pp. 1-401. London: Edward Arnold. 1991.
- Northfield, D. W. C., Osmond-Clarke, H.: Surgical treatment. In: Cervical spondylosis (Brain, R., Wilkinson, M., eds.), p. 215. London: W. Heinemann. 1967.
- O'Connell, J. E. A.: Maternal obstetrical paralysis. *Surg. Gynec. Obstet.* 79, 374-382 (1944).
- O'Connell, J. E. A.: Protrusions of the lumbar intervertebral discs. A clinical review based on five hundred cases treated by excision of the protrusion. *J. Bone Joint Surg.* 33B, 8-30 (1951).
- Ohki, K.: Biochemical studies on lumbar disc lesions, changes in the protein-polysaccharide complex. *J. Jap. Orthop. Ass.* 48, 567-579 (1974).
- Olerud, S., Karlstrom, G., Sjostrom, L.: Transpedicular fixation of thoracolumbar vertebral fractures. In: Clinical orthopaedics and related research, Vol. 227, pp. 44-50. Philadelphia: J. B. Lippincott. 1988.
- Olmaker, K.: Spinal nerve root compression, studies from the laboratory of experimental biology, departments of anatomy and orthopaedics, Sahlgren Hospital. University of Goteborg, Sweden. 1990.
- Ooi, Y., Mita, F., Sato, Y.: Myeloscopic study on lumbar spinal canal stenosis with special reference to intermittent claudication. *Spine* 15, 544-549 (1990).
- Paine, K. W. E., Haug, P. W. H.: Lumbar disc syndrome. *J. Neurosurg.* 37, 75-82 (1972).
- Palmer, J. J.: Spinal arachnoid cysts. *J. Neurosurg.* 41, 728-735 (1974).
- Pankovich, A. M., Korngold, L.: A comparison of the antigenic properties of the nucleus pulposus and cartilage protein polysaccharide complexes. *J. Immunol.* 99, 431-437 (1967).
- Parke, W., Gammel, K., Rothman, R. H.: Arterial vascularization of the cauda equina. *J. Bone Joint Surg.* 63A, 53-61 (1981).
- Parker, N.: Malingering. *Med. J. Aust.* 2, 1308-1311 (1972).
- Paulson, S., Sylven, B., Hirsch, C., Snellman, O.: Biophysical and physiological investigations on cartilage and other mesenchymal tissues. The diffusion rate of various substances in normal bovine nucleus pulposus. *Biochim. Biophys. Acta (Amst.)* 7, 207-213 (1951).
- Peacock, A.: Observations on the post-natal structure of the intervertebral disc in man. *J. Anat. (Lond.)* 86, 162-179 (1952).
- Peck, F. C., Jr.: A calcified thoracic intervertebral disk with herniation and spinal cord compression in a child. Case report. *J. Neurosurg.* 14, 105-109 (1957).
- Penning, L.: Functional pathology of the cervical spine. Amsterdam: Excerpta Medica. 1968.
- Pennybacker, J. (Oxford University): Personal communication, 1959.
- Perot, P. L., Munro, D. D.: Transthoracic removal of mid-line thoracic disc protrusions causing spinal cord compression. *J. Neurosurg.* 31, 452-458 (1969).
- Postaccini, F.: Lumbar spinal stenosis, pp 1-240. Wien: Springer. Bologna: Aulogaggi. 1989.
- Putti, V.: New conceptions in the pathogenesis of sciatic pain. *Lancet* 2, 53-60 (1927).
- Ransford, A. O., Harries, B. J.: Localized arachnoiditis complicating lumbar disc lesions. *J. Bone Joint Surg.* 54B, 656-665 (1972).

330 References

- Rathke, F. H., Schlegel, K. F.: Surgery of the spine. In: Atlas of orthopaedic operations (Hackenbroch, M., Witt, A. N., eds.), Vol. 1. Stuttgart: G. Thieme. 1979.
- Reynolds, F. C., Katz, S. F.: Herniated lumbar intervertebral disc. In: American Academy of Orthopaedic Surgeons Symposium on the Spine, pp. 84–96. St. Louis: C. V. Mosby. 1969.
- Riley, L. H., Robinson, R. A., Johnson, K. A., Walker, A. E.: The results of anterior interbody fusion of the cervical spine. Review of 93 consecutive cases. *J. Neurosurg.* 30, 127–133 (1969).
- Robinson, R. A., Smith, G. W.: Anterolateral cervical disc removal and interbody fusion for cervical disc syndrome. *Bull. Johns Hopkins Hospital* 96, 223–224 (1955).
- Robinson, R. A., Walker, A. E., Ferlic, D. C., Wiecking, D. K.: The results of anterior interbody fusion of the cervical spine. *J. Bone Joint Surg.* 44A, 1569–1587 (1962).
- Rothman, R. H., Simeone, F. A.: The spine, Vol. II. Philadelphia: W. B. Saunders. 1975.
- Roy-Camille, R., Lazennec, J. Y., Garreau, C., Saillant, G.: Grade three and grade four L5/S1 spondylolisthesis: Surgical reduction and fixation through a posterior approach about 29 cases. *Rachis* 3, 147–158 (1991).
- Sacks, S.: Anterior interbody fusion of the lumbar spine. *J. Bone Joint Surg.* 47B, 211–233 (1965).
- Sarpyener, M. A.: Congenital stricture of the spinal canal. *J. Bone Joint Surg.* 27, 70–79 (1945).
- Schatzker, J., Pennal, G. F.: Spinal stenosis, a cause of cauda equina compression. *J. Bone Joint Surg.* 50B, 606–618 (1968).
- Schmorl, G.: Die pathologische Anatomie der Wirbelsäule. *Verh. Dtsch. Orthop. Ges.* 21, 3–41 (1926).
- Schmorl, G., Junghanns, H.: The human spine in health and disease (translated by Wilk, S. P., Groin, L. S.), p. 38. New York: Grune and Stratton. 1959.
- Scott, J. H. S.: The Edinburgh repair of isthmic (Group 2) spondylolysis. *J. Bone Joint Surg.* 69B, 491 (1987).
- Selby, D. K., Henderson, R. J.: Circumferential (360 degree) spinal fusion. In: The adult spine principles and practice (Frymoyer, J. W., ed.), pp. 1989–2006. New York: Raven Press. 1991.
- Simeone, F. A.: The modern treatment of thoracic disc disease. *Orthop. Clin. North Am.* 2, 453–462 (1971).
- Simpson, J. A.: Electromyography. In: Scientific Foundations of Neurology, pp. 341–356. London: W. Heinemann. 1972.
- Smith, B. H.: Clinical spondylosis and its neurological complications. Springfield, Ill.: Ch. C. Thomas. 1968.
- Smith, J. W., Serafini-Fracassini, A.: The distribution of the protein polysaccharide complex in the nucleus pulposus matrix in young rabbits. *J. Cell. Sci.* 3, 33–40 (1968).
- Smith, L., Brown, J. E.: Treatment of lumbar intervertebral disc lesions by direct injection of chymopapain. *J. Bone Joint Surg.* 49B, 502–519 (1967).
- Sonnabend, D. H., Taylor, T. K. F., Chapman, G. K.: Intervertebral disc calcification syndromes in children. *J. Bone Joint Surg.* 64B, 25–31 (1982).
- Spangfort, E. V.: The lumbar disc herniation. *Acta Orthop. Scand., Suppl.* 142, 1–95 (1972).
- Spurling, R. G., Grantham, E. G.: The end results of surgery for ruptured lumbar intervertebral discs. A follow-up study of 327 cases. *J. Neurosurg.* 6, 57–64 (1949).
- Stauffer, R. N., Coventry, M. B.: Anterior interbody lumbar spine fusion. Analysis of Mayo Clinic series. *J. Bone Joint Surg.* 54A, 756–768 (1972).
- Stauffer, R. N., Coventry, M. B.: Posterolateral lumbar spine fusion. Analysis of Mayo Clinic series. *J. Bone Joint Surg.* 54A, 1195–1204 (1972).
- Stevenson, H. G.: Back injury and depression – a medico-legal problem. *Med. J. Aust.* 1, 1300–1302 (1970).
- Stewart, D. Y.: Current concepts of the “Barré syndrome” or the “posterior cervical sympathetic syndrome”. *Clin. Orthop.* 24, 40–48 (1962).

- Tan, S. B., Kozak, J. A., Graham, J. M.: A modified technique of anterior lumbar fusion with femoral cortical allograft. *J. Orthop. Surg. Techn.* 5, 83-93 (1990).
- Taylor, T. K. F., Akeson, W. H.: Intervertebral disc prolapse: a review of morphologic and biochemic knowledge concerning the nature of prolapse. *Clin. Orthop.* 76, 54-79 (1971).
- Torgerson, W. R., Dotter, W. E.: Comparative roentgenographic study of the asymptomatic and symptomatic lumbar spine. *J. Bone Joint Surg.* 58A, 850-853 (1976).
- Tsuji, H.: Comprehensive atlas of lumbar spine surgery. Mosby year book (1991).
- Van Akkerveeken, P. F.: Diagnosis and neuromechanisms: Pain patterns and diagnostic blocks. In: *The Lumbar Spine, Chapter 3* (Editorial committee - Weinstein, J. N. and Wiesel, S. W.). W. B. Saunders Company - Harcourt Brace Jovanovich, Inc. 1990.
- Venner, R. M., Crock, H. V.: Clinical studies of isolated disc resorption in the lumbar spine. *J. Bone Joint Surg.* 63B, 491-494 (1981).
- Verbiest, H.: A radicular syndrome from developmental narrowing of the lumbar vertebral canal. *J. Bone Joint Surg.* 36B, 230-237 (1954).
- Verbiest, H.: Further experience of the pathological influence of a developmental narrowness of the bony lumbar vertebral canal. *J. Bone Joint Surg.* 37B, 576-583 (1955).
- Verbiest, H.: The lateral approach to the cervical spine. *Clin. Neurosurg.* 20, 295-305 (1973).
- Verbiest, H.: Neurogenic intermittent claudication. Amsterdam: North-Holland. 1976.
- Vogelsang, H.: Intraosseous spinal venography. Amsterdam: Excerpta Medica. 1970.
- von Torklus, D., Gehle, W.: The upper cervical spine. London: Butterworths. 1972.
- Waddell, G., Kummel, E. G., Lotto, W. N., Graham, J. D., Hall, H., McCulloch, J. A.: Failed lumbar disc surgery and repeat surgery following industrial injuries. *J. Bone Joint Surg.* 61A, 201-206 (1979).
- Waddell, G., McCulloch, J. A., Kummel, E., Venner, R. M.: Nonorganic physical signs in low-back pain. *Spine* 5, 117-125 (1980).
- Watkins, M. B.: Postero-lateral bone grafting for fusion of the lumbar and lumbo-sacral spine. *J. Bone Joint Surg.* 41A, 388-396 (1959).
- Weinstein, P. R., Ehni, G., Wilson, C. B.: Lumbar spondylosis: diagnosis, management and surgical treatment. Chicago: Year Book Medical Publishers. 1977.
- White, A. A., Southwick, W. O., Deponte, R. J., Gainor, J. W., Hardy, R.: Relief of pain by anterior cervical spine fusion for spondylosis: report of 65 patients. *J. Bone Joint Surg.* 55A, 525-534 (1973).
- Williams, P. C.: Reduced lumbosacral joint space: its relation to sciatic irritation. *JAMA* 99, 1677-1682 (1932).
- Wilson, P. H., MacCarty, W. C.: Discography: its role in the diagnosis of lumbar disc protrusion. *J. Neurosurg.* 31, 520-523 (1969).
- Wiltberger, B. R.: The dowel intervertebral body fusion as used in lumbar disc surgery. *J. Bone Joint Surg.* 39A, 284-292 (1957).
- Wiltberger, B. R., Abbott, K. H.: Dowel intervertebral body fusion as used in lumbar disc therapy. *J. Int. Coll. Surg.* 29, 204-213 (1958).
- Wiltse, L. L.: Spondylolisthesis in children. *Clin. Orthop.* 21, 156-163 (1961).
- Wiltse, L. L.: The etiology of spondylolisthesis. *J. Bone Joint Surg.* 44A, 539-560 (1962).
- Wiltse, L. L.: Common problems of the lumbar spine: spondylolisthesis and its treatment. *JCE Orthop.* 7, 13-31 (1979).
- Wiltse, L. L.: Long term follow up of high grade spondylolisthesis treated by in-situ alar transverse fusions without spinal canal decompression. Video Presentation at 5th Annual Meeting, North American Spine Society, Monterey, California, August 1990.
- Wiltse, L. L., Bateman, J. G., Hutchinson, R. H., Nelson, W. E.: The paraspinous sacrospinalis-splitting approach to the lumbar spine. *J. Bone Joint Surg.* 50A, 919-926 (1968).
- Wiltse, L. L., Hutchinson, R. H.: Surgical treatment of spondylolisthesis. *Clin. Orthop.* 35, 116-135 (1964).

332 References

- Wiltse, L. L., Rocchio, P. D.: Preoperative psychological tests as predictors of success of chemonucleolysis in the treatment of the low-back syndrome. *J. Bone Joint Surg.* 57A, 478-483 (1975).
- Wiltse, L. L., Widell, E. H., Jr., Jackson, D. W.: Fatigue fracture: the basic lesion in isthmic spondylolisthesis. *J. Bone Joint Surg.* 57A, 17-22 (1975).
- Wullenweber, R., Brock, M., Hamer, J., Klinger, M., Spoerri, O.: Lumbar disc. Adult hydrocephalus. (*Advances in Neurosurgery*, Vol. 4.) Berlin-Heidelberg-New York: Springer, 1977.
- Yoshizawa, H., O'Brien, J. P., Smith, W. T., Trumper, M.: The neuropathology of intervertebral discs removed for low-back pain. *J. Path.* 132, 95-104 (1980).
- Zilkens, K.W., Peters, B., Schwanitz, B.: Biochemical markers for an earlier detection of spinal infections. Paper presented to the European Spine Society, Rome, 1991.

Subject Index

- Abdominal incisions 81–85, 311
- Abscesses
 - drainage of 280
- Acquired canal stenosis 311
- Acquired disc resorption 300
- Adhesions 303
- Air embolism 268
- Anatomy
 - of lumbar spine 13–21, 50–59, 176, 177, 198, 208, 209
- Anterior cervical interbody fusion
 - for cervical myelopathy 248, 250, 261, 262
 - for disc prolapse 226
 - for failed cervical fusion 312
 - for failed cervical stabilization with titanium implant 252, 254
 - for internal disc disruption 229
 - for vertebral fractures 229
- Anterior lumbar interbody fusion
 - for internal disc disruption 71–75, 80
 - for isolated disc resorption 28
 - for spondylolisthesis 80, 168
 - for spondyloptosis 161, 170, 172–174
- Anterior lumbar interbody fusion
 - combined with posterior fusion and internal fixation 311
 - supplementary to failed posterior fusion 311
- Anterior thoracic interbody fusion
 - for disc prolapse 114, 121
 - for internal disc disruption 53
 - for nucleus pulposus calcification 151, 153
- Anticoagulant therapy 318
- Anxiety state, acute 46
- Arachnoiditis of the cauda equina 205, 206, 213, 303, 308
- Arachnoiditis ossificans 217
- Autogenous bone grafts 91, 171, 178, 252, 258
- Auto-immunity 49
- Bath-tub sign 109
- Bed, vertically-tilting, for post-operative care 94
- Blood supply of muscle and nerve root 132
- Body weight loss 46
- Bone cement 94
- Bone graft substitutes 252
- Bone wax, use of 133, 144, 211
- Burst fractures, management of 229
- Capsular fibres, of facet joints 133, 134, 136
- Cauda equina
 - anatomy of 208
 - arachnoiditis of 205, 206, 213
 - arteries of 188
 - dysfunction in lumbar spinal stenosis 187, 188, 191, 192
 - dysfunction in spondylolisthesis 161
 - vascular supply of 188–192
 - veins of 189, 190, 191, 192
- Ceramic dowels 252
- Ceramic spacers 94
- Cerebrospinal fluid fistula 145, 318
- Cervical canal stenosis
 - anterior decompression and interbody fusion 248, 250, 261, 262
 - laminoplasty 272
- Cervical discography 227, 236

334 Subject Index

Cervical laminectomy 219, 267
 laminal pars interarticularis preservation,
 in cervical canal laminectomy 271
Cervical myelopathy 225, 232
Cervical spine
 anatomy 220, 228, 234, 242, 244, 247,
 268-271
 anterior interbody fusion
 for cervical disc prolapse 225
 for cervical spondylosis 219
 for internal disc disruption 225
 for post-surgical kyphosis 229
 for post-traumatic vertebral
 instability 229
 CT 224, 250, 253
 discography 229, 236
 external splinting of 250, 251, 257, 258, 263
 internal fixation of
 with plates and screws 228
 with sublaminar wires 232
 with trans-articular screws 230
 MRI 224, 226, 262
 plain X-ray 221-223, 230, 232, 233, 235,
 249, 254, 259, 260, 261, 266
 posterior fusion of 221, 263, 265
 tomography 231, 253
Chymopapain, injection of 121
Collars, cervical 250, 251, 257-259
Control X-rays, on theatre table 81
Counselling 321
CSF examination 119
CT 1, 27, 68, 147, 156, 202, 258
CT discography 53, 143
CT radiculography 109, 312, 314
CT three dimensional 203
Curettage of disc space 141, 308
Cysts, extradural arachnoid of the Schreiber
 type 36
Cysts, peri-neural of the Tarlov type 36

Decompression of spinal canal
 cervical 248, 250, 261, 262
 lumbar 204, 205, 207, 209-212
 thoracic 217
Degenerative disease of the spine, multilevel
 316
Degenerative spondylolisthesis 159
Depressive illness 47
Discitis 71, 299
Disc intervertebral
 calcification
 acute nucleus pulposus 80, 147
 adjacent to previously fused spinal
 segment 314

 in adults 149-153
 in children 148
 paraplegia, in 147
disruption
 internal, lumbar 46, 50
 post-traumatic, cervical, thoracic 53,
 61, 225, 229
prolapse 105-108, 142, 314
 instruments for surgical treatment of
 disc prolapses 126, 134, 136, 137,
 141
 investigations
 CSF examination 119
 discography 119
 electro-diagnostic 119
 intraosseous spinal venography
 119
 MRI 109-114
 myelography 115-118
 plain X-ray 109
treatment
 surgical, cervical 121, 225, 226
 anterior interbody fusion 219, 237,
 240, 241
 cervical laminectomy 219
 surgical, lumbar 120
 bilateral and nerve root canal
 decompression 143
 chymopapain injection 121, 122
 disc fragment excision 120
 disc space curettage 120
 micro-discectomy and percuta-
 neous discectomy 120
 posterior interbody fusion 120
 postero-lateral inter-transverse
 fusion 120
 surgical, thoracic 114, 121, 216
 transthoracic disc excision and
 interbody fusion 114, 121, 216
types
 above or below a fused spinal segment
 314
 central 106
 contained 106
 extraforaminal herniation 113, 143
 intraforaminal herniation 110, 111
 intraspongous disc herniation 107
 sequestered 106, 116-118
 upper lumbar 142
 resorption, isolated 1-9, 12, 21-23
Disc nutrition, mechanism of 48
Discography 65, 71, 119, 121, 166, 310
Dowel cavities, preparation of 88, 243
Dowel grafts 72-74

- Drugs 319, 321
 Dural injury 137, 144, 303, 308
 Dural opening 213, 303, 318
 Dural tears, small 308
 Dysphagia, in cervical spondylosis 225
- Ectopic ossification 297
 Electrodiagnostic tests 119
 Epidural abscess 234, 310, 314
 Epidural fat 16, 18, 19, 30
 Epidural venous system 20, 122, 131
 Exposure of lumbar spinal canal 127–131
 Extensor mechanism of spine 127
 Extra-foraminal disc prolapse 143
 Extra-peritoneal approaches
 left-sided 82
 right-sided 311
 Extra-peritoneal approaches to spine 72–81
- Facet joint subluxation 11, 24, 229
 Failed spinal operations 80, 297, 299, 300, 311
 management of 291, 292
 Foraminal stenosis 27, 181, 183, 184
 Fracture dislocations
 of cervical spine 229
 infected lesions in 274, 278, 280, 282, 284,
 285
 Fusion at the wrong level 310, 314
- Gadolinium enhancement 27, 111, 140
 Gas gangrene 314
 Gelfoam 144
 Gill and White operation 183
 Grafts
 ceramic 94, 252, 253
 iliac
 for cervical fusion 256
 for lumbar fusion 73, 74, 178, 182
 for thoracic fusion 218
 rib 218
 strut 252
 titanium mesh 252, 254, 255
 Graft bone, preparation of 91, 178, 252
 Graft donor site problems 181
 Graft impaction 93, 96, 255, 256
 Graft, non-union of 96
 Graft overgrowth 310
 Graft resorption 120
 Graft unwanted 178, 181, 312
- Haemostasis 86, 144, 213, 318
 High-speed drill, with diamond-tipped burr
 249, 303
 Hypertrophy of posterior fusions 312
- Iliac crest
 fractures 98, 182
 grafts cervical 256
 grafts lumbar 73, 74, 178, 182
 infection 182
 superior gluteal artery, haemorrhage 182
- Infections 145
 after anterior interbody fusion 264, 314
 graft site 97
 post-operative, see Wound infections
 unrecognized epidural 310
- Inflammatory disorders of cervical spine
 thoracic spine, lumbar spine 232–234
- Internal disc disruption, cervical 225
 Internal disc disruption, thoracic and lumbar
 45–104
 clinical features 45–48
 investigations 62–71
 discography 65–70
 MRI 63, 64
 plain X-ray 62
 radiculography 71
 venography 79, 88
 pathology 48–50, 60–62
 surgical treatment 71–95
 bilateral foraminal and nerve root
 canal decompressions 27–35, 75
 interbody fusion 71–75
 posterior spinal fusion 76
 vascular anatomy of vertebral bodies
 50–59
- Intertransverse alar fusions 174, 175, 177–
 180
- Intervertebral disc, see Disc
- Instruments 30–33, 35, 72, 73, 85, 87, 89, 90,
 92, 125, 126, 134–136, 237–240, 303
- Laminar pseudarthroses
 atrophy of, following spinal fusion 300,
 310
 excision of 183, 184
 identification of, in re-exploration of
 lumbar spine 307
 repair of 185
- Ligamentum flavum 14, 16, 17
 anatomy
 cervical 271
 lumbar 134, 136
 unfolding of 21
- Ligaments
 interspinous 33
 supraspinous 33
- Lumbar arteries 10, 11, 19, 50–55, 58, 76–78,
 84, 127, 130, 132, 133, 143, 188, 304

336 Subject Index

- Lumbar nerve roots, anatomy of 13, 14, 18–20
- Lumbar spinal canal
 - anatomy 13–21, 50–59, 176, 177, 198, 208, 209
 - exposure 127–131
 - stenosis of 187, 192
- Lumbar veins 20–22, 34, 56–59, 77–79, 84, 87, 95, 131
- Lumbo-dorsal fascia 127–129, 144
- Meningocele 297, 303, 304, 308
- Meralgia paraesthetica 97
- Microdiscectomy 128, 143
- MRI 1, 25, 45, 63, 71, 109, 140, 143, 147, 166, 170, 203, 279, 310, 312, 314
 - in cervical myelopathy 258
 - in multilevel cervical canal stenosis 272
 - with gadolinium enhancement 119, 237
- Muscles
 - abdominal 83, 84
 - cervical paraspinal 242
 - lumbar paraspinal 16, 80, 127, 129–132, 176
 - posterior cervical 268–270
 - trunk 128
- Myelography 41, 115, 167, 203, 277, 311
- Myelopathy 191
- Myeloscopy 187
- Needle biopsy 7, 279
- Negative laminectomy 71, 77
- Nerve conduction defects 24
- Nerve root
 - anatomy 13
 - claudication 23
 - injury 19
 - irritation 181
 - oedema 11
- Nerve root canal 1–43
 - anatomy
 - arterial and venous 19, 20
 - normal 13–19
 - pathological 21–24
 - operations 27
 - bilateral nerve root canal and foraminal decompression 27–35, 75
 - disc fragment excision 27
 - spinal fusion 28
 - technique 30
 - venous obstruction 19, 20
 - stenosis 1
 - clinical features 103
 - in isolated disc resorption 1
 - investigations
 - CT 9
 - 'flat tyre' effect 25
 - MRI 7, 8, 25
 - radiculography 12, 25
 - X-ray 3, 4
 - miscellaneous causes of 36–43
- Neurosis 46
- Non-prolapsing disc disorders 1, 44, 45, 104
- Nucleolysis, complications of 122
- Nucleus pulposus calcification 80, 147, 149, 150–153, 314
- Operating loop 139
- Osteoarthritis, unilateral facet 41
- Osteomyelitis, see Vertebral osteomyelitis
- Ostium, in meningoceles 308
- Pain, severe spinal 148
- Paraplegia
 - following calcified disc prolapse 147
 - following chymopapain injection 122
- Paraspinal muscles, separation of 127
- Paraspinal muscle spasm 156
- Pars interarticularis
 - defects of
 - in spondylolisthesis 159, 160, 163–165, 169, 170, 183, 184
 - in spondylolysis 163
 - in spondylolysis acquisita 316
 - preservation of, in decompression surgery 212
 - vascular relations of 14, 33, 130–133, 191
- Pedicle screw system for vertebral fixation
 - complications of 215
 - in degenerative spondylolisthesis 214
 - in spondyloptosis 170, 172–174
- Pedicle vein bleeding 185
- Percutaneous lumbar discectomy 143
- Periosteum of the lamina 127
- Post-discogram discitis 71
- Posterior cervical spinal fusion 219, 265
- Posterior fusion or inter-transverse alar fusion 76, 167
- Posterior interbody fusion 120, 173
- Posterior longitudinal ligament, ossification of 217
- Posterior lumbar interbody fusion
 - for disc sequestration 118
 - for isolated disc resorption 28
- Postero-lateral inter-transverse alar fusion 174
 - technique of 174
- Postero-lateral inter-transverse fusion 120

- Pre-vertebral abscesses 265
 Prolapse, see Disc intervertebral
 Prophylactic anticoagulant therapy 96
 Psychiatric disturbances 46, 47
 Punctate lesions, of vertebral end-plate 27
- Quadripareisis 265
 Quadriplegia 122
- Radicular arteries 188
 Radicular veins, retrograde venous distension of 187
 Radiculography 11, 25, 71, 203
 with CT 202
 Radiological changes after cervical interbody fusion 258
 "Rattlers", in spondylolisthesis 164, 165, 183
 Recurrence of sciatica 120, 142
 Re-exploration of the spine following spinal fusion operations 310
 Re-opening the spinal canal 306
 Retention of urine 94
 Retractor application, timing of 304
 Retrolisthesis
 in disc resorption 4, 41
 Retro-peritoneal fibrosis 86
 Rheumatoid arthritis 232
 Root oedema 41, 111
- Sacralization anomalies 5, 41, 88
 Sacro-spinalis aponeurosis 127-129
 Scar formation 307
 Selection of levels for decompression 204
 Self-retaining retractors 130
 Sequestered disc fragments 108, 139, 140, 217
 Spinal cord tumours 219
 Spinal injuries 229
 Spinal manipulations 77
 Spinal stenosis
 arachnoiditis of the cauda equina, in lumbar canal stenosis 213
 cervical 219, 222, 224, 232, 234
 investigations
 CT and CT radiculography 199, 202
 electrodiagnostic 119
 MRI 203, 216
 myeloscapy 192
 plain X-ray 194, 196
 radiculography 193-195, 200, 201
 tomography 212
 lumbar 187, 192
- lumbar canal decompression 204, 205, 207, 209-212
 pedicle screw fixation devices with
 facet fusions
 intertransverse fusions 215
 posterior interbody fusions 215
 thoracic 187
 thoracic canal decompression 217
 wound closure following lumbar canal decompression 215
- Spinous process
 arteries of 130, 132
 excision of
 in lumbar spinal canal decompressions 212
 preservation of
 in lumbar spinal canal decompressions 32, 209-211
 in laminal pseudarthrosis excisions 184
 veins of 131
- Spondylolisthesis 65, 80, 86, 142, 159, 292
 anterior interbody fusion in 80
 definition of "rattler" in 164, 165
 disc prolapse in 142
 discography in 65, 168, 170
 failed operations in 162, 292
 Gill and White operation 183
 Graf operation for 80
 inter-transverse alar fusions 175, 177-180
 investigations
 discography 163, 168
 MRI 161, 166, 172
 plain X-ray 160, 162, 164, 169, 170, 172, 180
 tomography 167, 168, 179
 laminal pseudarthrosis excision 183, 184
 laminal pseudarthrosis repair 185
 natural history of 159
 postero-lateral inter-transverse alar fusion 174
 removal of "rattler" in 165, 183
 surgical treatment of 159, 160, 163-165, 169, 170, 183, 184, 292
 transperitoneal approach for anterior interbody fusion 86
- Spondyloptosis 161
 implant failure in 172
 reduction with pedicle screws 170, 172-174
 spinal deformity in 171
- Spondylolysis acquisita 316
 Strut grafts 252
 Sub-acute bacterial endocarditis 273

338 Subject Index

- Sub-arachnoid haemorrhage 122
- Subcutaneous fat layer 127
- Subluxation, see Facet joint
- Subluxation of vertebra 234
- Supra-spinous ligaments 16, 145
- Surgery, positioning for 81, 122-125, 175, 237, 241, 267
- Synchronous combined anterior and posterior spinal fusion with internal fixation 316
- Thoracic canal decompression 217
- Thoracic disc prolapse 121, 217
- Thrombus, deep vein 96
- Thyroid gland 243
- Titanium mesh implants 252
- Tomography 28, 29, 61, 64, 70, 101-103, 151, 167, 168, 179, 212, 231, 275, 276, 280, 282, 283, 294, 298, 299, 302, 315
- Trans-dural approach 141
- Trans-dural disc fragment excision 308
- Trans-oral decompression 232
- Tuberculosis of the spine 234, 281
- Ulnar neuritis 122
- Unilateral inter-laminar approach 120
- Unilateral sciatica 5, 142
- Upper lumbar disc 142, 156
- Vascular anatomy of the spine 19-22, 50-59, 75-79, 87, 95, 130-133, 188-192, 210, 220, 234, 242, 247
- Vascular penetration of the graft 96
- Vascularisation, of interbody grafts 75
- Venous drainage of vertebral bodies 53
- Venous haemorrhage 19, 30, 138, 183, 185 management 138
- Venous obstruction 11, 19, 23, 188, 213
- Vertebra
 - dimensions, cervical 244
 - dimensions, lumbar 91
- Vertebral biopsy 7, 279
- Vertebral instability 28, 120, 215, 229
- Vertebral osteomyelitis 71, 264
 - acute 273-275
 - chronic 276
 - clinical findings 277
 - investigations 277
 - CT 277
 - MRI 279
 - Myelography 277, 278
 - Needle biopsy 279
 - spinal deformities in 277, 278, 280, 282, 284, 285
 - treatment 280
 - tuberculosis 281-286
- Vertebral venography 79, 88
- Warm pool therapy 318
- Water-soluble myelographic media 115
- Watson Cheyne dissector 135
- Wax, bone, use of 133, 144, 211
- Whiplash injury of neck 225, 228
- Wiltse, paraspinous muscle splitting incision 175
- Wound closure 144, 215, 255, 310
- Wound infections
 - post-operative 145, 286-289, 310, 314
 - treatment of 287, 288
- Wry neck 148
- X-rays
 - in disc calcification 147
 - in disc prolapse 109
 - in internal disc disruption 62
 - in isolated disc resorption 41
 - in spinal canal stenosis 202
 - in vertebral osteomyelitis 277
 - plain 24
 - tomography 28, 29, 61, 64, 70, 101-103, 151, 167, 168, 179, 212, 231, 275, 276, 280, 282, 283, 294, 298, 299, 302, 315

Herbert Resch, Emil Beck (eds.)

Arthroscopy of the Shoulder

Diagnosis and Therapy

Translated from the German
by Marie-Louise Antoft and Brigitte Marschall

1992. 125 figs. Approx. 200 pages
Cloth DM 198,-, öS 1386,-
ISBN 3-211-82339-5

Prices are subject to change without notice

This book focuses on arthroscopy of the shoulder joint and the subacromial space. Diagnosis as well as the current therapeutic possibilities are described in explicit detail. The book begins with describing the anatomy of the shoulder joint from an arthroscopic viewpoint. The diagnostic part gives a description of the individual structures in the glenohumeral joint as well as the subacromial space with regard to their pathologic changes and special attention is focused on differentiating between healthy and pathologic structures. The therapeutic part gives a detailed description of the Bankart refixation methods successfully applied by the authors which include a suturing technique, a refixation technique using absorbable tacks and an extraarticular screw fixation technique; furthermore the techniques of subacromial decompression, removal of a calcium deposits and the resection of the lateral end of the clavicle are described in detail. Starting with the indication for arthroscopy and/or arthroscopic therapy, the book then conveys information on positioning, draping, necessary instruments and then goes on the technical realization of the arthroscopic intervention itself, thus it gives all necessary details which are required for arthroscopy of the shoulder.

Springer-Verlag Wien New York



Mario Campanacci

Bone and Soft Tissue Tumors

**Co-authors of the Soft Tissue Section:
Franco Bertoni and Patrizia Bacchini**

Foreword: W. F. Enneking
Translator: Sylvia Notini
Translation from the Italian edition

1990. 881 figs. XI, 1131 pages.
Cloth with slipcase DM 548,-, öS 3.836,-
ISBN 3-211-82186-4

Prices are subject to change without notice

This book systematically treats the tumors of bones and soft tissues. An expert in the fields of pathology and orthopedic surgery, Professor Campanacci describes these tumors in terms of the pathological, clinical, radiographic, and therapeutic points of view. The introductory chapter deals with the classification, frequency, diagnostic tools, biopsies, and therapeutic strategies for these tumors. Following the histological classification, the author describes the primary, secondary, and metastatic tumors, and pseudotumoral lesions in detail.

Bone and Soft Tissue Tumors stems from both Professor Campanacci's 30 years of experience and from the clinical records of 15.000 studied and verified cases of the Istituto Ortopedico Rizzoli, the largest orthopedic clinic in Italy. The book contains illustrations of all varieties of tumors, with special emphasis on those cases which exemplify the typical tumors encountered in daily clinical practice. For the English edition the book has been completely revised and updated. The bibliography has been trimmed down to include only the most significant and recent publications. The addition of uniform subtitles makes this edition more concise and comprehensible.

Jointly published by **Springer-Verlag Wien New York**
and **Aulo Gaggi, Editore, Bologna**

Sole distribution rights: Springer-Verlag Wien New York

Springer-Verlag Wien New York



ISBN 3-211-82351-1
ISBN 0-387-82351-1